

# Ancient Schwannoma of the Thumb Pulp

Hajime Matsumine, MD,  
PhD\*†  
Masaki Takeuchi, MD, PhD‡

**Summary:** A 21-year-old woman had become aware of a mass on the palmar aspect of the distal phalanx of her left thumb 11 years earlier. Her medical history was unremarkable, with no traumatic injury of the left thumb. Initial examination revealed a hard but elastic, immovable tumor of 30×25 mm on the palmar aspect of the distal phalanx of the left thumb, with an ulcer formed at the center. No pain, sensory disturbance, or motor dysfunction was noted. The patient underwent punch biopsy at the outpatient clinic, and the tumor was histopathologically diagnosed as benign schwannoma. Total excision of the tumor was performed with digital nerve block under surgical microscope. Histopathological findings revealed a fibrous capsule covering the tumor, directional growth of tightly organized spindle-shaped cells, and mixed Antoni A and B patterns. The tumor also contained many various sized cysts and showed histological degenerative changes not observed in ordinary schwannoma, such as hemorrhage and prominent blood vessels with hyalinized walls. The S-100 stain was positive. Based on these findings, the patient was diagnosed as having ancient schwannoma. There was no evidence of infection, pain, complications such as ulcer formation, or recurrent tumor at 6 months postoperative. (*Plast Reconstr Surg Glob Open* 2015;3:e288; doi: 10.1097/GOX.0000000000000258; Published online 13 January 2015.)

**S**chwannoma is the most common soft-tissue tumor arising in the peripheral nerves. The majority of schwannomas develop in the head and neck region, and those arising in the distal upper limb, such as in the hand and wrist, account

for <1% of all cases.<sup>1,2</sup> In particular, schwannoma arising in the digits distal to the interphalangeal joint is extremely rare,<sup>3</sup> and only around 9% of all schwannomas of the hand arise in the thumb.<sup>4</sup> Ancient schwannoma, a subclass of schwannoma that shows degenerative changes during the long course of tumor formation, is also extremely rare in the distal hand region.<sup>5-7</sup> Ancient schwannoma is accompanied by various histological degenerative changes, such as cysts, hyalinization, angiogenesis, and atypical nuclei. Because of such histological changes, ancient schwannoma is often misdiagnosed as sarcoma or soft-tissue neoplasm in clinical practice.<sup>5</sup> To our knowledge, there have been no previous reports of ancient schwannoma in the distal phalanx of the thumb.

Here, the authors report an extremely rare case of ancient schwannoma arising on the palmar aspect of the distal phalanx of the thumb and provide a review of the literature.

From the \*Department of Plastic and Reconstructive Surgery, Tokyo Women's Medical University, School of Medicine, Shinjuku-ku, Tokyo, Japan; †Institute of Advanced Biomedical Engineering and Science, Tokyo Women's Medical University, School of Medicine, Shinjuku-ku, Tokyo, Japan; and ‡Department of Plastic Surgery, Yachiyo Medical Center, Tokyo Women's Medical University, Yachiyo-shi, Chiba, Japan.

Received for publication October 25, 2014; accepted November 13, 2014.

Copyright © 2015 The Authors. Published by Wolters Kluwer Health, Inc. on behalf of The American Society of Plastic Surgeons. All rights reserved. This is an open-access article distributed under the terms of the Creative Commons Attribution-NonCommercial-NoDerivatives 3.0 License, where it is permissible to download and share the work provided it is properly cited. The work cannot be changed in any way or used commercially.

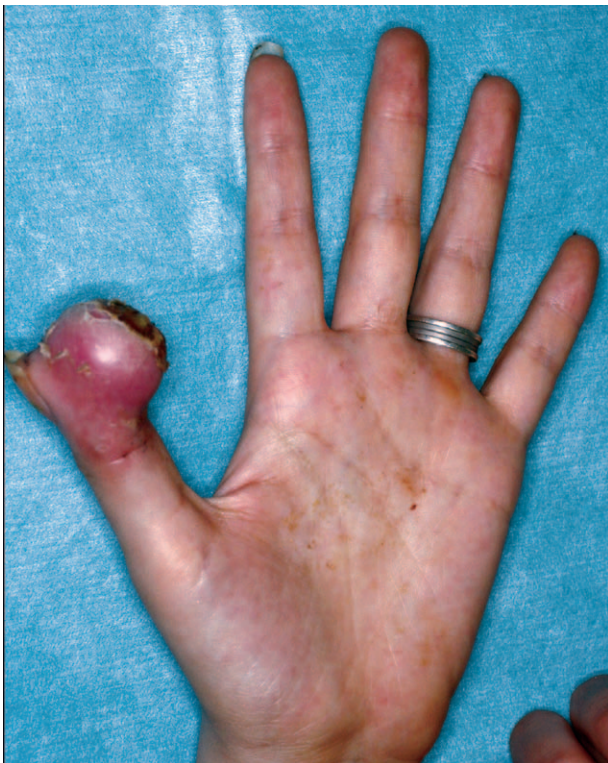DOI: 10.1097/GOX.0000000000000258

**Disclosure:** The authors have no financial interest to declare in relation to the content of this article. The Article Processing Charge was paid for by the authors.

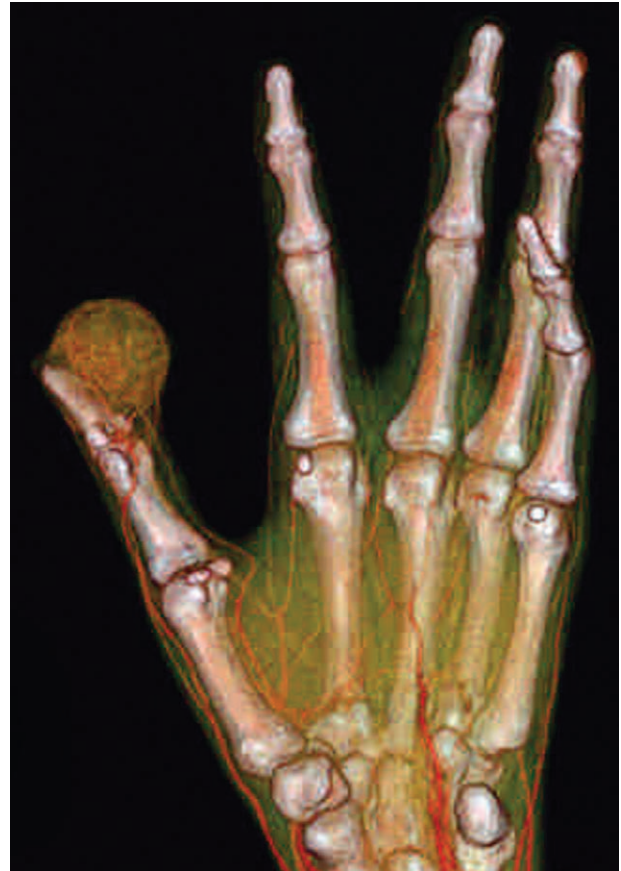## CLINICAL CASE

A 21-year-old woman had become aware of a mass on the palmar aspect of the distal phalanx of her left thumb 11 years earlier. The tumor had enlarged gradually over the years. Her medical history was unremarkable, with no traumatic injury of the left thumb. The tumor appeared to be sporadic, with no clinical findings indicative of neurofibromatosis. Despite occasional ulceration and fluid formation at its center, the patient was untroubled by the tumor and did not seek treatment before presenting to us with a large ulcerated lesion. Initial examination revealed a hard but elastic, immovable tumor of 30×25 mm on the palmar aspect of the distal phalanx of the left thumb, with an ulcer formed at the center (Fig. 1). Multidetector computed tomography (CT) of the tumor showed poor vascularization and no adherence to the distal phalanx of thumb or articular cavity (Fig. 2). No pain, sensory disturbance, or motor dysfunction was noted. The patient underwent punch biopsy at the outpatient clinic to screen for epidermal cyst, abscess due to penetration of a foreign object, and malignant tumor, and the tumor was histopathologically diagnosed as benign schwannoma.

Total excision of the tumor was subsequently performed with digital nerve block under surgical microscope. Despite adherence to the ulnar aspect of



**Fig. 1.** Clinical findings of ancient schwannoma. An indolent, hard but elastic, immovable skin tumor of 30×25 mm is present on the palmar aspect of the distal phalanx of the left thumb.

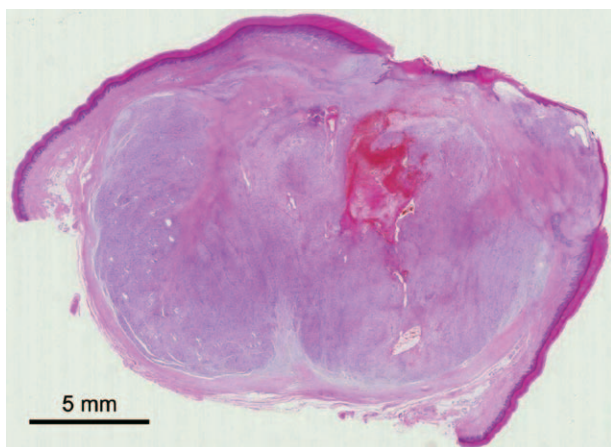


**Fig. 2.** Multidetector computed tomography findings. The tumor shows poor vascularization but no adherence to the surrounding bone.

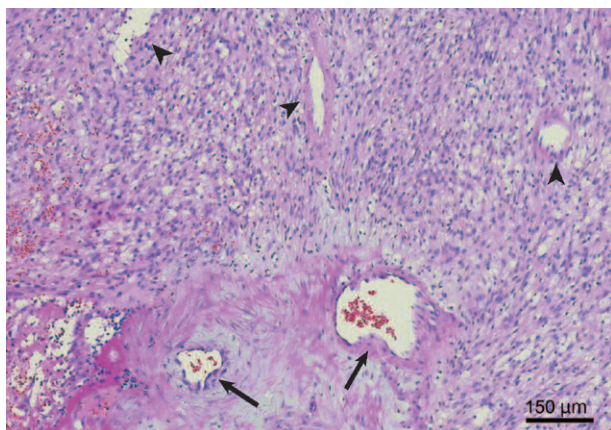
the distal digital nerve, the tumor was excised without injuring the nerve. Skin defect was reconstructed by grafting with artificial dermis.

Histopathological findings revealed a fibrous capsule covering the tumor, directional growth of tightly organized spindle-shaped cells, and mixed Antoni A and B patterns; specifically, the Antoni A region was characterized by Verocay bodies appearing as palisading oval nuclei, and the Antoni B region showed loosely organized cells that lacked the characteristic organization pattern and thus had morphological features of tumor cells. The tumor also contained many various sized cysts and showed histological degenerative changes not observed in ordinary schwannoma, such as hemorrhage and prominent blood vessels with hyalinized walls (Figs. 3, 4). The S-100 stain was positive. Based on these findings, the patient was diagnosed as having ancient schwannoma.

There was no evidence of infection, pain, complications such as ulcer formation, or recurrent tumor at 6 months postoperative, and the patient is scheduled to undergo reconstruction of the surgical site using a sensory flap.



**Fig. 3.** Low-magnification image of tumor tissue section stained with hematoxylin and eosin showing a fibrous tumor capsule, growth of tightly organized spindle-shaped cells. In the tumor, the formation of cysts with internal hemorrhage is apparent. Scale bar = 5 mm.



**Fig. 4.** High-power field image with hematoxylin and eosin stain showing newly formed blood vessels of different sizes (arrows) with hyalinization of the walls in the Antoni B region. Many cysts are scattered throughout the tumor (arrowheads). Scale bar = 150  $\mu$ m.

## DISCUSSION

In Ackerman and Taylor's<sup>8</sup> first report of ancient schwannoma in 1951, 10 of 48 neurogenous tumors of the thorax reviewed could be distinguished from typical neurilemmoma by the pronounced histological degenerative changes they had undergone. As many studies have reported,<sup>5</sup> ancient schwannoma tends to develop in areas deep inside the body where detection is relatively difficult (eg, in the head and neck or thoracic region, retroperitoneum, or pelvic cavity). In such cases, patients tend not to be aware of the schwannoma, resulting in delayed diagnosis and the discovery of ancient schwannoma after many years. Histopathologically, the tumor shows a mixture of Antoni type A and B patterns and may contain prominent blood vessels with hyalinized walls or cal-

cification. These degenerative changes are thought to be caused by insufficient blood flow due to the continuously enlarging tumor.<sup>9</sup> Our literature search for ancient schwannoma of the hand or finger revealed 1 report of ancient schwannoma arising in the middle finger.<sup>7</sup> Therefore, the present case seems to be the first of ancient schwannoma arising in the thumb and specifically the palmar aspect of the distal phalanx. White<sup>10</sup> reported schwannomas of the hand and wrist presenting with pain or tenderness and paresthesia in 89% and 59% of cases, respectively, but our patient experienced no pain and was not troubled by the schwannoma, leaving it untreated for many years until it eventually changed into ancient schwannoma.

Humber et al<sup>11</sup> performed preoperative CT imaging of ancient schwannoma in the upper lip and reported that the CT findings were extremely useful for accurate determination of the tumor margin and cystic degenerative changes. Multidetector CT findings in the present case were also useful in determining the location of the tumor relative to the distal phalanx and the size, spread, and internal structure of the tumor.

In general, schwannomas including ancient schwannomas are easy to excise because by definition they do not intertwine with the nerve fascicles, and therefore, nerve-sparing excision can be performed.<sup>12</sup> In the present case, damage to the digital nerve was avoided by gentle excision under microscopic visualization. Total excision with no need for margins is reported to be the only treatment for ancient schwannoma,<sup>13</sup> and postresection recurrence is rare.<sup>14</sup> Indeed, no recurrence was observed at 6 months postoperative in the present case following total excision. Although malignant transformation of ancient schwannoma is extremely rare,<sup>15</sup> caution must be paid when examining patients with ancient schwannoma because it is sometimes difficult to differentiate it from malignant tumors due to the presence of large cystic myxomatous areas with variable bizarre spindle cells and occasional mitoses.<sup>11</sup>

## CONCLUSIONS

The authors report on an extremely rare case of ancient schwannoma arising on the palmar aspect of the distal phalanx of the thumb. In the present case, multidetector CT findings were useful in determining the location of the tumor relative to the distal phalanx and the size, spread, and internal structure of the tumor.

*Hajime Matsumine, MD, PhD*

Department of Plastic and Reconstructive Surgery  
Tokyo Women's Medical University  
8-1 Kawada-cho  
Shinjuku-ku  
Tokyo 162-8666, Japan  
E-mail: matsumine@diary.ocn.ne.jp

## REFERENCES

1. Kransdorf MJ. Benign soft-tissue tumors in a large referral population: distribution of specific diagnoses by age, sex, and location. *AJR Am J Roentgenol.* 1995;164:395–402.
2. Myhre-Jensen O. A consecutive 7-year series of 1331 benign soft tissue tumours. Clinicopathologic data. Comparison with sarcomas. *Acta Orthop Scand.* 1981;52:287–293.
3. Rockwell GM, Thoma A, Salama S. Schwannoma of the hand and wrist. *Plast Reconstr Surg.* 2003;111:1227–1232.
4. Phalen GS. Neurilemmomas of the forearm and hand. *Clin Orthop Relat Res.* 1976;114:219–222.
5. Vlychou M, Dailiana ZH. Ancient schwannoma of the hand. *J Hand Surg Am.* 2011;36:2030–2033.
6. Isobe K, Shimizu T, Akahane T, et al. Imaging of ancient schwannoma. *AJR Am J Roentgenol.* 2004;183:331–336.
7. Tadvi JS, Anand A, Humphrey A. Ancient schwannoma of the middle finger. *J Hand Surg Eur Vol.* 2007;32:722.
8. Ackerman LV, Taylor FH. Neurogenous tumors within the thorax; a clinicopathological evaluation of forty-eight cases. *Cancer* 1951;4:669–691.
9. Vilanova JR, Burgos-Bretones JJ, Alvarez JA, et al. Benign schwannomas: a histopathological and morphometric study. *J Pathol.* 1982;137:281–286.
10. White NB. Neurilemmomas of the extremities. *J Bone Joint Surg Am.* 1967;49:1605–1610.
11. Humber CC, Copete MA, Hohn FI. Ancient schwannoma of upper lip: case report with distinct histologic features and review of the literature. *J Oral Maxillofac Surg.* 2011;69:e118–e122.
12. Payne WT, Merrell G. Benign bony and soft tissue tumors of the hand. *J Hand Surg Am.* 2010;35:1901–1910.
13. Forte A, Gallinaro LS, Bertagni A, et al. Neurinomas of the brachial plexus: case report. *Eur Rev Med Pharmacol Sci.* 1999;3:19–21.
14. Gravier S, Sinclair G, Kajani N. Ancient schwannoma of the foot. *J Foot Ankle Surg.* 1995;34:46–50.
15. Chu YC, Yoon YH, Han HS, et al. Malignant transformation of intrathoracic ancient neurilemmoma in a patient without Von Recklinghausen's disease. *J Korean Med Sci.* 2003;18:295–298.