











# Progressive encephalopathy due to chronic exposure to lead

## *Encefalopatia progressiva por exposição crônica ao chumbo*

Bárbara Cristina Vieira de Aquino<sup>1</sup>  Agábio Diógenes Pessoa Neto<sup>1</sup>   
Mariana Galvão de Lima Martins Freire<sup>2</sup>  Emanuela Coriolano Fidelix<sup>1</sup>   
Paulo Santiago de Moraes Brito<sup>1</sup>  Manuel Moreira Neto<sup>2</sup>  Rodrigo Alencar e Silva<sup>1</sup>   
Clécio de Oliveira Godeiro Junior<sup>1</sup> 

<sup>1</sup>Hospital Universitário Onofre Lopes, Departamento de Neurologia, Natal RN, Brazil.

<sup>2</sup>Hospital Universitário Onofre Lopes, Departamento de Radiologia, Natal RN, Brazil.

Address for correspondence Bárbara C. V. de Aquino (e-mail: barbaracvdeaquino@gmail.com).

Arq. Neuropsiquiatr. 2022;80(10):1079–1080.

A 70-year-old man reported a 2-year history of progressive gait imbalance and cognitive decline (memory, executive functions, and language impairment). A physical examination revealed spastic ataxia without peripheral involvement. The patient worked with car battery solutions for 40 years, until 13 years ago.<sup>1</sup> He had several hospitalizations due to acute lead poisoning, with levels of lead in the blood and urinary delta-aminolevulinic acid of 162,8 g/dl and 20 mg/U (normal: up to 40 g/dl and 4,5 mg/U) respectively). Recent brain neuroimages showed typical findings of saturnism (► **Figure 1**),<sup>2</sup> with normal bone profile blood tests. Therefore, chronic lead poisoning should be remembered as an environmental cause of leukoencephalopathy.<sup>2–5</sup>

### Authors' Contributions

BCVA, MGLMF: conception and organization of the research project, writing of the first draft; ADPN, ECF: execution of the research project, writing of the first draft; PSMB: conception of the research project, review, and critique; MMN: organization of the research project, review, and critique; RAS, COGJ: conception and organization of the research project, review, and critique.

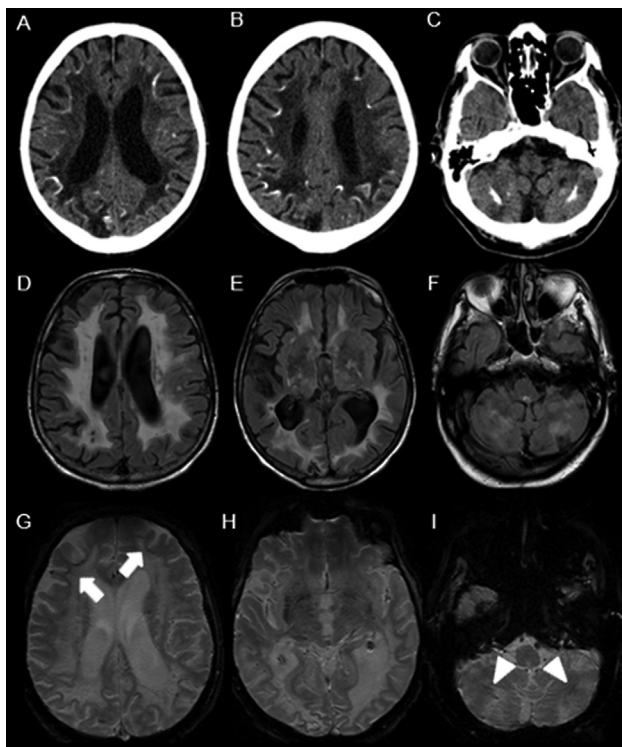
### Conflict of Interest

The authors have no conflict of interests to declare.

received  
January 27, 2022  
accepted  
May 1, 2022

DOI <https://doi.org/10.1055/s-0042-1758393>.  
ISSN 0004-282X.

© 2022. Academia Brasileira de Neurologia. All rights reserved. This is an open access article published by Thieme under the terms of the Creative Commons Attribution-NonDerivative-NonCommercial-License, permitting copying and reproduction so long as the original work is given appropriate credit. Contents may not be used for commercial purposes, or adapted, remixed, transformed or built upon. (<https://creativecommons.org/licenses/by-nc-nd/4.0/>)  
Thieme Revinter Publicações Ltda., Rua do Matoso 170, Rio de Janeiro, RJ, CEP 20270-135, Brazil



**Figure 1** Axial non-contrast computed tomography (CT) scan of the brain showing diffuse hypodensity in the deep white matter of both cerebral hemispheres with cerebellar and cerebral subcortical calcifications (A-C). Axial T2/fluid-attenuated inversion recovery (FLAIR) magnetic resonance imaging (MRI) scan showing confluent hypersignal in the periventricular, subcortical, and deep white matter of both cerebral hemispheres (D), the thalamus (E), and the cerebellar hemispheres (F), with hypointense areas involving the basal ganglia (E). Axial gradient echo (GRE) T2-weighted magnetic resonance imaging (MRI) scan showing subcortical white matter (G: arrows) with either microbleeds or mineralization in the basal ganglia (H) and cerebellar hemispheres (I: arrowheads).

## References

- 1 Landrigan PJ, Todd AC. Lead poisoning. *West J Med* 1994;161(02):153–159
- 2 Reyes PF, Gonzalez CF, Zalewska MK, Besarab A. Intracranial calcification in adults with chronic lead exposure. *AJR Am J Roentgenol* 1986;146(02):267–270
- 3 Mani J, Chaudhary N, Kanjalkar M, Shah PU. Cerebellar ataxia due to lead encephalopathy in an adult. *J Neurol Neurosurg Psychiatry* 1998;65(05):797–798
- 4 Manto M. Toxic agents causing cerebellar ataxias. *Handb Clin Neurol* 2012;103:201–213
- 5 Shih RA, Glass TA, Bandeen-Roche K, et al. Environmental lead exposure and cognitive function in community-dwelling older adults. *Neurology* 2006;67(09):1556–1562