

This is an Open Access article licensed under the terms of the Creative Commons Attribution-NonCommercial-NoDerivs 3.0 License (www.karger.com/OA-license), applicable to the online version of the article only. Distribution for non-commercial purposes only.

Usefulness of Microcatheters Inserted Overnight for Additional Injection of Sclerosant after Initial Balloon-Occluded Retrograde Transvenous Obliteration of Gastric Varices

Tetsuo Sonomura^a Shinya Sahara^a Wataru Ono^b
Morio Sato^a Nobuyuki Kawai^a Hiroki Minamiguchi^a
Motoki Nakai^a Kazushi Kishi^a

^aDepartment of Radiology, Wakayama Medical University, Wakayama, and

^bDepartment of Gastroenterology, Kishiwada Tokushukai Hospital, Kishiwada, Japan

Key Words

Balloon-occluded retrograde transvenous obliteration · Gastric varices · Microcatheter

Abstract

In patients with large gastric varices, dose limitation of the sclerosant can cause difficulties in achieving complete thrombosis of varices during a single balloon-occluded retrograde transvenous obliteration (BRTO) procedure. For patients with incomplete variceal thrombosis after the first BRTO, additional sclerosant must be injected in a second BRTO. We report a successful case of BRTO for large gastric varices in whom additional sclerosant was injected through a microcatheter that remained inserted overnight. To achieve complete variceal thrombosis in a patient with incomplete thrombosis of large gastric varices after a first BRTO, a retained microcatheter can be used to inject additional sclerosant in a second BRTO the next day.

Introduction

Gastric varices have a larger blood flow compared with esophageal varices, so when they are ruptured, there is a high mortality rate [1]. Therefore, prophylactic treatment is necessary in patients with gastric varices in danger of rupture. Balloon-occluded

retrograde transvenous obliteration (BRTO), which was introduced by Kanagawa et al., is a treatment for gastric varices that is minimally invasive and has a high success rate [2–4]. During the procedure, sclerosant is injected into the gastrosplenic shunt and into the gastric varices. The sclerosant induces thrombosis of the shunt and varices. Sufficient filling and stagnation of the sclerosant in the entire variceal complex is essential for a successful BRTO. However, in patients with large gastric varices, it may be difficult to achieve complete thrombosis of the varices in one BRTO procedure because of dose limitations of the sclerosant. For patients with incomplete thrombosis of the varices after a first BRTO, additional sclerosant must be injected in a second BRTO. However, the first BRTO commonly occludes the gastrosplenic shunt, so if the microcatheter is removed, additional injection of sclerosant is prevented because the balloon catheter is very far from the gastric varices. To overcome this problem, we navigated a microcatheter close to the gastric varices, through the balloon catheter, and kept the microcatheter inserted overnight. Additional sclerosant can then be injected through the microcatheter close to the varices in a second BRTO the following day, even when occlusion of the gastrosplenic shunt occurs. We treated a case of large gastric varices that required an additional injection of sclerosant using the method of overnight microcatheter insertion.

Case Report

A 68-year-old woman with large gastric varices caused by liver cirrhosis associated with hepatitis C, which were in danger of rupture, was admitted to our hospital for BRTO. Blood examination on admission was as follows: T-Bil 1.36 mg/dl, AST 80 IU/l, ALT 66 IU/l, ChE 115 IU/l, Alb 3.1 g/dl, Plt 76,000/ μ l, PT 80%. Her liver function was evaluated as Child-Pugh class B. Contrast-enhanced CT showed large varices in the fornix of the stomach and the presence of a gastrosplenic shunt (fig. 1a), while endoscopy revealed bulky gastric varices (fig. 2a).

An 8-Fr sheath (Cobra type; Medikit, Tokyo, Japan) was inserted into the left renal vein through the right internal jugular vein, by ultrasound-guided puncture, and a 6-Fr balloon catheter (balloon diameter of 20 mm, Cobra type; Clinical Supply, Gifu, Japan) was inserted into the gastrosplenic shunt. A 3-Fr microcatheter was navigated close to the gastric varices through the balloon catheter, and 19 ml of 5% ethanolamine oleate iopamidol (EOI) sclerosant was selectively injected into the varices through the microcatheter during balloon occlusion (fig. 3a). Twenty milliliters of 5% EOI solution was prepared by mixing 10 ml of contrast medium with 10 ml of 10% ethanolamine oleate (Oldamin; Grelan Pharmaceutical, Tokyo, Japan). The microcatheter remained in position overnight.

Contrast-enhanced CT performed the morning after the first BRTO showed incomplete thrombosis of the gastric varices (fig. 1b). A second BRTO was performed by injecting additional sclerosant (15 ml of 5% EOI) through the microcatheter that had been left inserted overnight (fig. 3b). Contrast-enhanced CT obtained 7 h after the second BRTO showed complete thrombosis of the gastric varices (fig. 1c), and all catheters were removed. There were minor complications of ascites, left pleural effusion and a high fever. A small amount of ascites increased in volume slightly, and a small amount of left pleural effusion appeared after the BRTO procedures, while the fever lasted several days between 37°C and 39°C. No major complications such as liver or renal failure were experienced. Contrast-enhanced CT (fig. 1d) and endoscopy (fig. 2b) 3 months after BRTO showed complete disappearance of the varices.

Discussion

Several benefits of microcatheters in BRTO are reported [5–7]. Selective injection of sclerosant through a microcatheter close to the gastric varices enables the use of a decreased dose of sclerosant, thus preventing sclerosant-related complications. Microcoil embolization of the collateral veins prevents leakage of sclerosant into the systemic

circulation. However, there are no reports regarding an additional injection of sclerosant through a microcatheter that has been left inserted overnight. After complete thrombosis of gastric varices has been confirmed on contrast-enhanced CT the next day, all catheters are removed. Since the first BRTO commonly occludes the gastrosplenic shunt, preventing additional injection of sclerosant through the balloon catheter far from the gastric varices, it is beneficial to keep the microcatheters inserted until complete thrombosis of the varices can be achieved. Overnight retention of a microcatheter close to the gastric varices enables an additional injection of sclerosant into the varices through the microcatheter the following day, even when occlusion of the gastrosplenic shunt occurs.

In performing additional injections, the microcatheter should be withdrawn by approximately 0.5–1.0 cm prior to each additional injection to avoid pain and extravasation of the sclerosant. This procedure enables the sclerosant to be injected into patent spaces, resulting in complete thrombosis of the gastric varices.

Conclusion

To achieve complete variceal thrombosis in a patient with incomplete thrombosis of large gastric varices after a first BRTO, a retained microcatheter can be used to inject additional sclerosant in a second BRTO the next day, even when occlusion of the gastrosplenic shunt occurs.

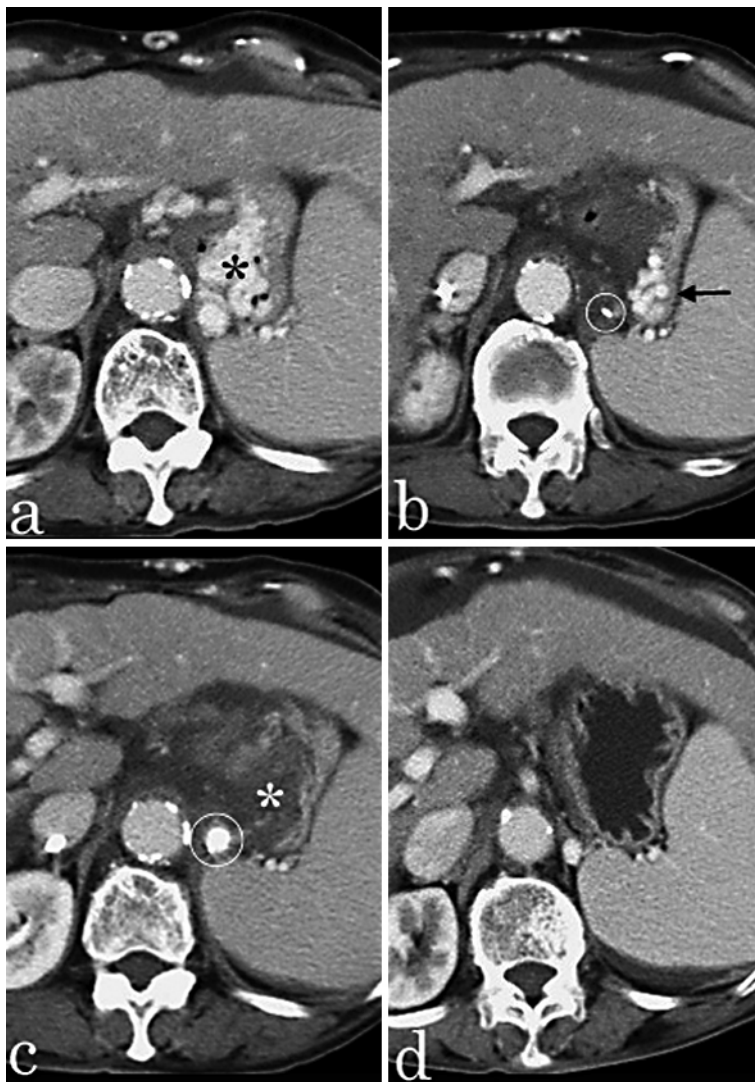


Fig. 1. Contrast-enhanced CT scans showing gradual disappearance of gastric varices after two BRTO procedures. **a** Large varices (asterisk) are seen in the stomach before BRTO. **b** Residual varices (arrow) are seen in the lateral portion of the stomach after the first BRTO. The microcatheter tip (circle) is in the gastroduodenal shunt close to the varices. **c** Complete thrombosis of the varices (asterisk) is achieved after the second BRTO. The sclerosant with contrast medium (circle) is detected in the gastroduodenal shunt. **d** No gastric varices are visible 3 months after the BRTO procedures.

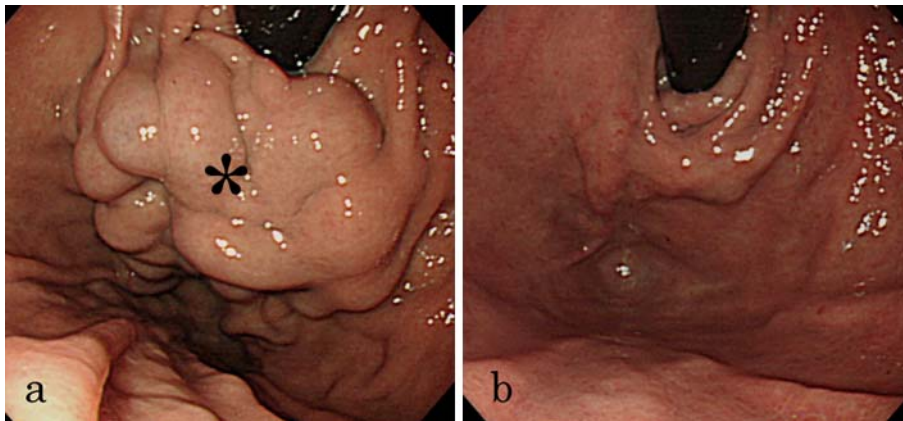


Fig. 2. Endoscopy showing disappearance of the gastric varices. **a** Bulky varices (asterisk) are seen in the fornix of the stomach before BRTO. **b** No gastric varices are visible 3 months after the BRTO procedures.

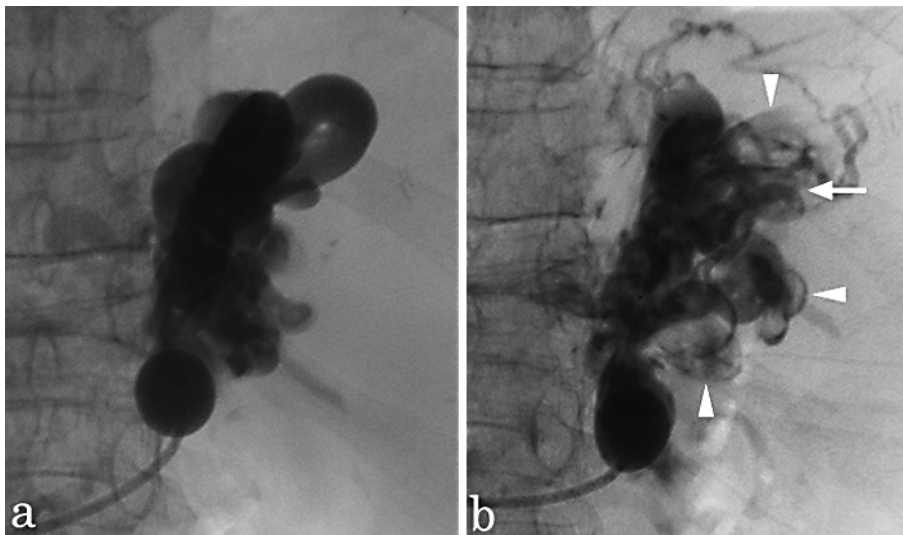


Fig. 3. Fluoroscopy showing partial thrombosis of the gastric varices during the BRTO procedures. **a** The gastric varices and gastrorenal shunt are fully opacified by the sclerosant with contrast medium during the first BRTO. **b** The varices and shunt show partial opacification during the second BRTO, suggesting residual varices (arrow) and thrombosis of the varices and shunt (arrowheads).

References

- 1 Trudenau W, Prindiville T: Endoscopic injection sclerosis in bleeding gastric varices. *Gastrointest Endosc* 1986;32:264–268.
- 2 Kanagawa H, Mima S, Kouyama H, Gotoh K, Uchida T, Okuda K: Treatment of gastric fundal varices by balloon-occluded retrograde transvenous obliteration. *J Gastroenterol Hepatol* 1996;11:51–58.
- 3 Sonomura T, Sato M, Kishi K, et al: Balloon-occluded retrograde transvenous obliteration for gastric varices: a feasibility study. *Cardiovasc Intervent Radiol* 1998;21:27–30.
- 4 Hirota S, Matsumoto S, Tomita M, Sako M, Kono M: Retrograde transvenous obliteration of gastric varices. *Radiology* 1999;211:349–356.
- 5 Takahashi K, Yamada T, Hyodoh H, et al: Selective balloon-occluded retrograde sclerosis of gastric varices using a coaxial microcatheter system. *AJR Am J Roentgenol* 2001;177:1091–1093.
- 6 Kiyosue H, Mori H, Matsumoto S, Yamada Y, Hori Y, Okino Y: Transcatheter obliteration of gastric varices: part 2. Strategy and techniques based on hemodynamic features. *Radiographics* 2003;23:921–937.
- 7 Sonomura T, Horihata K, Yamahara K, et al: Ruptured duodenal varices successfully treated with balloon-occluded retrograde transvenous obliteration: usefulness of microcatheters. *AJR Am J Roentgenol* 2003;181:725–727.