

Scleral fixation of hydrophobic acrylic intraocular lenses using a suture burial technique

Emre Altinkurt, Gizem Sayar Bilgin

The procedure involved an ab-externo scleral fixation technique using a double-armed 10-0 polypropylene suture with straight needles that require no scleral flaps. The IOLs are sutured to the sclera, the free suture ends are tied to the suture loops, and they are buried together under the sclera. Forty eyes of 37 patients were included. Postoperative complications are IOL capture in five eyes (12.5%), a significant IOL tilt in one eye (2.5%), recurrent UGH (uveitis-glaucoma-hyphema) syndrome in two eyes (5%), glaucoma in three eyes (7.5%), suture exposure in two eyes (5%) and IOL drop due to haptic breakage in one eye (2.5%). The technique can be effectively used for the refixation of dislocated hydrophobic acrylic IOLs by temporary haptic externalization through a corneal incision and for the treatment of aphakia with or without penetrating keratoplasty. Surgeons should be aware of the possibility of UGH syndrome due to IOL capture, especially in young eyes.

Key words: Aphakia, intraocular lens implantation, sclera, suture technique, uveitis

Conventional posterior chamber (PC) intraocular lenses (IOLs) for scleral fixation have rigid polymethylmethacrylate (PMMA) optics with diameters of 6 to 7 mm; therefore, they require a large corneoscleral incision. This large incision may result in slow visual recovery, intraoperative hypotony, and detachment of the retina.^[1,2] For this reason, single-piece acrylic (SPA) foldable IOLs have been used for scleral fixation to reduce the size of the surgical wounds.^[3-5] Specially designed, SPA foldable IOLs have been designed for transscleral suture fixation, but they are not useful for in-the-bag implantation because of their large haptic size.^[6] Also, additional cost and space are required to store them. Foldable SPA IOLs in appropriate diopters can easily be found in the operating theaters. They may be fixed to the sclera during phacoemulsification when a posterior capsule tear occurs, rather than switching to another back-up IOL. Dislocated foldable SPA IOLs can also be fixed to the sclera without removal from the eye, so no corneal incision enlargement is needed.

There are popular intrascleral haptic fixation techniques for 3-piece IOLs, and they have several advantages, including faster surgery and no need for scleral dissection. However, the insertion of the second haptic into a needle is challenging, and it can cause iris or ciliary body damage during surgery.^[7,8] Haptic breakage may also occur,^[8] and the IOL may drop into the vitreous cavity during implantation.^[9]

The suture burial technique (SBT) described by Baykara is an ab-externo scleral fixation technique that does not need

any scleral flaps.^[10] It may be performed with a double-armed 10-0 polypropylene suture on a long straight needle.^[10] The long-term results of this technique with PMMA IOLs have been published previously,^[11] but the results of SBT with hydrophobic acrylic IOLs have not been reported. The aim of this study was to evaluate the results of the scleral fixation of foldable hydrophobic acrylic IOLs by SBT.

Surgical Technique

The study was conducted in agreement with the ethical standards established in the Declaration of Helsinki and endorsed by the local clinical research ethics committee. Informed consent for clinical research and publication of patient findings and images was obtained from all participating subjects. If the patients were in pediatric age, informed consent was gathered from their parents or legal guardians.

The data for patients who underwent scleral fixation surgery with SBT with hydrophobic acrylic IOLs between January 2016 and August 2020 were retrospectively reviewed. All operations were performed by the same surgeon (EA). All patients underwent visual acuity assessment, biomicroscopic examination, intraocular pressure (IOP) measurement, and dilated fundus examination preoperatively and then on the postoperative first week, the first month, and third month and then every three months. Biometric

This is an open access journal, and articles are distributed under the terms of the Creative Commons Attribution-NonCommercial-ShareAlike 4.0 License, which allows others to remix, tweak, and build upon the work non-commercially, as long as appropriate credit is given and the new creations are licensed under the identical terms.

For reprints contact: WKHLRPMedknow_reprints@wolterskluwer.com

Cite this article as: Altinkurt E, Sayar Bilgin G. Scleral fixation of hydrophobic acrylic intraocular lenses using a suture burial technique. Indian J Ophthalmol 2021;69:1600-4.

Videos Available on:
www.ijo.in

Access this article online

Website:
www.ijo.in

DOI:
10.4103/ijo.IJO_3151_20

Quick Response Code:



Istanbul University, Istanbul Faculty of Medicine, Department of Ophthalmology, Istanbul, Turkey

Correspondence to: Dr. Emre Altinkurt, Istanbul University, Istanbul Faculty of Medicine, Department of Ophthalmology, 34093 Fatih/Capa, Istanbul, Turkey. E-mail: altinkurtemre@gmail.com

Received: 04-Oct-2020

Revision: 07-Feb-2020

Accepted: 14-Feb-2021

Published: 21-May-2021

measurements of the patients were obtained by optical (IOL Master 500, Carl Zeiss Meditec, Inc., USA) or ultrasound biometry (OcuScan RxP, Alcon Laboratories, Inc., USA).

All cases underwent anterior vitrectomy accompanied by triamcinolone acetonide injection. A conjunctival peritomy was performed in the nasal and temporal quadrants, and the anterior chamber (AC) maintainer was inserted [Fig. 1]. Diathermy was applied to the sclera, a 3.2 mm temporal clear corneal tunnel incision was made, and then one arm of a double-armed 10-0 polypropylene suture (Visionary Medical 10-0 Sutralene 1 × 8" St000-6 double-armed) on a long straight needle was inserted into the eye, 3 mm behind the surgical limbus, through the sclera and was then taken out with the guidance of a 27-gauge peribulbar needle (Teknomek peribulbar Atkinson 0.40 × 22 mm) from the opposite side. The 10-0 suture was pulled out through the tunnel incision using a Kuglen hook. The IOL was then loaded into the cartridge and injected into the AC onto the iris, while the trailing haptic was left outside the eye. The 10-0 suture was cut in the center. One end of the suture was tied to the trailing haptic, and the haptic was placed into the AC. The IOL was dialed clockwise.

After the leading haptic was externalized and tied, the IOL was implanted into the PC. After one more bite on the sclera, the sutures were tied to themselves and buried in the sclera as described by Baykara.^[10] The conjunctiva was closed with an 8-0 vicryl suture. The video of a routine surgery is in Video 1 and the detailed video of the suture burial technique is in Video 2.

If the surgery was needed due to IOL dislocation, the patient's own IOL was used. The haptics of the IOL were externalized and tied through the corneal tunnel. In cases that were combined with penetrating keratoplasty (PK), the suture was first passed through the sclera, and then the recipient bed was prepared. After the suture was tied onto the haptics and the IOL was implanted in the PC, the corneal graft was sutured onto the recipient bed. If the surgery was performed due to lens subluxation or microspherophakia, then scleral fixation surgery was performed after lensectomy surgery.

Visual acuity of all cases was converted to logMAR, and the paired sample t-test and SPSS Statistics V21.0 were used. A value of $P < 0.05$ was accepted as statistically significant.

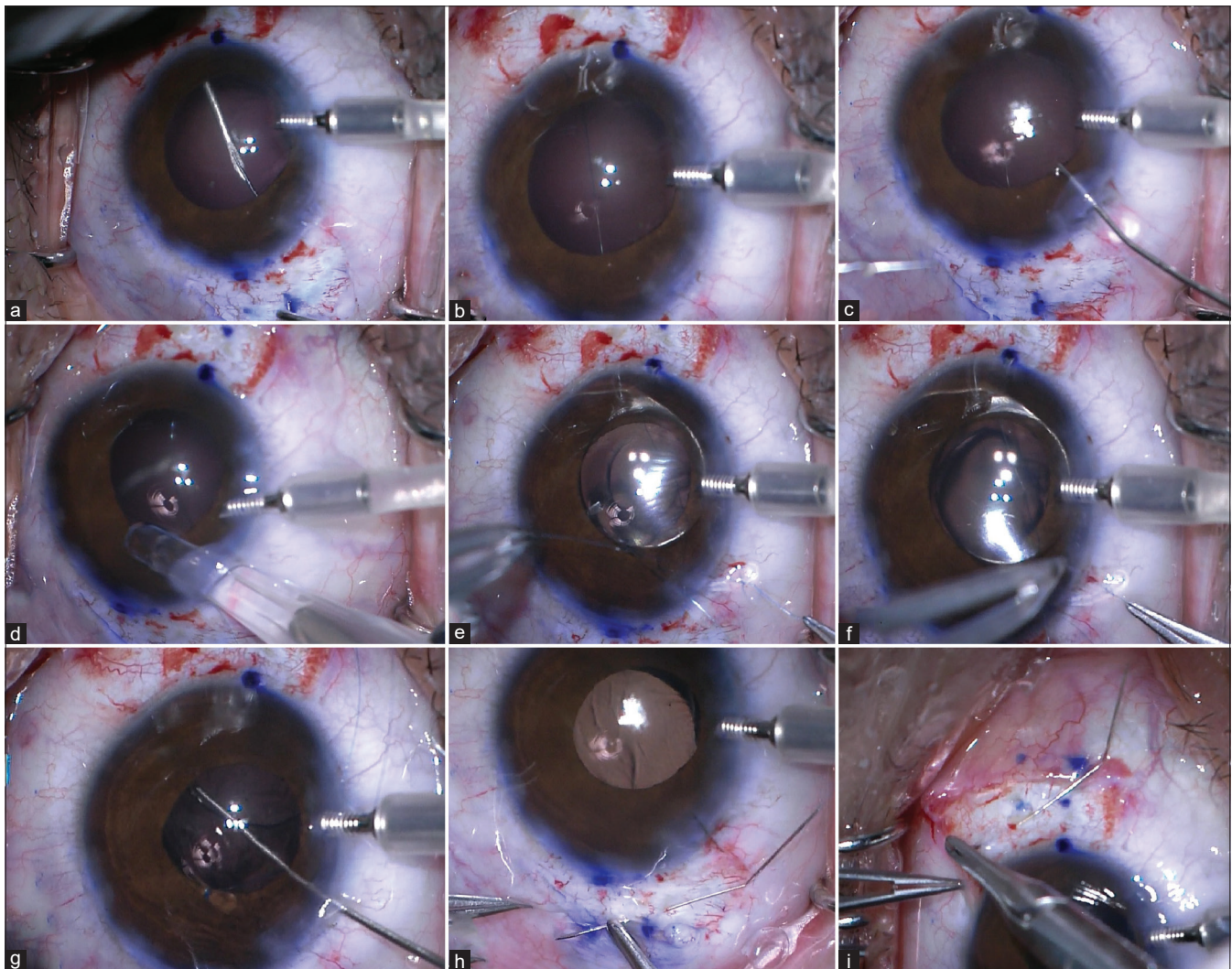


Figure 1: Steps of the surgery: (a) Inserting the 27-gauge peribulbar needle into the straight needle of the suture (b) Polypropylene suture is inside the eye (c) Pulling out the suture with Kuglen hook through the corneal incision (d) Implanting the IOL onto the iris (e) Suturing the trailing haptic (f) Externalizing and suturing the leading haptic after the IOL is dialed (g) Implanting the IOL into the posterior chamber (h) Suturing the polypropylene suture to the sclera (i) Burying the suture into the sclera

Results

Forty eyes of 37 patients were included in the study. The mean patient age was 50.4 ± 21.1 years (6–78 years). The mean follow-up time was 17.3 ± 7.7 months. The surgical indications and the IOLs used in the operations are listed in Table 1.

The preoperative mean uncorrected visual acuity (UCVA) (1.40 ± 0.7 logMAR) and postoperative mean UCVA (0.84 ± 0.60 logMAR) were significantly different ($P=0.006$). The preoperative mean best-corrected visual acuity (BCVA) (0.62 ± 0.72 logMAR) and postoperative mean BCVA (0.45 ± 0.63 logMAR) were also significantly different ($P=0.042$). The postoperative mean spherical refraction was 0.32 ± 1.34 D and the postoperative mean astigmatism was -2.28 ± 2.31 D.

Intraoperative complications

When the 27-gauge peribulbar needle was pulled out, the proximal end of the straight needle of the polypropylene suture became stuck in the sclera in one eye. It was hung up in the eye, attached to the inside of the sclera, but no part of the needle was outside the eye. Therefore, it could not be pulled out from outside the eye. To prevent the suture from breaking, the surgeon pushed the needle from the inside to the outside of the eye with a serrated 23-gauge forceps by pars plana approach using a wide-angle viewing system and 23-gauge illumination.

After the IOL was implanted, the part of the thread that was outside of the eye was broken in 4 (10%) eyes while the thread was being sutured (2 eyes) or buried into the sclera (2 eyes) in the study. The threads were tied to each other using a European death knot style, and the surgery was continued.

Postoperative complications

One of the haptics was broken one week after surgery in one eye (2.5%). The IOL (AcrySof SA60AT) dropped into the vitreous cavity. Pars plana vitrectomy was performed, and the IOL was removed. Explantation of the intraocular lens due to the broken of one haptic is in Video 3.

IOL capture was seen in five (12.5%) eyes. IOL decentralization of 1 mm in two (5%) eyes and an IOL decentralization of 2 mm with a significantly IOL tilt that induced 2 D lenticular astigmatism was seen in one (2.5%) eye.

Inflammation occurred two weeks after surgery in one (2.5%) eye in an eight-year-old patient (AcrySof SA60AT) who had undergone surgery due to microspherophakia. Intermittent IOL capture was observed during the biomicroscopic examination, and the inflammation subsided following topical steroid therapy for two weeks. No hyphema and no increase in IOP was seen in the eye.

Table 1: The surgical indications and the IOLs used in the operations

	AcrySof SA60AT	AcrySof SN60WF	Total
Aphakia	13	1	14
IOL dislocation*	10	2	12
Corneal leukoma** +aphakia	9		9
Crystalline lens subluxation***	1	2	3
Microspherophakia***	2		2
Total	35	5	40

*The patient's own IOL was used. **Penetrating keratoplasty was performed.

***Lensectomy was performed

Recurrent uveitis-glaucoma hyphema (UGH) syndrome was diagnosed in two (5%) eyes of two different patients (28 and 32 years old). Intermittent IOL (AcrySof SA60AT) capture and blurred vision occurred in a sudden head down position in both patients. During the follow-up period, uveitis attacks were seen mean 3.5 ± 0.7 times in these eyes. Their inflammation was resolved with topical steroid therapy. No cystoid macular edema (CME) was captured in the macular optical coherence tomography of these eyes. The 28-year-old patient was not using any glaucoma medication, but the 32-year-old patient [Fig. 2], whose surgery was combined with PK, used three different glaucoma medications at the last visit.

Three (7.5%) patients who did not have glaucoma preoperatively used a mean of 2.3 ± 0.6 glaucoma medications after surgery in the study. In two of them, IOL capture was seen. None of the patients in the study needed any glaucoma surgery. Suture exposure was seen in two (5%) eyes.

Discussion

Scleral fixation of foldable hydrophobic acrylic IOLs using the SBT is a useful technique for treating aphakia and IOL dislocation, but some challenges arise during some steps of the surgery. The manipulation of the straight needle of 10-0 polypropylene is rugged so bending both the 27-gauge peribulbar needle and the needle of 10-0 polypropylene nearly 30 degrees at the junction of 1/3 proximal side and 2/3 distal (pointed) side of the body of the needles is advocated.

In some cases, the needle of 10-0 polypropylene does not stick into the lumen of the 27-gauge needle sufficiently. In this case, when the 27-gauge needle is pulled out of the eye, the needle of 10-0 polypropylene may come off the 27-gauge needle and may drop into the vitreous cavity. This step can be made more secure by pushing the needle of 10-0 polypropylene with a 23-gauge serrated micro forceps through the main corneal incision as the 27-gauge peribulbar needle is pulled out of the eye.

One of the haptics of an implanted AcrySof SA60AT IOL was broken one week after surgery in one eye. The hydrophobic acrylic IOLs and 10-0 polypropylene are both made of fragile materials. The suture's tension on the haptics must be carefully adjusted to avoid cutting the haptics.^[12]

The thread outside of the eye was broken in four eyes (10%) in this study during burying and suturing to the sclera. Therefore, surgeons should be familiar with the techniques to tie the threads' broken ends to each other.

Suture exposure through the conjunctiva was seen in two eyes in the study, and it may cause endophthalmitis.^[13,14] Leaving the free suture ends under a scleral flap reduces this risk,^[15] but scleral dissection and hemostasis are needed to make scleral flaps and are time-consuming. Additionally, scleral flaps may affect corneal curvature and induce astigmatism.^[16]

The SBT does not require any scleral flaps, but it needs conjunctival dissection, so it is not very suitable for eyes with scarred conjunctiva from previous surgery. Conjunctival dissection may also induce ocular surface scarring, so eyes that require glaucoma surgery in the future are not good candidates for the SBT.

In the study, inflammation two weeks after surgery was observed in one eye (8-year-old patient), and UGH was seen in two eyes (28 and 32-year-old patients). AcrySof SA60AT was implanted in all three of these eyes. Intermittent IOL capture occurred with sudden head down positions in the patients with UGH syndrome. In terms of preventing postoperative IOL capture, keeping the eye normotensive

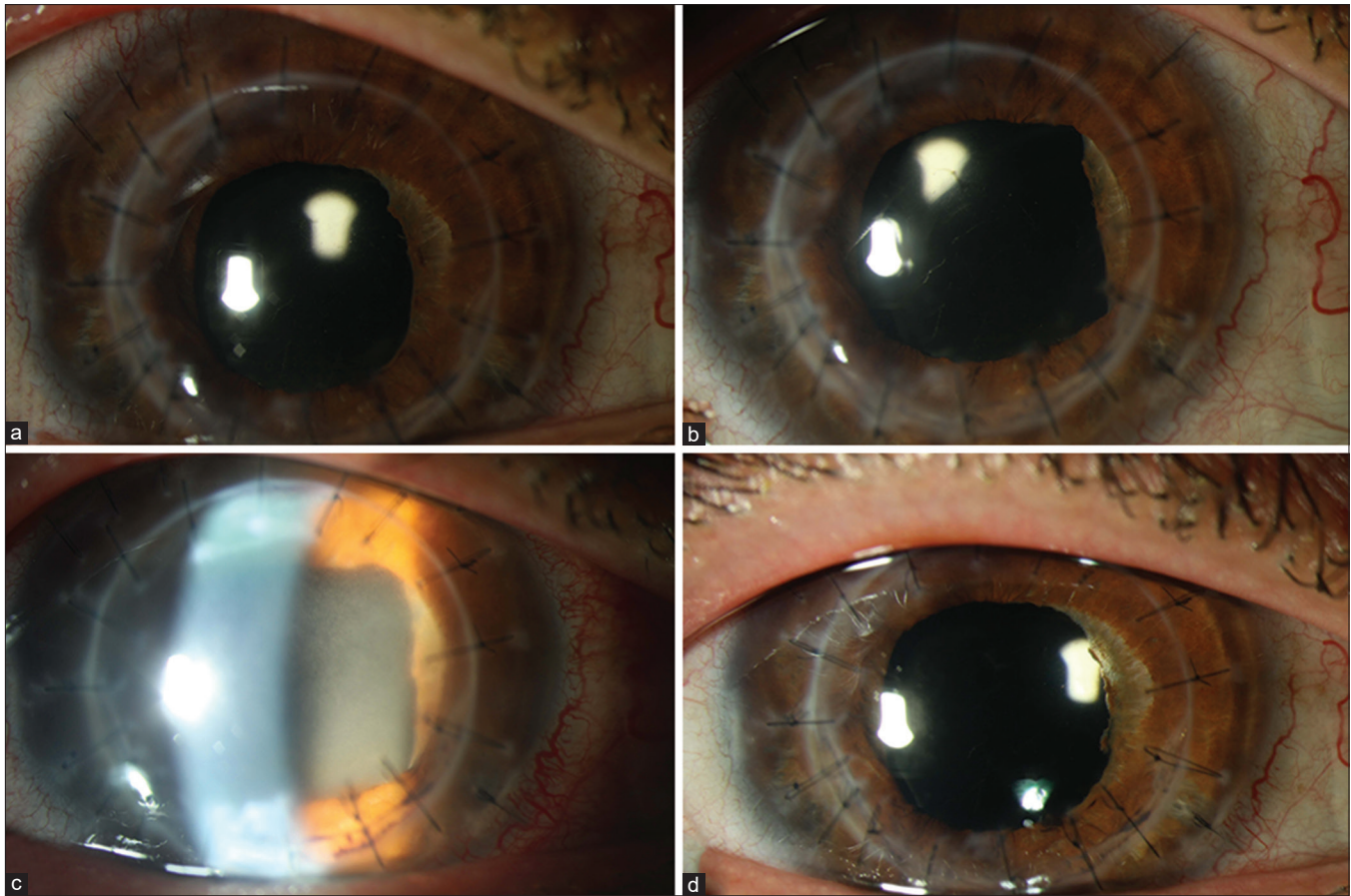


Figure 2: UGH syndrome and intermittent IOL capture in a 32-years old patient in a sudden head down position (a) No IOL capture during biomicroscopic examination on postoperative 4th month (b) IOL capture occurred in a sudden head down position in the same examination (c) Patient presented with IOL capture and UGH syndrome on postoperative 7th month (d) After several IOL capture and 4 UGH attacks, iris atrophy is evident on postoperative 14th month

helps control the suture's tension during surgery.^[17] If the IOP is high, the IOL will stretch during the surgery, and when the IOP decreases, the IOL will then be loose, and IOL capture may occur postoperatively. All three of our patients who had postoperative inflammation were relatively young. Younger and myopic patients have larger pupils in scotopic conditions,^[18] and pupillary capture of the IOL is more common in younger patients.^[19] So young or myopic eyes may be more prone to chafing of the iris pigment epithelium from the haptics of hydrophobic acrylic IOLs. Hydrophilic acrylic materials had better uveal biocompatibility,^[20] and the use of hydrophilic acrylic IOLs for scleral fixation surgery may be better in these patients to avoid UGH syndrome. However, dystrophic optic opacification has been reported with hydrophilic acrylic IOLs,^[21] surgeons should consider this possible complication. Inflammation and IOP in UGH syndrome can be controlled by medical treatment, and YAG laser iridotomy can be used in eyes with reverse pupillary block.^[22] If these procedures do not work, then surgical removal of the IOL is recommended.^[23]

SBT technique creates free suture ends while tying the threads on the IOL's haptics. Although it is not reported in some studies,^[4,15,24] free suture ends may provoke iris chafing and inflammation by rubbing on the ciliary body and iris. Cow-hitch knots have been proposed to avoid this problem.^[3] However, cow-hitch knots are slack, and they may slip along the haptics and unravel over the haptic end.^[21] Some SPA IOLs have closed haptics or eyelets and spaces that facilitate suturing

and make the surgery safer.^[3,16,21,25-27] Using a cow-hitch knot with those kinds of IOLs may be less likely to irritate the iris.

The puncture point location ranges from 0.5–3 mm posterior to the corneal limbus in the literature.^[3-5,16,27,28] The sclera was punctured 3 mm posterior to the corneal limbus instead of at a closer point to reduce the possibility of iris chafing and vitreous hemorrhage from ciliary processes, and we observed no vitreous hemorrhage in our study. We believe that puncturing the sclera more posteriorly reduces the possibility of bleeding.

IOL decentralization was seen in three eyes in our study. The patients were rehabilitated with eyeglasses, but the patient with a significant IOL tilt was not satisfied with his glasses. Instability of the acrylic material's haptic-optic junction creates difficulties in positioning the hydrophobic acrylic IOLs in eyes with a larger horizontal corneal diameter.^[29] Tilts greater than 15 degrees induce coma aberration that cannot be corrected with eyeglasses and result in significant visual disturbances.^[30] To avoid this problem, some authors advocate four-point fixation techniques.^[25]

The long-term stability of our technique remains unknown. Suture-fixated PC IOLs can dislocate due to the suture material's degradation, necessitating surgical repair.^[31] Suture degradation and breakage may be minimized using larger diameter (9-0 instead of 10-0) polypropylene suture material^[32] or polytetrafluoroethylene sutures.^[33]

The SBT technique can also be used for scleral fixation of dislocated hydrophobic acrylic IOLs by temporary haptic externalization. Repositioning dislocated IOLs can provide the same vision as before dislocation, and it also avoids enlarging the corneal incision to remove the IOL.^[34]

Baykara and Timucin used PMMA IOLs with SBT, and they did not observe any chronic low-grade inflammation or increased IOP throughout the 24 months of follow-up.^[11] Kaya *et al.* used modified Z Baykara SBT with PMMA IOLs and reported 4.5% suture erosion, 2.2% IOL tilt, and % 4.5 CME which resolved with intravitreal triamcinolone acetamide injections.^[35] Many studies have described scleral fixation of different SPA acrylic IOLs with different techniques.^[3-5,16,21,25-28] None of these eyes showed any complications, such as chronic low-grade inflammation, iris chafing, pigment dispersion, UGH syndrome, IOL decentration, or IOL tilt. Only CME was observed in three eyes,^[3,16] and one of them^[16] was resolved with intravitreal triamcinolone acetamide injections.

Conclusion

Our study showed that the SBT could be used for the scleral fixation of hydrophobic acrylic IOLs, even with PK. This technique is advantageous when no back-up IOL is available in the operation room. The study population of the present study is small, and the nature of the study is retrospective, so our data should be confirmed by other studies with larger clusters of cases.

Financial support and sponsorship

Nil.

Conflicts of interest

There are no conflicts of interest.

References

- Hayashi K, Hayashi H, Nakao F, Hayashi F. Intraocular lens tilt and decentration, anterior chamber depth, and refractive error after trans-scleral suture fixation surgery. *Ophthalmology* 1999;106:878-82.
- Wang Z, Lu Y, Xiao K, Gao Y, He J, Zhang S, *et al.* Bimanual irrigation-aspiration for ectopia lentis and use of a small incision for 4-point scleral-sutured foldable intraocular lens and anterior vitrectomy in patients with Marfan syndrome. *Indian J Ophthalmol* 2019;67:1629-33.
- Taskapili M, Gulikilig G, Engin G, Kocabora MS, Yilmazli C, Ozsutcu M, *et al.* Transscleral fixation of a single-piece hydrophilic foldable acrylic intraocular lens. *Can J Ophthalmol* 2007;42:256-61.
- Kim SJ, Lee SJ, Park CH, Jung GY, Park SH. Long-term stability and visual outcomes of a single-piece, foldable, acrylic intraocular lens for scleral fixation. *Retina* 2009;29:91-7.
- Can E, Basaran R, Gul A, Birinci H. Scleral fixation of one piece intraocular lens by injector implantation. *Indian J Ophthalmol* 2014;62:857-60.
- Product brochure of Acryva HAF. Available from: <https://www.vsybiotechnology.com/wp-content/uploads/2020/01/Acryva-Haf.pdf>. [Last accessed on 2020 Oct 03].
- Karadag R, Bayramlar H. Re: Yamane *et al.* Sutureless 27-gauge needle-guided intrascleral intraocular lens implantation with lamellar scleral dissection. *Ophthalmology* 2014;121:e42.
- Kumar DA, Agarwal A, Packiyalakshmi S, Jacob S, Agarwal A. Complications and visual outcomes after glued foldable intraocular lens implantation in eyes with inadequate capsules. *J Cataract Refract Surg* 2013;39:1211-8.
- Jacob S, Agarwal A, Agarwal A, Narasimhan S. Closed-chamber haptic reexternalization for posteriorly displaced sclerotomy and inadequate haptic tuck in glued posterior chamber intraocular lenses. *J Cataract Refract Surg* 2015;41:268-71.
- Baykara M. Suture burial technique in scleral fixation. *J Cataract Refract Surg* 2004;30:957-9.
- Baykara M, Timucin OB. Long-term results of a suture burial technique. *Eur J Ophthalmol* 2008;18:368-70.
- Tanaka H, Fujinami K, Watanabe K, Noda T, Akiyama K. Haptic Breakage after transscleral fixation of a single-piece acrylic intraocular lens. *Case Rep Ophthalmol* 2014;5:212-6.
- Kang HM, Chung EJ. Late-onset *Citrobacter koseri* endophthalmitis with suture exposure after secondary intraocular lens implantation. *Korean J Ophthalmol* 2011;25:285-8.
- Heilskov T, Joondeph BC, Olsen KR, Blankenship GW. Late endophthalmitis after transscleral fixation of a posterior chamber intraocular lens. *Arch Ophthalmol* 1989;107:1427.
- Long C, Wei Y, Yuan Z, Zhang Z, Lin X, Liu B. Modified technique for transscleral fixation of posterior chamber intraocular lenses. *BMC Ophthalmol* 2015;15:127.
- Ma LW, Xuan D, Li XY, Zhang JS. Corneal astigmatism correction with scleral flaps in trans-scleral suture-fixed posterior chamber lens implantation: A preliminary clinical observation. *Int J Ophthalmol* 2011;4:502-7.
- Choi JY, Han YK. In-and-out technique for intraocular lens scleral fixation. *Clin Ophthalmol* 2018;12:1279-84.
- Guillon M, Dumbleton K, Theodoratos P, Gobbe M, Wooley CB, Moody K. The effects of age, refractive status, and luminance on pupil size. *Optom Vis Sci* 2016;93:1093-100.
- Choi SR, Jeon JH, Kang JW, Heo JW. Risk factors for and management of pupillary intraocular lens capture after intraocular lens transscleral fixation. *J Cataract Refract Surg* 2017;43:1557-62.
- Abela-Formanek C, Amon M, Schauersberger J, Kruger A, Nepp J, Schild G. Results of hydrophilic acrylic, hydrophobic acrylic and silicone intraocular lenses in uveitic eyes with cataract: Comparison to a control group. *J Cataract Refract Surg* 2002;28:1141-52.
- Wallmann AC, Monson BK, Adelberg DA. Transscleral fixation of a foldable posterior chamber intraocular lens. *J Cataract Refract Surg* 2015;41:1804-9.
- Singh H, Modabber M, Safran SG, Ahmed II. Laser iridotomy to treat uveitisglaucomahyphema syndrome secondary to reverse pupillary block in sulcusplaced intraocular lenses: Case series. *J Cataract Refract Surg* 2015;41:2215-23.
- Chang DF, Masket S, Miller KM, Braga-Mele R, Little BC, Mamalis N, *et al.* Complications of sulcus placement of single-piece acrylic intraocular lenses: Recommendations for back-up IOL implantation following posterior capsule rupture. *J Cataract Refract Surg* 2009;35:1445-58.
- Pan Q, Yang Z, Chen X, Wei W, Ke Z, Chen D, *et al.* Suturing technique for scleral fixation of toric intraocular lens in the traumatic aphakic eye with corneal astigmatism. *Eur J Ophthalmol* 2019;29:100-5.
- Goel N. Clinical outcomes of combined pars plana vitrectomy and trans-scleral 4-point suture fixation of a foldable intraocular lens. *Eye* 2018;32:1055-61.
- Kaluzny BJ, Laudenska A, Malukiewicz G. Modified scleral suture fixation technique for foldable IOL with fenestrations in the proximal part of the haptics. *Eur J Ophthalmol* 2015;25:254-7.
- Rho S, Song WK, Sung Y, Kwon HJ, Lew H. Scleral fixation technique using a hydrophobic foldable intraocular lens with ring-shaped connecting bridges. *J Cataract Refract Surg* 2015;41:262-7.
- Li B, Zhang Y, Gao X. Simple technique for transscleral fixation of a foldable posterior chamber intraocular lens using a single suture. *J Invest Surg* 2020;33:446-52.
- Jacob S. Intrascleral IOL fixation. *Asia Pac J Ophthalmol* 2017;6:381-7.
- Holladay JT. Evaluating the intraocular lens optic. *Surv Ophthalmol* 1986;30:385-90.
- Lyu J, Zhao P. Simplified ab externo fixation technique to treat late dislocation of scleral-sutured polymethyl methacrylate intraocular lenses. *Eye* 2016;30:668-72.
- Price MO, Price FW, Werner L, Berlie C, Mamalis N. Late dislocation of scleral-sutured posterior chamber intraocular lenses. *J Cataract Refract Surg* 2005;31:1320-6.
- Khan MA, Gupta OP, Smith RG, Ayres BD, Raber IM, Bailey RS, *et al.* Scleral-fixation of intraocular lenses using Gore-Tex suture: Clinical outcomes and safety profile. *Br J Ophthalmol* 2016;100:638-43.
- Kokame GT, Yamamoto I, Mandel H. Scleral fixation of dislocated posterior chamber intraocular lenses: Temporary haptic externalization through a clear corneal incision. *J Cataract Refract Surg* 2004;30:1049-56.
- Kaya M, Donmez O, Ayhan Z, Ozturk T, Kaynak S, Kocak N. The safety and efficacy of modified suture burial technique to prevent complications in transscleral fixated Intraocular lenses. *Glo-Kat* 2019;14:72-7.