



Since January 2020 Elsevier has created a COVID-19 resource centre with free information in English and Mandarin on the novel coronavirus COVID-19. The COVID-19 resource centre is hosted on Elsevier Connect, the company's public news and information website.

Elsevier hereby grants permission to make all its COVID-19-related research that is available on the COVID-19 resource centre - including this research content - immediately available in PubMed Central and other publicly funded repositories, such as the WHO COVID database with rights for unrestricted research re-use and analyses in any form or by any means with acknowledgement of the original source. These permissions are granted for free by Elsevier for as long as the COVID-19 resource centre remains active.

# Highlights of the Management of Adult Histiocytic Disorders: Langerhans Cell Histiocytosis, Erdheim-Chester Disease, Rosai-Dorfman Disease, and Hemophagocytic Lymphohistiocytosis

Hind Abdin Salama,<sup>1,2</sup> Abdul Rahman Jazieh,<sup>1,2</sup> Ayman Yahya Alhejazi,<sup>1,2</sup> Ahmed Absi,<sup>3</sup> Saeed Alshieban,<sup>2,4</sup> Mohsen Alzahrani,<sup>1,2</sup> Ahmed Alaskar,<sup>1,2</sup> Giamal Gmati,<sup>1,2</sup> Moussab Damlaj,<sup>1,2</sup> Khadega A. Abuelgasim,<sup>1,2</sup> Abdulrahman Alghamdi,<sup>2,5</sup> Bader Alahmari,<sup>1,2</sup> Areej Almugairi,<sup>2,4</sup> Hazza Alzahrani,<sup>6</sup> Ali Bazarbachi,<sup>7</sup> M.O.H. Musa,<sup>8</sup> Gaurav Goyal<sup>9</sup>

## Abstract

Histiocytic disorders are an exceptionally rare group of diseases with diverse manifestations and a paucity of approved treatments, thereby leading to various challenges in their diagnosis and management. With the discovery of novel molecular targets and the incorporation of targeted agents in the management of various adult histiocytic disorders, their management has become increasingly complex. In an attempt to improve the understanding of the clinical features and management of common adult histiocytic disorders (Langerhans cell histiocytosis, Erdheim-Chester disease, Rosai-Dorfman disease, and hemophagocytic lymphohistiocytosis), we created this document based on existing literature and expert opinion.

*Clinical Lymphoma, Myeloma & Leukemia*, Vol. 21, No. 1, e66-75 © 2020 Elsevier Inc. All rights reserved.

**Keywords:** BRAF, COVID-19, MEK, Targeted, Treatment

## Introduction

Histiocytic disorders are an exceptionally rare group of diseases characterized by tissue infiltration of histiocytes and dendritic cells. These disorders can involve one or more organs, and owing to their rarity, diagnosis is often delayed or missed. Recommendations for the management of adult histiocytic disease are sparse. In 2018, our

first set of local guidelines were published<sup>1</sup>; however, owing to the discovery of new molecular data and incorporation of targeted therapies, these guidelines need refinement and updating for the different categories of histiocytic diseases. This document will provide highlights for management of the most commonly encountered histiocytic diseases (Langerhans cell histiocytosis,

<sup>1</sup>Department of Oncology, King Abdul-Aziz Medical City, Riyadh, Saudi Arabia

<sup>2</sup>King Saud bin Abdul-Aziz University for Health Science, College of Medicine, Riyadh, Saudi Arabia

<sup>3</sup>Section of Adult Hematology and Hematopoietic Stem Cell Transplant, Princess Nora Oncology Centre, King Abdul-Aziz Medical City, Jeddah, Saudi Arabia

<sup>4</sup>Departments of Pathology and Clinical Laboratory, King Abdul-Aziz Medical City, Riyadh, Saudi Arabia

<sup>5</sup>Department of Clinical Pharmacy, King Abdul-Aziz Medical City, Riyadh, Saudi Arabia

<sup>6</sup>Section of Adult Hematology and Stem Cell Transplant, Department of Oncology, King Faisal Specialist and Research Centre, Riyadh, Saudi Arabia

<sup>7</sup>Bone Marrow Transplantation Program, Department of Internal Medicine American University of Beirut, Medical Center, Beirut, Lebanon

<sup>8</sup>Department of Hematology, Fedail Hospital, Khartoum, Sudan

<sup>9</sup>Division of Hematology-Oncology, University of Alabama at Birmingham, Birmingham, AL

Submitted: Jul 12, 2020; Revised: Aug 7, 2020; Accepted: Aug 10, 2020; Epub: Aug 18, 2020

Addresses for correspondence: Dr Hind Abdin Salama, MD, Department of Hematology-Oncology, King Abdul-Aziz Medical City Hospital, 11421, Riyadh, Saudi Arabia; or Dr. Gaurav Goyal, MD, Division of Hematology-Oncology, University of Alabama at Birmingham, Birmingham, AL, 35294

E-mail contact: [salamahe@ngha.med.sa](mailto:salamahe@ngha.med.sa); [ggoyal@uabmc.edu](mailto:ggoyal@uabmc.edu)

Erdheim-Chester disease, Rosai-Dorfman disease, and hemophagocytic lymphohistiocytosis). This document was mainly developed through literature review and expert opinion.<sup>2</sup>

### **Langerhans Cell Histiocytosis (LCH)**

LCH is a clonal disorder with *MAPK-ERK* mutations present in most patients. *BRAFV600E* is present in more than 50% of cases.<sup>2</sup> LCH is characterized by tissue infiltration with dendritic cells. Presumptive diagnosis of LCH is usually made on radiologic and clinical findings without tissue diagnosis (eg, typical apical lung nodules or cystic lesions on chest computed tomography [CT], or the characteristic lytic lesions seen on bone images [moth-eaten or punched out appearance]) (Figure 1).<sup>2</sup> Definite diagnosis of LCH requires the presence of CD68/163+ histiocytes that are positive for CD1a and/or langerin (CD207) on immunohistochemical (IHC) staining. Electron microscope examination for demonstration of Birbeck granules is not required for diagnosis anymore in the era of IHC. Mutational analysis for *BRAFV600E* or *MAPK-ERK* mutations is required, as this will influence the treatment decision process and can sometimes aid in diagnosis.

LCH can involve single system or organ (SS-LCH) or multiple systems (MS-LCH). LCH with risk-organ (RO-LCH) is identified when there is an infiltration of vital organs (eg, bone marrow, spleen, liver, and central nervous system [CNS]).

The clinical presentation of adult LCH (a-LCH) varies depending on the site of involvement. Bone involvement is common, with the skull being the most commonly involved bony site (60%). Vertebral involvement with or without soft tissue involvement and cranial fossa involvement with intracranial soft tissue extension can occur. Patients usually present with bone pain, fractures, or cord compression. For bones, LCH fluorodeoxyglucose-positron emission tomography-CT (FDG-PET-CT) is the most sensitive functional test used in identification of the lesions and assessment of response to therapy. If FDG-PET-CT is not available, a technetium 99m bone scan should be performed in addition to a skeletal survey.

Thirty percent of adult patients with LCH present with diabetes insipidus (DI) secondary to pituitary fossa involvement, and it can precede LCH diagnosis by several years.

In children, isolated lung involvement is rare, whereas in adults, lung involvement can occur as an isolated disease mainly in smokers. Typical lesions found by a high-resolution CT in the form of nodules, cavitated nodules and cysts coexist mainly in the upper and middle lungs. Pulmonary function tests may show reduced diffusion capacity, exhibiting a restrictive or obstructive pattern.<sup>2</sup> Tissue biopsy is recommended to diagnose atypical lung lesions.

CNS involvement incidence is 5%.<sup>2</sup> Lesions are either in the form of the tumor most commonly involving the hypothalamic-pituitary region or non-tumorous involvement of cerebellum or brain stem.<sup>3</sup> Some can present with neurodegenerative manifestations including cognitive function impairment. Skin involvement occurs in 15% to 30% of patients.<sup>2</sup> Any form of rash could occur and should be documented by histologic examination.

Liver involvement is usually represented by the occurrence of hepatomegaly of greater than 3 cm below the costal margin or abnormal liver function tests. Indicators include gamma-glutamyl transferase that is greater than 2 times the upper limit of normal and/or alanine aminotransferase/aspartate aminotransferase that is greater than 3 times the upper limit of normal, a bilirubin level greater than 3 times

the upper limit of normal, ascites, edema, or an intrahepatic mass. Life-threatening sclerosing cholangitis can occur because of hepatic infiltration. Rarely, LCH may involve the ears, eyes, mucus membranes, gastrointestinal tract, spleen, and bone marrow.

The approach to diagnose and manage LCH is mostly based on general agreement between experts.<sup>2,3</sup> To diagnose LCH, an involved tissue should be examined for specific (IHC) and (*BRAFV600E*) mutation testing.<sup>4</sup> For patients with MS-LCH who are *BRAF-V600E* negative; consider next generation sequencing for *MAPK/ERK* pathway mutations. FDG-PET-CT is the gold standard image for pretreatment evaluation and follow-up. High-resolution chest CT should be performed if pulmonary LCH is suspected, followed by bronchoalveolar lavage (BAL) if a lesion is identified. The presence of greater than 5% CD1a-positive cells in the fluid is diagnostic in nonsmokers (CD1a), as the stain can be positive in the BAL of smokers without lung disease; lung biopsy is needed if BAL is not conclusive.<sup>5,6</sup>

If DI is suspected, a pituitary magnetic resonance imaging (MRI) should be performed. A spinal MRI should be performed in all patients with vertebral bone involvement to exclude cord compression.

### **Treatment of LCH**

LCH with isolated bone disease can regress spontaneously. Indications to treat LCH are: the presence of MS-LCH, multifocal bone lesion, single lesion in CNS, single lesion with RO or the risk of CNS involvement (eg, craniofacial lesions, ears or eye involvement that is not amenable to local therapy), and isolated pulmonary LCH that is not responsive to smoking cessation.

### **Treatment of SS-LCH**

Single system-unifocal bone disease will need treatment if the lesion is in a weight-bearing area, if it causes disfigurement, if there is a risk of spinal cord compression, if the bone lesions are at areas with CNS risk (eg, skull or if the lesion affects functionality).

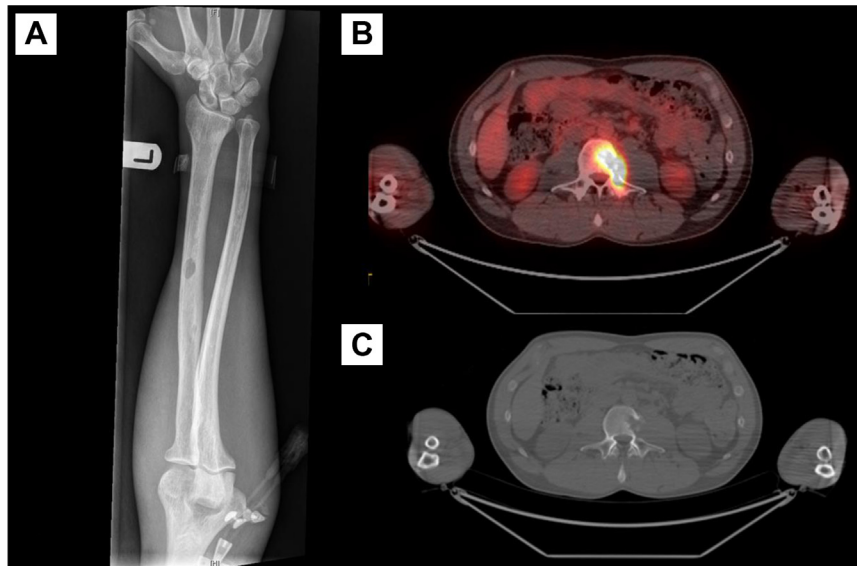
The type of treatment of SS-unifocal bone lesion depends mainly on the lesion size and location. For lesions < 5 cm, curettage would be sufficient for diagnosis and treatment. Radical excision should be avoided as it might cause permanent disfigurement. Intraregional injection of steroid may allow rapid healing, and the dose varies between 40 and 160 mg of methyl prednisolone. Radiation may be considered for single lesions that have recurred after surgery or cannot be surgically excised. Systemic therapy is indicated for lesions > 5 cm or lesions at risk of transferring to the CNS or lesions in critical sites where local therapies are not feasible or risky.

Multifocal bone disease is treated as MS-LCH (Figure 2). SS-LCH other than bone is treated according to the location. For the skin, usually topical nitrogen mustard ointment 20% can be sufficient to control the disease. If not successful or the involved areas are extensive, other options would include: corticosteroid with or without vinblastine, low doses of oral methotrexate 20 mg weekly alone or in combination with prednisolone and azathioprine, single-agent azathioprine at the dose of 2 mg/kg orally (PO) daily, thalidomide at a dose of 100 mg PO daily (especially if multifocal skin lesion or mucous membrane involvement).

Isolated lung LCH is rare, mainly occurring in smokers, and can lead to recurrent pneumothorax or cardiorespiratory arrest. In most

## Clinical Features and Management of Histiocytic Disorders

**Figure 1** Osseous Manifestations of Langerhans Cell Histiocytosis. A, X-ray Showing a Small Well-defined Oval Shape Lytic Lesion in the Mid Diaphysis of the Left Radius; B, Fluorodeoxyglucose Positron Emission Tomography-Computed Tomography (CT); and C, Computed Tomography Scan of a Patient Demonstrating a Lytic “Punched Out” L3 Vertebral Lesion That is Fluorodeoxyglucose-avid



cases, smoking cessation is sufficient to cause disease regression.<sup>6</sup> If not, options would include single-agent cladribine or vinblastine and steroids. However, the latter did not show efficacy in adults with pulmonary LCH.<sup>5</sup> Severe cases of pulmonary LCH might need lung transplantation.

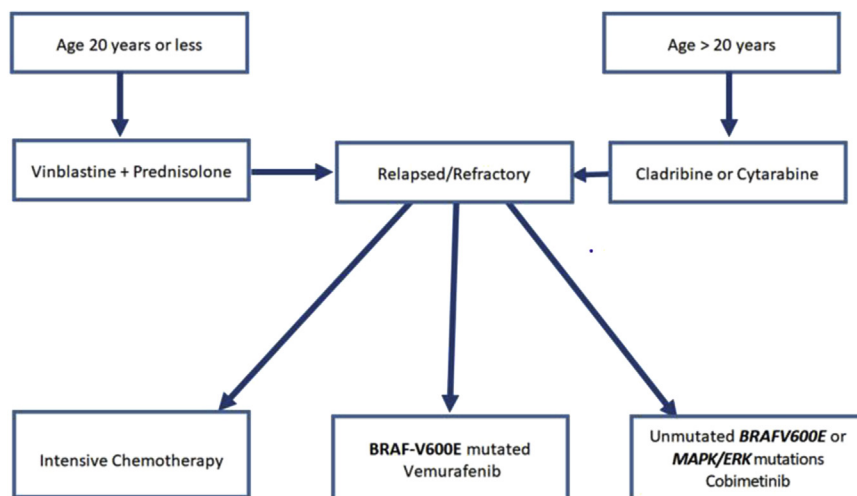
Isolated pituitary involvement does not require therapy unless there is progressive structural disease on imaging. However, desmopressin should be used for symptomatic patients. Neurodegenerative disease and cognitive impairment are not rare in adults. There is currently no

optimal treatment available for neurodegenerative LCH. Some pediatric studies suggest benefit with early initiation of targeted therapies such as *BRAF* and *MEK* inhibitors.<sup>7</sup> Therefore, these agents may be considered over conventional agents.

### *Treatment of Multisystem-LCH (MS-LCH)*

There is no standard front-line regimen for adults as there is for pediatrics. In children, the standard protocol is 1 or 2 cycles of vinblastine and steroids followed by maintenance.<sup>4</sup> This approach is

**Figure 2** Treatment of Multi-system Langerhans Histiocytosis



**Table 1 Methotrexate With Leucovorin Rescue, Doxorubicin, Cyclophosphamide, Vincristine, Prednisone, and Bleomycin (MACOP-B)**

Chemotherapy	Doses
Methotrexate	400 mg/m <sup>2</sup> IV D8, D36, D64 followed by leucovorin rescue
Doxorubicin	50 mg/m <sup>2</sup> IV 50 mg/m <sup>2</sup> D1, D15, D29, D43, D57, D71
Cyclophosphamide	350 mg/m <sup>2</sup> IV D1, D15, D29, D43, D57, and D71
Vincristine	1.4 mg/m <sup>2</sup> D8, D22, D36, D50, D64 (maximum dose 2 mg)
Prednisolone	40 mg/m <sup>2</sup> D1-D84 (start taper off from day 70)
Bleomycin	10 mg/m <sup>2</sup> D22, D50, D78

Abbreviations: D = Day; IV = intravenous

recommended for adults with MS-LCH or SS-LCH with RO up to the age of 20 years (Figure 2). For older adults, it was found to be less effective and more toxic. Therefore, single-agent chemotherapy or a targeted agent is preferred.

Cytarabine at a dose of 100 mg/m<sup>2</sup> IV for 5 days every 28 days is a preferred option for symptomatic MS-LCH with no RO, and for patients with CNS involvement. If the patient is in complete or partial remission (CR or PR) after the first cycle, it is advisable to continue maintenance cytarabine 100 mg/m<sup>2</sup> for 6 to 12 months.

Another effective single agent is cladribine, as it is a preferred option for MS-LCH with RO. Cladribine is usually given at dose of 6 mg/m<sup>2</sup> or 0.14 mg/kg IV for 5 days every 28 days. If the patient is in CR or PR after 2 cycles, it is recommended to continue for no more than 4 cycles due to risk of prolonged lymphopenia. Recently, a report was published highlighting the use of single-agent cladribine for 37 patients with LCH, and showed that single-agent cladribine has high overall response rate, and most of the patients achieved PR regardless of the mutation of *BRAFV600E*.<sup>8</sup>

Etoposide as a single agent can be used at dose of 100 mg/m<sup>2</sup> for 5 days every 28 days, up to 6 cycles.

Combination chemotherapy, for instance the MACOP-B (methotrexate, doxorubicin, cyclophosphamide, vincristine, prednisone, and bleomycin) regimen (Table 1), was found to be effective and resulted in a long-lasting response without a need for maintenance after the induction course was completed; however, it is not a preferred regimen given good efficacy and less toxicity of single agent chemotherapy agents listed above.<sup>9</sup>

For MS-LCH with mild symptoms and no RO-LCH, either methotrexate 20 mg PO weekly or azathioprine 2 mg/kg PO daily can be given.

**Treatment of Relapsed or Refractory LCH**

For refractory or relapsed LCH, the general concept is to use different agents rather than repeating initial therapy. Any of the conventional agents can be used (cladribine, cytarabine, or vinblastine + prednisolone).

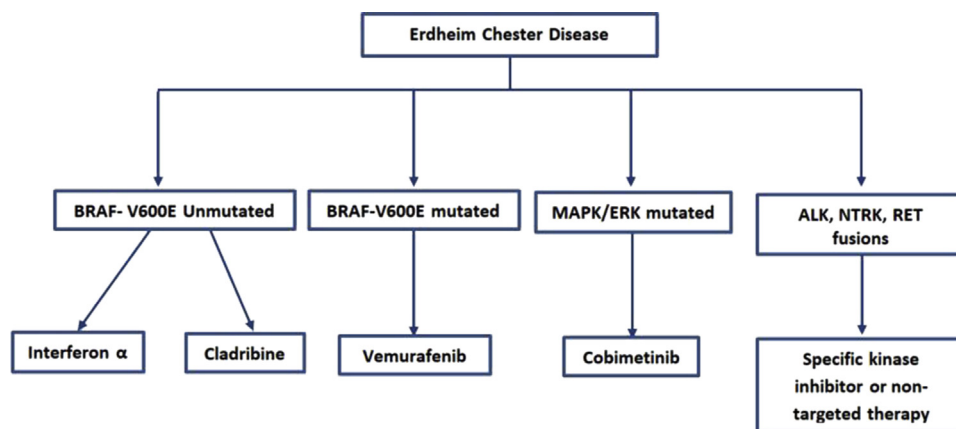
Vemurafenib may be considered in relapsed or refractory cases with *BRAF V600E* mutations.<sup>10</sup> MEK inhibitor (cobimetinib) can be considered in severe illness, critical organ involvement, or refractory non-*BRAF-V600E*-mutated LCH. A phase II trial using cobimetinib in 18 patients with histiocytosis regardless of their genotype showed an overall response rate of 89%.<sup>11</sup>

Cytarabine and cladribine combination is a toxic regimen and is associated with increased risk of infection. Therefore, it should be reserved for severe cases or refractory RO-LCH.

**Role of Hematopoietic Stem Cell Transplant (HSCT)**

Autologous or allogeneic stem cell transplant may be considered for relapse refractory transplant-eligible patients. In children, the preferred conditioning chemotherapy regimen remains unclear, and can involve either myeloablative conditioning or reduced intensity conditioning (RIC). For adults, RIC is the preferred salvage option owing to the lower posttransplant-associated morbidity and mortality; however, the relapse rate is higher after RIC. The role of HSCT in the era of targeted therapies is unclear and may even become obsolete in adults, as these therapies are uniformly effective.

**Figure 3 Treatment of Erdheim Chester Disease**



# Clinical Features and Management of Histiocytic Disorders

**Table 2** HLH-2004 Diagnostic Criteria

Presence of Either:
1. Molecular diagnosis consistent with HLH: mutations of <i>PRF1</i> , <i>UNC13D</i> , <i>Munc18-2</i> , <i>Rab27a</i> , <i>STX11</i> , <i>SH2D1A</i> , or <i>BIRC4</i>
2. Five or more of the 8 criteria listed below:
• Fever $\geq 38.5^\circ\text{C}$
• Splenomegaly
• Cytopenia (affecting at least 2 of 3 lineages in the peripheral blood):
Hemoglobin $< 9$ g/dL
Platelets $< 100 \times 10^3/\text{mL}$
Neutrophils $< 1 \times 10^3/\text{mL}$
• Hypertriglyceridemia (fasting $\geq 265$ mg/dL or $\geq 3$ mmol/L) and/or hypofibrinogenemia ( $< 1.5$ g/dL)
• Hemophagocytosis in bone marrow, spleen, lymph nodes, or liver
• Low or absent natural killer-cell activity
• Ferritin $\geq 500$ ng/mL
• Elevated sCD25 (ie, soluble IL-2 receptor $\geq 2400$ U/mL)

Abbreviations: HLH = Hemophagocytic lymphohistiocytosis; IL-2 = interleukin-2

## Erdheim-Chester Disease (ECD)

ECD is a clonal disorder marked by recurrent *BRAFV600E* mutations in more than 50% of patients. Other mutations involving *MAPK-ERK* or *PI3K-AKT* pathway can be frequently detected in remaining patients.<sup>12</sup> The characteristic histopathologic findings of ECD include tissue infiltration with foamy histiocytes that are positive for CD68/CD163 and negative for CD1a and langerin (CD207).

## Clinical Presentation

ECD can involve any organ system; however, it is seen especially in bones, CNS, and the cardiovascular system. The finding of symmetric osteosclerosis of the meta-diaphysis of long bones in the legs (around knees) is present in almost 90% of patients with ECD with or without bone pain.<sup>2</sup>

Cardiovascular manifestations affect more than 50% of patients with ECD.<sup>2</sup> The most common abnormality is circumferential soft-tissue sheathing of the thoracic and abdominal aorta seen on a CT scan as a “coated aorta.” Other manifestations include pseudo-tumor infiltration of the right atrium visualized clearly on MRI as a mass lesion. Furthermore, hypertension, coronary artery disease, and pericardial disease can also occur. However, valvular lesions and conduction defects are rare.

Lung involvement is usually asymptomatic or can present with a cough, dyspnea, lung infiltrates, and an observation of restrictive patterning on spirometry. Fluid from BAL might show lipid-laden macrophages.

The CNS is involved in 40-50% of the patients,<sup>2</sup> mainly in the form of cerebellar and pontine involvement, thereby causing progressive cerebellar symptoms. Unilateral or bilateral peri-orbital involvement resulting in exophthalmos, eye pain, or blindness can also occur.

Sixty percent of patients with ECD present with abdominal and pelvic involvement including infiltration of perinephric tissues, leading to the characteristic “hairy kidney.” Hydronephrosis, retroperitoneal fibrosis, and mass-like soft-tissue infiltration can occur.

**Table 3** H-Score

Diagnostic Criteria	Scoring
Known underlying immunosuppression	No 0
HIV-positive or receiving long-term immunosuppressive therapy (ie, glucocorticoids, cycloSPORINE, azathioprine)	Yes +18
Organomegaly	No 0
	Hepato or splenomegaly +23
	Hepatomegaly and splenomegaly +38
Number of cytopenias (defined as hemoglobin $\leq 9.2$ g/dL ( $\leq 5.71$ mmol/L) and/or WBC $\leq 5000/\text{mm}^3$ and/or platelets $\leq 110,000/\text{mm}^3$ )	1 lineage 0
	2 lineage +24
	3 lineage +34
Ferritin, ng/mL	$< 2000$ 0
	2000-6000 +35
	6000 + 50
Triglyceride, mmol/L	$< 1.5$ 0
	1.5-4 +44
	$> 4$ +64
Fibrinogen, g/L	$> 2.5$ 0
	$2 \leq .5$ +30
AST, U/L	$< 30$ 0
	$\geq 30$ +19
Hemophagocytosis features on bone marrow aspirate	No 0
	Yes +35
Temperature, $^\circ\text{C}$	$< 38.4$ 0
	38.4-39.4 +33
	$> 39.4$ +49

Abbreviations: AST = Aspartate aminotransferase; HLH = hemophagocytic lymphohistiocytosis; WBC = white blood cell  
 HScores greater than 169 are 93% sensitive and 86% specific for HLH. Note that bone marrow hemophagocytosis is not a requisite for a diagnosis of HLH. HScores can be calculated using an online HScore calculator (<http://saintantoine.aphp.fr/score/>).

Skin manifestations such as peri-orbital xanthelasmas and xanthomas may present. Additionally, endocrine manifestations can present in  $>50\%$  of ECD cases, including DI, erectile dysfunction, and gonadotrophin insufficiency.

## Treatment of ECD

**Pretreatment Evaluation.** History should include symptoms of bone pain, abnormal gait, weakness, decreased vision, polyuria, and polydipsia. Constitutional symptoms in the form of fever, weight loss, fatigability, and sweating were found in 28% of patients with ECD.<sup>13</sup> We reported a case of ECD with a 50-kg weight loss and no skeletal bone involvement.<sup>14</sup>

Complete physical examination looking for skin lesions, soft-tissue swelling, xanthelasmas, and funduscopy, in addition to cardiovascular, chest, cognitive, and neurologic examinations should be undertaken. Pretreatment workup should include full peripheral blood counts, liver function, renal function, sodium level, C-reactive protein, serum and urine osmolality, and gonadotropin levels. In addition to the IHC and morphology examination of the involved tissue, mutation analysis and next-generation sequencing



**Table 4** HLH-94 Protocol

Regimen	
Initiation Phase	Continuation Phase
8 Weeks	1 Year
Etoposide	Dexamethasone
IV 150 mg/m <sup>2</sup> twice weekly during the first 2 weeks, then weekly × 6 weeks	PO 10 mg/m <sup>2</sup> × 3 days every 2 weeks
Dexamethasone	Etoposide
PO 10 mg/m <sup>2</sup> for 2 weeks followed by 5 mg/m <sup>2</sup> for 2 weeks, 2.5 mg/m <sup>2</sup> for 2 weeks, 1.25 mg/m <sup>2</sup> for 1 week and 1 week of tapering	150 mg/m <sup>2</sup> IV every 2 weeks
Intrathecal methotrexate	Cyclosporine
12 mg weekly × 4 weeks start on the 3rd week, for patients with progressive neurologic symptoms and/or persisting abnormal cerebrospinal fluid findings	6 mg/m <sup>2</sup> daily orally in 2 divided doses keep level at 200 mcg/L

Abbreviations: HLH = Hemophagocytic lymphohistiocytosis; IV = intravenous; PO = orally. In older adults, consider modifications of etoposide to weekly instead of twice per week and use doses from 50-100 mg/m<sup>2</sup>.

(NGS) for *BRAF V600E* and *MAPK-ERK* pathway should be conducted. Full body (vertex to toes) FDG-PET-CT scans are recommended for every patient at baseline. Cardiac MRI and MRI brain are also recommended at diagnosis as they are sensitive for diagnosing asymptomatic ECD involvement of the respective organs.

In general, therapy is initiated for all patients diagnosed with ECD except asymptomatic patients with only bone disease or those who present only with DI.<sup>14</sup> Treatment options (Figure 3) include interferon alpha at a dose of 3 to 9 million IU via IV 3 times per week or pegylated interferon alpha at a dose of 135 mcg/week subcutaneously. Higher doses at 180 mcg/week may be needed for suboptimal responses or cardiac/CNS involvement. Interferon therapy should be continued until disease progression, lack of response, or intolerance owing to side effects. Common side effects include fever, flu-like symptoms, myalgia, arthralgia, neuropsychiatric manifestations, transaminitis, and pruritus.

Vemurafenib (BRAF kinase inhibitor)<sup>10,15</sup> is indicated as a first-line therapy for patients with mutated *BRAF V600E* ECD or as a second-line therapy for those who are refractory to the conventional first-line therapy. The recommended dose is 480 mg PO twice per day, until disease progression or intolerance. Dose reductions may be required based on toxicities and/or side effects. Common toxicities include fatigue, arthralgia, headaches, multiple skin lesions, QTc prolongation, peripheral edema, and diarrhea. Prolonged exposure to vemurafenib can cause squamous cell carcinoma so dermatologic examination is essential. Dabrafenib, another BRAF-inhibitor could be used instead of vemurafenib as well and may be better tolerated.

MEK-inhibitors such as cobimetinib or trametinib should be considered for relapsed refractory cases with MAPK/ERK mutations, or newly diagnosed with multisystem involvement, or involvement of a vital organ. Cobimetinib is used at dose of 20 to 60 mg daily for 21 days as part of a 28-day cycle.<sup>13</sup> Patients on MEK inhibitors can suffer from cardiac and retinal toxicities, therefore echocardiogram and retinal exam are recommended. Some cases may have rare *ALK*,

*NTRK*, *RET* fusions or *CSF1R* mutations, and specific kinase inhibitors may be considered for those situations as available.

Single-agent cladribine may be considered for *BRAF V600E*-negative cases or those that are unresponsive or intolerant to interferon therapy, at a dose of 0.14 mg/kg or 6 mg/m<sup>2</sup> via IV infusion for 2 hours daily for days 1 to 5 days on a 28-day cycle. If the patient is responding after 2 cycles, up to 2 additional cycles may be administered. All patients should be given pneumocystis and anti-viral prophylaxis while on therapy and for several months beyond completion.

**Assessment of Treatment Response.** FDG PET-CT should be performed every 3 months for all patients following the initiation of treatment; afterwards, the interval between scans can be increased once the disease has stabilized. Organ-specific imaging should be performed after 3 months of initial therapy and then every 6 months. Once disease stabilization is achieved, scans should be repeated only as indicated by changes in clinical status or laboratory values.

### Rosai-Dorfman Disease (RDD)

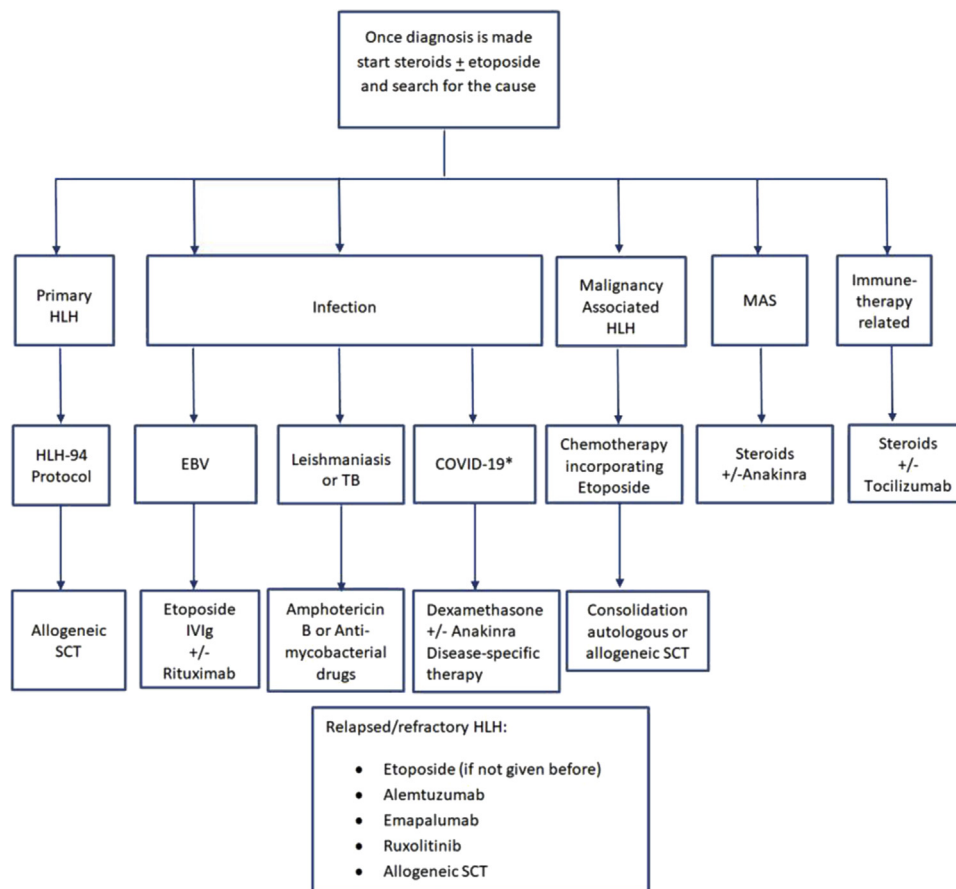
RDD is a rare type of non-Langerhans cell histiocytosis. Histologic examination typically showed peri-capsular fibrosis and dilated sinuses heavily infiltrated with large histiocytes, lymphocytes, and plasma cells. The engulfment of lymphocytes and plasma cells by histiocytes that express S-100 is considered diagnostic of RDD. IHC stains of RDD cells are also positive for CD68 and CD163, whereas CD1a is typically negative. Recent studies have raised the possibility of a clonal origin owing to the presence of *KRAS*, *NRAS*, and *MAP2K1* genes.<sup>16</sup> Unlike LCH and ECD, the *BRAFV600E* mutation is typically absent. Gene sequencing is recommended, especially in refractory cases.

RDD usually presents as painless and massive lymphadenopathy that is mainly cervical, accompanied by a fever, night sweats, and weight loss. Isolated extra nodal involvement is present in over half of cases mainly involving the skin, soft tissues, upper respiratory tract, retro-orbital tissue, and bones.<sup>17</sup> CNS and ophthalmic manifestations is present in 10% of cases.<sup>2</sup> Normochromic normocytic anemia is not uncommon. Additionally, there are reported cases of RDD presenting with autoimmune hemolytic anemia.<sup>18,19</sup>

### Treatment of RDD

Asymptomatic patients can be observed and followed closely. Patients with constitutional symptoms or sudden enlargement of lymph nodes require treatment. Treatment options include a prolonged course of low-dose prednisone (1 mg/kg of prednisone equivalent for 2-3 weeks followed by gradual taper over 2 months) or high-dose steroids for patient with compression to vital organs or systemic disease. Sirolimus at a dose of 2.5 mg/m<sup>2</sup> for 18 months is has been used by some clinicians.<sup>20</sup> Rituximab 375 mg/m<sup>2</sup> once a week × 4 doses is recommended for those with immune-related RDD. Low-dose methotrexate combined with 6-mercaptopurine or single-agent cladribine are recommended for patients with severe RDD. Lenalidomide or thalidomide have been tried with success for refractory cutaneous RDD.<sup>16</sup>

**Figure 4** Treatment of Adult HLH. \*Evidence Supporting the True Occurrence of HLH With COVID-19 Is Sparse and Is Evolving. We Recommend Following the Latest Evidence While Managing COVID-19 Related Hyperinflammation Syndromes



Abbreviations: COVID-19 = Coronavirus-19 disease; EBV = Epstein-Barr virus; HLH = hemophagocytic lymphohistiocytosis; IVIg = intravenous immunoglobulin; MAS = macrophage activation syndrome; SCT = stem cell transplantation; TB = tuberculosis.

Clofarabine was used on 3 patients with relapsed refractory RDD; 2 patients achieved CR and 1 achieved PR.<sup>16</sup> Cobimetinib is recommended for refractory RDD with mutations involving MAPK-ERK pathway.<sup>16</sup>

### Hemophagocytic Lymphohistiocytosis (HLH)

HLH is a hyperinflammatory immune response syndrome driven by T-cells. It could be either primary or secondary to a trigger. Secondary HLH accounts for the majority of adult HLH (a-HLH). Secondary HLH is mainly owing to inability of the hosts' immune system to restrict the stimulatory effects of different triggers.

HLH was previously understood as a pediatric disease, with most of the HLH guidelines being based on the HLH-94 and HLH-2004 pediatric trials. However, over the past 10 years, a-HLH has been diagnosed more frequently. As a result, recent HLH publications have explored a-HLH in greater detail.

### Diagnosis of HLH

HLH is frequently misdiagnosed as acute sepsis. The accurate and timely diagnosis is crucial owing to the high mortality rate. HLH-2004 diagnostic criteria (Table 2) was developed for children, and it is not validated in adults; however, it is still widely used to diagnose a-HLH.

Serum ferritin greater than 10,000 ng/mL was found to be 96% specific and 90% sensitive for diagnosis in children<sup>21,22</sup>; however, this is not the case in adults. Soluble CD25 (sCD25 or interleukin-2) activity is a more sensitive tool to suggest a-HLH rather than serum ferritin. A high transaminase is a common presentation in a-HLH, but is not part of the HLH2004 diagnostic criteria. Therefore, there is a need for better tools for diagnosis of HLH in adults.

The H-Score (Table 3) is an online scoring calculator that incorporates clinical and laboratory data, with the cumulative score



ranged between 0 and 300.<sup>23</sup> In a multicenter trial, the performance of HLH-2004 diagnostic criteria was compared with the H-Score in 147 children and adults with suspected HLH. The authors concluded that the H-score is more efficient in diagnosing HLH for both children and adults.<sup>24</sup> If the biochemical and clinical markers are suggestive of a-HLH, a bone marrow or tissue biopsy should be performed to look for evidence of hemophagocytosis. However, morphologic evidence of hemophagocytosis in bone marrow may not always be captured on a biopsy and is not a mandatory criteria for making a diagnosis of HLH. HLH should be considered in the differential diagnosis of patients with otherwise unexplained fevers, bicytopenia, and elevated ferritin levels, especially in combination with elevated sCD25 receptor assay.

Mutation analysis for the genes involved in familial HLH (*PRF1*, *UNC13D*, *Munc18-2*, *Rab27A*, *STX11*, *SH2D1A*, *BIRCC4*) should be sent in young patients, especially in cases with EBV-driven HLH. Other tests to look for the trigger such as Epstein-Barr virus (EBV) polymerase chain reaction, cytomegalovirus polymerase chain reaction, HIV1/2 antigen assay and blood and urine culture, and autoimmune screen should be undertaken, in addition to an FDG PET-CT looking for an underlying lymphoma or other neoplasm. Brain MRI and cerebrospinal fluid examination should be performed for those with neurologic symptoms.

### **Treatment of adult HLH**

Owing to the high mortality of HLH and delays in specialized test results like sCD25 assay, treatment with dexamethasone or another corticosteroid should be initiated at initial suspicion. The management approach of a-HLH follows 2 strategies: suppressing the cytokine storm and treating the underlying trigger. The HLH-94 (Table 4) is widely used for HLH in children. Owing to the heterogeneity of a-HLH, a one size protocol does not fit all. Offering HLH-94 protocol to primary or refractory HLH is a recommendation of this document. This protocol consists of extensive cytotoxic medications given in 2 phases for a total duration of 1 year.<sup>25</sup> For adults, this can be abbreviated based on response to therapy and treatment of underlying trigger.

Adult tolerability to etoposide is less than in children; therefore, the etoposide dose can be modified to 50 to 100 mg/m<sup>2</sup>, in addition to administering it on a weekly schedule when compared with the twice per week protocol seen in children. Once HLH is suspected, IV immunoglobulin 1 to 2 gm/kg for 1 to 2 days with or without steroids may be given, as this will temporarily control the cytokine storm until the specific cause is identified (Figure 4).

### **Malignancy-associated HLH (Mal-HLH)**

Mal-HLH is the most aggressive subtype and carries a high mortality rate. It accounts for 40% to 70% of a-HLH.<sup>26</sup> Fifty percent of secondary HLH in adults is a result of hematologic malignancies. Lymphoma is the most common cause, especially NK-cell and peripheral T-cell lymphoma (35%), followed by B-cell lymphomas (32%), leukemias 6%, Hodgkin lymphoma (6%), and solid malignancies (3%).<sup>27</sup> Diagnosis of underlying malignancy can be challenging and repeated biopsies may be needed to confirm a diagnosis. There is some evidence to suggest that a high sCD25/

ferritin ratio may point toward a lymphoma as an underlying cause for HLH rather than other secondary causes.<sup>27</sup>

Treatment initiation with corticosteroid therapy is crucial. Whenever possible, tissue biopsy should be obtained prior to the initiation of steroids. In severe HLH with risk of organ damage, etoposide 50 to 100 mg/m<sup>2</sup> can be added to control the HLH before the start of specific chemotherapy. It is reasonable to add etoposide to lymphoma treatment using CHOP (cyclophosphamide, doxorubicin, vincristine, and prednisone) if the patient is fit enough to tolerate the additional drug. For a-HLH secondary to T-cell lymphoma, it is usually recommended to offer autologous or allogeneic-HSCT as consolidation post-chemotherapy.

### **Primary HLH**

Familial HLH is extremely rare in adults. Familial HLH should be considered in young males with a family history of HLH, who are EBV-positive, or young patients with CNS disease or albinism. The *PRF1* gene mutation has been detected in 10% of healthy Caucasians.<sup>28</sup> For familial HLH and HLH with an unknown trigger, we recommend using the HLH-94 protocol.

Allogeneic stem cell transplantation should be considered for familial and relapsed/refractory HLH. In children, RIC is the preferred conditioning regimen, showing 3 years OS with myeloablative versus RIC at 43% and 92%, respectively. In adults, RIC did not show superiority based on a retrospective European society for Blood and Marrow Transplantation study.<sup>29</sup> The underlying trigger, the patient's comorbidity index, and age should guide the decision on which conditioning chemotherapy is appropriate.

### **HLH Secondary to Infection**

HLH secondary to infection is usually associated with intracellular organisms that trigger the immune response, such as tuberculosis, malaria, leishmaniasis, and rickettsia.<sup>30</sup> HLH secondary to EBV can occur at any age, and it may be associated with X-linked immunodeficiency disorder, which is characterized by T-cell deficiency, and a genetic predisposition to EBV infection; additionally, some patients may present with HLH during adulthood. Other infectious triggers for HLH include HIV, cytomegalovirus, herpes simplex virus, fungi, and influenza virus. The treatment usually incorporates IV immunoglobulin and specific antimicrobials with or without corticosteroids. Etoposide is reserved for severe cases where no response has been achieved with other treatment options. For EBV-HLH, rituximab can be added; however, etoposide may be needed as T-cells are often infected by the virus leading to hyperinflammation.

### **Macrophage Activation Syndrome (MAS)**

HLH secondary to autoimmune disease (MAS) is reported more frequently in children and can be misdiagnosed in adults. It has been reported in 10% to 15% of adult-onset juvenile rheumatoid arthritis and in 0.9% to 9% of systemic lupus erythematosus.<sup>31</sup> An adult rheumatologist should be involved in the diagnosis and management of MAS.

Management options included combinations of immunosuppressants with corticosteroids as a backbone. Recent evidence showed excellent response of anakinra, an IL1 inhibitor in MAS associated with adult juvenile rheumatoid arthritis.<sup>32</sup>

# Clinical Features and Management of Histiocytic Disorders

## **Immunotherapy-induced HLH**

Immunotherapeutic agents that target CD19, such as chimeric antigen receptor (CAR), bispecific antibodies (blinatumomab), and programmed cell death protein 1 check point inhibitors can induce HLH as a part of cytokine release syndrome (CRS).<sup>21</sup> The anti-interleukin (IL)-6 antibody, tocilizumab, is often used to control drug-induced cytokine storm. Etoposide may be considered in cases that do not respond appropriately to tocilizumab.

## **Post-transplant HLH**

HLH is reported post organ transplant and post-allogeneic stem cell transplant; in the later it might be misdiagnosed as sepsis or graft-versus-host disease. Clinical awareness and post-transplant serum ferritin assessment might help in early diagnosis.

## **Pregnancy**

There are reported cases of idiopathic or secondary HLH during pregnancy, in which early steroid initiation resulted in improved outcomes.<sup>33,34</sup>

## **COVID-19–induced CRS and HLH**

The COVID-19 pandemic has resulted in approximately 900,000 deaths, according to the most recent data. A CRS that resembles HLH with release of IL-6, IL-1, and other inflammatory markers has been associated with severe COVID-19 cases.<sup>35,36</sup>

A recent multicenter study from Wuhan, China, on 150 patients with COVID-19 revealed that high serum ferritin and high IL-6 predicted for worse mortality, suggesting that COVID-19 mortality might be related to CRS/HLH like disease.<sup>35</sup> A few authors suggested the possibility of applying the H-Score for all patients with severe COVID-19 in an attempt to classify those who could benefit from immunosuppression.<sup>37,36</sup> Furthermore, a case series found that the use of anakinra in patients with COVID-19 with positive H-scores resulted in an improved respiratory function.<sup>38</sup> Tocilizumab has been used with success in China for patients with COVID-19–induced pneumonia and high IL-6.<sup>36,39</sup> Therefore, there are several overlaps between s-HLH and the CRS associated with COVID-19 infection. Moreover, the RECOVERY trial has shown that, dexamethasone administration to patients with COVID-19 who required respiratory support resulted in reduction of mortality.<sup>40</sup> These data suggest that patients with COVID-19 who develop CRS and HLH like illness may benefit from dexamethasone in conjunction with anti-cytokine therapy. There are ongoing trials with etoposide and dexamethasone for severe CRS related to COVID-19.<sup>41</sup>

## **Treatment Options of Relapsed/Refractory HLH**

Relapsed/refractory HLH has a dismal outcome. If the HLH-94 protocol is not used initially, it can be used followed by allogeneic HSCT as a primary option. Alemtuzumab (antiCD52 antibody) has been used in 22 pediatric patients with refractory HLH at median dose of 1 mg/kg divided over a duration of 2 to 10 days; 77% of the patients survived to undergo allogeneic HSCT.<sup>42</sup>

Other options would include Janus kinase inhibitors (ruxolitinib).<sup>21</sup> Plasmapheresis can be used in critically ill patients. Anti-

interferon-gamma monoclonal antibody emapalumab has been recently approved for refractory primary HLH in children and adults, and there are ongoing trials in secondary HLH.<sup>21,43</sup>

In addition to HLH-directed therapy, supportive therapy is warranted. Patients usually present with cytopenias and disseminated intravascular coagulopathy, as well as defective T cell immunity that increases their risk for a fatal infection. Correction of any cytopenia and coagulopathy is imperative to safe management. Furthermore, repeated blood transfusions as well as prompt infection management protocols are mandatory. Antivirals are recommended for prophylaxis for all patients; fungal and pneumocystis prophylaxis is given to patients on the HLH-94 protocol, as well as those with prolonged neutropenia or long-term steroid use.

Granulocyte colony-stimulating factor and granulocyte-macrophage colony-stimulating factor have been reported to cause capillary leak syndrome, and experts advise to avoid their use in active HLH; however, risk versus benefit ratio should be assessed carefully. For patients with Mal-HLH on an intensive chemotherapy protocol, it can be utilized to support patients throughout the treatment process.

## **Acknowledgment**

The authors would like to thank Dr Ronald Go, Division of Hematology, Mayo Clinic, for his input in formulation of these guidelines.

## **Disclosure**

The authors have stated that they have no conflicts of interest.

## **References**

1. Salama HA, Alhejazi AY, Absi A, et al. Guide lines for management of adult histiocytic disease. *J Appl Hematol* 2018; 9:111-9.
2. Goyal G, Young JR, Koster MJ, et al. The Mayo Clinic Histiocytosis Working Group Consensus Statement for the Diagnosis and Evaluation of Adult Patients With Histiocytic Neoplasms: Erdheim-Chester Disease, Langerhans Cell Histiocytosis, and Rosai-Dorfman Disease. *Mayo Clinic Proc* 2019; 94:P2054-71.
3. Euro Histo Net Work Group for LCH Guidelines for Adults. EHN: Langerhans Cell Histiocytosis (LCH) - Adults [Internet]. Available at: [https://www.eurohistio.net/e1623/e1554/e3219/index\\_eng.html](https://www.eurohistio.net/e1623/e1554/e3219/index_eng.html). Accessed: March 15, 2020.
4. Girschikofsky M, Arico M, Castillo D, et al. Management of adult patients with Langerhans cell histiocytosis: recommendations from an expert panel on behalf of Euro-Histio-Net. *Orphanet J Rare Dis* 2013; 8:72.
5. Haupt R, Minkov M, Astigarraga I, et al. Euro Histo Network. Langerhans cell histiocytosis (LCH): guidelines for diagnosis, clinical work-up, and treatment for patients till the age of 18 years. *Pediatr Blood Cancer* 2013; 60:175-84.
6. Juvet SC, Hwang D, Downey GP. (2010). Rare lung diseases III: pulmonary Langerhans' cell histiocytosis. *Can Respir J* 2010; 17:e55-62.
7. McClain KL, Picarsic J, Chakraborty R, et al. (2018). CNS Langerhans cell histiocytosis: Common hematopoietic origin for LCH-associated neurodegeneration and mass lesions. *Cancer* 2018; 124:2607-20.
8. Goyal G, Hu M, Abeykoon JP, et al. *Single-agent cladribine as an effective therapy for adults with Langerhans cell histiocytosis*. Washington, DC: American Society of Hematology; 2019.
9. Derenzini E, Fina MP, Stefoni V, et al. MACOP-B regimen in the treatment of adult Langerhans cell histiocytosis: experience on seven patients. *Ann Oncol* 2009; 21:1173-8.
10. Diamond EL, Subbiah V, Craig Lockhart A, et al. Vemurafenib for BRAF V600-mutant Erdheim-Chester disease and langerhans cell histiocytosis analysis of data from the histology-independent, phase 2, open-label VE-BASKET study. *JAMA Oncol* 2018; 4:384-8.
11. Diamond EL, Durham BH, Ulaner GA, et al. Efficacy of MEK inhibition in patients with histiocytic neoplasms. *Nature* 2019; 567:521-4.
12. Goyal G, Heaney ML, Collin M, et al. Erdheim-Chester disease: consensus recommendations for evaluation, diagnosis, and treatment in the molecular era. *Blood* 2020; 135:1929-45.
13. Diamond EL, Reiner AS, Buthorn JJ, et al. A scale for patient-reported symptom assessment for patients with Erdheim-Chester disease. *Blood Adv* 2019; 3:934-8.

14. Salama H, Kojan S, Abdulrahman S, Azzumea F, Alhejazi A. Erdheim-Chester disease with no skeletal bone involvement and massive weight loss. *Case Rep Hematol* 2017; 2017:3862052.
15. Diamond EL, Dagna L, Hyman DM, et al. Consensus guidelines for the diagnosis and clinical management of Erdheim-Chester disease. *Blood* 2014; 124:483-92.
16. Abla O, Jacobsen E, Picarsic J, et al. Consensus recommendations for the diagnosis and clinical management of Rosai-Dorfman-Destombes disease. *Blood* 2018; 131: 2877-90.
17. Goyal G, Ravindran A, Young JR, et al. Clinicopathological features, treatment approaches, and outcomes in Rosai-Dorfman disease. *Haematologica* 2020; 105: 348-57.
18. Lardhi AA, Al-Mutairi AK, Al-Qahtani MH, Al-Mutairi AK. Rosai-Dorfman disease complicated by autoimmune hemolytic anemia in a child: a case report and review of the literature. *Case Rep Oncol* 2018; 11:55-62.
19. Sachdeva M, Abdulhaq H. A Rare case of Rosai-Dorfman disease in an adult male associated with auto-immune hemolytic anemia. *Med J Hematol Infect Dis* 2013; 5: e2013022.
20. Cooper SL, Arceci RJ, Gamper CJ, Teachey DT, Schafer ES. Successful treatment of recurrent autoimmune cytopenias in the context of sinus histiocytosis with massive lymphadenopathy using sirolimus. *Pediatr Blood Cancer* 2016; 63:358-60.
21. Rosée PL, Horne AC, Hines M, Greenwood, et al. Recommendations for the management of hemophagocytic lymphohistiocytosis in adults. *Blood* 2019; 133: 2465-77.
22. Allen CE, Yu X, Kozinetz CA, McClain KL. Highly elevated ferritin levels and the diagnosis of hemophagocytic lymphohistiocytosis. *Pediatric Blood Cancer* 2008; 50: 1227-35.
23. Fardet L, Galicier L, Lambotte O, et al. (2014). Development and validation of the hscore, a score for the diagnosis of reactive hemophagocytic syndrome. *Arthritis Rheumatol* 2014; 66:2613-20.
24. Debaugnies F, Mahadeb B, Ferster A, et al. Performances of the H-score for diagnosis of hemophagocytic lymphohistiocytosis in adult and pediatric patients. *Am J Clin Pathol* 2016; 145:862-70.
25. Trottestam H, Horne AC, Aricò M, et al. Chemoimmunotherapy for hemophagocytic lymphohistiocytosis: long-term results of the HLH-94 treatment protocol. *Blood* 2011; 118:4577-84.
26. Schram AM, Berliner N. How I treat hemophagocytic lymphohistiocytosis in the adult patient. *Blood* 2014; 125:2908-14.
27. Tsuji T, Hirano T, Yamasaki H, Tsuji M, Tsuda H. A high sIL-2R/ferritin ratio is a useful marker for the diagnosis of lymphoma-associated hemophagocytic syndrome. *Ann Hematol* 2014; 93:821-6.
28. Voskoboinik I, Trapani JA. Perforinopathy: a spectrum of human immune disease caused by defective perforin delivery or function. *Front Immunol* 2013; 4:441.
29. Machowicz R, Suarez F, Jedrzejczak WW, et al. Allogeneic hematopoietic stem cell transplantation in hemophagocytic lymphohistiocytosis (HLH) in adults: a retrospective study of the Chronic Malignancies and Inborn Errors Working Parties (CMWP and IEWP) of the EBMT. *Blood* 2016; 128:3490.
30. Kodan P, Chakrapani M, Shetty M, Pavan R, Bhar P. Hemophagocytic lymphohistiocytosis secondary to infections: a tropical experience! *J Postgrad Med* 2015; 61:112-5.
31. Carter SJ, Tattersall RS, Ramanan AV. Macrophage activation syndrome in adults: recent advances in pathophysiology, diagnosis and treatment. *Rheumatology (Oxford)* 2019; 58:5-17.
32. Vastert SJ, Jamilloux Y, Quartier P, et al. Anakinra in children and adults with Still's disease. *Rheumatology (Oxford)* 2019; 58:vi9-22.
33. Cheng J, Niu J, Wang Y, et al. Hemophagocytic lymphohistiocytosis in pregnancy: a case report and review of the literature. *J Obstet Gynaecol* 2020; 40: 153-9.
34. Samra B, Yasmin M, Arnaout S, Azzi J. Idiopathic hemophagocytic lymphohistiocytosis during pregnancy treated with steroids. *Hematol Rep* 2015; 7:70-3.
35. Ruan Q, Yang K, Wang W, Jiang L, Song J. Clinical predictors of mortality due to COVID-19 based on an analysis of data of 150 patients from Wuhan, China [published correction appears in *Intensive Care Med* 2020; 46:1294-1297]. *Intensive Care Med* 2020; 46:846-8.
36. Opoka-Winiarska V, Grywalska E, Roliński J. Could hemophagocytic lymphohistiocytosis be the core issue of severe COVID-19 cases? *BMC Med* 2020; 18:214.
37. Mehta P, McAuley DF, Brown M, Sanchez E, Tattersall RS, Manson JJ, HLH Across Speciality Collaboration, UK. COVID-19: consider cytokine storm syndromes and immunosuppression. *Lancet* 2020; 395:1033-4.
38. Dimopoulos G, de Mast Q, Markou N, et al. Favorable anakinra responses in severe Covid-19 patients with secondary hemophagocytic lymphohistiocytosis. *Cell Host Microbe* 2020; 28:117-23.e1.
39. Fu B, Xu X, Wei H. Why tocilizumab could be an effective treatment for severe COVID-19? *J Transl Med* 2020; 18:164.
40. RECOVERY Collaborative Group, Horby P, Lim WS, Emberson JR, et al. Dexamethasone in hospitalized patients with Covid-19 - preliminary report. *N Engl J Med* 2020, Online ahead of print.
41. Hamizi K, Aouidane S, Belaaloui G. Etoposide-based therapy for severe forms of COVID-19. *Med Hypotheses* 2020; 142:109826.
42. Marsh RA, Allen CE, McClain KL, et al. Salvage therapy of refractory hemophagocytic lymphohistiocytosis with alemtuzumab. *Pediatr Blood Cancer* 2013; 60: 101-9.
43. Locatelli F, Jordan MB, Allen C, et al. Emapalumab in children with primary hemophagocytic lymphohistiocytosis. *N Engl J Med* 2020; 382:1811-22.