



## Case report

## Plate-assisted bone segment transport: Novel application on distal tibia defect after tumour resection. A case report

Ahmed A. Eldesouqi<sup>a</sup>, Raymond Ching Hin Yau<sup>b,\*</sup>, Wai-Yip Kenneth Ho<sup>b</sup>, Ying-Lee Lam<sup>b</sup><sup>a</sup> Department of Orthopaedic Surgery and Traumatology, Alexandria University, Egypt<sup>b</sup> Department of Orthopaedics & Traumatology, Queen Mary Hospital, Hong Kong

## ARTICLE INFO

## Keywords:

Tibia  
 Bone defect  
 Distraction osteogenesis  
 Plate-assisted bone segment transport  
 Case report  
 Preceice

## ABSTRACT

**Introduction:** Reconstruction of a large bone defect of the distal tibia after limb salvage surgery is difficult. The options include custom-made ankle endoprosthesis replacement, arthrodesis, and biological or metallic intercalary reconstructions. This report introduces a technique that provides the patient with a long-lasting biological reconstruction while preserving the native ankle.

**Presentation of case:** We present the case of a 47-year-old man with osteosarcoma of the distal tibia. After neoadjuvant chemotherapy, wide excision was performed while preserving the ankle joint. Bone reconstruction by Plate-assisted bone segment transport (PABST) was performed with a non-invasive growing intramedullary nail. At 34 months of follow-up, there was solid union and the Musculoskeletal Tumour Society Score was 26/30.

**Discussion:** This is the first report of PABST after distal tibia tumour resection. It shows that this is a viable and safe method of reconstruction. Despite the use of adjuvant chemotherapy, regenerate was formed and union was achieved.

**Conclusion:** PABST is a useful tool in the armamentarium to tackle difficult large bone defects.

## 1. Introduction

Primary bone tumors affecting the distal tibia is uncommon. Only 3.8% of osteosarcomas present at the distal tibia; the 10-year survival rate is 78% [1]. Below knee amputation was the standard treatment for such cases. However, limb salvage surgery is now the achievable goal in most cases in major tumour centres [2].

Reconstruction of the bony defect after limb salvage surgery is difficult in this region. If the ankle joint cannot be salvaged, the options include a custom-made ankle endoprosthesis replacement and arthrodesis. If the ankle joint can be preserved, then the options include biological (allograft, masquet technique, recycled-bone autograft, vascularized or non-vascularized autograft, distraction osteogenesis) and metallic (intercalary prosthesis) reconstructions [2–4].

We report a case with distal tibia defect after osteosarcoma resection that used Plate-assisted bone segment transport (PABST) with a non-invasive growing intramedullary nail for reconstruction. This is the first report in the literature using this technique for reconstruction of the distal tibia defect after oncological resection.

This report has been written in compliance with the SCARE 2020

guidelines [5].

## 2. Presentation of case

A 47-year-old non-smoking gentleman presented with right leg pain for a few months. Examination revealed a bony hard swelling over the anterolateral aspect of distal tibia with mild tenderness.

Radiographs revealed an eccentric lytic lesion at the distal tibial metaphysis with cortical erosion (Fig. 1). Contrast MRI found a 27 × 44 × 59 mm intramedullary mass with breach of the lateral tibial cortex and lobulated extra-osseous component. The tumour involved the interosseous membrane and abutted onto the fibula, anterior tibial neurovascular bundle and peroneal vessels. The lesion was T1-weighted intermediate signal, T2-weighted high signal and contrast-enhancing (Fig. 2). The lesion was biopsied and shown to be a chondroblastic osteosarcoma (Fig. 3). The patient was Enneking Stage IIB [6] as systemic involvement was found to be negative. Two cycles of neoadjuvant chemotherapy (Cisplatin & Doxorubicin) were given.

The surgical options of limb salvage surgery and below-knee amputation were discussed with the patient. He refused amputation as

\* Corresponding author.

E-mail address: [raymondyau@ortho.hku.hk](mailto:raymondyau@ortho.hku.hk) (R.C.H. Yau).

<https://doi.org/10.1016/j.ijscr.2021.106079>

Received 21 April 2021; Received in revised form 26 May 2021; Accepted 3 June 2021

Available online 9 June 2021

2210-2612/© 2021 The Authors. Published by Elsevier Ltd on behalf of IJS Publishing Group Ltd. This is an open access article under the CC BY-NC-ND license

(<http://creativecommons.org/licenses/by-nc-nd/4.0/>).

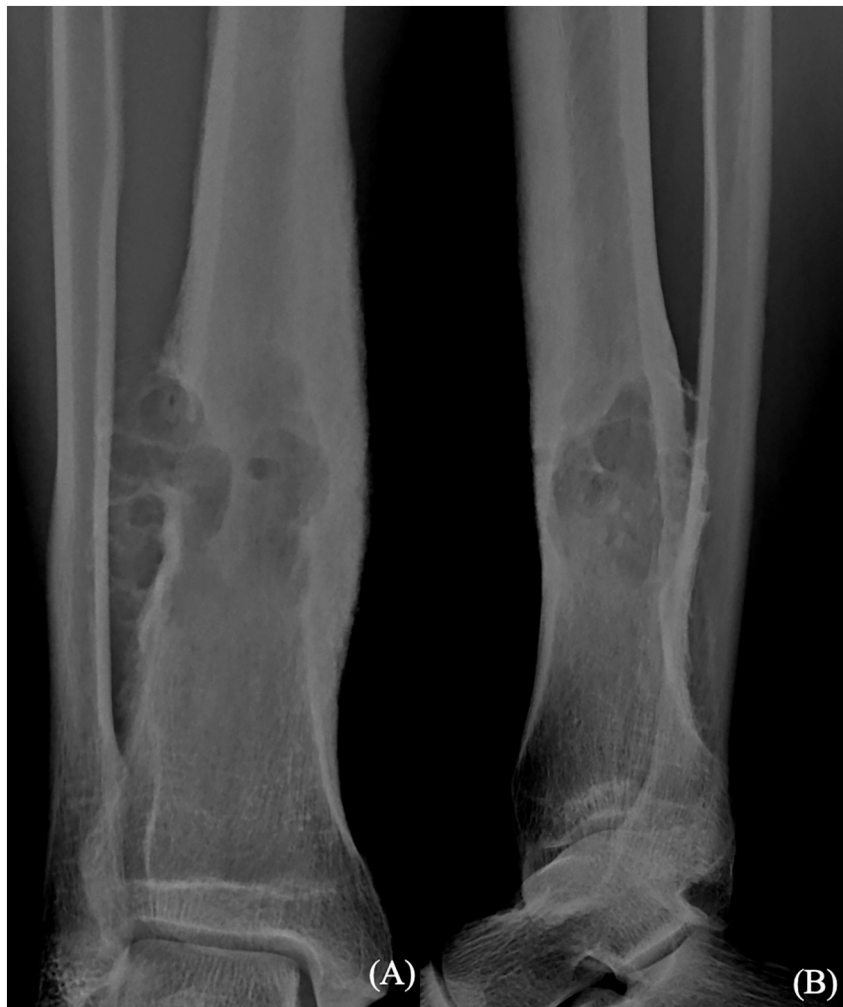

Fig. 1. AP (A) & Lateral (B) radiograph of right distal tibia with lytic lesion at the lateral cortex.

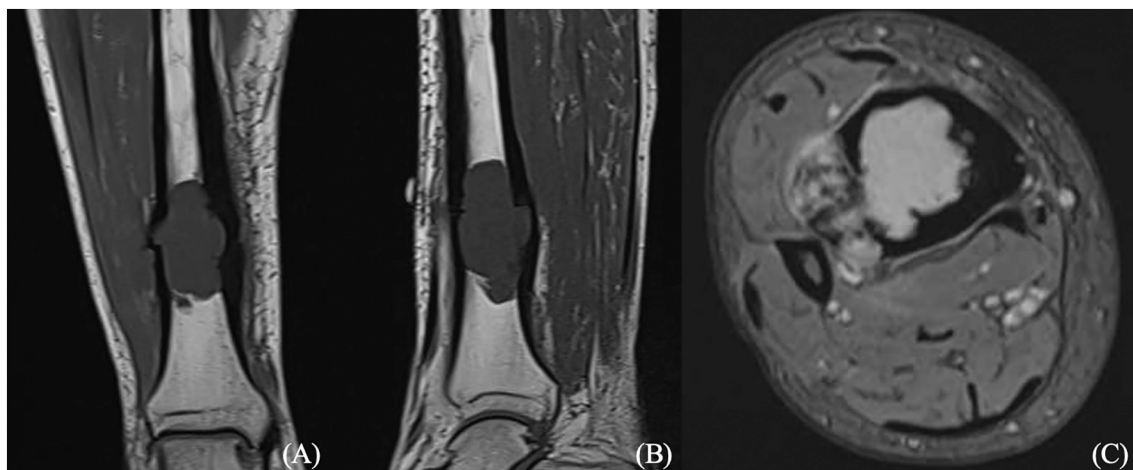
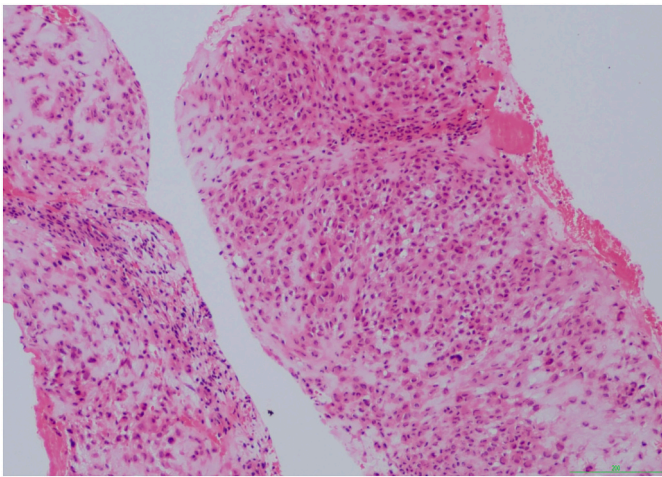


Fig. 2. Contrast MRI of the tumour. T1-weighted coronal (A), sagittal (B) and T2-weighted axial (C) cuts showing cortical breach of the lateral tibial cortex and extra-osseous soft tissue component abutting on the fibula.

long as wide local excision was possible. Reconstruction options were also discussed in length during multiple visits before the surgery. Detailed pre-operative planning was performed based on MRI and CT images. Wide local excision of the distal tibia was performed by the corresponding author (RY) with the aid of a custom 3D-printed cutting-

guide and computer navigation. The medial cortex of the fibula was resected together with the tumour.

The resultant bony defect measured 10 cm in length with 2 cm of tibial plafond remaining. A Nuvasive Specialized Orthopedics (San Diego, USA) Precice® growing nail was inserted. Corticotomy was made



**Fig. 3.** Haematoxylin & Eosin stain of biopsy sample showing a chondroblastic osteosarcoma [Original magnification 40 $\times$ ].

in the proximal tibia with bone gap of 8 mm. The tibial defect was bridged with a 3.5 mm locking plate. There was an iatrogenic fracture of the distal fibula and it was fixed with a distal fibula locking plate (Fig. 4).

Bone transport began 17 days after the operation at 1 mm per day.

Final histology report confirmed a chondroblastic osteosarcoma with tumour necrosis of less than 5%. Immunohistochemical stain for IDH1 was negative. The resection margins were clear and Ki-67 proliferative index was less than 1%. The patient completed 4 cycles of adjuvant chemotherapy (Cisplatin & Doxorubicin). Bone transport continued through-out his chemotherapy at 0–1 mm per day.

At 7 months after the index surgery, the nail reached its maximum distraction distance of 80 mm. Approximately 35 mm of defect remained. The second surgery was performed to revise the distal fixation

of the nail. It was complicated by superficial wound infection which resolved with debridement and antibiotics. Bone transport resumed 6 days after the second surgery and continued until docking was achieved at 10 months (Fig. 5).

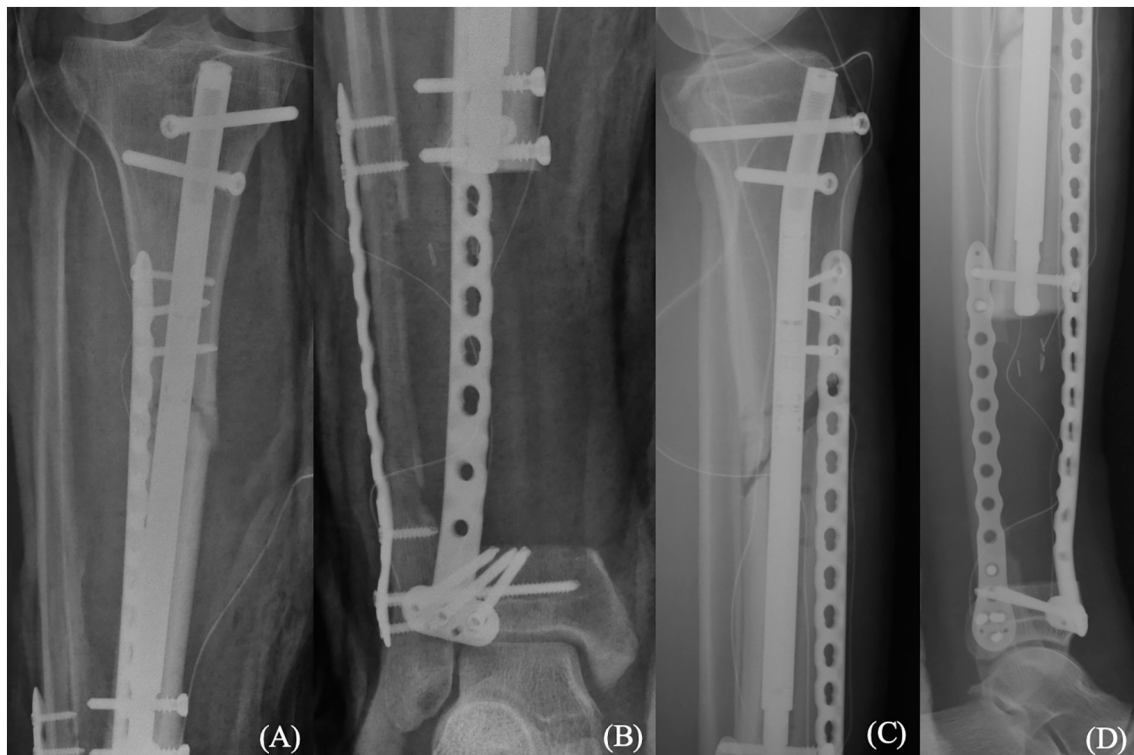
A third surgery was performed at 13 months where the Precice® nail was exchanged with a static titanium nail. Corticocancellous bone graft was taken from the iliac crest and fixed to the docking site with a screw. Cancellous bone graft from the iliac crest was placed at the regenerate. Progressive weight bearing was allowed and at 26 months after the index surgery, both the regenerate and docking sites showed bony union.

The latest follow-up was at 34 months after index surgery. The range of motion of his knee was 0–130°, and 0–30° for his ankle. He was able to walk on hiking trails and could drive. The Musculoskeletal Tumour Society Score [7] was 26/30. There was good consolidation of the corticotomy and docking sites (Fig. 6), and no evidence of recurrent or metastatic disease on surveillance MRI and PET/CT scans.

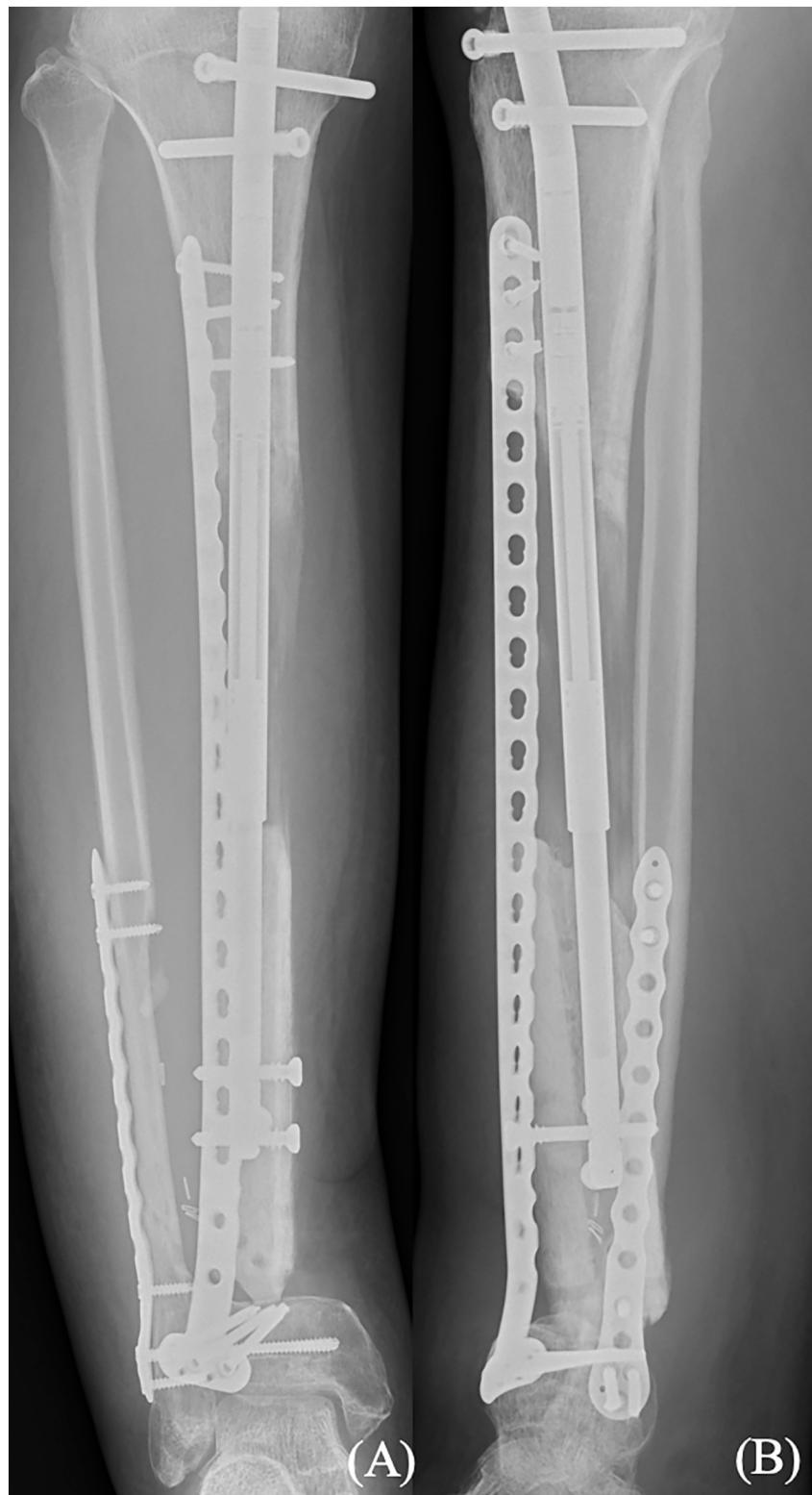### 3. Discussion

Reconstruction of distal tibia bone defects after resection of a malignant bone tumour is a challenge due to the difficulty to obtain good soft tissue coverage [8,9] and lack of established endoprosthesis for the ankle joint; hence below-knee amputation was the standard treatment in the past. Satisfactory functional results were reported [1,10] but nowadays amputation is not easily accepted by the patient. Early rehabilitation is offset by significant psychological, social and prosthetic issues in the longer term [10,11]. Many tumour centres can now perform limb salvage surgery for most of their patients and a multitude of reconstruction methods have been reported for distal tibia defects without clear superiority [2–4].

The ideal reconstruction should have biological affinity, resistance to infection, adequate biomechanical strength, durability and minimal complications [12].



**Fig. 4.** Postoperative AP (A&B) & Lateral (C&D) radiographs showing resection of distal tibial tumour, and corticotomy, with Precice® nail and locking plates inserted.



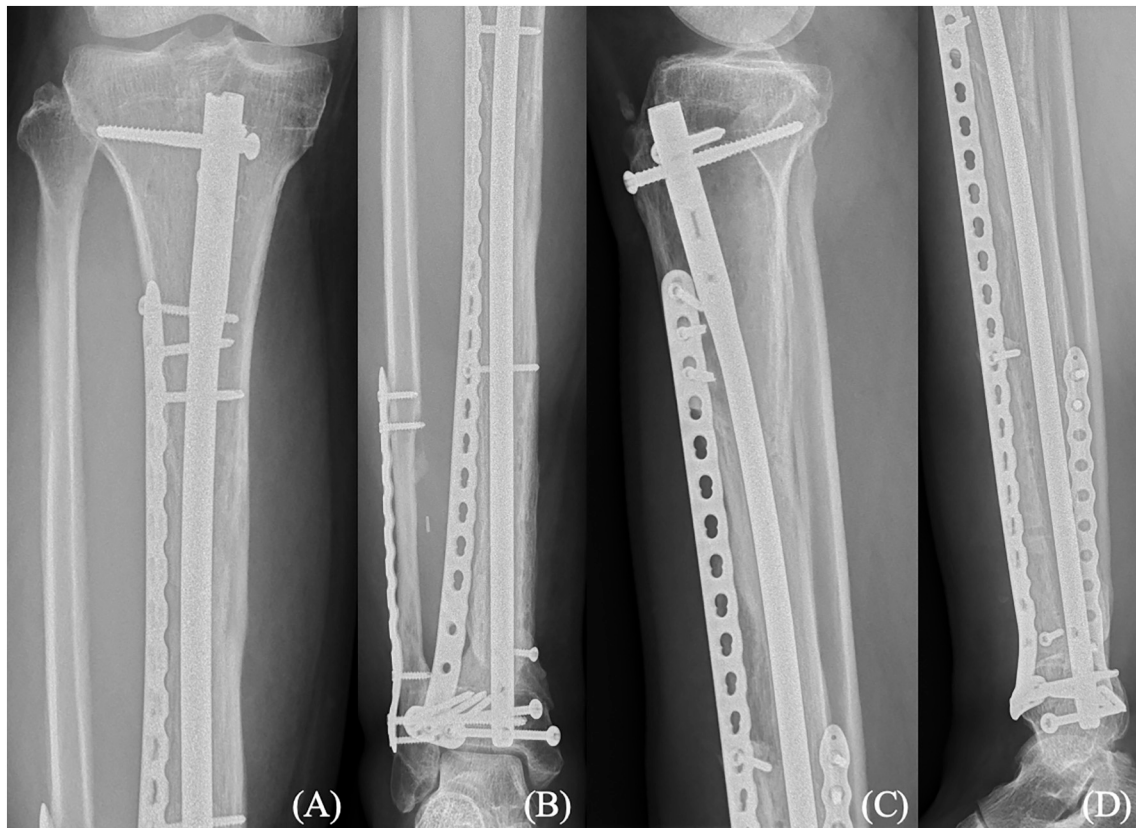
**Fig. 5.** AP (A) & lateral (B) radiographs at 10 months follow-up showing docking of the transported bone segment and regenerate formation.

Endoprosthetic replacements restore skeletal integrity immediately and allow early rehabilitation. However, late complications such as infection, wear, and loosening subject the long-term survivor to revision surgeries and the risk of delayed amputation [13–15].

Allografts can be used to reconstruct both small and large defects. However, they may not be readily available [16] and obtaining a good fit is sometimes difficult. Moreover, their use is associated with high

rates of fracture (12–20%), nonunion (11–17%) and infection (12–15%) [17,18].

Autografts provide a biological means of reconstruction for small defects while large defects demand the use of vascularized fibular graft which is technically demanding and has significant donor site morbidity. In our case, the use of the ipsilateral fibula as a pedicle graft was not desirable as the resection margin included the medial cortex of



**Fig. 6.** AP (A&B) & lateral (C&D) radiographs at 34 months follow-up showing consolidation of regenerate and union at docking site. Static titanium tibial nail has been inserted.

the distal fibula.

Bone recycling is an attractive option due to its simple technique and exact size-matching. However, complete incorporation by living bone takes a long time [19].

Distraction osteogenesis is a biological reconstructive technique that can generate healthy bone [20–25]. When the regenerate ossifies and there is union at the docking site, skeletal integrity is restored with living bone that has resistance against infection and can remodel to stress [26]. This technique has been widely used for the treatment of deformity, limb-length discrepancy, osteomyelitis, non-union and traumatic bone defects [3]. Traditional distraction osteogenesis requires the prolonged use of external fixator which carries a significant risk of infection. This is particularly undesirable for oncological patients who undergo chemotherapy. There is also some concern that chemotherapy may affect the formation of regenerate. However, the evidence is discordant [27–31] and no conclusion can be drawn at the present.

Tsuchiya et al. [29] reported the use of distraction osteogenesis for reconstruction of bony defects after excision of tumour. In their series of 19 patients with defects in the femur or tibia, unilateral frame or Ilizarov external fixator was applied with additional intramedullary nail in selected cases. Excellent results were achieved although complications were present for 10 of the 19 patients.

With the development of a non-invasive growing intramedullary nail, the risk of infection in distraction osteogenesis is reduced. Its use in PABST was reported recently [32]. This is an attractive technique for the musculoskeletal oncology patient as it provides skeletal stabilization with all-internal fixation and bone transport can be continued during adjuvant chemotherapy by the patient at home. After the regenerate has consolidated, this biological reconstruction should last the patient's lifetime.

The reconstruction by this technique is limited by the distraction length of the Precice® nail (80 mm). Hence a second operation was

required to reset the distracted nail. It also had to be exchanged to a static titanium nail subsequently as it was not MRI-compatible. Union at the docking site and consolidation of the regenerate are also variables that may require close monitoring and additional bone grafting procedure.

In our literature search for bone transport via an all-internal fixation technique, we found only a few examples of oncological patients and only one involving the tibia [33]. We report this first case of PABST after distal tibia tumour resection to demonstrate the feasibility of an uncommon technique in this difficult area. The addition of a bridging-plate gives adequate stability for a defect close to the joint. Given the risks inherent to the prolonged use of external fixator, many surgeons may not consider bone transport as a viable option without awareness of this technique, and may not attempt to salvage the native ankle joint. We believe this is a useful tool to add to the armamentarium of the orthopaedic oncologist.

#### 4. Conclusion

This is the first case report of bone transport using the PABST technique after distal tibia tumour resection. It shows that this is a viable and safe method of reconstruction for a difficult distal tibia large bone defect. Despite the use of chemotherapy, regenerate was formed and consolidated to give the patient excellent long-term prospects.

#### Sources of funding

This research did not receive any specific grant from funding agencies in the public, commercial, or not-for-profit sectors.

## Ethical approval

Ethical approval by the Institutional Review Board of the University of Hong Kong/Hospital Authority Hong Kong West Cluster has been obtained (Ref No. UW 15-414)

## Consent

Written consent was obtained from the patient for publication of this case report and accompanying images. A copy of the written consent is available for review by the Editor-in-Chief of this journal on request.

## CRedit authorship contribution statement

Ahmed A Eldesouqi: Drafting of manuscript.  
Raymond Ching Hin Yau: Data collection, Revision of manuscript.  
Wai-Yip Kenneth Ho: Data analysis and interpretation, Revision of manuscript.  
Ying-Lee Lam: Conception of work, Final approval.  
Research Registration.  
Not applicable.  
Guarantor.  
Raymond Ching Hin Yau, Ying-Lee Lam.

## Declaration of competing interest

Nothing to declare.

## Acknowledgements

We would like to acknowledge the help of Dr. Shek Wai Hung, Tony (Department of Pathology, Queen Mary Hospital, Hong Kong) for his help in preparation of the histology slide.

## Provenance and peer review

Not commissioned, externally peer-reviewed.

## References

- [1] A.F. Mavrogenis, C.N. Abati, C. Romagnoli, P. Ruggieri, Similar survival but better function for patients after limb salvage versus amputation for distal tibia osteosarcoma, *Clin. Orthop. Relat. Res.* 470 (6) (2012) 1735–1748.
- [2] R.J. Grimer, Surgical options for children with osteosarcoma, *Lancet Oncol.* 6 (2) (2005) 85–92.
- [3] K. Erler, C. Yildiz, B. Baykal, A.S. Atesalp, M.T. Ozdemir, M. Basbozkurt, Reconstruction of defects following bone tumor resections by distraction osteogenesis, *Arch. Orthop. Trauma Surg.* 125 (3) (2005) 177–183.
- [4] P. Kunz, L. Bernd, Methods of biological reconstruction for bone sarcoma: indications and limits, *Recent Results Cancer Res.* 179 (2009) 113–140.
- [5] R.A. Agha, T. Franchi, C. Sohrabi, G. Mathew, A. Kerwan, The SCARE 2020 guideline: updating consensus surgical CAse REport (SCARE) guidelines, *Int. J. Surg.* 84 (2020) 226–230.
- [6] W.F. Enneking, S.S. Spanier, M.A. Goodman, A system for the surgical staging of musculoskeletal sarcoma, *Clin. Orthop. Relat. Res.* (153) (1980) 106–120.
- [7] W.F. Enneking, W. Dunham, M.C. Gebhardt, M. Malawar, D.J. Pritchard, A system for the functional evaluation of reconstructive procedures after surgical treatment of tumors of the musculoskeletal system, *Clin. Orthop. Relat. Res.* (286) (1993) 241–246.
- [8] S. Shalaby, H. Shalaby, A. Bassiony, Limb salvage for osteosarcoma of the distal tibia with resection arthrodesis, autogenous fibular graft and Ilizarov external fixator, *J. Bone Joint Surg. (Br.)* 88 (12) (2006) 1642–1646.
- [9] W. Ebeid, S. Amin, A. Abdelmegid, Y. Refaat, A. Ghoneimy, Reconstruction of distal tibial defects following resection of malignant tumours by pedicled vascularised fibular grafts, *Acta Orthop. Belg.* 73 (3) (2007) 354–359.
- [10] A.M. Davis, M. Devlin, A.M. Griffin, J.S. Wunder, R.S. Bell, Functional outcome in amputation versus limb sparing of patients with lower extremity sarcoma: a matched case-control study, *Arch. Phys. Med. Rehabil.* 80 (6) (1999) 615–618.
- [11] M. Laitinen, J. Hardes, H. Ahrens, et al., Treatment of primary malignant bone tumours of the distal tibia, *Int. Orthop.* 29 (4) (2005) 255–259.
- [12] Y.Y. Abed, G. Beltrami, D.A. Campanacci, M. Innocenti, G. Scoccianti, R. Capanna, Biological reconstruction after resection of bone tumours around the knee: long-term follow-up, *J. Bone Joint Surg. (Br.)* 91 (10) (2009) 1366–1372.
- [13] G. Ottaviani, R.S. Robert, W.W. Huh, N. Jaffe, Functional, psychosocial and professional outcomes in long-term survivors of lower-extremity osteosarcomas: amputation versus limb salvage, *Cancer Treat. Res.* 152 (2009) 421–436.
- [14] L.M. Jeys, R.J. Grimer, S.R. Carter, R.M. Tillman, Risk of amputation following limb salvage surgery with endoprosthetic replacement, in a consecutive series of 1261 patients, *Int. Orthop.* 27 (3) (2003) 160–163.
- [15] D. Biau, F. Faure, S. Katsahian, C. Jeanrot, B. Tomeno, P. Anract, Survival of total knee replacement with a megaprosthesis after bone tumor resection, *J. Bone Joint Surg. Am.* 88 (6) (2006) 1285–1293.
- [16] C. Delloye, O. Cornu, V. Druetz, O. Barbier, Bone allografts: what they can offer and what they cannot, *J. Bone Joint Surg. Br. Vol.* 89 (2007) 574–579.
- [17] R.C. Thompson Jr., A. Garg, D.R. Clohisy, E.Y. Cheng, Fractures in large-segment allografts, *Clin. Orthop. Relat. Res.* 370 (2000) 227–235.
- [18] N. Dion, F.H. Sim, The use of allografts in musculoskeletal oncology, *Instr. Course Lect.* 51 (2002) 499–506.
- [19] K. Hayashi, H. Tsuchiya, N. Yamamoto, H. Minato, K. Tomita, Histological examination of autoclaved bone removed 12 years after it was transplanted, *J. Orthop. Sci.* 10 (4) (2005) 425–429.
- [20] H. Tsuchiya, M.E. Abdel-Wanis, K. Tomita, Biological reconstruction after excision of juxta-articular osteosarcoma around the knee: a new classification system, *Anticancer Res.* 26 (1B) (2006) 447–453.
- [21] H. Tsuchiya, K. Tomita, Distraction osteogenesis for treatment of bone loss in the lower extremity, *J. Orthop. Sci.* 8 (1) (2003) 116–124.
- [22] H. Tsuchiya, M. Abdel-Wanis, S. Kitano, K. Sakurakichi, T. Yamashiro, K. Tomita, The natural limb is best: joint preservation and reconstruction by distraction osteogenesis for high-grade juxta-articular osteosarcomas, *Anticancer Res.* 22 (4) (2002) 2373–2376.
- [23] H. Tsuchiya, M.E. Abdel-Wanis, K. Sakurakichi, T. Yamashiro, K. Tomita, Osteosarcoma around the knee. Intraepiphyseal excision and biological reconstruction with distraction osteogenesis, *J. Bone Joint Surg. (Br.)* 84 (8) (2002) 1162–1166.
- [24] K. Hayashi, H. Tsuchiya, N. Yamamoto, A. Takeuchi, K. Tomita, Functional outcome in patients with osteosarcoma around the knee joint treated by minimised surgery, *Int. Orthop.* 32 (1) (2008) 63–68.
- [25] H. Tsuchiya, A.F. Morsy, H. Matsubara, K. Watanabe, M.E. Abdel-Wanis, K. Tomita, Treatment of benign bone tumours using external fixation, *J. Bone Joint Surg. (Br.)* 89 (8) (2007) 1077–1083.
- [26] K. Watanabe, H. Tsuchiya, N. Yamamoto, et al., Over 10-year follow-up of functional outcome in patients with bone tumors reconstructed using distraction osteogenesis, *J. Orthop. Sci.* 18 (1) (2013) 101–109.
- [27] M. Subasi, A. Kapukaya, C. Kesemenli, T.A. Balci, H. Buyukbayram, M. Ozates, Effect of chemotherapeutic agents on distraction osteogenesis. An experimental investigation in rabbits, *Arch. Orthop. Trauma Surg.* 121 (7) (2001) 417–421.
- [28] J. Canadell, M. San-Julian, J. Cara, F. Forriol, External fixation in tumour pathology, *Int. Orthop.* 22 (2) (1998) 126–130.
- [29] H. Tsuchiya, K. Tomita, K. Minematsu, Y. Mori, N. Asada, S. Kitano, Limb salvage using distraction osteogenesis. A classification of the technique, *J. Bone Joint Surg. (Br.)* 79 (3) (1997) 403–411.
- [30] B. Demiralp, T. Ege, O. Kose, Y. Yurttas, M. Basbozkurt, Reconstruction of intercalary bone defects following bone tumor resection with segmental bone transport using an Ilizarov circular external fixator, *J. Orthop. Sci.* 19 (6) (2014) 1004–1011.
- [31] H. Tsuchiya, T. Shirai, A.F. Morsy, et al., Safety of external fixation during postoperative chemotherapy, *J. Bone Joint Surg. (Br.)* 90 (7) (2008) 924–928.
- [32] G. Barinaga, A.M. Beason, M.P. Gardner, Novel surgical approach to segmental bone transport using a magnetic intramedullary limb lengthening system, *J. Am. Acad. Orthop. Surg.* 26 (22) (2018) e477–e482.
- [33] U.K. Olesen, T. Nygaard, D.E. Prince, et al., Plate-assisted bone segment transport with motorized lengthening nails and locking plates: a technique to treat femoral and tibial bone defects, *J. Am. Acad. Orthop. Surg. Glob. Res. Rev.* 3 (8) (2019), e064.