



Treatment of osteoporotic fractures in alkaptonuria by teriparatide stimulates bone formation and decreases fracture rate – A report of two cases

L.R. Ranganath^{a,d}, M. Khedr^a, A. Mistry^b, S. Vinjamuri^c, J.A. Gallagher^{d,*}

^a Department of Clinical Biochemistry and Metabolic Medicine, Royal Liverpool University Hospital, Prescot Street, Liverpool L7 8XP, United Kingdom

^b Department of Radiology, Royal Liverpool University Hospital, Prescot Street, Liverpool L7 8XP, United Kingdom

^c Department of Nuclear Medicine, Royal Liverpool University Hospital, Prescot Street, Liverpool L7 8XP, United Kingdom

^d IACD, University of Liverpool, William Henry Duncan Building, West Derby Street, Liverpool L7 8TX, United Kingdom

ARTICLE INFO

Keywords:

Alkaptonuria
Nitisinone
Homogentisic acid
Ochronosis
Osteoporosis
Bisphosphonates
Teriparatide
Fractures
PTH
P1NP
CTX
DEXA
CtBMD

ABSTRACT

Two cases of advanced alkaptonuria (AKU) with co-existing osteoporosis are described. Case 1 developed multiple non-vertebral fragility fractures, while Case 2 developed vertebral fragility fractures, both refractory to bisphosphonates. Difficulties in diagnosing osteoporosis in AKU complicated by extensive calcifying and ossifying spondylosis are discussed. Both patients continued to fracture despite nitisinone therapy for metabolic control of AKU, as well as bisphosphonate antiresorptive therapy for osteoporosis. Subsequently the patients were treated with teriparatide 20 µg subcutaneous injections daily for two years, leading to reduction in fractures soon after commencing therapy in both cases. Markers of bone remodelling P1NP and CTX were stimulated. No complications due hypercalcaemia or calcification were encountered in either case. We conclude that teriparatide is an effective adjunct in the treatment of AKU when bisphosphonates prove ineffective.

1. Introduction

Abnormalities of the homogentisate 1,2 dioxygenase (HGD; EC 1.13.11.5) gene, which maps to the human chromosome 3q21-q23, results in the autosomal recessive disorder alkaptonuria (AKU; OMIM 203500), a multisystem disorder with a general prevalence of approximately 1: 250,000–1,000,000 (La Du et al., 1958; Phornphutkul et al., 2002; O'Brien et al., 1963). Absence of HGD leads to the failure to breakdown homogentisic acid (HGA) resulting in ochronosis, the deposition of pigment in connective tissues including cartilage (Zannoni et al., 1969; Ranganath et al., 2019). Ochronosis makes connective tissues brittle and liable to degradation (Taylor et al., 2011). The symptoms of AKU are the result of ochronosis-mediated tissue damage, and include pigmentation in ears, eyes and skin, as well as lithiasis (kidney,

prostate, gall bladder, salivary), renal failure, osteopenia, fracture, ruptures (tendon, ligaments, muscle), spondylo-arthropathy (weight-bearing regions), kyphosis, scoliosis and osteoarthritis (Ranganath and Cox, 2011; Cox and Ranganath, 2011). There is now an efficacious therapy in AKU (Ranganath et al., 2020) nitisinone, an inhibitor of hydroxyphenylpyruvate dioxygenase (HPPD; EC 1.13.11.27), which potently and rapidly decreases HGA.

Although alkaptonuria is sometimes referred to as “black bone disease”, mineralised bone matrix does not become pigmented possibly because the mineral prevents HGA binding to collagen. Despite the lack of ochronosis in bone, the risk of osteoporosis in AKU has been underestimated. For example, an influential review of 58 confirmed AKU patients did not mention osteoporosis or fractures (Phornphutkul et al., 2002). However, it has recently been shown that osteoporosis and

Abbreviations: PTH, parathyroid hormone; P1NP, procollagen type 1 N-terminal propeptide; CTX, C terminal telopeptide; DEXA, dual-energy X-ray absorptiometry; CtBMD, cortical bone mineral density.

* Corresponding author at: Department of Clinical Biochemistry and Metabolic Medicine, Royal Liverpool University Hospital, Prescot Street, Liverpool L7 8XP, United Kingdom.

E-mail address: jag1@liverpool.ac.uk (J.A. Gallagher).

<https://doi.org/10.1016/j.bonr.2021.101151>

Received 31 August 2021; Received in revised form 9 November 2021; Accepted 15 November 2021

Available online 28 November 2021

2352-1872/© 2021 Published by Elsevier Inc. This is an open access article under the CC BY-NC-ND license (<http://creativecommons.org/licenses/by-nc-nd/4.0/>).

fractures are common features of AKU (Ranganath et al., 2021). Focal osteoporosis, possibly as a result of stress shielding by ochronotic cartilage, and excessive osteoclastic activity leads to thinning of trabeculae and subchondral plates in affected joints (Taylor et al., 2011) and aberrant bone formation which can lead to the formation of trabecular excrescences (Taylor et al., 2012). These latter structures involve templating of bone by adipocytes and possibly synthesis of matrix by these cells. There is also generalised osteopenia in vertebral and non-vertebral sites, leading to fractures. One small survey has indicated that the frequency of osteopenia and fractures in a cohort of 15 AKU patients was 46.7 and 53.3% respectively (Ranganath and Cox, 2011). Brunetti et al. reported that in a cohort of 7 adult AKU patients while lumbar spine T-score was inside the normal range, femoral T-score reached osteopenic levels. Furthermore higher circulating RANKL and C-terminal telopeptide of collagen type 1 and lower osteoprotegerin levels were observed than in controls (Brunetti et al., 2018). Additionally, spontaneous osteoclastogenesis and high percentage osteoclast precursors in peripheral blood mononuclear cell cultures were detected in two children with AKU (Brunetti et al., 2018). Spinal fracture has been reported previously by a few authors (Millea et al., 1992; Paniagua et al., 2015; Wu et al., 2019).

There is no evidence that nitisinone stabilises BMD or prevents fractures in AKU. Furthermore, there is no evidence that oral bisphosphonates, can reverse the bone loss process or prevent fractures in ochronotic osteoporosis, even though it is used as the mainstay of treatment (Aliberti et al., 2007; Zacharia et al., 2009). A recent study of 87 patients (55 men and 32 women) attending the United Kingdom National Alkaptonuria Centre at the Royal Liverpool University Hospital (NAC) revealed a high risk of bone loss and fractures in AKU (Ranganath et al., 2021).

We report two patients with AKU attending the NAC with advanced AKU complicated by osteoporosis and recurrent fractures despite bisphosphonate therapy. We describe our experience with teriparatide (1–34) therapy in these two patients.

2. Case reports

2.1. Case 1

A Caucasian female, 61 years of age, with AKU diagnosed at 53 years. Discolouration of her eyes and ears appeared in her late thirties. A small pigmented macule appeared on the chin in her late forties. A skiing accident at the age of 17 years caused damage to ligaments and tendons. A torn hamstring followed in 2005. Cervical, thoracic and lumbar spine, knee, hip, ankle, feet, shoulder and hand, were painful. She had lost 4 in. in height. Activity levels remained excellent with walking 3–5 miles regularly. She was a non-smoker and consumed 14–20 units of alcohol per week. Medications included omega fish oils, vitamin C 1 g daily, as well as glucosamine and chondroitin sulphates, paracetamol and ibuprofen since 2000. A five-year course of post-menopausal oestrogen replacement therapy followed at age 50 years. Stress fractures of the right tibia and right fibula followed at age 60 and 61 years respectively. Left total hip replacement for ochronotic osteoarthropathy followed at age of 59 years.

BMI was 20.1 kg/m² with a weight of 50.2 kg. Her blood pressure was initially labile at around 146/90 mmHg. Her chest expansion was 8 cm. Her peak expiratory flow rate was 400 l/min. Pulse was 75/min regular and felt in all accessible peripheral arteries. She had Dupuytren's contracture in the right hand. Pigmentation was noted in both her eyes and ears (Fig. 1). Kyphoscoliosis was also noticed.

2.1.1. Investigations

X-ray of the thoracic and lumbar spine showed widespread spondylotic changes associated with distal calcification and osteophyte formation. There was lumbar scoliosis as well as fused vertebrae at T12-L2., T10-T11 and T5-T7. MRI Scan of the spine showed widespread

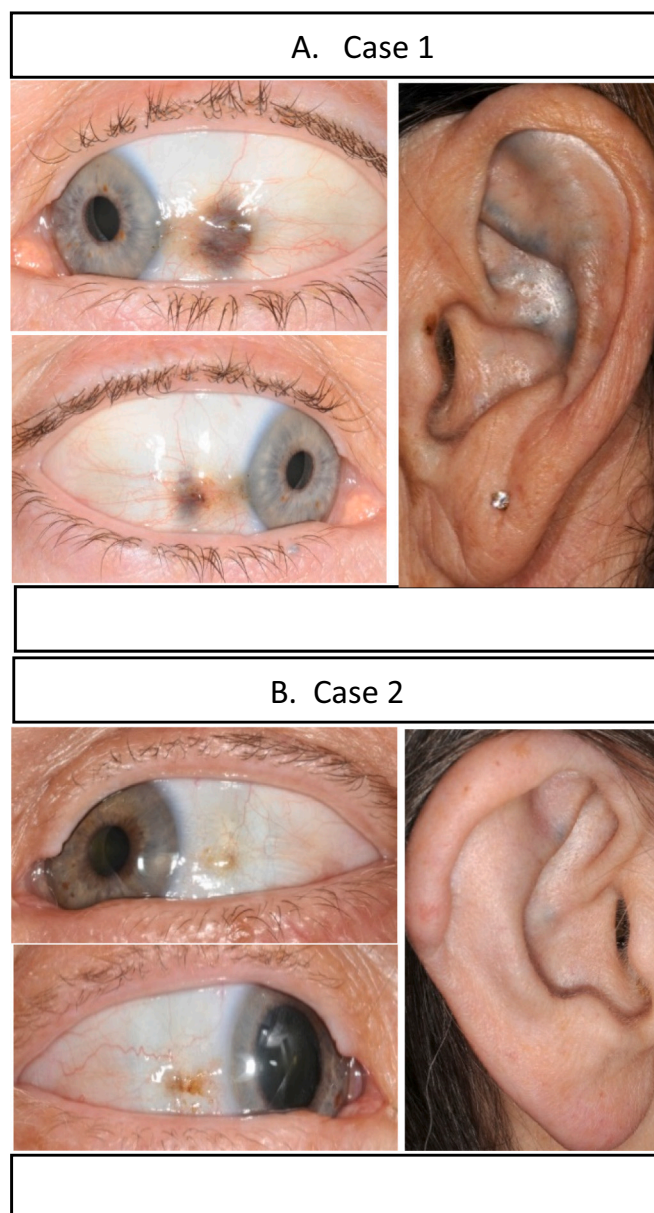


Fig. 1. (A) Case 1 and (B) Case 2 showing scleral and auricular ochronosis.

spondylotic change with spinal fusion. No vertebral fractures were noted. The F¹⁸ PET CT Bone scan showed active arthropathy in both shoulders, several vertebrae in the cervical, thoracic and lumbar spines, right ankle and the left mid foot. Linear and intense tracer uptake in three right lower ribs suggested low-trauma or stress fractures. A standard echocardiogram showed slightly thickened mitral and aortic valves, which opened well and were not stenosed. DEXA assessment was made using DXA scanner GE iDXA 2005. QCT Images were acquired on GE PET-CT Discovery 690; 2010. Software analysed using QCTPRO provided by Mindways 2010.

2.1.2. Treatment and progress

She started nitisinone 2 mg oral in June 2012, along with dietary protein restriction (Table 1). In 2013, further stress fracture in the tibia in 2012 followed. Calcium and vitamin D supplementation, as well as intravenous zoledronate 5 mg were then administered. Left hip, right shoulder and the left shoulder replacements followed at the ages of 59, 62 and 63 years. F¹⁸ PET CT scintigraphic scan in 2014 suggested stress fractures of second right rib and several ribs in the left rib cage. Three

Table 1
Metabolic, bone mineral density and Bath indices data before and after nitisinone in Case 1 and 2.

Metabolic data before and after nitisinone in Case 1 and 2.					
	Serum homogentisic acid $\mu\text{mol/l}$	Serum tyrosine $\mu\text{mol/l}$	Serum nitisinone $\mu\text{mol/l}$	Daily urine homogentisic acid excretion $\mu\text{mol}/24\text{ h}$	
Case 1					
Baseline (V1)	75	82	<0.2	24,260	
12 Months (V3)	4.7	422	1.4	357	
24 Months (V4)	<3.1	778	1.1	541	
36 Months (V5)	2.3	915	1.0	361	
48 Months (V6)	1.3	762	1.7	355	
60 Months (V7)	<3.1	598	1.1	274	
72 Months (V8)	<3.1	742	1.5	211	
Case 2					
Baseline (V1)	16.7	50	<0.2	17,272	
12 Months (V2)	<3.1	1127	0.8	173	
24 Months (V3)	3.4	1224	0.9	187	
36 Months (V4)	<3.1	895	1.2	154	
48 Months (V5)	<3.1	1002	1.2	96	
60 Months (V6)	2.1	707	0.9	188	
72 Months (V7)	<3.1	1135	1.0	156	
Bone mineral density (BMD) and Bath indices data before and after teriparatide					
			Baseline	Pre-teriparatide	Post-teriparatide
Case 1	DEXA	Neck of femur	-2.6		-2.5
		Total hip	-		-
	CTBMD	L2-L4	-1.5		+1.7
		Neck of femur	-2.97	-3.1	-3.2
		Total hip	-3.62	-3.73	-3.71
Case 2	CTBMD	L2-L4	-3.78	-3.42	-2.3
		L2-L4			+0.2
Case 1	BASDAI		5	6.09	4.93
	BASFI		3.8	3.26	3.9
	BASMI		4.0	3.2	3.4
Case 2	BASDAI		4.29	7.35	7.8
	BASFI		4.6	5.6	4.5
	BASMI		6.5	7.4	7.7

further stress fractures in the metatarsals in the right foot followed (Fig. 2A & B). Additional investigations at this stage showed: Blood tests (reference range in brackets) – 25-hydroxycholecalciferol 114 nmol/l (>75); sodium 140 mmol/l (133–146), potassium 4.0 mmol/l (3.5–5.3), chloride 96 mmol/l (95–108), bicarbonate 25 mmol/l (22–29), urea 3.5 mmol/l (2.5–7.8), creatinine 73 $\mu\text{mol/l}$ (50–130), eGFR 70 ml/min (>60), anion gap 23 (6–16), glucose 4.5 mmol/l (3.5–6.0), adjusted calcium 2.31 mmol/l (2.2–2.6), phosphate 1.21 mmol/l (0.8–1.5), total protein 73 g/l (60–80), albumin 49 g/l (35–50), globulin 24, ESR 9 mm/h (<20), haemoglobin 127 g/l (118–148), haematocrit 0.378 (0.39–0.44), white blood count 7.1×10^9 (3.5–11), platelets 473×10^9 (150–400). Her alkaptonuria metabolic data are shown in Table 1. Her bone metabolism data is shown in Fig. 3. Her bone mineral density studies are shown in Table 1. Coeliac disease, myeloma, hyperparathyroidism, vitamin D deficiency and hyperthyroidism were excluded.

The patient continued to fracture despite bisphosphonates therapy and therefore teriparatide 20 μg daily subcutaneous self-injection was commenced in January 2015, with discontinuation of zoledronate (after nearly 5 years of bisphosphonates). A triple arthrodesis of the right foot was also carried out in October 2016. She had no further fractures after commencing teriparatide and she completed two years of teriparatide therapy in January 2017. She was then switched to denosumab 60 mg subcutaneous injection therapy with the first injection on 18th January 2017. In November 2017, she underwent a right scarf or double chevron angulation peri-articular osteotomy and lateral release surgery to straighten her big toe. She then developed an abscess of the hard palate in the midline in December 2018, which was excised and histology consistent with osteonecrosis of the hard palate. She has not had any new fracture three years after teriparatide therapy.

2.2. Case 2

A Caucasian female, 65 years of age, was diagnosed with AKU following total left knee replacement at 54 years of age. Ascorbic acid 1 g daily was started. She had pigmentation of her ears, as well as black ear wax. She had no fractures or ruptured tendon, muscle or ligament. Cervical, thoracic and lumbar spine, knees, hips and shoulders were painful, requiring naproxen and cocodamol. She had noticed increasing kyphosis. She was a non-smoker and consumed 2 units of alcohol and had never smoked. Her menarche was at the age of 14 years. Oestrogen replacement therapy followed for five years at 39 years following a surgical menopause. Total right hip replacement, total left hip replacement, total left shoulder replacement, total right knee replacement, total right shoulder replacement, and a revision right shoulder surgery followed at 55, 57, 58, 60, 61, and 62 years of age.

She was 1.56 m with a weight of 66 kg and a BMI of 27 kg/m². Blood pressure was 142/80 mmHg. Chest expansion was 4 cm. Peak expiratory flow-rate was 350 l/min. Pulse was 83 per minute regular and felt in accessible peripheral arteries. Ochronotic pigmentation in the nails of the hands, eyes, ears and epiglottis (Fig. 4) were observed. Restricted spinal movements were seen in all planes, with bony enlargement in small joints of the hands, and bilateral hallux valgus deformity.

2.2.1. Investigations

Transthoracic echocardiogram demonstrated a thickened but not stenosed mitral valve, with mitral annulus calcification. The aortic valve was also thickened but not stenosed, but with dilated aortic sinus and ascending aorta. MRI of spine revealed asymptomatic mild wedge chronic insufficiency fractures of T6-T9 and chronic insufficiency vertebral inferior endplate fracture at L4 despite an X-ray of the spine showing no fracture, and alendronate 70 mg was begun. End-stage changes at the intervertebral discs of the thoracic and lumbar spine, with multiple segment fusions of T7 to T9, T10 to T11 and T12 to L4 were seen. F¹⁸ PET CT scintigraphic scan showed active extensive arthropathy in the cervical, upper thoracic, mid thoracic and lumbar regions, both acromioclavicular joints, right 5th rib costo-transverse

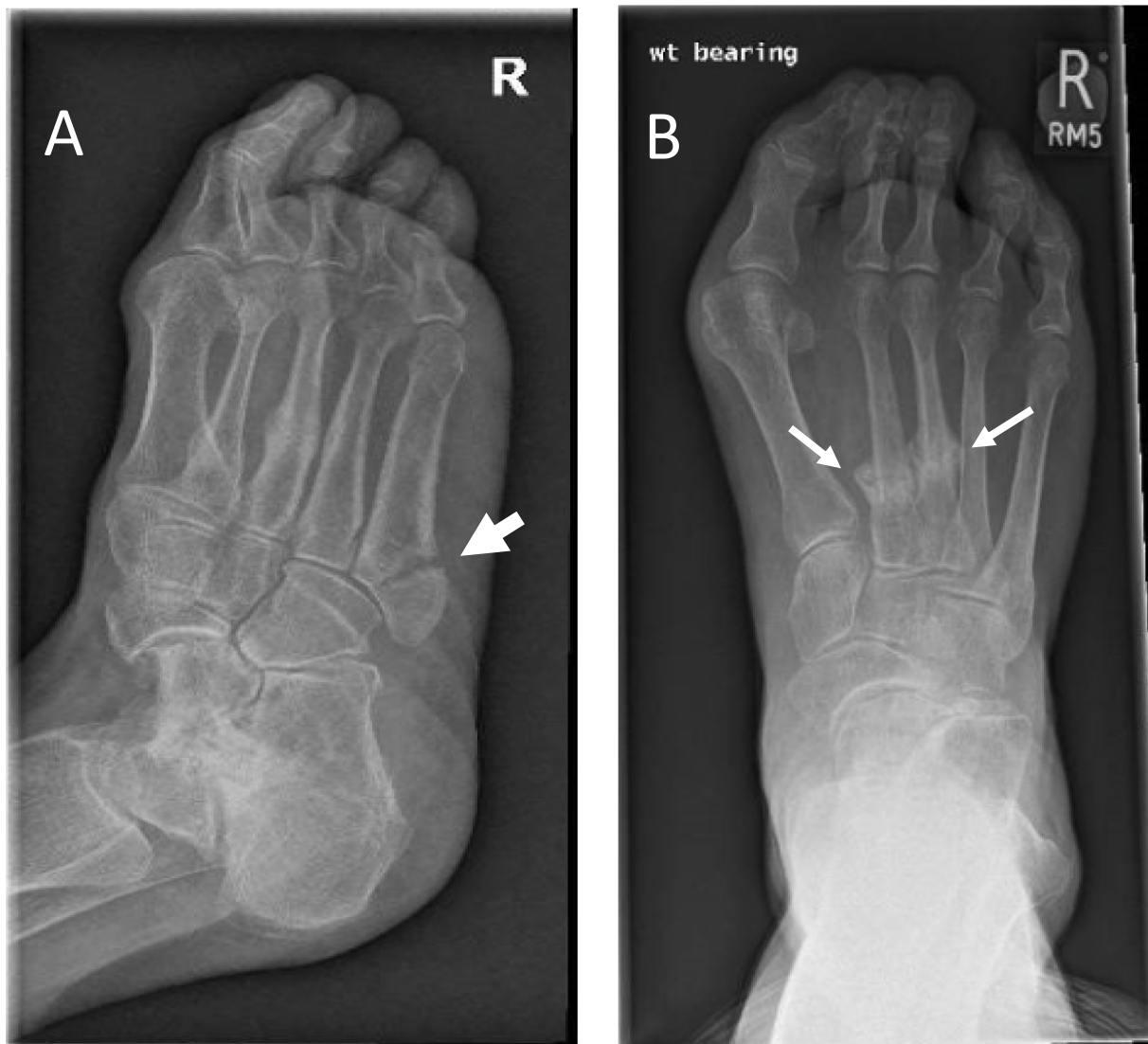

Fig. 2. Case 1. X-rays of right foot showing (A) displaced fracture (arrow) at base of fifth metatarsal and (B) fractures with callus formation (two arrows) in shafts of second and third metatarsals.

articulation, symphysis pubis, both sacroiliac joints, both calcaneal tuberosities and the right first metatarsophalangeal joint.

2.2.2. Treatment and progress

Medication administered by the General Practitioner included calcium and vitamin D and alendronate 70 mg weekly, cocodamol, lansoprazole, naproxen, ascorbic acid, and salbutamol inhaler. Following her referral to the NAC in February 2014, Nitisinone 2 mg oral daily along with dietary protein restriction was started. Partial rupture of the right Achilles tendon followed in November 2014, requiring topical lidocaine plasters. In 2015, F^{18} PET CT scintigraphic scans revealed new uptake at multiple lateral rib sites on both sides of the thoracic cage indicating the development of stress or insufficiency fractures. (Fig. 5). MRI whole spine in 2015 showed an increased in the kyphosis however no discernible change related to the known chronic vertebral fractures. In addition, endplate uptake at multiple vertebral levels on the F^{18} PET CT scintigraphic scan persisted on 2015 and 2016 studies. Patient developed back pain driving her car over a pothole in the road in 2017 and again in 2018.

Teriparatide 20 μ g subcutaneous daily self-injection replaced alendronate in January 2018. Additional investigations at this stage showed: Blood tests (reference range in brackets) – 25-

hydroxycholecalciferol 60 nmol/l (>75); sodium 142 mmol/l (133–146), potassium 4.5 mmol/l (3.5–5.3), chloride 102 mmol/l (95–108), bicarbonate 26 mmol/l (22–29), urea 6.2 mmol/l (2.5–7.8), creatinine 61 μ mol/l (50–130), eGFR 84 ml/min (>60), anion gap 19 (6–16), adjusted calcium 2.37 mmol/l (2.2–2.6), phosphate 1.01 mmol/l (0.8–1.5), total protein 66 g/l (60–80), albumin 43 g/l (35–50), globulin 23, ESR 2 mm/h (<20), haemoglobin 120 g/l (118–148), haematocrit 0.359 (0.39–0.44), white blood count 8.7×10^9 (3.5–11), and platelets 199×10^9 (150–400). Her metabolic data are shown in Table 1. Her bone mineral density studies are shown in Table 1. A two-year course of teriparatide concluded in January 2020 with denosumab 60 mg subcutaneous injections twice a year to follow. No further fractures have occurred since then.

3. Discussion

Two patients with advanced AKU are presented in this report characterised by osteoporosis and fractures. Both patients had experienced numerous musculoskeletal events associated with AKU. Fig. 1 shows pigmentation in the sclera of the eyes and the ears in both patients. Case 1 had more ochronotic pigmentation in the sclera and the ear and had more fractures. Ochronosis can lead to a reduction in bone mass by

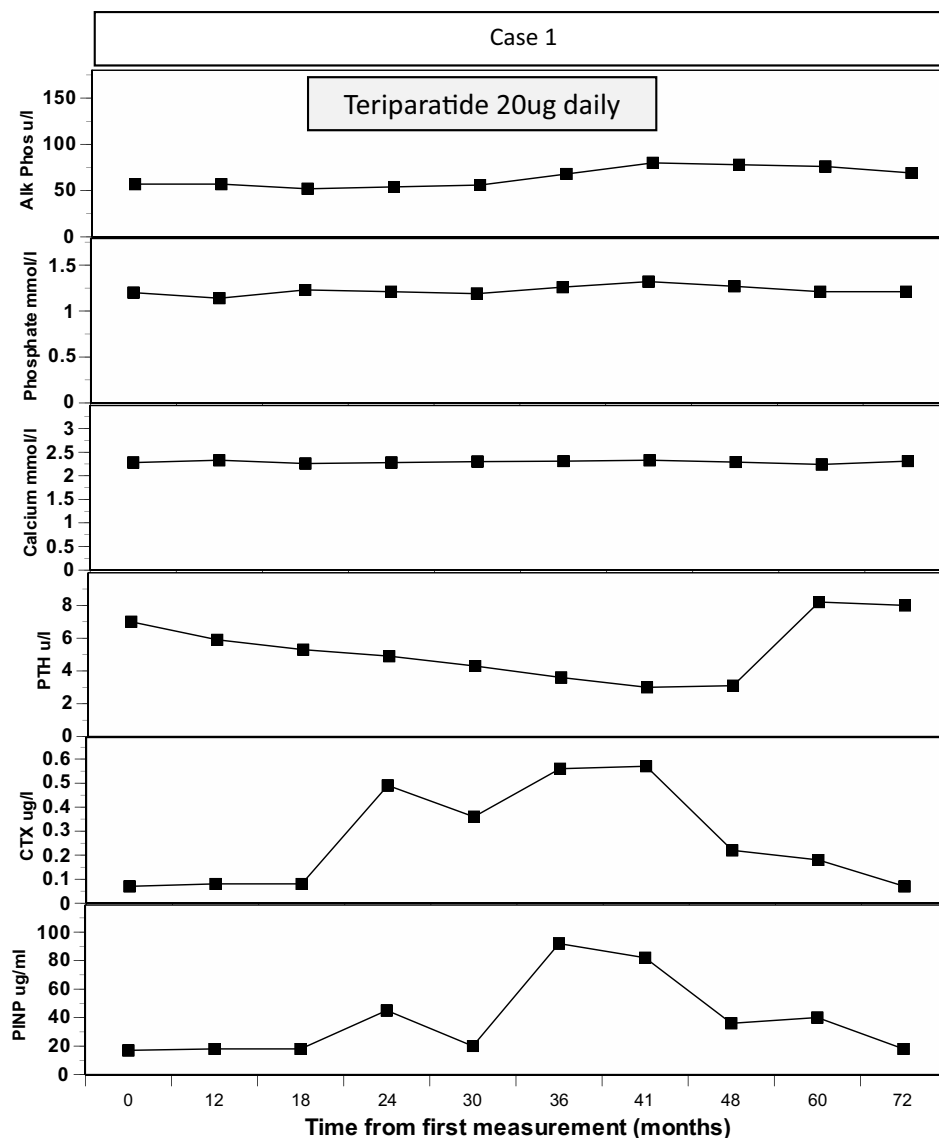


Fig. 3. Case 1: data on alkaline phosphatase, phosphate, adjusted calcium, intact PTH, CTX and PINP.

altering the mechanical loading on the skeleton focally but there are systemic effects too.

Osteoporosis, a systemic disease, is common and characterised by low bone mass and structural deterioration of bone tissue, with an increase in bone fragility and predisposition to fracture. The causes for osteoporosis are innumerable and commoner ones include menopause, male hypogonadism, corticosteroid, and ageing. Osteoporosis and fragility fractures in the two cases presented in this report occurred in the presence of advanced ochronosis in AKU, which might therefore be considered a major cause. However, the coincidental co-existence of a common condition such as osteoporosis in a rare disease cannot be excluded. Secondary causes of osteoporosis were excluded in both patients and both were proven to be calcium and vitamin D replete. The two women presented here had history of previous oestrogen replacement therapy. Case 2 experienced premature surgical menopause, and having received oestrogen replacement only five years, probably had more oestrogen-deprived lifetime years as a contributory factor in her osteoporosis and fractures. Case 1 had an apparently low normal BMI of 20.1 kg/m² despite significant loss of height masking her true values, and therefore could be considered as having slender habitus. She had always partaken high-intensity exercise, which could be additional factors in the cause of her fractures. The data in Table 1 shows markedly

increased urine HGA daily excretion (uHGA₂₄), as well as increased serum HGA (sHGA) in both case 1 and 2, much more in Case 1 than in Case 2. These data are consistent with an important role for HGA in osteoporosis. Following nitisinone treatment, there was a 99.1 and 96% decrease in uHGA₂₄ and sHGA in Case 1 respectively, while it was 99.1 and 81.1% respectively in Case 2. There was a suggestion of improvement in vertebral BMD in Case 1 but a deterioration in Case 2 following nitisinone, although overall in these two patients nitisinone therapy alone did not prevent further fractures.

Reliable recognition of osteoporosis is needed for prompt treatment to prevent fractures. According to the WHO criteria, osteoporosis is defined as a BMD that lies 2.5 standard deviations or more below the average value for young healthy women (a T-score of < -2.5 SD), usually based on DEXA measurements (Shuster et al., 2008; Siris et al., 2014). The standard DEXA measurement assumes that readings are generated from bone mineral, commonly the proximal hip bone or vertebrae L2–L4, with associated soft tissue or intervertebral discs not contributing to the signal. AKU is a condition where extensive calcification and ossification of the spine accompanies spondylosis and can produce misleading DEXA spinal data as has been previously noted (Klingberg et al., 2012). This why CT BMD was used in the two patients presented in this report, and it is apparent that the DEXA spinal BMD

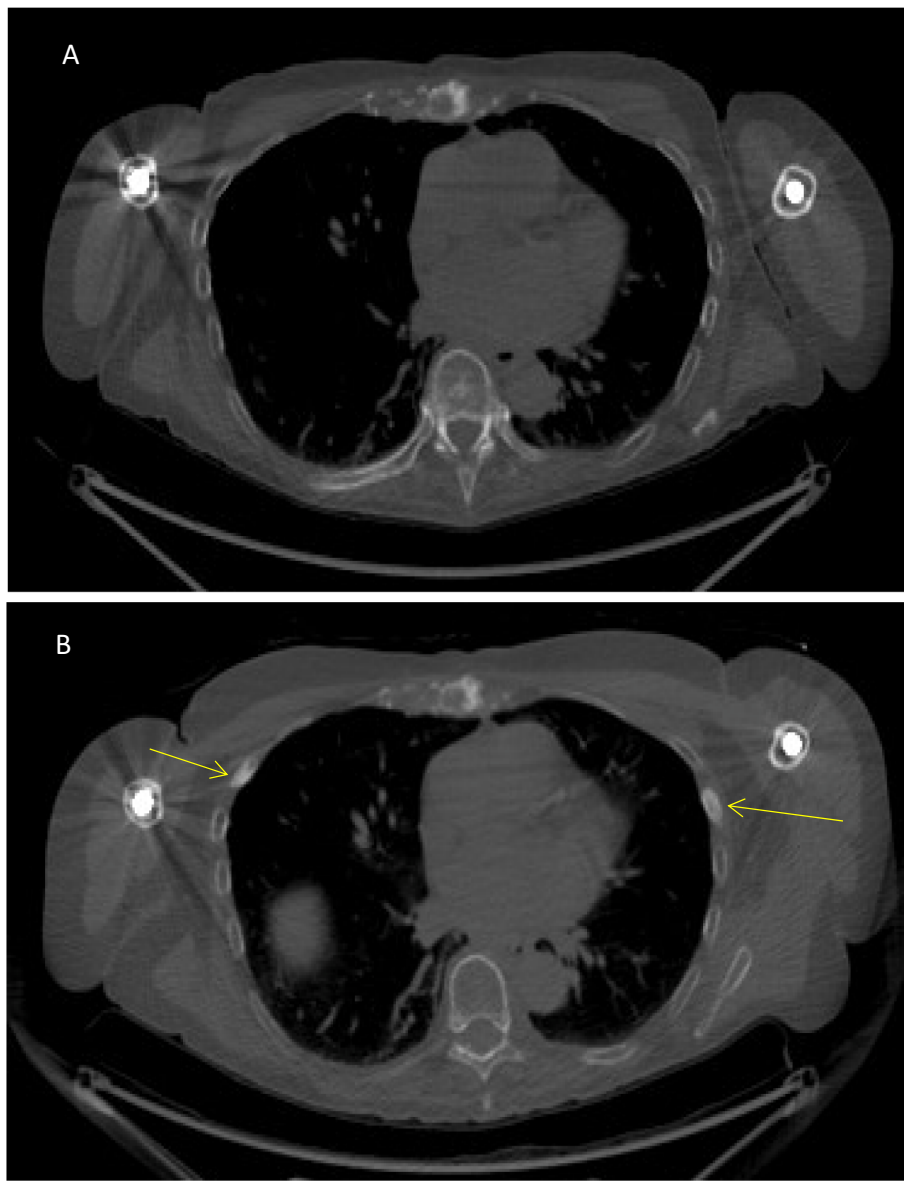


Fig. 4. Case 2: (A) CT component of F18 PET CT 2014 and (B) CT component of F18 PET CT 2015, equivalent slice. Arrows indicate sclerotic reaction related to bilateral rib stress/insufficiency fractures.

Case 2: (C) maximum intensity projection (MIP) component of F18 PET CT 2014 and (D) Maximum intensity projection (MIP) component of F18 PET CT 2015, arrows indicate multiple sites of uptake at the lateral aspects of ribs on both sides consistent with stress or insufficiency fractures.

Case 2: (E) MRI 2014 sagittal view and, (F) MRI 2016 sagittal view showing the mild increase in kyphosis of upper and mid thoracic spine. Both show no change of the chronic grade 1 insufficiency fracture of T6, T7, T8, T9 and L4.

differs from the CT BMD; DEXA and CT BMD measurements in the hip were comparable. CT BMD in Case 2 predicted vertebral fracture but not DEXA BMD. In our experience, standard DEXA BMD should not be used to characterise bone mineral density in AKU at the spine, as it will underestimate the degree of vertebral osteopenia compromising treatment decisions; it is possible that hip or wrist BMD T-scores are more reliable to predict fracture risk in AKU if DEXA is used.

This difficulty in diagnosis of osteoporosis in AKU mirrors the situation in ankylosing spondylitis (AS) and diffuse interosseous skeletal hyperostosis (DISH), both of which show analogous spinal calcification and fusion (Klingberg et al., 2012; Nascimento et al., 2014; Diederichs et al., 2011). Osteoporosis complicates both AS and DISH and when fracture occur, are more likely to result in unstable significant 3 column spinal fractures with potential to compromise spinal cord function and frequently require surgical intervention, unlike insufficiency fractures of

non-fused spines; therefore, accurate measurement of BMD is problematic in these three conditions for diagnosis and treatment. Despite the ankylosis of AKU being similar to these fusion syndromes, displaced fractures compromising spinal cord have not been described in AKU to our knowledge.

The mechanism of osteopenia in long bones has been attributed to ochronosis in cartilage in AKU (Aliberti et al., 2007). Careful *ex vivo* study of a hip following total replacement in an AKU patient showed severe juxta-articular loss of bone, as well as marked activation of osteoclasts (Taylor et al., 2011, this was attributed to the stress shielding of the overlying hardened articular cartilage (Gallagher et al., 2016). This process could explain the juxta-articular osteopenia seen in AKU joints, where collapse of the joint can occur (Shimizu et al., 2007).

The mechanism of vertebral osteopenia in AKU is not well understood. Immobility of the spine due to spinal fusion, present in both Case

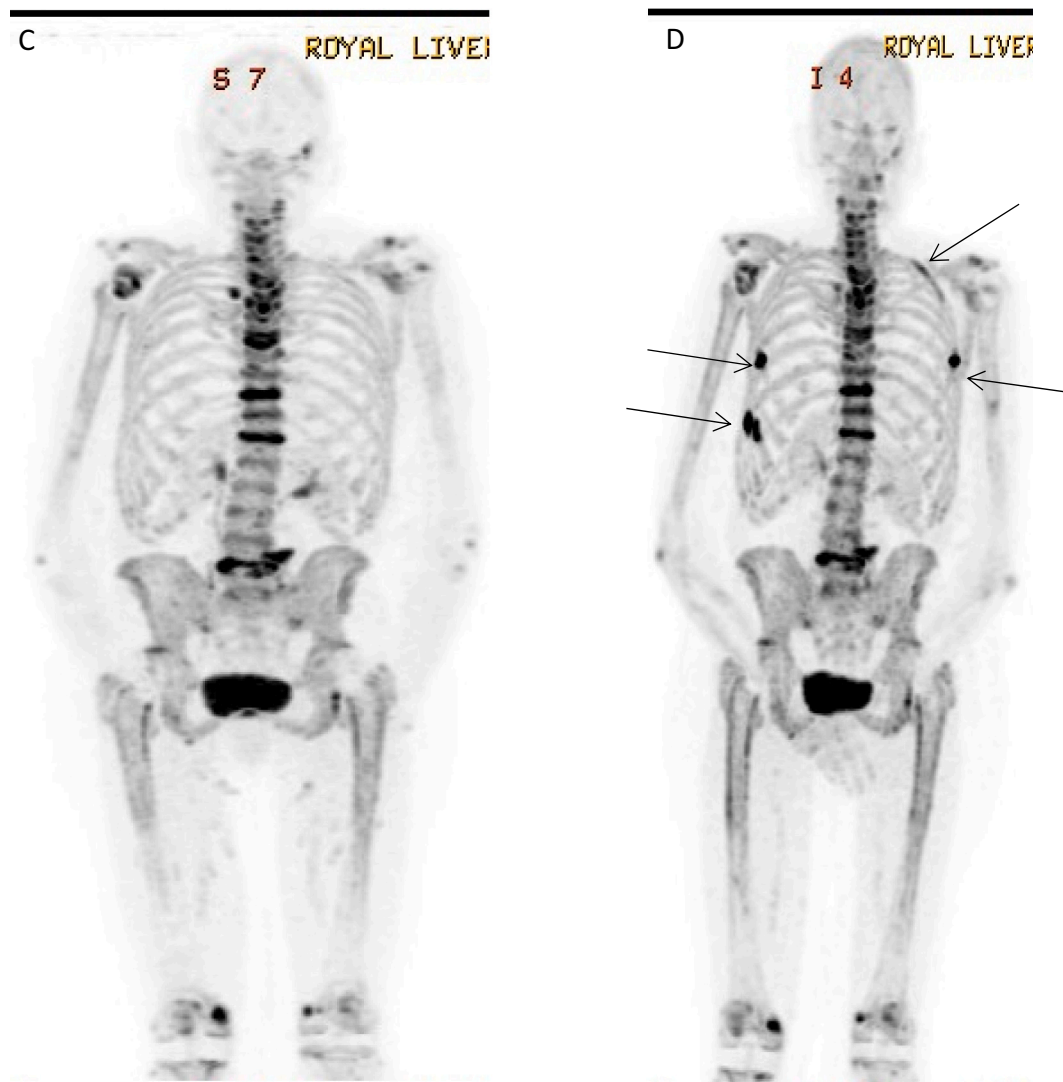


Fig. 4. (continued).

1 and 2 likely contributed to bone loss. It is not known if the hardened calcified ochronotic intervertebral discs and ochronosis in the adjacent articular cartilage in the vertebrae, could similarly cause stress shielding and bone loss. It is surprising vertebral fractures are not more common in AKU where ochronotic spine is universally seen in all patients. It could be hypothesised that the calcified ‘cage’ around the vertebral bodies offers protection.

Fractures recurred in our two patients despite bisphosphonate therapy, raising questions of compliance, especially in Case 2 who was on oral alendronate. As mentioned earlier secondary causes of osteoporosis were excluded in both patients. Carboxy-terminal cross-linked telopeptide of type 1 collagen (CTX), a marker of bone resorption, and procollagen type 1 amino-peptide propeptide (PINP), a formation marker were measured serially in serum in both cases in line with the recommendations of the Bone Marker Working Group (Wheater et al., 2013; Vasikaran et al., 2011). Plasma CTX and PINP were suppressed in Case 1 at presentation due to already having started intravenous zoledronate. In Case 2 the low normal plasma CTX and PINP is consistent with a slower bisphosphonate effect on oral alendronate (Figs. 2, 3). Increased bone turnover remains coupled in untreated AKU patients and has been previously described by others (Phornphutkul et al., 2002; Aliberti et al., 2003). The increased bone turnover in AKU justifies the use of anti-resorptive drugs as the first line, as in our two patients. However, both patients suffered further fractures despite bisphosphonate treatment,

similar to previous experience (Wu et al., 2019).

Another approved therapy in osteoporosis, which is anabolic rather than anti-resorptive, is parathyroid hormone administration (Neer et al., 2001). PTH has long been known to have a direct effect on proliferation of osteoblasts (MacDonald et al., 1986) and more recently has been shown to promote bone formation by inhibiting the production of sclerostin and permitting the anabolic action of the Wnt pathway (reviewed in Silva and Bilezikian, 2015). Teriparatide (PTH 1-34) has been approved to treat post-menopausal women with osteoporosis, men with hypogonadal or idiopathic osteoporosis, and men and women with glucocorticoid-induced osteoporosis who are at high risk for fracture (Lindsay et al., 1997). Teriparatide has been used “off-label” for the management of fractures and non-unions (Babu et al., 2015) although other reports and a meta analysis suggest it is not effective (Zhongju et al., 2016). Teriparatide has been used previously in bisphosphonate-resistant osteoporotic fracture of AKU and showed anti-fracture efficacy 22 months after completion of the course (Millea et al., 1992).

In the two cases described in this report, teriparatide therapy was well tolerated. There was an increase in alkaline phosphatase, PINP and CTX in Case 1 and 2 following teriparatide consistent with a coupled bone turnover exhibiting a successful initial bone formation, more robust in Case 2 who did not receive intravenous zoledronate, followed by subsequent concurrent bone formation and resorption (Figs. 2, 3). The CT-BMD response was positive and improved in the vertebrae in

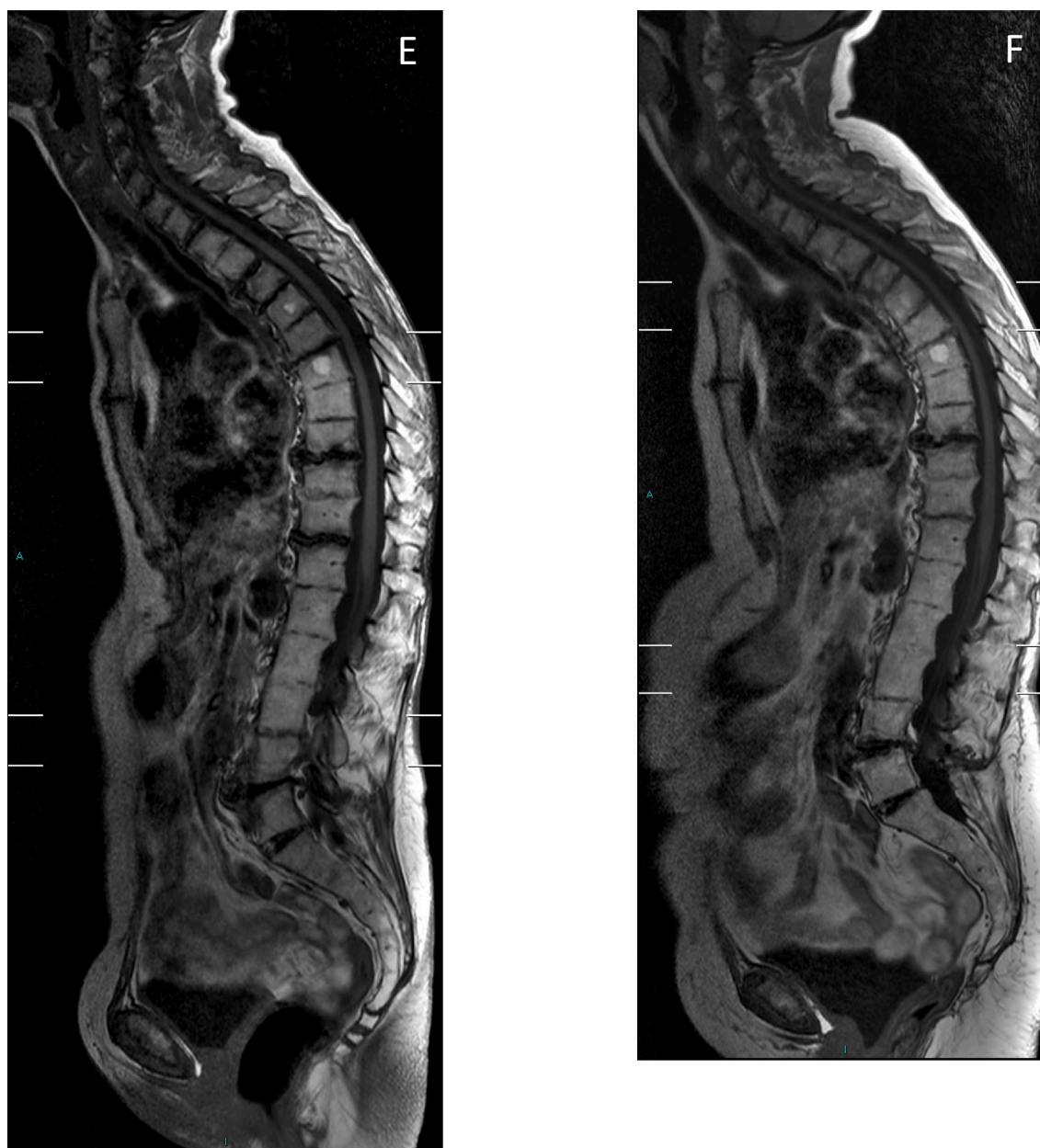


Fig. 4. (continued).

both Case 1 and 2 (Table 1). Most importantly both patients stopped fracturing during and after completion of the two-year course of teriparatide. Both were eucalcaemic during their teriparatide treatment. Both patients also showed a convincing decrease in endogenous PTH secretion, starting soon after teriparatide therapy and returning to baseline after completion of treatment, similar to the findings reported previously and suggesting good compliance with daily teriparatide self-injection therapy (Figs. 2, 3) (Anastasilakis et al., 2008).

We carefully considered whether it was safe for these two patients to commence teriparatide therapy since previous experience in AKU was extremely limited (Millea et al., 1992). PTH has been associated with unwanted calcification in several sites and in many studies (Iwata et al., 2012; Koh et al., 1996; Orwoll et al., 1981; Sturdee and Bollen, 2004). There was concern that PTH therapy could lead to complication such as calcification of the spine and worsen functionality of the spine. The spondylosis in AKU resembles ankylosing spondylitis and therefore we used Bath indices to assess the spines (Garrett et al., 1994). The Bath indices in Table 1 show stable scores if not an improvement in both Case

1 and 2, suggesting that teriparatide therapy did not worsen the spinal disease. The other concern was an adverse effect on cardiac calcification since a previous report described cardiac calcification with primary hyperparathyroidism (Iwata et al., 2012); both patients had normal functioning but ochronotic aortic and mitral valves with Case 2 also displaying mitral calcification. Serial echocardiograms however show no deterioration following teriparatide therapy in valve function or imaging in both cases. Of interest teriparatide has been used to very effectively to treat spinal osteoporosis and fractures in AS and DISH (Fattah et al., 2014; Iida et al., 2013). In summary, we present two cases of AKU complicated by osteoporosis and fractures, resistant to bisphosphonate therapy. The difficulties in accurately characterising the bone mineral density to correctly diagnose osteoporosis are demonstrated in these two cases. Despite reported finding that osteoclastic activity and resorption are up-regulated in AKU (Brunetti et al., 2018; Taylor et al., 2011) both these patients continued to fracture following initiation of anti-resorptive bisphosphonates therapy. The occurrence of fractures ceased soon after starting teriparatide therapy and continues

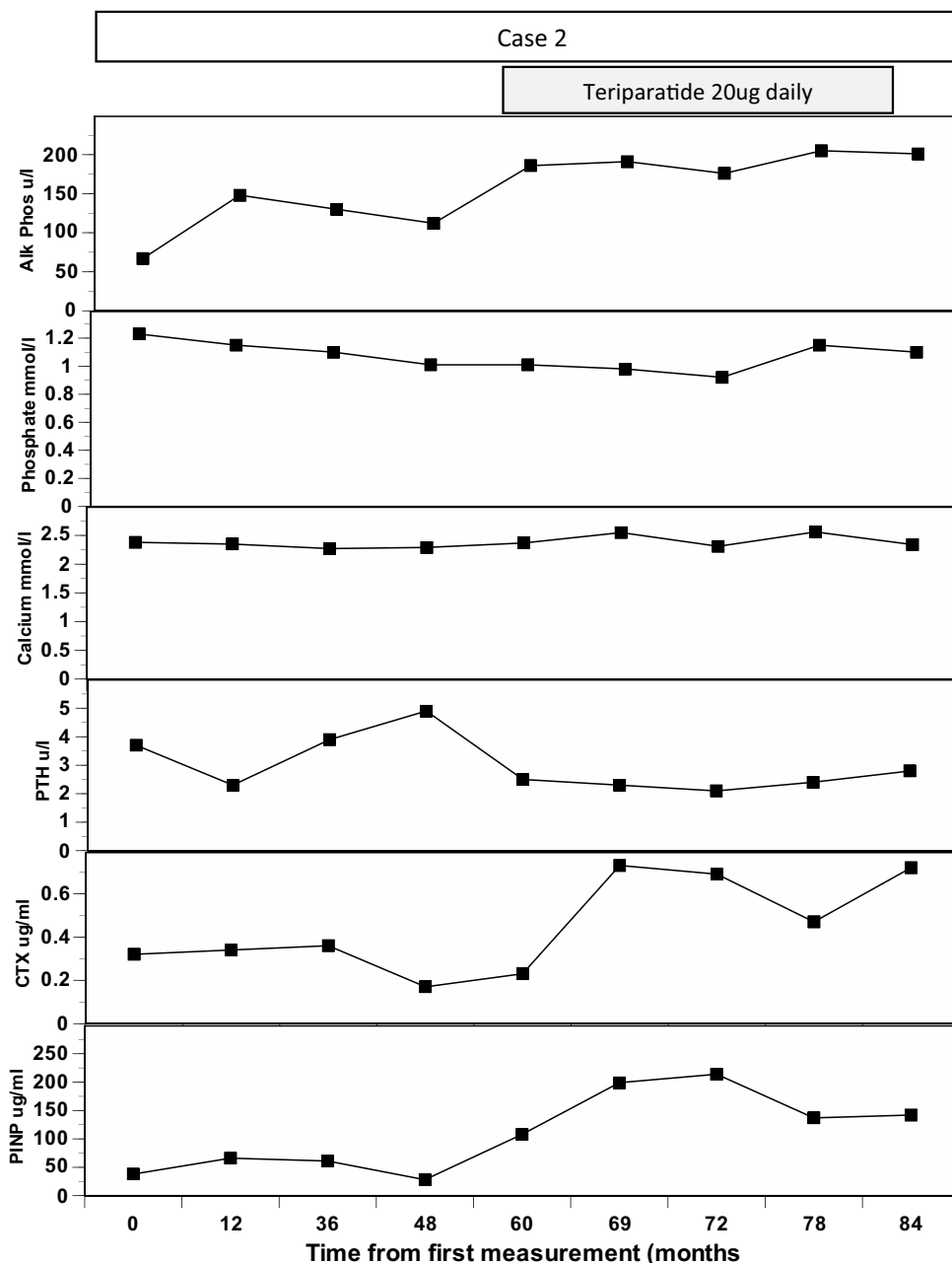


Fig. 5. Case 2: data on alkaline phosphatase, phosphate, adjusted calcium, intact PTH, CTX and PINP.

beyond completion. Stimulation of osteoblastic activity by teriparatide therapy is safe and efficacious and an important adjunct in managing osteoporotic fractures in AKU, especially when anti-resorptive therapy is not successful.

Contributors

All authors contributed to analysis of the data, edited the manuscript and approved the final version.

Funding

This work was supported by funding granted in April 2012 by the NHS England Highly Specialized Services in establishing the UK National Alkaptonuria Centre in the Royal Liverpool University Hospital. The funding source was not involved in the study design, collection, analysis and interpretation of data, the writing of the manuscript, or in

the decision to submit the manuscript for publication. The authors confirm independence from the funders; the content of the article has not been influenced by the funders.

Ethics approval

The data collected from the NAC was approved by the Institutional Audit Committee (Audit No: ACO3836). Data from the NAC has been published previously (see references provided underneath).

Data sharing statement

The authors agree to honour any reasonable request by other researchers for materials, methods or data necessary to verify the conclusion of the article.

Declaration of competing interest

None.

References

- Aliberti, G., et al., 2003. Bone metabolism in ochronotic patients. *J. Intern. Med.* 254, 296–300.
- Aliberti, G., et al., 2007. Bisphosphonate treatment in ochronotic osteoporotic patients. *Clin. Rheumatol.* 26, 729–735.
- Anastasilakis, A.D., et al., 2008. Endogenous intact PTH is suppressed during teriparatide (rhPTH 1–34) administration in postmenopausal women with established osteoporosis. *Endocrinol. J.* 55, 613–616.
- Babu, Satish, Sandiford, Nemandra A., Vrahas, Mark, 2015. Use of teriparatide to improve fracture healing: what is the evidence? *World J Orthop.* 6, 457–46129.
- Brunetti, G., Tummolo, A., D'Amato, G., Gaeta, A., Ortolani, F., Piacente, L., Giordano, P., Colucci, S., Grano, M., Papadia, F., Faienza, M.F., 2018. Mechanisms of enhanced osteoclastogenesis in Alkaptonuria. *Am J Pathol* 188, 1059–1068.
- Cox, T.F., Ranganath, L.R., 2011. A quantitative assessment of alkaptonuria: testing the reliability of two disease severity scoring systems. *J. Inherit. Metab. Dis.* 34, 1153–1162.
- Diederichs, G., Engelken, F., Marshall, L.M., et al., 2011. Diffuse idiopathic skeletal hyperostosis (DISH): relation to vertebral fractures and bone density. *Osteoporos. Int.* 22, 1789–1797.
- Fattah, Z., et al., 2014. Complete healing of traumatic multiple spinal fractures in a patient with ankylosing spondylitis who refused surgical intervention with teriparatide. *Rheumatology* 53, i66.
- Gallagher, J.A., Ranganath, L.R., Boyde, A., 2016. What does the arthropathy of alkaptonuria teach us about disease mechanisms in osteoarthritis and ageing of joints? *Rheumatology* 55, 1151–1152.
- Garrett, S., et al., 1994. A new approach to defining disease status in ankylosing spondylitis: the Bath ankylosing spondylitis disease activity index. *J. Rheumatol.* 21, 2286–2291.
- Iida, Y., et al., 2013. Successful treatment of spine fracture for diffuse idiopathic skeletal hyperostosis with teriparatide - a report of two cases. *Open J. Orthop.* 3, 278–282.
- Iwata, S., et al., 2012. Aortic valve calcification in mild primary hyperparathyroidism. *J. Clin. Endocrinol. Metab.* 97, 132–137.
- Klingberg, E., et al., 2012. Osteoporosis in ankylosing spondylitis prevalence, risk factors and methods of assessment. *Arthritis Res. Ther.* 14, R108–R120.
- Koh, E., et al., 1996. Hyperparathyroidism as a cause of calcification of the abdominal aorta in elderly female subjects. *J. Bone Miner. Metab.* 14, 35–38.
- La Du, B.N., et al., 1958. The nature of the defect in tyrosine metabolism in alkaptonuria. *J. Biol. Chem.* 230, 251–260.
- Lindsay, R., et al., 1997. Randomised controlled study of effect of parathyroid hormone on vertebral-bone mass and fracture incidence among postmenopausal women on oestrogen with osteoporosis. *Lancet* 350, 550–555.
- MacDonald, B.R., Gallagher, J.A., Russell, R.G., 1986. Parathyroid hormone stimulates the proliferation of cells derived from human bone. *Endocrinology* 118 (6), 2445–2449.
- Millea, T.P., et al., 1992. Spine fracture in ochronosis. Report of a case. *Clin. Orthop. Relat. Res.* 281, 208–211.
- Nascimento, F.A., et al., 2014. Diffuse idiopathic skeletal hyperostosis: a review. *SNISpine* 5, S122–S125.
- Neer, R.M., et al., 2001. Effect of parathyroid hormone (1–34) on fractures and bone mineral density in postmenopausal women with osteoporosis. *N. Engl. J. Med.* 344, 1434–1441.
- O'Brien, W.M., La Du, B.N., Bunim, J.J., 1963. Biochemical, pathologic and clinical aspects of alcaptonuria, ochronosis and ochronotic arthropathy: review of world literature (1584–1962). *Am J Med.* 34, 813–838.
- Orwoll, E.S., Margolin, D.L., Hammerstad, J.P., 1981. Hyperparathyroidism and intracerebral calcification. *Miner. Electrolyte Metab.* 5, 273–279.
- Paniagua, I.C., et al., 2015. *Reumatol Clin.* 11, 330–331.
- Phornphutkul, C., et al., 2002. Natural history of alkaptonuria. *N. Engl. J. Med.* 347, 2111–2121.
- Ranganath, L.R., Cox, T.F., 2011. Natural history of Alkaptonuria revisited: analysis based on scoring systems. *J Inherit Metab Dis.* 34, 1141–1151.
- Ranganath, L.R., Norman, B.P., Gallagher, J.A., 2019. Ochronotic pigmentation is caused by homogentisic acid and is the key event in alkaptonuria leading to the destructive consequences of the disease – a review. *J. Inherit. Metab. Dis.* 42, 776–792.
- Ranganath, L.R., Psarelli, E.E., Arnoux, J.B., et al., 2020 Sep. Efficacy and safety of once-daily nitisinone for patients with alkaptonuria (SONIA 2): an international, multicentre, open label, randomised controlled trial. *Lancet Diabetes Endocrinol.* 8 (9), 762–772.
- Ranganath, L.R., Khedr, M., Vinjamuri, S., Gallagher, J.A., 2021 May. Frequency, Diagnosis, Pathogenesis and Management of Osteoporosis in Alkaptonuria: Data Analysis From the UK National Alkaptonuria Centre, 32 (5), 927–938.
- Shimizu, Ichiro, Hamada, Tetsuo, Khalpey, Zain, Miyaniishi, Keita, Hara, Toshihiko, 2007. Ochronotic arthropathy: pathological evidence of acute destruction of the hip joint. *Clinical Rheumatology* 26, 1189–1191.
- Shuster, L.T., Gostout, B.S., Grossardt, B.R., Rocca, W.A., 2008. Prophylactic oophorectomy in pre-menopausal women and long-term health - a review. *Menopause Int.* 14, 111–116.
- Silva, B.C., Bilezikian, J.P., 2015. Parathyroid hormone: anabolic and catabolic actions on the skeleton. *Curr. Opin. Pharmacol.* 22, 41–50.
- Siris, E.S., Adler, R., Bilezikian, J., et al., 2014. The clinical diagnosis of osteoporosis: a position statement from the National Bone Health Alliance Working Group. *Osteoporos. Int.* 25, 1439–1443.
- Sturdee, S.W., Bollen, S.R., 2004. Intra-articular calcification in primary hyperparathyroidism. *Knee* 11, 323–325.
- Taylor, A.M., Boyde, A., Davidson, J.S., Jarvis, J.C., Ranganath, L.R., Gallagher, J.A., 2012. Identification of trabecular excrescences, novel microanatomical structures, present in bone in osteoarthropathies. *Eur Cell Mater.* 21 (23), 300–308 discussion 308-9.
- Taylor, A.M., et al., 2011. The role of calcified cartilage and subchondral bone in the initiation and progression of ochronotic arthropathy in alkaptonuria. *Arthritis Rheum.* 63, 3887–3896.
- Vasikaran, S., et al., 2011. Markers of bone turnover for the prediction of fracture risk and monitoring of osteoporosis treatments: a need for international reference standards. *Osteoporos. Int.* 22, 391–420.
- Wheater, G., et al., 2013. The clinical utility of bone marker measurements in osteoporosis. *Journal of Translational Medicine* 11, 201–215.
- Wu, K., Bauer, E., Myung, G., Fang, M.A., 2019. Musculoskeletal manifestations of alkaptonuria: a case report and literature review. *Eur. J. Rheumatol.* 6, 98–101.
- Zacharia, B., et al., 2009. Black hip, fracture neck of femur and scoliosis: a case of ochronosis. *J. Inherit. Metab. Dis.* 32, S215–S220.
- Zannoni, V.G., Lomtevas, N., Goldfinger, S., 1969. Oxidation of homogentisic acid to ochronotic pigment in connective tissue. *Biochim. Biophys. Acta* 177, 94–105.
- Zhongju, S., et al., 2016. Effectiveness of teriparatide on fracture healing: a systematic review and meta-analysis. *PLoS One* 11 (12), e0168691, 20.