

## A Case Report of Pediatric Brucellosis in an Algerian Immigrant

Eimear Kitt,<sup>1</sup> Kristina R. Brannock,<sup>2,3</sup> Lauren A. VonHolz,<sup>1</sup> Paul J. Planet,<sup>1,3,4</sup> Erin Graf,<sup>1,2,3</sup> and Vinodh Pillai<sup>2,3</sup>

<sup>1</sup>Division of Infectious Diseases and <sup>2</sup>Department of Pathology and Laboratory Medicine, Children's Hospital of Philadelphia, Pennsylvania; <sup>3</sup>University of Pennsylvania, Philadelphia; <sup>4</sup>Sackler Institute for Comparative Genomics, American Museum of Natural History, New York

An 8-year old girl presented to our facility with a 10-day history of fever, fatigue, abdominal pain and refusal to walk. She recently travelled from her native Algeria where she first developed symptoms. On evaluation, she was ill-appearing, febrile and tachycardic with hepatosplenomegaly and lymphadenopathy noted on examination. A strong musty odor was also noted from the child. Laboratory evaluation revealed pancytopenia, hyponatremia, and an elevated AST, ALT, and LDH. Malaria testing was negative, as was a PPD. On further questioning, the family reported multiple sick contacts in Algeria with similar symptoms. After discussion with Oncology and Infectious Diseases, she underwent a bone marrow biopsy that was significant for multiple non-caseating ring granulomas. She was started on combination therapy of doxycycline and for presumed brucellosis infection with improvement in her symptoms and resolution of fever. Bone marrow culture returned several days later positive for *Brucella melitensis*.

**Keywords.** Algeria; *Brucella melitensis*; Maghreb; ring granuloma.

### CASE

A previously healthy 8-year-old Algerian immigrant presented with 10 days of fever, fatigue, weight loss, abdominal pain, and refusal to walk. She first developed daily tactile temperatures and marked anergia. Anorexia then followed, with 3 kg weight loss and diffuse abdominal pain. She refused to leave her bed because of fatigue and right leg pain. Her parents noted a strong musty odor from the child. A physician in Algeria had prescribed flubendazole and recommended a series of tests, which were not completed. After receiving a dose of flubendazole, she traveled to the United States.

Received 10 August 2016; editorial decision 12 December 2016; accepted 19 December 2016.  
Correspondence: P. Planet, MD, PhD, Division of Infectious Diseases, Children's Hospital of Philadelphia, 34th and Civic Center Blvd, Philadelphia, PA 19104 (planetp@email.chop.edu).

### Open Forum Infectious Diseases®

© The Author 2017. Published by Oxford University Press on behalf of Infectious Diseases Society of America. This is an Open Access article distributed under the terms of the Creative Commons Attribution-NonCommercial-NoDerivs licence (<http://creativecommons.org/licenses/by-nc-nd/4.0/>), which permits non-commercial reproduction and distribution of the work, in any medium, provided the original work is not altered or transformed in any way, and that the work is properly cited. For commercial re-use, please contact [journals.permissions@oup.com](mailto:journals.permissions@oup.com)  
DOI: 10.1093/ofid/ofw263

On arrival to our hospital, she was febrile to 39.2°C with tachycardia to the 130s. She appeared tired with hepatosplenomegaly, a systolic murmur, and bilateral cervical, axillary, and inguinal lymphadenopathy. She limped with ambulation without overlying skin findings or joint effusion. A peripheral blood smear showed pancytopenia (white blood cell 2.2 K/ $\mu$ L, hemoglobin 9.1 g/dL, and platelet 59 K/ $\mu$ L) with differential of 58.9% neutrophils, 35.7% lymphocytes, and 4.5% monocytes. Laboratory testing was otherwise significant for hyponatremia (129 mmol/L), aspartate aminotransferase (232  $\mu$ /L), alanine aminotransferase (50  $\mu$ /L), and lactate dehydrogenase (1919  $\mu$ /L). Abdominal ultrasound revealed hepatosplenomegaly without focal lesions.

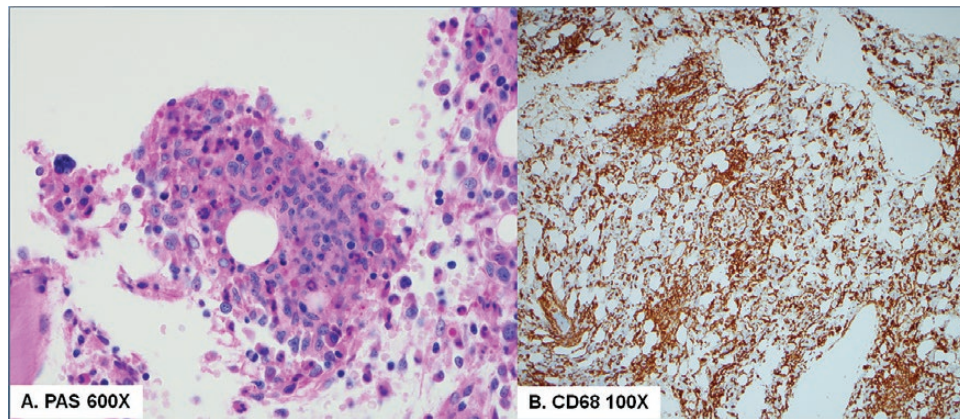
Upon admission, she remained febrile. Initial infectious work up was unrevealing with negative parvovirus serum polymerase chain reaction, negative malaria testing and negative purified protein derivative and human immunodeficiency virus testing. Epstein-Barr virus (EBV) serologies showed evidence of past infection. Blood culture returned without growth. A bone marrow biopsy was performed that was negative for blasts but showed numerous neutrophil-rich ring granulomas comprising 20%–30% of the marrow cellularity (Figure 1). Bone marrow culture returned positive for small Gram-negative coccobacilli at 5 days (Figure 2) and was confirmed several days later as *Brucella melitensis*. *Brucella* antibody titers were strongly positive (1:1280). Doxycycline and rifampin therapy were started with rapid improvement in symptomatology and fever resolution.

### DISCUSSION

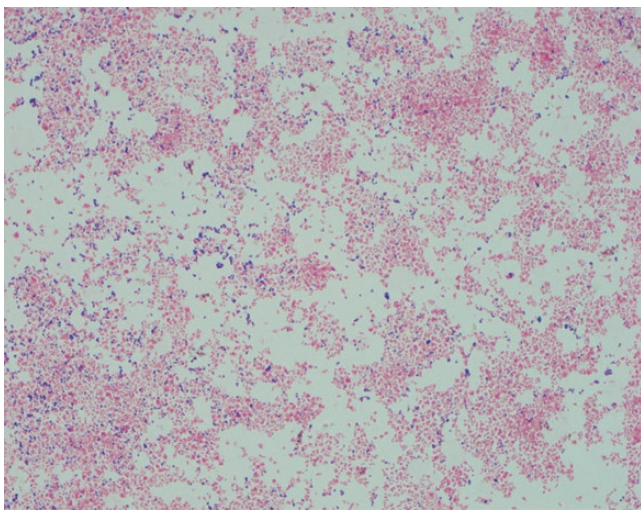
Brucellosis, due to species in the *Brucella* genus, remains endemic in the Mediterranean basin, particularly the Maghreb region of Algeria, Morocco, and Tunisia. Despite attempts at eradication, there remain 500 000 cases annually worldwide, with many going unreported [1]. Since the 1980s, several outbreaks have occurred in the Ghardaia province, most recently in 2016 [2], at the time of our patient's exposure.

*Brucella* species are encapsulated Gram-negative coccobacilli known to affect wild and domestic animals, causing abortion and infertility. *Brucella melitensis* infects mainly sheep and goats and is the major implicated pathogen in human disease. Transmission occurs through ingestion of unpasteurized dairy products, in addition to direct contact with infected animals. Human-to-human transmission through breast milk has been described [3]. In addition, brucellosis is the most common laboratory-acquired infection, accounting for 2% of all infections [4].

Clinical manifestations are nonspecific making the diagnosis a challenge [5–7]. One quarter of cases in endemic regions are diagnosed in children less than 14 years of age [6]. The most common symptoms include fever, night sweats, malaise, joint



**Figure 1.** (A) High-power view of neutrophil-rich ring granulomas in brucellosis. (B) CD163 immunostain for histiocytes highlights extensive infiltration of the marrow by granulomas.



**Figure 2.** The Gram stain from bone marrow culture demonstrated small Gram-negative coccobacilli. This was later confirmed as *Brucella melitensis*.

pain, and weight loss, with hepatosplenomegaly and lymphadenopathy noted on examination [7]. A characteristic musty odor may be described [8]. Osteoarticular manifestations are the most common pediatric complication, frequently involving the hips, knees, ankles, or sacroiliac joint [7, 9, 10]. Neurobrucellosis and cardiac complications have also been described [5, 7].

Isolation of *Brucella* spp from a sterile site such as the blood or bone marrow makes the diagnosis definitive. The rate of isolation from blood varies but is currently estimated to be approximately 50% [11]. Serologic testing may be helpful, with titers greater than or equal to 1:160 indicative of active infection. Titers alone are insufficient to make a diagnosis in endemic areas, given the high prevalence of antibodies in this population [10]. Further supportive criteria include elevated inflammatory markers, increased liver enzymes, and hematologic abnormalities including pancytopenia [6, 7, 9]. Fibrin ring granulomas are uncommon findings in general, but from an infectious standpoint, the differential includes Q

fever (*Coxiella burnetii*), EBV infection, leishmaniasis, histoplasmosis, bartonellosis, and mycobacterial diseases. This finding has also been reported in brucellosis [12].

*Brucella* spp are intracellular pathogens, thus treatment focuses on antimicrobials that penetrate the cell, and full eradication may require prolonged treatment. Regimens involve at least 2 agents, with combinations of (1) trimethoprim-sulfamethoxazole and rifampin and (2) doxycycline and rifampin being common in children [4]. Complicated brucellosis associated with endocarditis, arthritis, or spondylitis usually warrants triple therapy with addition of an aminoglycoside such as streptomycin or gentamicin [13]. Duration is usually a minimum of 6 weeks with relapse rates in children estimated at 4.5% [5, 13].

## CONCLUSIONS

Although brucellosis is a rare disease in the United States and Europe, more cases are being diagnosed, particularly with increased displacement of populations from endemic regions [14, 15]. Providers with a high suspicion of brucellosis based on recent travel and relevant clinical findings should not hesitate to initiate therapy while pursuing a definitive diagnosis for this potentially fatal disease.

## Acknowledgment

**Potential conflicts of interest.** All authors: No reported conflicts.

All authors have submitted the ICMJE Form for Disclosure of Potential Conflicts of Interest. Conflicts that the editors consider relevant to the content of the manuscript have been disclosed.

## References

- Lounes N, Cherfa MA, Le Carrou G, et al. Human brucellosis in Maghreb: existence of a lineage related to socio-historical connections with Europe. *PLoS One* 2014; 9:e115319.
- ProMED-Mail 2016. ProMED-mail. Brucellosis—Algeria (03): (Ghardaia) epidemic. Available at: <http://promedmail.org/direct.php?id=20160422.4174904>. Accessed 19 July 2016.
- Palanduz A, Palanduz S, Güler K, Güler N. Brucellosis in a mother and her young infant: probable transmission by breast milk. *Int J Infect Dis* 2000; 4:55–6.
- Lowe CF, Showler AJ, Perera S, et al. Hospital-associated transmission of *Brucella melitensis* outside the laboratory. *Emerg Infect Dis* 2015; 21:150–2.

5. Uluğ M, Yaman Y, Yapici F, Can-Uluğ N. Clinical and laboratory features, complications and treatment outcome of brucellosis in childhood and review of the literature. *Turk J Pediatr* **2011**; 53:413–24.
6. Bosilkovski M, Krteva L, Caparoska S, et al. Childhood brucellosis: review of 317 cases. *Asian Pac J Trop Med* **2015**; 8:1027–32.
7. Dean AS, Crump L, Greter H, et al. Clinical manifestations of human brucellosis: a systematic review and meta-analysis. *PLoS Negl Trop Dis* **2012**; 6:e1929.
8. Mousa ARM, Elhag KM, Khogali M, Marafie AA. The nature of human brucellosis in Kuwait: study of 379 cases. *Clin Infect Dis* **1988**; 10: 211–17.
9. Akbayram S, Dogan M, Akgun C, et al. An analysis of children with brucellosis associated with pancytopenia. *Pediatr Hematol Oncol* **2011**; 28:203–8.
10. Hizel K, Guzel O, Dizbay M, et al. Age and duration of disease as factors affecting clinical findings and sacroiliitis in brucellosis. *Infection* **2007**; 35:434–7.
11. Çıraklı S, Karlı A, Şensoy G, et al. Evaluation of childhood brucellosis in the central Black Sea region. *Turk J Pediatr* **2015**; 57:123–28.
12. Kvasnicka H, Thiele J. Differentiation of granulomatous lesions in the bone marrow. *Der Pathologe* **2002**; 23:465–471.
13. Alavi SM, Alavi L. Treatment of brucellosis: a systematic review of studies in recent twenty years. *Caspian J Intern Med* **2013**; 4:636–41.
14. Norman FF, Monge-Maillo B, Chamorro-Tojeiro S, et al. Imported brucellosis: a case series and literature review. *Travel Med Infect Dis* **2016**; 14:182–99.
15. Garofolo G, Fasanella A, Di Giannatale E, et al. Cases of human brucellosis in Sweden linked to Middle East and Africa. *BMC Res Notes* **2016**; 9:277.