

# Successful Treatment of Urticarial Vasculitis in a Patient With Systemic Lupus Erythematosus With Rituximab

Samar Alharbi<sup>1,2,3</sup> and Jorge Sanchez-Guerrero<sup>1,2</sup>

<sup>1</sup>Division of Rheumatology, Toronto Western Hospital, University Health Network, Toronto, ON, Canada. <sup>2</sup>Division of Rheumatology, Mount Sinai Hospital, University of Toronto, Toronto, ON, Canada. <sup>3</sup>Department of Medicine, Taibah University, Medina, Saudi Arabia.

Clinical Medicine Insights: Arthritis and Musculoskeletal Disorders  
Volume 13: 1–5  
© The Author(s) 2020  
Article reuse guidelines:  
sagepub.com/journals-permissions  
DOI: 10.1177/1179544120967374



**ABSTRACT:** Urticarial vasculitis is an eruption of erythematous wheals that clinically resemble urticaria but histologically show changes of leukocytoclastic vasculitis. In association with connective tissue disease it is most commonly seen complicating Systemic lupus erythematosus (SLE) and, less often, Sjogren's syndrome. Here, we report a 25-year-old woman who developed SLE in 1998. In May 2013 she presented with urticarial vasculitis; her skin biopsy was consistent with leukocytoclastic vasculitis. She also developed bilateral uveitis. She had most of the clinical and laboratory characteristics of hypocomplementemic urticarial vasculitis syndrome (HUVS) which is difficult to be differentiated from SLE. She was treated with high-dose prednisone, Mycophenolate Mofetil (MMF), colchicine, and Dapsone but failed. We decided to give her Rituximab (RTX), her urticarial vasculitis and uveitis symptoms improved significantly. Unfortunately, later on she presented with severe discoid lupus. We started her on thalidomide and responded well. Our case highlights that Rituximab is a good option for severe refractory urticarial vasculitis and thalidomide is effective in treatment of discoid lupus erythematosus (DLE), and can be used safely in specialist rheumatological practice.

**KEYWORDS:** Systemic lupus erythematosus, urticarial vasculitis, hypocomplementemic urticarial vasculitis, leukocytoclastic vasculitis, rituximab

**RECEIVED:** June 30, 2020. **ACCEPTED:** September 22, 2020.

**TYPE:** Case Report

**FUNDING:** The author(s) received no financial support for the research, authorship, and/or publication of this article.

**DECLARATION OF CONFLICTING INTERESTS:** The author(s) declared no potential conflicts of interest with respect to the research, authorship, and/or publication of this article.

**CORRESPONDING AUTHOR:** Samar Alharbi, Department of Medicine, Taibah University, Zip Code 42312, Additional No. 3779, Medina, Saudi Arabia.  
Email: dr.samar.omar@hotmail.com

## Introduction

Systemic lupus erythematosus (SLE) is a chronic multisystem autoimmune inflammatory disease with dermatologic manifestations in 72% to 85% of cases.<sup>1,2</sup> Urticarial vasculitis in SLE can be difficult to manage and can present in lupus patients while they are in remission in term of major organ involvement, such as lupus nephritis. It also can be associated with angioedema and ocular manifestations such as scleritis, which was seen in our patient. Rituximab can be useful in treating cases of urticarial vasculitis and SLE, but not protective from other cutaneous manifestations such as discoid lupus erythematosus.

## Case Presentation

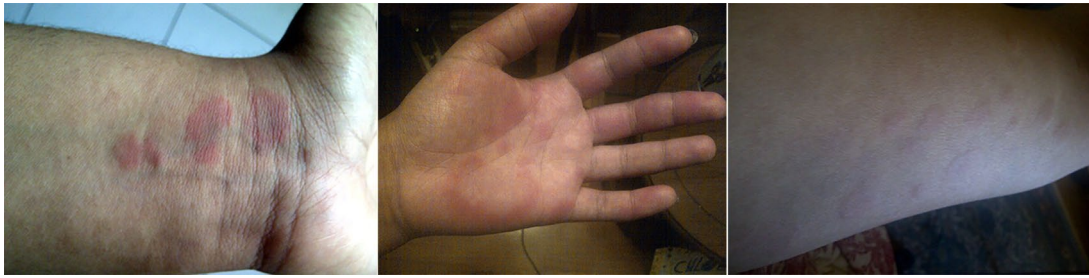A 25-year-old woman diagnosed with SLE in 1998, with initial manifestations including polyarthritides, thrombocytopenia, anemia, class III lupus nephritis that transformed into to class IV in 2001 as well as positive antibodies for ANA, Anti ds-DNA, anti-Sm, and anti-Ro antibodies. In May 2013, while she was on remission of the lupus nephritis, presented with skin lesions over her body predominantly urticarial, non-pruritic (Figure 1), lasting for more than 24 hours, and healing with post-inflammatory hyperpigmentation. She also developed scleritis affected both of her eyes, confirmed by her ophthalmologist. Several months prior to her skin manifestations she had 4 episodes of lip swelling her picture was suggestive of angioedema (Figure 2), not triggered by known medication such as ACE inhibitor. It was mild not associated with difficulty swallowing or labored breathing, transient and subsided

by itself without any intervention. When she was seen and assessed in the clinic, she had no more angioedema symptoms for a while. Otherwise testing the autoantibody to C1 inhibitor (C1-INH) should be considered to roll out acquired C1-INH deficiency in the context of SLE.

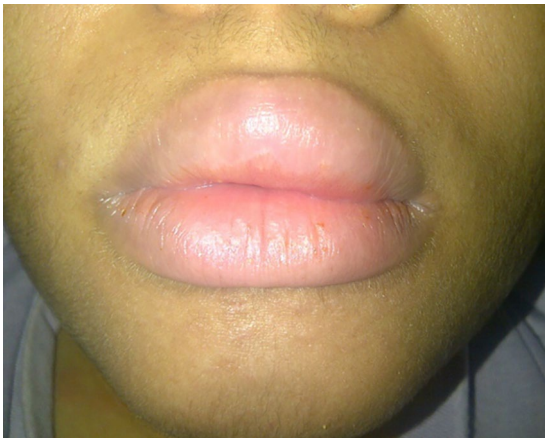
Skin biopsy was consistent with leukocytoclastic vasculitis. Serologically the patient was highly active with Anti ds-DNA(Farr) > 100 U/ml (normal ≤ 7), both C3 and C4 were significantly low 0.45 and 0.04 g/l (normal, 0.9–1.8 and 0.1–0.4, respectively). Unfortunately anti C1q was not done although it's important to be requested in all cases of UV and in my opinion especially for the patients who present with new onset UV as it's helpful in HUVS diagnosis, however it is not specific and have been found in several other rheumatic diseases including SLE.

She was treated with high dose prednisone (60 mg) orally, and her MMF dose increased from 2 to 3 g daily. She was already on HCQ 400 mg daily and started on Colchicine, then Dapsone with poor response. In September 2014, she received Rituximab 1000 mg twice with 2 weeks apart. Her urticarial vasculitis and scleritis symptoms improved gradually. Her prednisone dose tapered gradually. Six weeks later, she presented with severe discoid lupus erythematosus affecting her scalp, around the eyebrows, behind ears, and over nose (Figure 3). She was started on clobetasol lotion and propionate cream with partial response. In spite she was on hydroxychloroquine, oral prednisone and topical treatment in addition to MMF, She had new lesions. In February, we decided starting





**Figure 1.** Urticarial vasculitic skin lesions of forearm, palms, and thigh.



**Figure 2.** Angioedema of lips.

her on Thalidomide. Dermatologist was agreed and followed her with us. Patient was counseled verbally about the need for adequate contraception. Recommended guidelines for the use of thalidomide were employed.

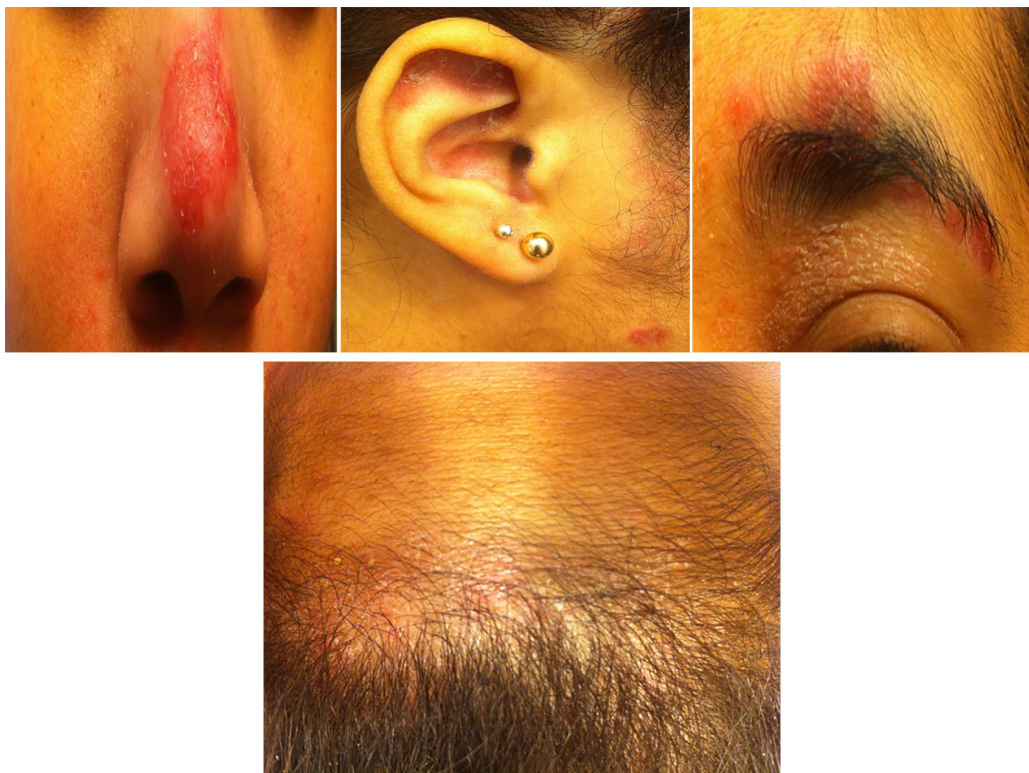She was started on Thalidomide 100 mg PO daily, 2 to 3 weeks later her discoid lesions improved significantly. Unfortunately, In March 2015 the urticarial vasculitis flared more severe than before. Also, the scleritis returned, although with less severity than before. She received rituximab for the second time in April 2015, with similar dosing as the previous treatment, and 3 months later her symptoms improved significantly.

### Outcome and Follow-Up

Thalidomide was tapered down to 50 mg after 3 months from its starting dose and tolerated well with no new lesions and the old lesions healed nicely. Seven months later thalidomide was discontinued. During her treatment course, the patient denied any paresthesias, muscle weakness, gastrointestinal symptoms, or other side effects related to Thalidomide. In September 2015 (5 months after receiving RTX) her serology results showed Anti ds-DNA(Farr) 37U/ml (normal  $\leq 7$ ), both C3 and C4 were 0.89 and 0.08 g/l (normal, 0.9-1.8 and 0.1-0.4, respectively) which indicate improvement. Her lupus serology results before and after RTX treatment are summarized in Table 1. Seven months after receiving rituximab for the second time, the patient was doing well and remained in remission in terms of her urticarial vasculitis and scleritis.

### Discussion

Systemic lupus erythematosus (SLE) is a multisystemic disease that primarily affects women in their reproductive years. Cutaneous vasculitis was found in 19% to 28% in a descriptive analysis of 704 European lupus patients.<sup>3</sup> Drenkard et al observed incident vasculitis in 35.9% during a follow-up period of 10 years. Cutaneous involvement was reported in 82.4%.<sup>4</sup> Another cohort study was conducted in Barcelona by Ramos-Casals et al between 1980 and 2004, with the finding of 11% developing vasculitis. Cutaneous lesions were the main clinical presentation in 89% patients.<sup>5</sup> Urticarial lesions may be the major manifestation of cutaneous vasculitis. It is characterized by recurrent episodes of urticaria with biopsy evidence of leukocytoclastic vasculitis, usually painful and nonpruritic, and typically persists for more than 24 hours, resolves with hyperpigmentation or purpura.<sup>6</sup> Although urticarial vasculitis is frequently idiopathic, it has been reported to be associated with connective tissue diseases such as systemic lupus erythematosus (SLE) and primary Sjogren's syndrome.<sup>7</sup> In general, urticarial vasculitis can be divided into 2 groups, those with normal complement levels and those with hypocomplementemic urticarial vasculitis (HUV).<sup>3,4</sup> The hypocomplementemic form more often is associated with systemic symptoms and has been linked to connective-tissue disease such as SLE.<sup>8-10</sup> Systemic features which could be associated with HUV include constitutional symptoms (fever, malaise, and fatigue), arthralgia, arthritis, ocular symptoms, serositis, glomerulonephritis, interstitial nephritis, and Raynaud's phenomenon.<sup>7</sup> Also patients may have angioedema-like lesions that are present in as many as 40%, frequently involving the lips, tongue, periorbital tissue, and hands.<sup>7</sup> In the absence of well-defined systemic disease, HUV may be considered idiopathic and represent a rare autoimmune disorder also called HUV syndrome (HUVS) or McDuffie syndrome.<sup>11</sup> HUVS is present in 7% to 8% of SLE patients, and 54% of HUVS patients are diagnosed with SLE in follow-up period.<sup>9,12</sup> There is clinical and laboratory overlap between SLE and HUVS which make it the most difficult diagnosis to differentiate especially early in the course of the disease. Co-existence of HUVS and SLE have been reported previously in many cases.<sup>9,10,12</sup> The most common clinical and laboratory features of HUVS and SLE are summarized in Tables 2 and 3. Our patient is known to have SLE since 1998 and while she was in remission from her lupus nephritis and



**Figure 3.** Discoid lupus erythematosus of nose, ear, around eyebrow, and scalp.

**Table 1.** Lupus serology results before and after RTX treatment.

DATE	ANTI DS-DNA(FARR)	C3	C4
May 2013	63	0.72	0.10
July 2013	>100	0.45	0.04
April 2014	81	0.5	0.03
August 2014	100	0.57	0.03
March 2015 (6 mo after receiving RTX first time)	55	0.66	0.07
September 2015 (6 mo after receiving RTX second time)	37	0.89	0.06

Normal values, Anti ds-DNA(Farr), ≤7U/ml, C3 and C4, 0.9-1.8g/l and 0.1-0.4 g/l, respectively.

**Table 2.** Clinical symptoms of hypocomplementemic urticarial vasculitis syndrome compared with systemic lupus erythematosus.

HYPOCOMPLEMENTEMIC URTICARIAL VASCULITIS SYNDROME (HUVS)		SYSTEMIC LUPUS ERYTHEMATOSUS (SLE)	
SYMPTOMS	FREQUENCY (%)	SYMPTOMS	FREQUENCY (%)
Urticaria-like skin lesions (with biopsy-consistent LCV)	100	Urticaria	<10
		Cutaneous symptoms (malar eruption, oral ulcer, photosensitivity)	80
Angioedema	72	Angioedema	<5
Arthralgia and/or arthritis	100	Arthralgia and/or arthritis	95
Chronic obstructive pulmonary disease	65	Restrictive pulmonary disease	24-30
Renal involvement	50	Renal involvement	36-50
Pericardial effusion	17	Pericarditis	30
Eye involvement	61	Eye involvement	15

**Table 3.** Laboratory investigation of hypocomplementemic urticarial vasculitis syndrome compared with systemic lupus erythematosus.

HYPOCOMPLEMENTEMIC URTICARIAL VASCULITIS SYNDROME (HUVS)		SYSTEMIC LUPUS ERYTHEMATOSUS (SLE)	
INVESTIGATION	FREQUENCY (%)	INVESTIGATION	FREQUENCY (%)
Hematologic abnormalities	11	Hematologic abnormalities	85
ANA	61-71	ANA	95
Rheumatoid factor	28	Rheumatoid factor	25-33
dsDNA Ab (transient)	17	dsDNA Ab (transient)	≥70
Anti-SS-A/SS-B Ab	16-17	Anti-SS-A/SS-B Ab	30-45
Anti-C1q autoAb	100	Anti-C1q autoAb	35
Low C1q	100	Hypocomplementemia	22-47
Raised ESR	60-70	Raised ESR	50

Abbreviations: ANA, antinuclear antibodies; Anti-C1q autoAb, autoantibodies to C1q; dsDNA Ab, antibodies to native DNA; ESR, erythrocyte sedimentation rate; Anti-SS-A/SS-B Ab, antibodies to SS-A/SS-B.

her other known lupus features started to have a new onset UV. She had most of the clinical and laboratory characteristics of HUVS which is probably not a separate entity and could be considered as a subtype of SLE.

With regards of urticarial vasculitis treatment response is variable, and a wide variety of therapeutic agents may be efficacious, but with no clinical trials or consensus on an effective therapeutic regimen. Antihistamine or non-steroidal anti-inflammatory drugs (NSAIDs) may provide symptomatic relief.<sup>12</sup> Moderate to high doses of oral steroids (40 mg/day) have been demonstrated as being the most effective treatment. Dapsone, colchicine, and hydroxychloroquine (HCQ) also have been used.<sup>13,14</sup> Other immunosuppressive therapies, including azathioprine, methotrexate, and cyclophosphamide may be considered if lesions are refractory.<sup>15</sup> Rituximab(RTX), which is a chimeric monoclonal antibody that depletes B-cells by binding to the surface molecule CD20 present at all stages of B-cell maturation, with the exception of early B-cell progenitors and plasma cells, may be considered in refractory cases.<sup>8</sup> Our patient presented with a lupus flare in the form of urticarial vasculitis which was poorly responded to high steroid dose, MMF, HCQ, Colchicine, Dapsone but responded well to RTX, unfortunately shortly after RTX she presented with DLE which was treated successfully with Thalidomide. This finding may supports the study done by Edward M. Vital et al which conclude that the clinical response to rituximab in cutaneous manifestations of SLE depends on the subtype. In which none of the CCLE patients responded, and new CCLE lesions were observed during B cell depletion,<sup>16</sup> suggesting that initiation and activity of these lesions is not B cell dependent. Flares of a range of skin diseases after B cell depletion may indicate a change in the immune regulation following B cell-targeted therapy.

## Conclusion

Our lupus patient presented with lupus flare in the form of UV. She had most of the clinical and laboratory characteristics of HUVS which is difficult to be differentiated from SLE and most likely fall into the same spectrum of autoimmune diseases. Her urticarial vasculitis was poorly responding to high dose corticosteroid and other treatment modalities, however she responded well to rituximab. Further controlled clinical studies are needed to validate the long term safety and efficacy of rituximab therapy in SLE and urticarial vasculitis.

## Acknowledgement

The author would like to thank Dr Sanchez Guerrero (Professor of Medicine, University of Toronto Head, Division of Rheumatology, Mount Sinai Hospital/University Health Network) for his support.

## Author Contributions

Samar Alharbi conceived the idea, collected data of the patient and wrote the manuscript. Jorge Sanchez-Guerrero revised the manuscript. Both authors reviewed and approved of the final manuscript.

## Informed Consent

Written informed consent was obtained from the patient for publication of this case report.

## REFERENCES

1. Dubois EL, Tuffanelli DL. Clinical manifestations of systemic lupus erythematosus: computer analysis of 520 cases. *JAMA*. 1964;190:104-111.
2. Harvey AM, Shulman LE, Tumulty PA, Conley CL, Schoenrich EH. Systemic lupus erythematosus: review of the literature and clinical analysis of 138 cases. *Medicine*. 1954;33:291.
3. Vitali C, Bencivelli W, Isenberg D, et al. Disease activity in systemic lupus erythematosus: report of the Consensus Study of the European Workshop for Rheumatology Research.

- I. A descriptive analysis of 704 European lupus patients. European Consensus Study Group for Disease Activity in SLE. *Clin Exp Rheumatol*. 1992;10:527-539.
4. Drenkard C, Villa A, Reyes E, Abello M, Alarcon-Segovia D. Vasculitis in systemic lupus erythematosus. *Lupus*. 1997;6:235-242.
5. Ramos-Casals M, Nardi N, Lagrutta M, et al. Vasculitis in systemic lupus erythematosus: prevalence and clinical characteristics in 670 patients. *Medicine*. 2006;85:95-104.
6. Wisnieski JJ. Urticarial vasculitis. *Curr Opin Rheumatol*. 2000;12:24-31.
7. Venzor J, Lee WL, Huston DP. Urticarial vasculitis. *Clin Rev Allergy Immunol*. 2002;23:201-216.
8. Saigal K, Valencia IC, Cohen J, Kerdel FA. Hypocomplementemic urticarial vasculitis with angioedema, a rare presentation of systemic lupus erythematosus: rapid response to rituximab. *J Am Acad Dermatol*. 2003;49:283-285.
9. Aydogan K, Karadogan SK, Adim SB, Tunali S. Hypocomplementemic urticarial vasculitis: a rare presentation of systemic lupus erythematosus. *Int J Dermatol*. 2006;45:1057-1061.
10. Her MY, Song JY, Kim DY. Hypocomplementemic urticarial vasculitis in systemic lupus erythematosus. *J Korean Med Sci*. 2009;24:184-186.
11. McDuffie FC, Sams WM Jr, Maldonado JE, Andreini PH, Conn DL, Samayoa EA. Hypocomplementemia with cutaneous vasculitis and arthritis: possible immune complex syndrome. *Mayo Clin Proc*. 1973;48:340-348.
12. Davis M, Daoud MS, Kirby B, Gibson LE, Rogers R III. Clinicopathologic correlation of hypocomplementemic and normocomplementemic urticarial vasculitis. *J Am Acad Dermatol*. 1998;38:899-905.
13. Curd J, Zuraw B. Efficacy of hydroxychloroquine treatment of urticarial vasculitis. *J Allergy Clin Immunol*. 1984;73:600-603.
14. Fortson JS, Zone JJ, Hammond ME, Groggel GC. Hypocomplementemic urticarial vasculitis syndrome responsive to dapsone. *J Am Acad Dermatol*. 1986;15:1137-1142.
15. Jachiet M, Flageul B, Deroux A, et al. The clinical spectrum and therapeutic management of hypocomplementemic urticarial vasculitis: data from a French nationwide study of fifty-seven patients. *Arthritis Rheumatol*. 2015; 67:527-534.
16. Vital EM, Wittmann M, Edward S, et al. Brief report: responses to rituximab suggest B cell-independent inflammation in cutaneous systemic lupus erythematosus. *Arthritis Rheumatol*. 2015;67:1586-1591.