

Inside-out Medial Meniscal Repair: Improved Surgical Exposure With a Sub-semimembranosus Approach



J. Lee Pace, M.D., Paul M. Inclan, M.D., and Matthew J. Matava, M.D.

Abstract: Inside-out meniscal repair is considered the gold standard for reparable tears of the medial and lateral menisci despite the recent popularity of all-inside devices. Accurate suture passage is required to perform a stable repair as well as to prevent inadvertent neurovascular injury from the suture needles. Placement of a deep soft-tissue retractor is necessary to identify and retrieve these needles prior to tying the sutures. Several authors have recommended placement of this retractor in the interval anterior to the gastrocnemius muscle belly and above the semimembranosus tendon. However, we have noted that the needles often pass distal to the retractor when it is placed in this interval owing to the reorientation of the joint line that occurs with the knee in a relatively extended position during suture placement. We describe a modified technique in which the retractor is placed inferior to the semimembranosus, which puts it directly in line with the needles' trajectory. This modification makes inside-out medial meniscal repair safer and more efficient.

Inside-out meniscal repair has long been regarded as the gold standard for repair of tears of the posterior horn and body of both the medial and lateral menisci.¹⁻⁴ However, inside-out repair has become less commonly used with the advent of all-inside meniscal repair devices that do not require an open incision or surgical assistant.⁵ Although advances in meniscal repair technology have led to more surgeons attempting a repair, inside-out meniscal repair still has a significant role in the preservation of meniscal tissue for a variety of tear patterns.

There are several advantages to an inside-out meniscal repair that merit discussion and that are

often overlooked given the widespread prevalence of marketing efforts touting all-inside devices. Thinner needles are used to pass the sutures, which compare favorably with the larger-bore needles and implants required by most all-inside devices. Multiple points of fixation can be achieved on both the superior and inferior meniscal surfaces with high-strength, braided No. 2-0 sutures that can be placed in a vertical mattress configuration that is optimal to capture the circumferentially oriented collagen fibers on both sides of the tear^{6,7} (Fig 1). Low-profile suture knots can be tied under direct visualization on the posterior capsule with tactile and visual feedback confirming compression across the tear, which optimizes meniscal healing. The inside-out technique also eliminates the risk of implant migration within the joint that can cause damage to the articular cartilage surfaces that has been described with all-inside devices.^{8,9} Finally, the inside-out technique is appealing from a cost perspective because the sutures needed for the repair are considerably less expensive than 1 all-inside anchor.

The surgical technique used to expose the posterior capsule from which the suture needles will pass is paramount to performing this procedure safely and effectively. Accurate exposure of the deep intermuscular tissue planes is required for needle visualization. For a medial meniscal repair, the triangular interval between the semimembranosus tendon, medial head of the gastrocnemius, and posteromedial capsule

From the Department of Orthopaedic Surgery, University of Connecticut School of Medicine, Farmington, Connecticut, U.S.A. (J.L.P.); Elite Sports Medicine, Connecticut Children's Medical Center, Farmington, Connecticut, U.S.A. (J.L.P.); and Department of Orthopaedic Surgery, Washington University School of Medicine, St Louis, Missouri, U.S.A. (P.M.I., M.J.M.).

The authors report the following potential conflicts of interest or sources of funding: J.L.P. receives grant support and personal fees from Arthrex, outside the submitted work Full ICMJE author disclosure forms are available for this article online, as [supplementary material](#).

Received July 28, 2020; accepted October 19, 2020.

Address correspondence to Matthew J. Matava, M.D., 14532 S Outer Forty Dr, Chesterfield, MO 63017, U.S.A. E-mail: matavam@wustl.edu

© 2020 by the Arthroscopy Association of North America. Published by Elsevier. This is an open access article under the CC BY-NC-ND license (<http://creativecommons.org/licenses/by-nc-nd/4.0/>).

2212-6287/201321

<https://doi.org/10.1016/j.eats.2020.10.032>

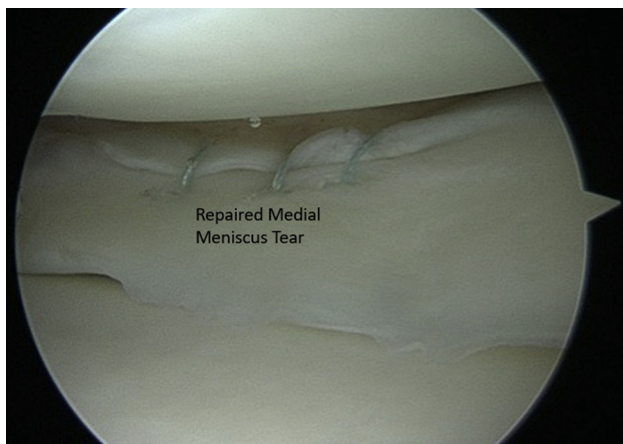


Fig 1. View of medial compartment of knee from anterolateral portal after successful meniscal repair (right knee). Vertical mattress sutures for the medial meniscal tear are placed to capture the circumferential collagen fibers of the meniscus.

is entered. The knee is typically in a position of 90° of flexion during this dissection. A Henning retractor, sterile spoon, pediatric speculum, or other curved retractor is placed in this space to identify and retrieve the suture needles as they are passed. Historically, it has been recommended that the retractor be placed in the interval anterior to the gastrocnemius tendon and superior to (above) the semimembranosus tendon.¹⁰⁻¹² However, to perform an arthroscopic medial meniscal repair, the knee must be extended to approximately 15° with a valgus force applied to expose the posterior meniscal horn. As the knee is extended, the joint line is “rotated” distally and becomes relatively perpendicular to the long axis of the semimembranosus tendon, which becomes more taut, forcing the retractor superiorly. This causes the needle trajectory to be directed distal to the retractor. Visualization as well as retrieval of the suture needles is prevented, and iatrogenic injury to the popliteal soft tissue may ensue. We have found that by placing the retractor inferior to (below) the semimembranosus

tendon, the needles are much easier to identify because the more distally placed retractor is in line with the needles’ trajectory, which avoids inadvertent soft-tissue perforation.

The purpose of this article is to describe our modified surgical approach that allows for a more ideal position of the soft-tissue retractor needed to identify the suture needles (Video 1). Difficulties with needle passage and retrieval are largely avoided because the position of the retractor is unaffected by the knee flexion angle.

Indications

The indications for inside-out meniscal repair are consistent with the accepted criteria for meniscal repair in general.^{2,13,14} These include tears that are unstable, that measure 10 mm or greater in length and are located in the vascularized red-red or red-white zone,^{15,16} and that have minimal traumatic damage. Horizontal cleavage tears¹⁷ and radial tears¹⁸ (Fig 2) that are located in the vascularized zones of the meniscus can also be repaired with the inside-out technique. With the exception of medial meniscal root tears¹⁹ and ramp lesions,²⁰ virtually any meniscal tear of the posterior horn or body of the medial (or lateral) meniscus is appropriate for the inside-out technique. Tear patterns that are more suitable for the inside-out method than for all-inside repair options include displaced longitudinal (bucket-handle) tears (Fig 3) and complex double longitudinal tears that have more than 1 reparable tear present (Fig 4). The small-diameter stainless steel needles can be directed in a variety of trajectories by straight or curved cannulas that provide multiple points of suture fixation on both the superior and inferior surfaces of the meniscus (Fig 5).

Surgical Technique

Surgical Setup

The patient is positioned supine on the operating table, and a thigh-high tourniquet is placed. It is left to the surgeon’s discretion whether the procedure is

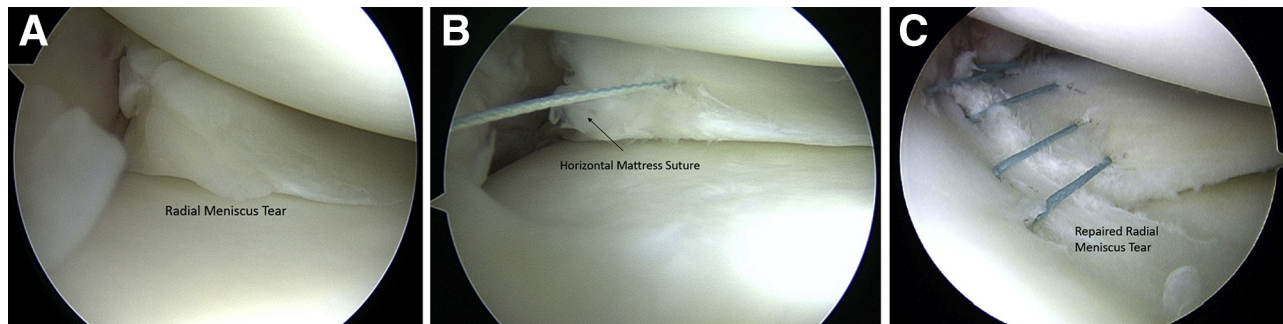


Fig 2. View of medial compartment of knee from anterolateral portal. (A) A radial tear of the left medial meniscus is identified at the time of diagnostic arthroscopy. (B) The first horizontal mattress suture has been placed in an inside-out fashion. (C) Completed inside-out repair of vascularized region of radial tear with debridement of avascular white-white zone.

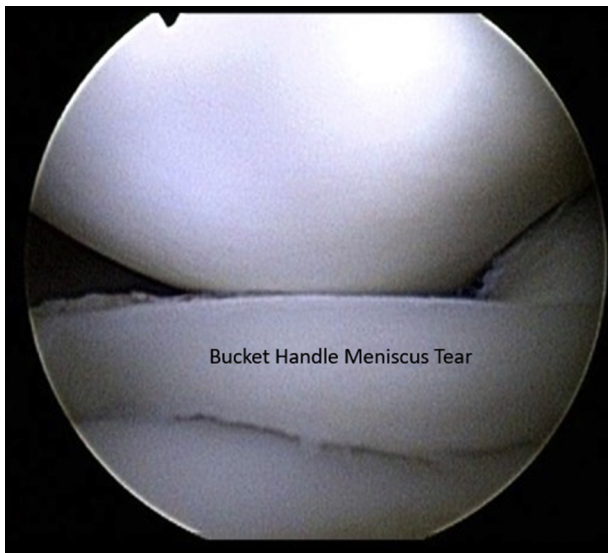


Fig 3. View of medial meniscus from anterolateral portal (left knee). A bucket-handle tear of the medial meniscus is identified at the time of diagnostic arthroscopy.

performed with the knee and operating room table straight in extension or with the foot of the bed "broken" (flexed 90°), allowing the knee to be suspended with a circumferential thigh holder and the contralateral lower extremity supported by a well-leg holder. Irrespective of the initial position, the setup should be performed in such a way that the foot of the bed is dropped when the time comes to pass the meniscal repair needles because it is ideal for the person who is retrieving the needles to be seated and unencumbered by the uninvolved extremity. After standard preparation and draping, the limb is exsanguinated with an Esmarch bandage and the tourniquet is inflated. Some surgeons may prefer not to use a tourniquet.

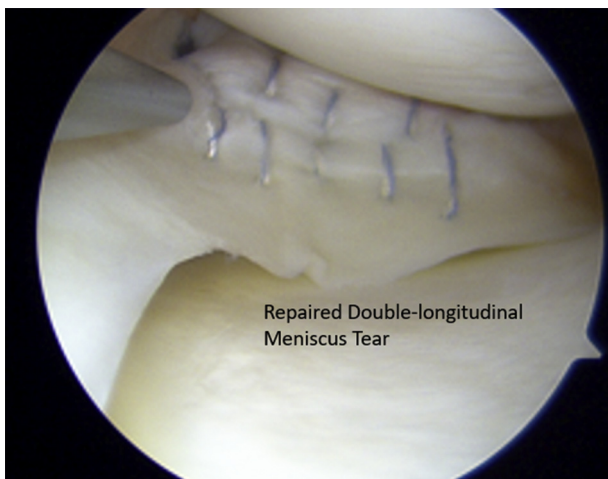


Fig 4. View of medial meniscus from anterolateral portal after successful repair. A double longitudinal tear is repaired in 2 layers using the inside-out technique.

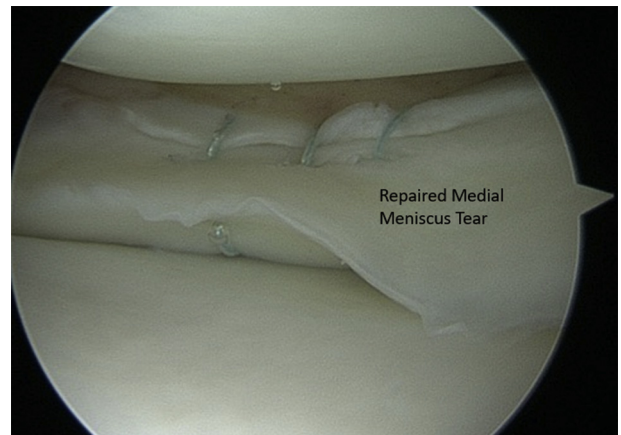


Fig 5. View of medial meniscus from anterolateral portal after successful repair (right knee). Repair of the longitudinal tear is performed by placing sutures on both the superior and inferior meniscal surfaces.

Diagnostic arthroscopy is carried out in a standard fashion to confirm the meniscal tear and its suitability for an inside-out repair. If needed, the superficial medial collateral ligament can be carefully fenestrated ("pie crusted") with an 18-gauge needle to improve visualization of the medial meniscus (Fig 6). A meniscal rasp and/or an arthroscopic shaver without suction can be used to lightly abrade the tear and adjacent meniscosynovial junction to stimulate bleeding at the repair site²¹ (Fig 7).

Open Surgical Exposure

The arthroscope is withdrawn, and the open posteromedial approach is performed. With the knee flexed between 70° and 90°, a 3- to 4-cm incision is made one-third above and two-thirds below the medial joint line, posterior to the superficial medial collateral ligament (Fig 8). It is oriented in a slightly oblique direction while the knee is flexed so that it will be parallel to the lower extremity with the knee in full extension. Superficial

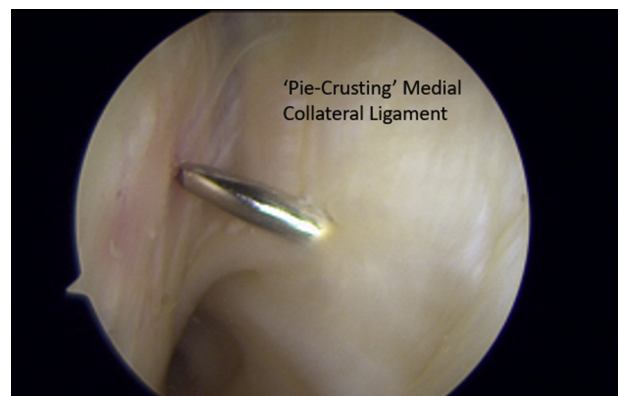


Fig 6. View from medial gutter from anterolateral portal. An 18-gauge needle is used to perform pie crusting of the superficial medial collateral ligament to improve visualization of the medial compartment.

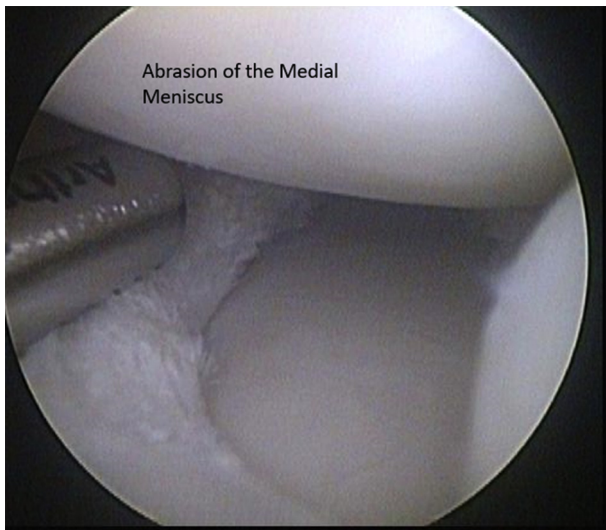


Fig 7. View of body of medial meniscus from anterolateral portal prior to arthroscopic repair. An arthroscopic shaver is used to lightly abrade the meniscosynovial junction to enhance healing (left knee).

dissection is carried down in standard fashion to the sartorial fascia, which is incised (Fig 9). Care should be taken to avoid the saphenous vein and nerve, located between the sartorius and gracilis tendons, that should be retracted inferiorly with an Army-Navy retractor. Deep to these structures is a strip of fat overlying the semimembranosus tendon. This 1-cm-thick tendon is oriented horizontally prior to attaching in multiple slips to the posteromedial tibia (Fig 10). While knee flexion is maintained, Metzenbaum scissors are used to penetrate the deep fascia just below the semimembranosus,

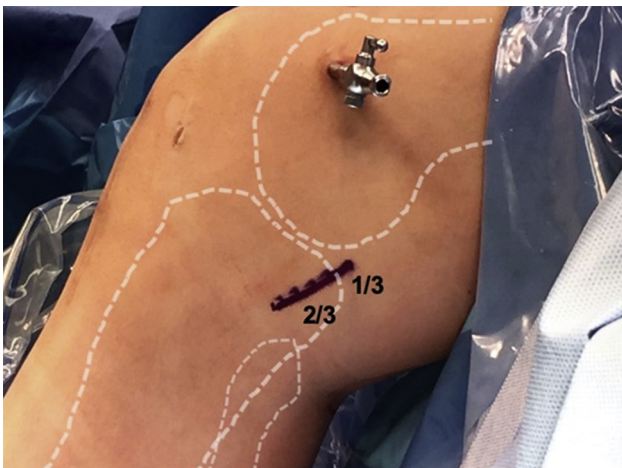


Fig 8. View of medial aspect of knee prior to surgical incision (right knee). The patient is positioned supine with the leg suspended in a leg holder. A medial incision is made to perform an inside-out medial meniscal repair. The incision is located one-third proximal and two-thirds distal to the medial joint line and posterior to the superficial medial collateral ligament.

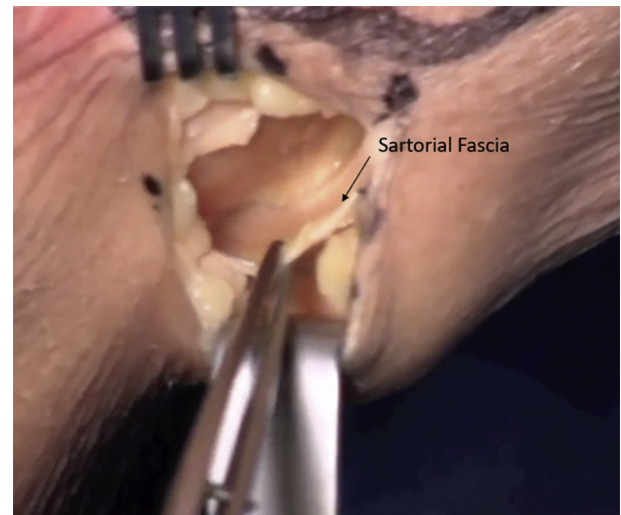


Fig 9. View of superficial dissection of medial knee. An incision is made in the sartorial fascia in a longitudinal fashion. Forceps are grasping the incised sartorial fascia (right knee).

anterior to the medial head of the gastrocnemius muscle belly and posterior to the posteromedial border of the proximal tibia (Fig 11). The fascia is bluntly and sharply opened, as needed, to create enough room for the curved soft-tissue retractor. The gastrocnemius can be easily mobilized on the medial side (Fig 12). Finger palpation can be used to ensure that the dissection is carried far enough laterally that the intercondylar notch and proximal tibial insertion of the posterior cruciate ligament are easily felt. If the posteromedial capsule is inadvertently perforated during this dissection, it should be repaired with a No. 3-0 absorbable suture to prevent fluid extravasation during the meniscal repair.

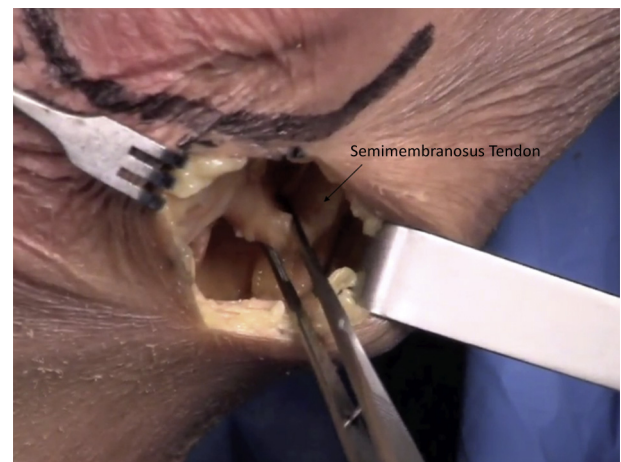

Fig 10. View of deep dissection of medial knee after incision of sartorial fascia (right knee). The semimembranosus tendon is held in the forceps. The Army-Navy device retracts the posterior skin and soft tissue while a Senn retractor is placed anteriorly.

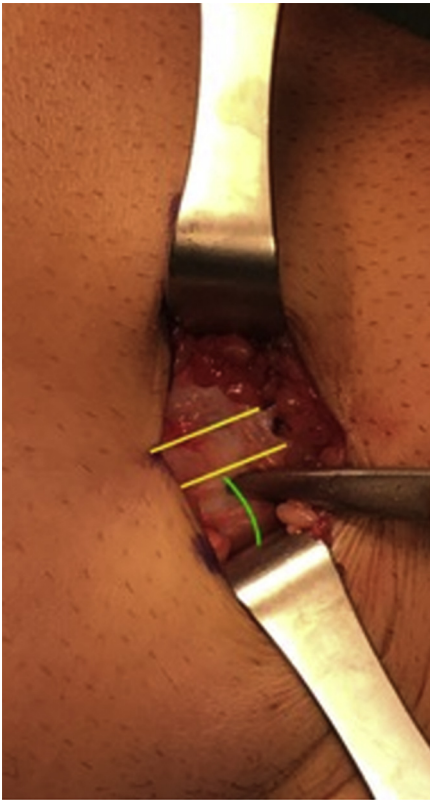


Fig 11. View of medial knee with scissors placed at interval between semimembranosus and gastrocnemius (right knee). The deep dissection is located distal to the semimembranosus (outlined by yellow lines) and anterior to the medial head of the gastrocnemius (outlined by curved green arrow).

While the knee is maintained in flexion, the retractor is placed in the triangular interval between the semimembranosus, medial head of the gastrocnemius, and posterior tibia. The surgeon's index finger can be placed within this interval while the foot is passively plantar flexed and dorsiflexed to ensure that the gastrocnemius muscle is entirely posterior to the retractor (Fig 13). An

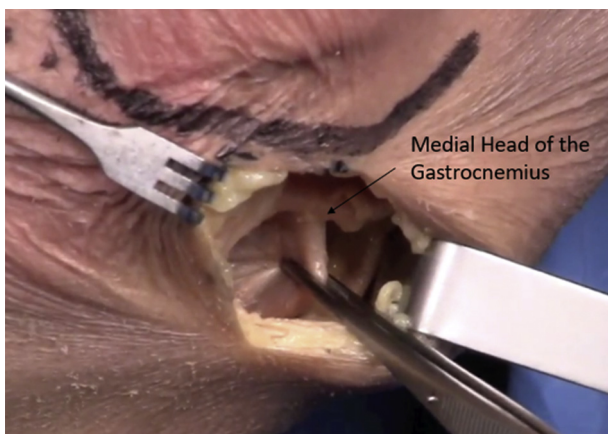

Fig 12. Medial gastrocnemius tendon held in forceps. The Army-Navy device retracts the posterior skin and soft tissue while a Senn retractor is placed anteriorly.

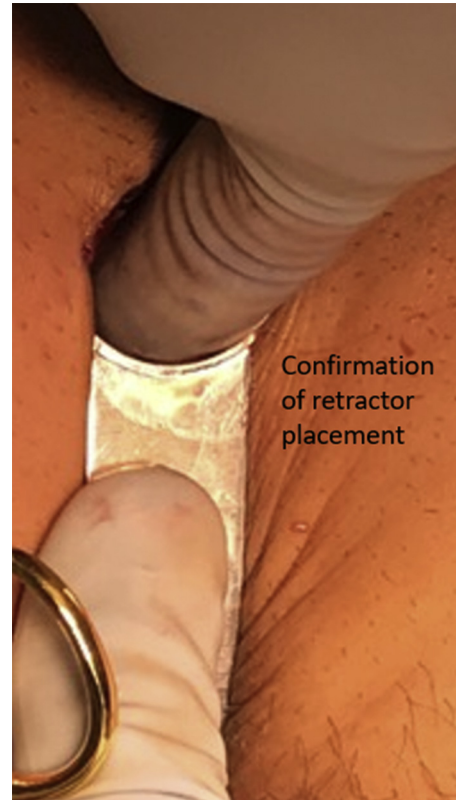


Fig 13. Placement of an index finger within the medial knee wound while passively dorsiflexing and plantar flexing the ankle will confirm adequate posterior retraction of the gastrocnemius muscle (right knee).

advantage of a smaller incision is that skin tension helps retain the retractor in place, which eliminates the need for the assistant to retrieve the needles while holding the retractor. As the knee is brought into extension, it can be confirmed that the joint line remains oriented in line with the retractor and not distal to it as typically occurs when the retractor is placed above the semimembranosus (Fig 14).

One useful strategy to improve the efficiency and ease with which needles are retrieved is to create an instrument "holster" with the use of a Kocher clamp attached to the draping at chest level for the assistant, who typically sits while retrieving the needles (Fig 15). A needle driver is placed in one finger ring, and a heavy pair of suture scissors is placed in the other finger ring. We also recommend that the assistant use a headlamp during suture retrieval to improve visualization of the needles as they pass through the capsule, as well as to avoid inadvertent damage to suture knots that have already been tied. A basin or other receptacle can be placed at the assistant's feet to dispose of the needles.

Arthroscopic Meniscal Repair

The arthroscope is reinserted into the knee, and the medial compartment is accessed. Suture passage can proceed in a routine fashion. Our preference is to use

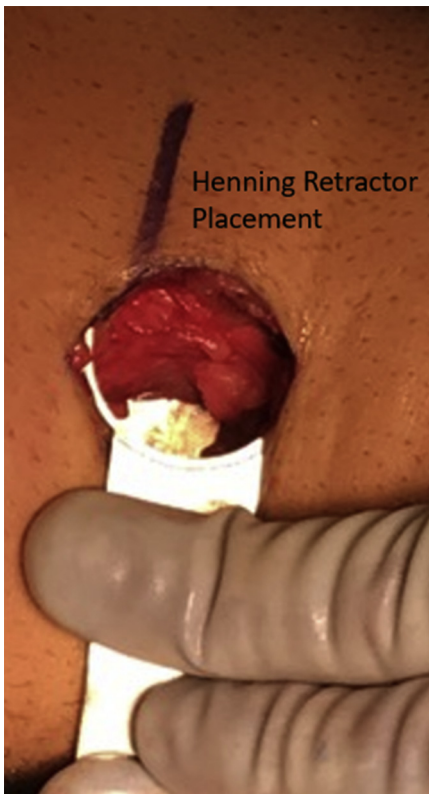

Fig 14. View of medial knee wound (right knee). The Henning retractor is oriented in line with the medial joint line when placed below the semimembranosus tendon.

No. 2-0 Mini SutureTape (Arthrex, Naples, FL) because this suture has a broad surface, which reduces the risk of cutting through the meniscus and is less prone to breaking during knot tying. Alternatively, No. 2-0 FiberWire (Arthrex) can be used. This braided suture has a Kevlar core (DuPont, Wilmington, DE), which provides improved strength for a smaller-gauge suture. Both sutures are 38 inches long and are swaged onto 11-inch stainless steel needles. Single- or double-barrel curved or straight cannulas are used to guide the suture needles across the tear based on surgeon preference, local anatomy, and tear location (Fig 16).

The sutures are placed in a vertical mattress configuration, 3 to 5 mm apart, beginning on the superior meniscal surface to “set” the meniscus on the tibial plateau (Fig 17). As the needles are passed, the assistant retrieves them with the needle driver, bending the tip 90° and re-gripping so that the needle driver is perpendicular to the line of pull, which prevents slippage of the needle from the needle driver (Fig 18). A headlamp can be worn by the assistant to facilitate visualization of deep sutures. The needle is pulled out of the wound, cut from the suture, and deposited in the needle basin. Once both needles of each suture are passed and removed, the suture limbs are pulled taut while the video monitor is visualized (Fig 19). There should be tactile resistance once the sutures are pulled

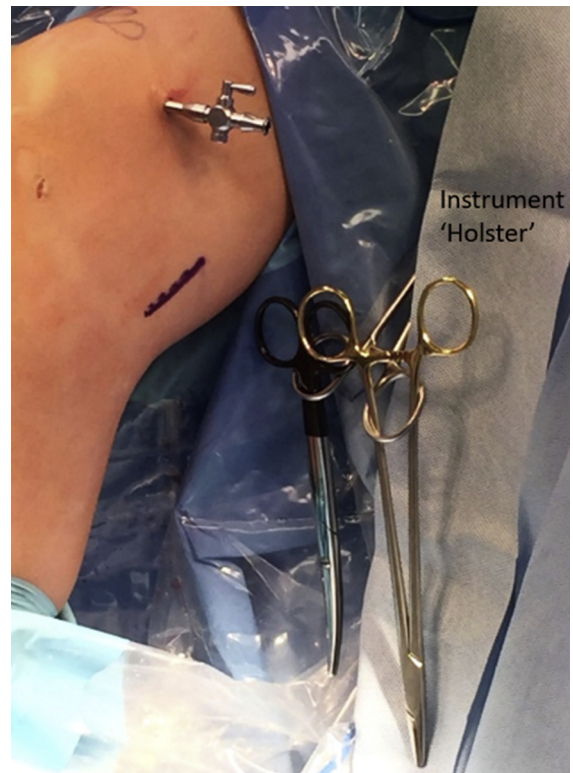

Fig 15. A holster is used to hold the needle driver and suture scissors for the surgical assistant, who will sit at knee height to retrieve the meniscal needles on the medial side of the knee (right knee).

taut and the tear is reduced. It is important not to over-tighten the sutures, which may cause the inner meniscal segment to displace upward; this will be evident from the arthroscopic video. The sutures are then tied with 5 alternating half-hitch knots, and the redundant suture material is cut. Alternating sutures are placed on the inferior surface to create a “stacked vertical mattress” based on the tear pattern (Fig 20).

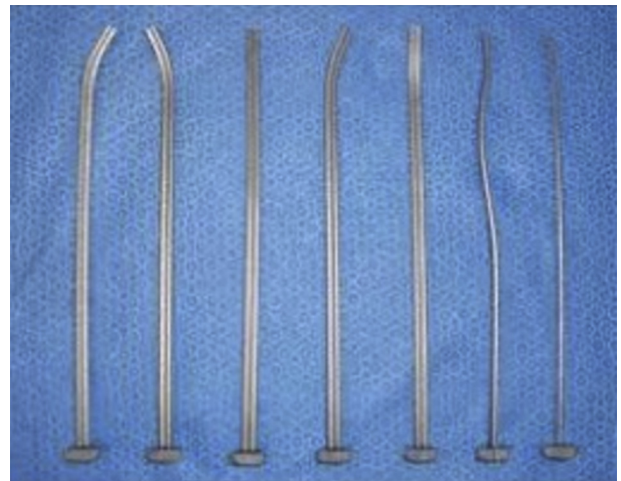

Fig 16. Variety of straight and curved single- and double-barrel meniscal repair cannulas.

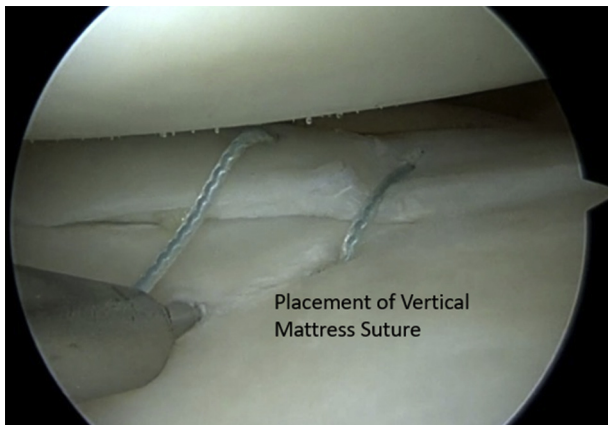


Fig 17. View of medial meniscus from anteromedial portal (right knee). The suture needle is guided by the cannula to place the second limb of the vertical mattress suture.

This method of suture passage is continued until a sufficient number of stitches have been placed to reduce and stabilize the tear (Fig 21). If the retractor is unable to block a needle that is placed close to the posterior root, either the retractor or spoon can be inserted deeper into the wound or a longer retractor can be inserted.

If the meniscus is repaired in isolation without concomitant intra-articular ligament surgery, marrow venting of the intercondylar notch or the non-chondral portion of the medial femoral condyle is performed to cause egress of marrow elements into the joint to aid healing²² (Fig 22). The posteromedial incision is closed in a standard fashion, as are the arthroscopic portals. Postoperative management is dictated by the tear type, concomitant procedures, and surgeon preference. However, this revised approach does not alter any aspects of the postoperative rehabilitation.

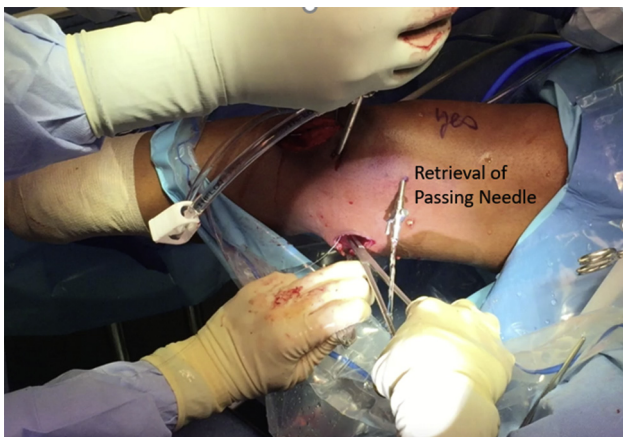

Fig 18. View of medial knee after passage of passing needle through medial meniscus (right knee). The surgical assistant grasps the needles and pulls them out of the wound. It is important to grasp the needles at 90° to avoid slippage from the needle driver.

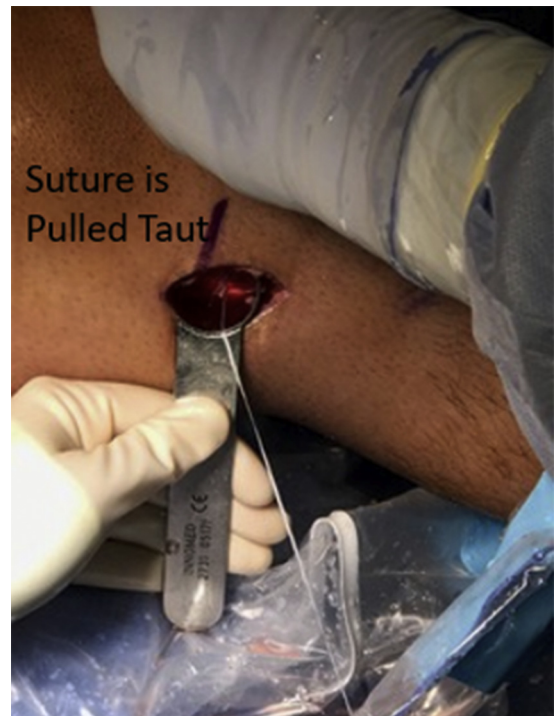

Fig 19. View of medial knee after retrieval of passing needle from medial knee wound (right knee). The suture is pulled taut after removal of the needle.

Discussion

The benefits of meniscal preservation have been well described to retain the primary functions of the menisci in the knee, including shock absorption and load transmission,²³ joint stability,²⁴ proprioception,²⁵ and articular cartilage nutrition.²⁶ Inside-out meniscal repair is an integral tool to preserve meniscal tissue and should be familiar to the arthroscopic knee surgeon.

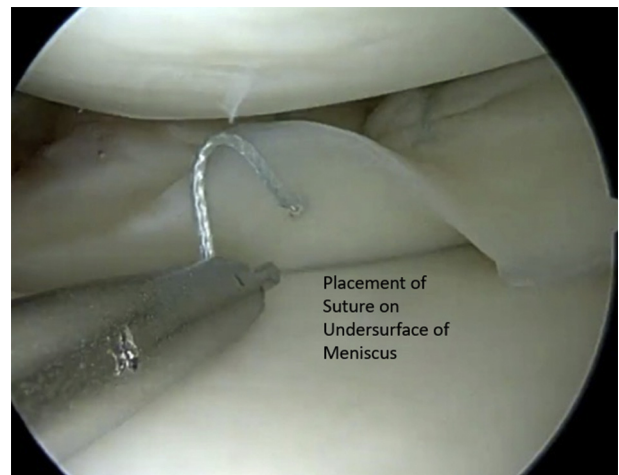


Fig 20. View of medial meniscus from anterolateral portal during meniscal repair (right knee). A vertical mattress suture is placed on the inferior meniscal surface. Alternating vertical sutures are placed on both meniscal surfaces.

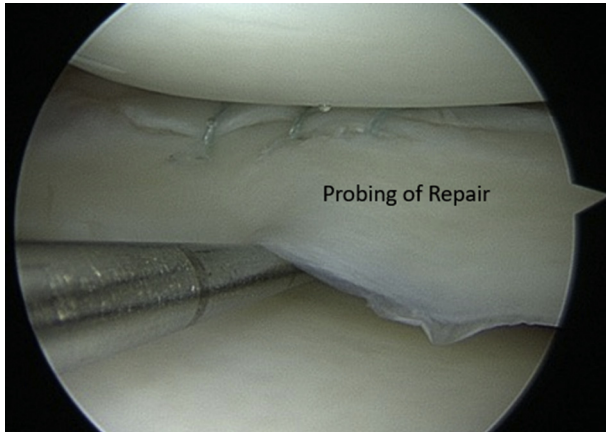


Fig 21. View of medial meniscus from anterolateral meniscus after completion of meniscal repair (right knee). Repair stability is confirmed with an arthroscopic probe.

Although technological advances have created opportunities for newer, less invasive all-inside implants, inside-out repair still plays a critical role in most meniscal tear patterns. The primary drawback of inside-out meniscal repair is the need for an open surgical incision for retrieval of the needles by a surgical assistant. Whereas the recent literature has focused primarily on the results of all-inside devices,²⁷⁻³¹ these studies often compare their outcomes with those of inside-out repair because it is still considered the gold standard for meniscal repair.¹⁻⁴

Most published techniques for inside-out medial meniscal repair describe development of the interval above the semimembranosus tendon and anterior to the gastrocnemius muscle as the desired location to place the soft-tissue retractor to block and retrieve the suture needles¹⁰⁻¹² (Fig 23). Because the retractor is initially placed with the knee in 70° to 90° of flexion,

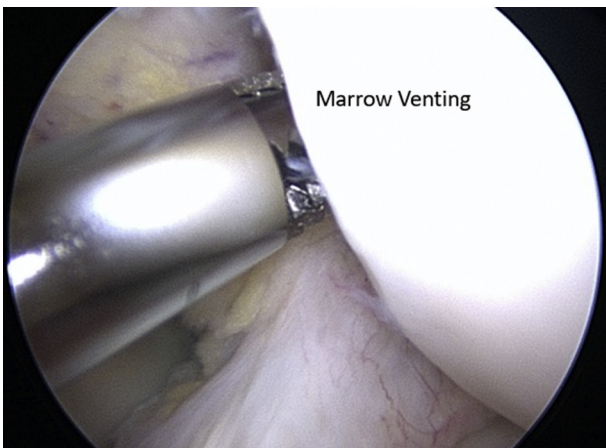


Fig 22. View of medial condyle and intercondylar notch after meniscal repair (right knee). A shaver is used to perform marrow venting of the intercondylar notch to increase the presence of marrow elements to facilitate healing.

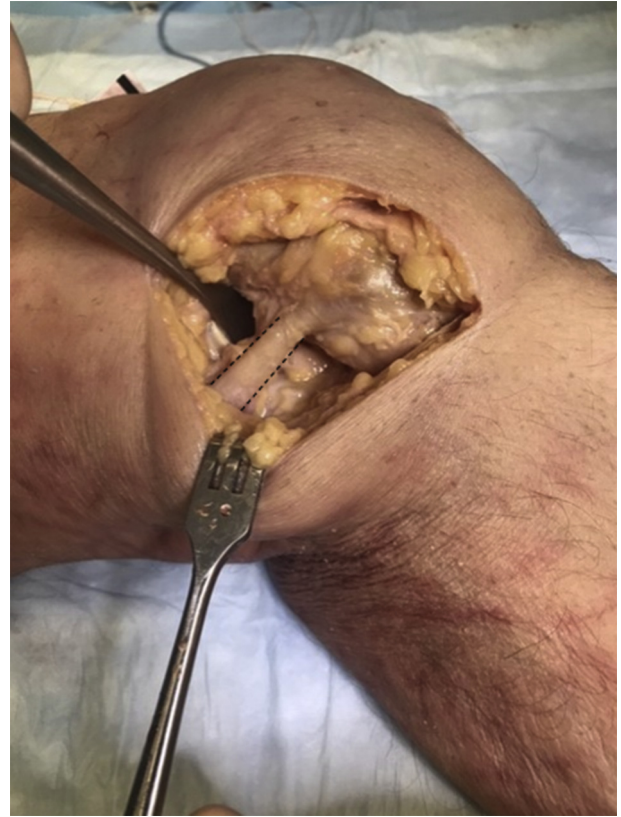

Fig 23. View of medial knee after deep dissection (left knee). The retractor is traditionally placed proximal to the semimembranosus (dashed lines) during an inside-out meniscal repair.

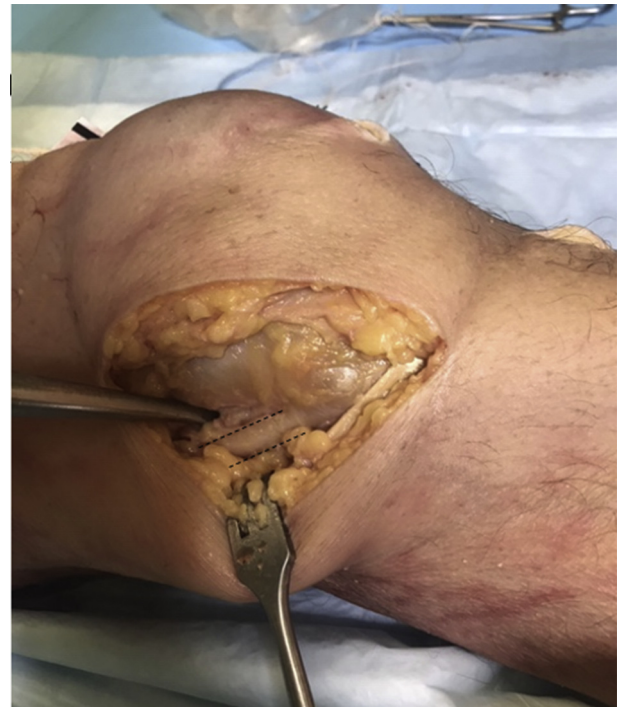

Fig 24. View of medial wound after operative exposure (left knee). A table spoon "retractor" is placed in the traditional location proximal to the semimembranosus tendon (dashed lines).

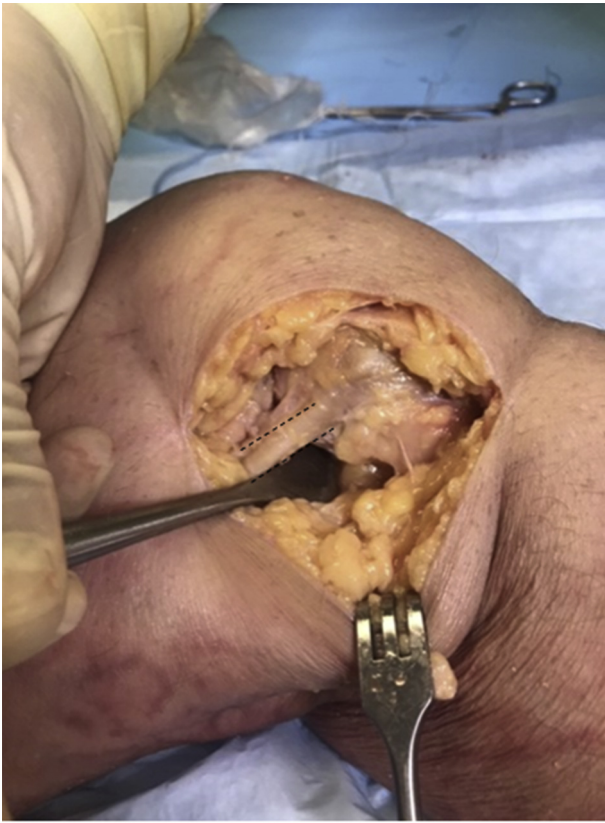


Fig 25. Cadaveric dissection showing our recommended modified location in which the retractor is placed distal to the semimembranosus (dashed lines; left knee).

the semimembranosus is roughly parallel to the joint line, which provides adequate orientation of the retractor in relation to the joint line (Fig 24). However, during arthroscopic visualization of the medial compartment, the knee is in a relatively extended position. Thus, the semimembranosus tendon, which now assumes a position that is more perpendicular to

Table 1. Advantages and Disadvantages of Modified Inside-out Meniscal Repair

Advantages	
Accurate placement of soft-tissue retractor that is in line with posteromedial joint line irrespective of knee flexion	
More efficient needle retrieval	
Less risk of needle-stick injury to surgical assistant	
Less risk of neurovascular injury	
Reduced operating room time	
Disadvantages	
Possibility of passing suture through semimembranosus tendon	
Lack of familiarity with procedure	

the joint line, displaces the retractor proximally away from the more distally oriented joint line. When this occurs, the needles tend to pass inferior to the retractor. This contributes to the difficulty that is often associated with the inside-out technique, as well as the neurovascular risk associated with this procedure.

Conversely, when the retractor is placed below the semimembranosus (Fig 25), it is not displaced proximally and it maintains an ideal location in line with the medial joint line irrespective of the degree of knee flexion (Fig 26). This technical modification increases the safety and reliability of needle passage and reduces the operative time because suture passage and retrieval are much more efficient. Advantages and disadvantages of the modified inside-out technique are described in Table 1. Pearls and pitfalls are listed in Table 2.

In conclusion, despite recent advances in meniscal repair technology, the inside-out repair continues to play a central role in most meniscal tears involving the posterior horn and mid body of the medial and lateral menisci. Unfortunately, technical difficulties owing to imprecise needle passage and retrieval have lessened its popularity. This is due, at least in part, to the unfounded recommendation to position the deep

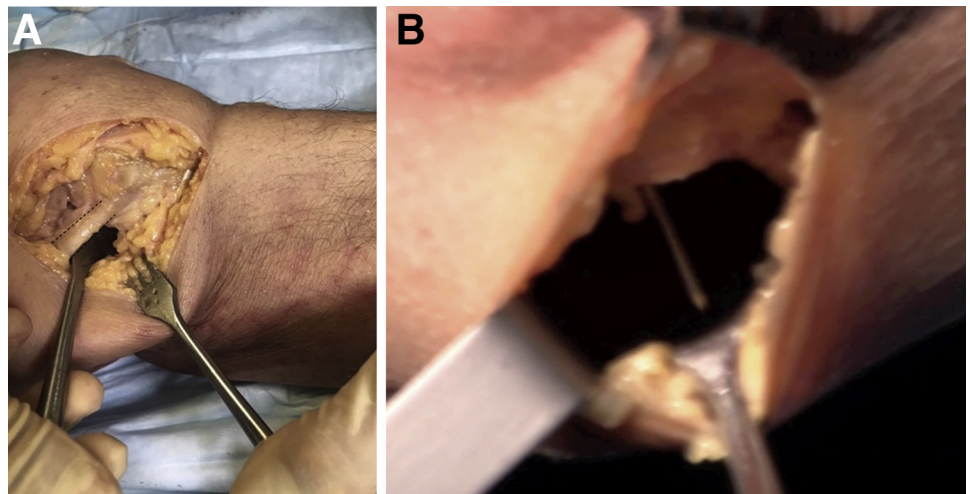


Fig 26. Cadaveric dissection of medial knee (left knee). (A) A tablespoon retractor is placed in the recommended location distal to the semimembranosus tendon (dashed lines). (B) The meniscal needle is passed in line with the retractor.

Table 2. Pearls and Pitfalls of Modified Inside-out Meniscal Repair

Pearls	Pitfalls
A 3- to 4-cm incision is made one-third proximal and two-thirds distal to the medial joint line posterior to the sMCL.	More than 1 retractor is needed depending on patient size.
Dissection and retractor placement are performed with the knee in flexion.	Larger knees with a thicker soft-tissue envelope may require a longer retractor to provide access to the posteromedial joint line.
Blunt dissection down to the sartorial fascia will minimize the risk of injury to the saphenous nerve and vein.	The saphenous nerve and vein lie deep to the sartorius tendon and can be injured.
The saphenous vein and nerve are identified deep to the sartorius tendon and retracted posteriorly.	The needle may not always be readily visible in the retractor, especially when passing needles close to the posterior root. The surgeon should always check for a tactile feel of a firm ("metal-on-metal") stop during needle advancement.
The semimembranosus tendon is covered with a layer of fat and runs in a horizontal direction.	The surgeon should be cognizant of the anatomy of the semimembranosus. It can fan out owing to multiple insertion sites on the proximal tibia and can sometimes be mistaken for the pes anserine tendons.
The incision should be large enough to retain the retractor. Tension from the skin can help hold it in place.	The posteromedial capsule may be inadvertently perforated during the deep dissection. If identified, repair should be performed to prevent fluid extravasation.
A teaspoon or tablespoon can be used if a Henning retractor is not available.	Failure to confirm that the gastrocnemius tendon is posterior to the retractor with passive ankle motion may result in needle passage through the muscle.

sMCL, superficial medial collateral ligament.

soft-tissue retractor superior to the semimembranosus tendon. Implementation of the modified technique described in this article, which places the retractor in the interval below the semimembranosus, significantly improves needle retrieval and allows for a much more reliable, safe, and efficient inside-out medial meniscal repair.

References

- Buckland DM, Sadoghi P, Wimmer MD, et al. Meta-analysis on biomechanical properties of meniscus repairs: Are devices better than sutures? *Knee Surg Sports Traumatol Arthrosc* 2015;23:83-89.
- Fisher SR, Markel DC, Koman JD, et al. Pull-out and shear failure strength of arthroscopic meniscal repair systems. *Knee Surg Sports Traumatol Arthrosc* 2002;10:294-299.
- Rankin CC, Lintner DM, Noble PC, et al. A biomechanical analysis of meniscal repair techniques. *Am J Sports Med* 2002;30:492-497.
- Woodmass JM, LaPrade RF, Sgaglione NA, et al. Current concepts review. Meniscal repair: Reconsidering indications, techniques, and biologic augmentation. *J Bone Joint Surg Am* 2017;99:1222-1231.
- Turman KA, Diduch DR, Miller MD. All-inside meniscal repair. *Sports Health* 2009;5:438-444.
- Mow VC, Ratcliffe A, Chern KY, Kelley MA. Structure and function relationships of the menisci of the knee. In: Mow VC, Arnoczky SP, Jackson DW, eds. *Knee meniscus: Basic and clinical foundations*. New York: Raven Press, 1992;37-57.
- Petersen W, Tillmann B. Collagenous fibril texture of the human knee joint menisci. *Anat Embryol* 1998;197:317-324.
- Menetrey J, Seil R, Frischy D. Chondral damage after meniscal repair with the use of a bioabsorbable implant. *Am J Sports Med* 2002;30:896-899.
- Tachabana Y, Sakaguchi K, Tatsuru G, et al. Repair integrity by second-look arthroscopy after arthroscopic meniscal repair with the Fast T-Fix during anterior cruciate ligament reconstruction. *Am J Sports Med* 2010;38:965-971.
- Chahla J, Serra Cruz R, Cram TR, Dean CS, LaPrade RF. Inside-out meniscal repair: Medial and lateral approach. *Arthrosc Tech* 2016;5:e163-e168.
- Nelson CG, Bonner KF. Inside-out meniscus repair. *Arthrosc Tech* 2013;2:e453-e460.
- Noyes FR, Barber-Weston SD. Chapter 23: Meniscus repairs: Diagnosis, repair techniques, and clinical outcomes. In: Noyes FR, Barber-Weston SD, eds. *Noyes' knee disorders. Surgery, rehabilitation, clinical outcomes*. Ed 2. Amsterdam: Elsevier, 2017;677-718.
- Heckman TP, Barber-Weston SD, Noyes FR. Indications, techniques, rehabilitation, and clinical outcome. *J Orthop Sports Phys Ther* 2006;36:795-814.
- Karia M, Ghaly Y, Al-Hadithy N, Mordecai S, Gupte C. Current concepts in the techniques, indications and outcomes of meniscal repairs. *Eur J Orthop Surg Traumatol* 2019;29:509-520.
- Arnoczky SP, Warren RF. The microvasculature of the human meniscus. *Am J Sports Med* 1982;10:90-95.
- DeHaven KE. Decision-making features in the treatment of meniscal lesions. *Clin Orthop Relat Res* 1990;252:49-54.
- Kurzweil PR, Lynch NM, Coleman S, Kearney B. Repair of horizontal meniscus tears: A systematic review. *Arthroscopy* 2014;30:1513-1519.
- Pareek A, O'Malley MP, Levy BA, Stuart MJ, Krych AJ. Inside-out repair for radial meniscus tears. *Arthrosc Tech* 2016;5:e793-e797.

19. Bhatia S, LaPrade CM, Ellman MB, LaPrade RF. Meniscal root tears: Significance, diagnosis, and treatment. *Am J Sport Med* 2014;42:3016-3030.
20. Chahla J, Dean CS, Moatshe G, et al. Meniscal ramp lesions: Anatomy, incidence, diagnosis, and treatment. *Orthop J Sports Med* 2016;4. 2325967116657815.
21. Taylor SA, Rodeo SA. Augmentation techniques for isolated meniscal tears. *Curr Rev Musculoskelet Med* 2013;6: 95-101.
22. Dean CS, Chahla J, Matheny LM, Mitchell JJ, LaPrade RF. Outcomes after biologically augmented isolated meniscal repair with marrow venting are comparable with those after meniscal repair with concomitant anterior cruciate ligament reconstruction. *Am J Sports Med* 2017;45:1341-1348.
23. Baratz ME, Fu FH, Mengato R. Meniscal tears: The effect of meniscectomy and of repair on intraarticular contact areas and stress in the human knee. A preliminary report. *Am J Sports Med* 1986;14:270-275.
24. Levy IM, Torzilli PA, Gould JUD, et al. The effect of medial meniscectomy on anterior-posterior motion of the knee. *J Bone Joint Surg Am* 1982;64:883-888.
25. Dye SF, Vaupel GL, Dye CC. Conscious neurosensory mapping of the internal structures of the human knee without intraarticular anesthesia. *Am J Sports Med* 1998;26:773-777.
26. Fithian DC, Kelly MA, Mow VC. Material properties and structure-function relationship in the menisci. *Clin Orthop Relat Res* 1990;25:19-31.
27. Ayeni O, Peterson D, Chan K, Javidan A, Gandhi R. Suture repair versus arrow repair for symptomatic meniscus tears of the knee: A systematic review. *J Knee Surg* 2012;25:397-402.
28. Elmallah R, Jones LC, Malloch L, Barrett GR. A meta-analysis of arthroscopic meniscal repair: Inside-out versus outside-in versus all-inside techniques. *J Knee Surg* 2019;32:750-757.
29. Fillingham YA, Riboh JC, Erickson BJ, Bach BR Jr, Yanke AB. Inside-out versus all-inside repair of isolated meniscal tears. *Am J Sports Med* 2017;45:234-242.
30. Grant JA, Wilde J, Miller BS, Bedi A. Comparison of inside-out and all-inside techniques for the repair of isolated meniscal tears: A systematic review. *Am J Sports Med* 2010;40:459-468.
31. Samuelsen BT, Johnson NR, Hevesi M, et al. Comparative outcomes of all-inside versus inside-out repair of bucket-handle meniscal tears: A propensity-matched analysis. *Orthop J Sports Med* 2018;6. 2325967118779045.