

# Semaglutide-associated bullous pemphigoid



Clayton P. Burruss, BS,<sup>a</sup> Jordan M. Jones, MD,<sup>b</sup> and Jyoti B. Burruss, MD<sup>b</sup>  
Lexington and Louisville, Kentucky

**Key words:** diabetes mellitus; drug interactions; glucagon-like peptide-1; pemphigoid; semaglutide.

## INTRODUCTION

Bullous pemphigoid (BP) is an autoimmune subepidermal blistering disease characterized by intensely pruritic urticarial plaques and bullae of the skin and, to a lesser extent, the mucosa.<sup>1,2</sup> While many cases of BP are determined to be idiopathic, the incidence of BP with various medications resulting in drug-associated bullous pemphigoid (DABP) is on the rise.<sup>3</sup> Glucagon-like peptide-1 (GLP-1) agonist-associated BP has been previously reported after administration of dulaglutide.<sup>4</sup> Here we report a unique case of BP attributed to semaglutide, another medication in the GLP-1 agonist class.

## CASE REPORT

A 61-year-old woman with type II diabetes mellitus on semaglutide and glimepiride presented in December 2020 with a single erythematous, crusted lesion on her breast. Her medical history was otherwise significant for hypertension, hyperlipidemia, lichen sclerosus, fibromyalgia, chronic gingivitis, and rheumatoid arthritis, and her medications at the time of presentation included cyclobenzaprine, amitriptyline, hydroxychloroquine, oxycodone/paracetamol, atorvastatin, losartan, chlorhexidine oral rinse, and clobetasol 0.05% cream. Her only recent medication change was the initiation of semaglutide in November 2020.

The patient returned in January 2021 with new crusted erosions of the breast and lower back, along with worsening erythema and edema of the gingivae beyond her baseline gingivitis (Fig 1). Prior to presentation, she had applied 2% ketoconazole cream and 2.5% hydrocortisone cream—both left over from a previously treated and resolved case of intertrigo—to the new cutaneous lesions without benefit.

### Abbreviations used:

BP:	bullous pemphigoid
DABP:	drug-associated bullous pemphigoid
DPP-4is:	dipeptidyl peptidase-4 inhibitors
ELISA:	enzyme-linked immunosorbent assay
GLP-1:	glucagon-like peptide-1
IgG:	immunoglobulin G
IIF:	indirect immunofluorescence

Skin biopsies were obtained from the patient's lower back and breast for hematoxylin-eosin staining and, additionally, from the patient's breast for immunofluorescence testing. No mucosal biopsies were taken. Biopsies revealed subepidermal vesiculation with brisk mixed dermal infiltrate containing many eosinophils. Direct immunofluorescence demonstrated linear immunoglobulin G (IgG) reactivity in an n-serrated pattern and linear C3 staining along the basement membrane (Fig 2). Indirect immunofluorescence (IIF) was positive with IgG4 epidermal localization on human split-skin substrate. Enzyme-linked immunosorbent assay (ELISA) testing of the patient's serum was significant for elevated levels of anti-BP180 antibodies at 86 units (positive,  $\geq 9$  units). Anti-BP230 antibody levels were not pathologically elevated at 1 unit (positive,  $\geq 9$  units). Direct immunofluorescence staining, IIF split-skin localization, and positive ELISA titers together supported a diagnosis of BP. The patient discontinued semaglutide shortly after diagnosis, followed by marked improvement in the cutaneous erosions and reduced inflammation of her gingivae. She did not use any additional topical treatments for these lesions from the time of diagnosis through the time of resolution. At follow up 5 months after presentation, she had mild gingival irritation that was consistent with her baseline gingivitis. IIF titers were repeated, which again demonstrated IgG4

From the University of Kentucky College of Medicine, Lexington<sup>a</sup>; University of Louisville, Department of Medicine, Division of Dermatology.<sup>b</sup>

Funding sources: None.

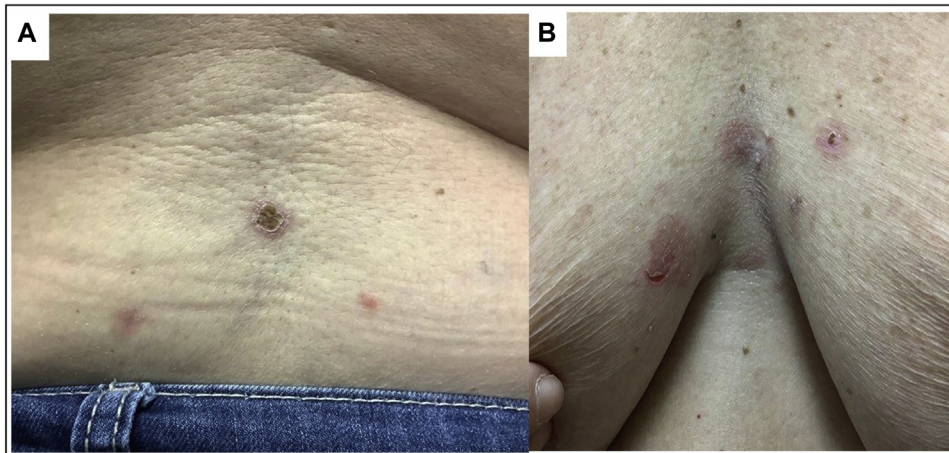
Correspondence to: Clayton P. Burruss, BS, 1316 Gray Hawk Rd. #C, Lexington, KY 40502. E-mail: [clayton.burruss@uky.edu](mailto:clayton.burruss@uky.edu).

JAAD Case Reports 2021;15:107-9.

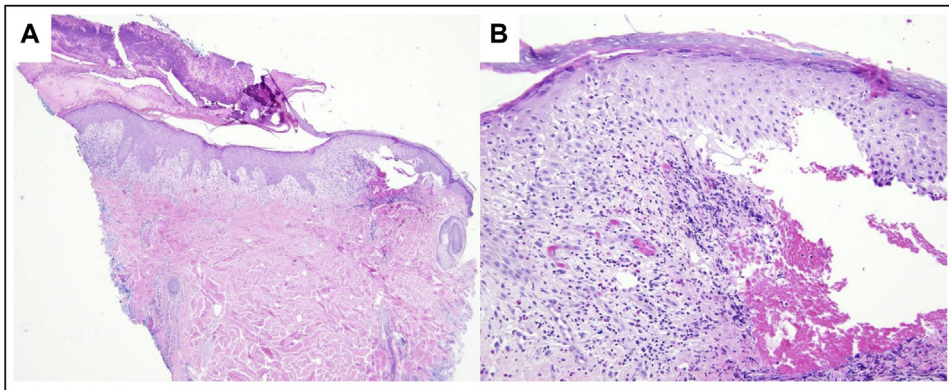
2352-5126

© 2021 by the American Academy of Dermatology, Inc. Published by Elsevier, Inc. This is an open access article under the CC BY-NC-ND license (<http://creativecommons.org/licenses/by-nc-nd/4.0/>).

<https://doi.org/10.1016/j.jidcr.2021.07.027>



**Fig 1.** Bullous pemphigoid: erythematous erosions with crusting on lumbar back (A) and breasts (B).



**Fig 2.** Punch biopsy of the superior lumbar aspect of the back with subepidermal vesiculation, brisk mixed infiltrate with numerous eosinophils. Hematoxylin-eosin staining; original magnification,  $\times 40$  (A) and  $\times 100$  (B).

epidermal localization on human split skin and elevated levels (though slightly decreased from initial examination) of anti-BP180 antibodies at 69 units on ELISA. Anti-BP230 antibody testing remained negative at 1 unit.

## DISCUSSION

Although DABP is becoming more prevalent, as the number of implicated medications grows, it is important to note that the presentation of DABP may differ from classic BP upon physical examination. In this case, the patient demonstrated signs of classic BP with exacerbation of her pre-existing gingivitis. Although mucosal involvement may occur in BP, it is less common when compared with other blistering diseases. For this reason, the differential diagnosis included pemphigus vulgaris, which commonly presents with mucosal involvement with subsequent development of cutaneous disease. ELISA results demonstrated normal anti-desmoglein 1 and

anti-desmoglein 3 IgG antibody levels, further opposing the diagnosis of pemphigus vulgaris. Direct immunofluorescence and IIF results supported the diagnosis of BP.

Of the drugs listed in this patient's medication history, losartan has also been implicated in causing DABP. In particular, Saraceno *et al.*<sup>5</sup> reported a case of losartan-associated BP, in which the patient developed pruritic vesicular lesions one week after administration of losartan. The patient we describe, however, had been on losartan for over a year without complications and only developed symptoms shortly after a month following semaglutide initiation. Furthermore, her symptoms resolved after removal of semaglutide, supporting the premise that this was the medication responsible for the development of the patient's symptoms. The time course of symptom development in this case mirrors that seen in another report of BP related to a different GLP-1 agonist (dulaglutide), with patients

in both instances demonstrating pruritic lesions approximately 2 months after starting the medication.<sup>4</sup>

The pathogenesis of classic BP is characterized by autoantibodies to BP180, a transmembrane collagen hemidesmosomal protein that maintains the dermal-epidermal connection. While BP230, a plakin family member protein, also plays a role in dermal-epidermal adhesion, the significance of BP230 is relatively unknown.<sup>6</sup> It has been proposed that monitoring autoantibody levels toward these proteins (through IIF, ELISA, or immunoblot studies) has utility in assessing disease activity or response to treatment. However, one review of the literature suggested that up to 50% of classic BP patients continue to have detectable anti-basement membrane zone antibodies while in clinical remission, though usually at decreased levels compared to pre-treatment.<sup>7</sup> The persistence of elevated anti-BP180 antibodies following resolution of this patient's clinical disease is therefore not atypical or suggestive of continued BP activity. As reported by Yamagami et al in a series of patients with vancomycin-induced linear immunoglobulin A bullous dermatosis, immunoglobulin A autoreactivity to the basement membrane zone required continuous presence of vancomycin in serum.<sup>8</sup> Therefore, it stands to reason that a similar mechanism exists for DABP patients, in which objectively elevated autoantibody levels (as seen on this patient's IIF) become clinically significant only in the presence of the triggering medication.

Although DABP is less common than classic BP, medication history should not be overlooked when searching for a potential trigger. It is also important to recognize that the clinical presentation of DABP may not mimic the tense bullae formation characteristic of classic BP, and autoantibody titers may remain elevated even in clinical remission. Being aware of clinical variants will help clinicians recognize the possible etiology for the eruption and proceed with appropriate management. As new therapeutics are

developed, the variety of medication classes implicated in DABP grows.<sup>1,9</sup> Providers must be cognizant of medications that are associated with DABP while keeping an open mind to new triggers and understand how management and monitoring disease response differs from classic BP cases.

We thank the Department of Medicine, Division of Dermatology at the University of Louisville for their clinical assistance with this case. We would also like to acknowledge Dr. John Zone from the University of Utah for his assistance in immunological testing and interpretation of the significance of these findings.

#### Conflicts of interest

None declared.

#### REFERENCES

1. Khumalo NP, Murrell DF, Wojnarowska F, Kirtschig G. A systematic review of treatments for bullous pemphigoid. *Arch Dermatol*. 2002;138(3):385-389.
2. Hammers CM, Stanley JR. Mechanisms of disease: pemphigus and bullous pemphigoid. *Annu Rev Pathol*. 2016;11:175-197.
3. Lambadiari V, Kountouri A, Kousathana F, et al. The association of bullous pemphigoid with dipeptidyl-peptidase 4 inhibitors: a ten-year prospective observational study. *BMC Endocr Disord*. 2021;21(1):23.
4. Fukuda G, Yoshida T, Hirayama A, Umezawa Y, Takemoto M. Dulaglutide-related bullous pemphigoid in a patient with type 2 diabetes: a case report. *Geriatr Gerontol Int*. 2019; 19(12):1289-1290.
5. Saraceno R, Citarella L, Spallone G, Chimenti S. A biological approach in a patient with psoriasis and bullous pemphigoid associated with losartan therapy. *Clin Exp Dermatol*. 2008;33(2): 154-155.
6. Tasanen K, Varpuluoma O, Nishie W. Dipeptidyl peptidase-4 inhibitor-associated bullous pemphigoid. *Front Immunol*. 2019; 10:1238.
7. Leuci S, Gürcan HM, Ahmed AR. Serological studies in bullous pemphigoid: a literature review of antibody titers at presentation and in clinical remission. *Acta Derm Venereol*. 2010;90(2):115-121.
8. Yamagami J, Nakamura Y, Nagao K, et al. Vancomycin mediates IgA autoreactivity in drug-induced linear IgA bullous dermatosis. *J Invest Dermatol*. 2018;138(7):1473-1480.
9. Stavropoulos PG, Soura E, Antoniou C. Drug-induced pemphigoid: a review of the literature. *J Eur Acad Dermatol Venereol*. 2014;28(9):1133-1140.