

Modified roll technique for soft tissue augmentation in prosthetic rehabilitation: A case report

Shahabe A. Saquib,¹ Mohammed Yunis S. Bhat,¹ Mukhtar A. Javali,¹ Shaheen V. Shamsuddin,² Mohammed A. Kader³

¹Department of Periodontics and Community Dental Sciences;

²Division of Orthodontics;

³Department of Restorative Dentistry, King Khalid University, College of Dentistry, Abha. Asir, Saudi Arabia

Abstract

There are various causes for residual alveolar ridge defects, most common being the collapse of the cortical plate during extraction. Localized defects of alveolar ridge affect prosthetic restoration due to poor emergence profile of the pontic. Various soft tissue augmentation procedures have been recommended for the correction of these defects. Abrams's roll technique has been widely used for soft tissue ridge augmentation in the maxillary anterior region where aesthetics is a prime concern. The original Abrams's roll technique has been modified and revisited by many authors to overcome the limitations. The present clinical case report discusses the modified roll technique as an option to treat alveolar ridge deformity. The current procedure resulted in expectable ridge augmentation, uneventful healing, and good aesthetic outcome. Hence this modified technique can be selected for the treatment of mild to moderate Seibert class I ridge defects in the aesthetic zone.

Introduction

Localized alveolar ridge defect is common after prolonged edentulism. These defects may be caused by the deficiency in the volume of bone and soft tissue resulting from extractions, advanced periodontitis, and periapical pathologies.¹ Replacement of missing anterior maxillary tooth with ridge defect is challenging, because of the high esthetic demand in this region.² Esthetic outcome of fixed prosthesis depends on three-dimensional emergence profile of the pontic which is highly dependent on harmony between soft tissue and prosthesis. Therefore surgical or mucogingival alteration of hard tissue and soft tissue is essen-

tial in the defected area of the ridge to rehabilitate the prosthesis.³

Seibert (1983) classified these defects as follows.⁴

Class I defect: Loss of bucco-lingual dimension with normal apico-coronal dimension. Class II defect: Loss of apico-coronal dimension with normal buccolingual dimension. Class III defect: Loss of bucco-lingual and apico-coronal dimension.

Allen (1985) classified the ridge defect according to the depth of the deformity.⁵

Mild: Depth less than 3 mm; Moderate: Ranging from 3mm to 6mm; Severe: More than 6 mm. Different techniques to correct ridge deformities have been recommended in the past.⁶ Soft tissue ridge augmentation procedures include, onlay free gingival graft, connective tissue grafts, pouch graft, roll, and modified roll grafts. A free gingival graft is recognized as a predictable way of augmenting soft tissue around tooth and implant. It is most commonly done to improve esthetics in the pre-maxillary area. Free gingival graft carries the possibility of being associated with post-operative pain, hemorrhage, impaired phonetics, and function. Considering these limitations, Abrams introduces roll pedicle graft technique.⁷

The roll technique comprises of de-epithelization of palatal pedicle flap and exposure of palatal bone. This pedicle is then rolled beneath the buccal mucosa to augment the soft tissue in the bucco-lingual dimension. To avoid exposure of palatal bone, modified roll technique was altered using *trap-door* technique.⁸ The epithelium over the palatal connective tissue is raised and preserved to cover the palatal bone in this technique. This technique is recommended for augmentation of moderate defects like Seibert's Class I. It provides the advantages of increased vascular supply to the graft, color compatibility with the adjacent tissue, and single surgical exposure.

The present case report demonstrate modified rolled palatal pedicle connective tissue graft combined with immediate temporization of the area to correct the localized maxillary anterior alveolar ridge defects and to get an emergence profile for the pontic.

Case Report

A 28-year-old, systemically healthy female patient visited the outpatient department of Periodontology and Implantology, presenting Seibert class I deformity in the edentulous ridge following extraction of the maxillary left lateral incisor few years before (Figure 1). This region only requires soft tissue augmentation to correct the ridge

Correspondence: Shahabe Saquib, Department of Periodontics and Community Dental Sciences, King Khalid University, College of Dentistry, Abha. Asir, Saudi Arabia.

E-mail: sshahabe@kku.edu.sa

Key words: Connective tissue pedicle graft; Aesthetics; Localized ridge defect; Ridge augmentation; Roll technique.

Contributions: the authors contributed equally.

Conflict of interest: the authors declare no potential conflict of interest.

Funding: none.

Received for publication: 16 October 2018.

Revision received: 10 February 2019.

Accepted for publication: 19 February 2019.

This work is licensed under a Creative Commons Attribution NonCommercial 4.0 License (CC BY-NC 4.0).

©Copyright S. Saquib et al., 2019

Licensee PAGEPress, Italy

Clinics and Practice 2019; 9:1110

doi:10.4081/cp.2019.1110

defect before fabrication of fixed prosthesis, so modified pedicle roll technique was selected to augment the defect.

Informed consent was obtained from the patient following the guidelines as per Helsinki declaration. Before commencing surgical procedure, the patient was asked to rinse with 0.2% chlorhexidine mouthwash. The area was anesthetized by infiltration anesthesia, 2% lidocaine with 1:80,000 epinephrine. Number 15 surgical blade was used to make partial thickness incision at mid of the alveolar ridge in mesio-distal direction (incision A). Sharp dissection was performed on the palatal side to separate a thin layer of connective tissue and epithelium from the underlying connective tissue. The blade is carefully positioned below the soft tissue to prevent flap perforation. Underlying connective was then separated from the adjacent tissue by providing two vertical incisions at both the ends (incision B) and one incision at the apical end of the tissue (incision C) (Figure 2). A periosteal elevator was used to separate the graft from the underlying bone (Figure 3).

The buccal flap was reflected by using two releasing incisions to make space for the pedicle connective tissue graft. The connective tissue pedicle was then inverted and tucked into the buccal flap, and the flap was sutured in its original position with the help of vicryl 4-0 resorbable suture material (Figure 4). Immediate temporization was

done to get an optimum esthetic molding of the soft tissue while healing. The temporization consists of ovate pontic which was placed in contact with the soft tissue (Figure 5). Post-operative instruction, antibiotic and analgesic were prescribed to the patient to avoid any untoward event. Healing was reported to be uneventful in the first postoperative week. The patient was kept under regular follow up for one month, followed by final rehabilitation without any complication.

Discussion

The alveolar ridge defects compromise the functional and aesthetics of the normal oral tissues. The prosthetic treatment procedures in case with alveolar ridge defects cannot be carried out with optimum aesthetics because tooth to the gingival relationship is disturbed.⁹ Isolated alveolar ridge defects can be treated by two different approaches: guided bone regeneration and soft tissue grafting. The decision to select either of surgical procedure depends on the type of the defect and type of prosthetic rehabilitation. However, when the fixed partial denture is planned as an option for rehabilitation, in the majority of cases acceptable aesthetic outcome can be achieved by soft tissue correction alone.¹⁰

Free gingival Autograft is recognized for their high rate of clinical predictability, and long-term success.¹¹ Pedicle grafts have the advantage of a better blood supply that can result in rapid healing of tissue, less graft shrinkage, and higher probabilities of graft acceptance. Abrams's palatal roll technique was one of the first procedures to use the pedicle palatal connective tissue for the correction of the ridge defect.⁷ The limitations of the palatal roll technique were risk of graft necrosis and pain due to healing by secondary intention, this led many researchers to modify and revisit the technique.

Scharf and Tarnow have modified the Abrams's technique by giving a trap door incision to acquire the pedicle of connective tissue.⁸ This allowed complete closure of the palatal donor site, thereby reducing the pain and discomfort related with Abrams technique. Sclar used a *tunnel* approach to reposition a connective tissue pedicle from palate and named the procedure as "Vascularized inter-positional periosteal-connective tissue flap".¹² In the present case report modified palatal roll technique was used in combination with ovate temporization to improve the emergence profile of fixed partial denture, however similar technique has been used by Kulkarni *et al.* for

the augmentation of soft tissue around dental implant.¹³ However, in the trap-door approach, due to the placement of three incisions, there is a high chance for flap necrosis because of impaired blood supply.¹³ Moreover, a higher number of inci-

sions usually require more sutures which will have an adverse effect on the healing outcome of the flap. In the present case report single incision was adopted for obtaining connective tissue pedicle, which presents several advantages: i) It requires

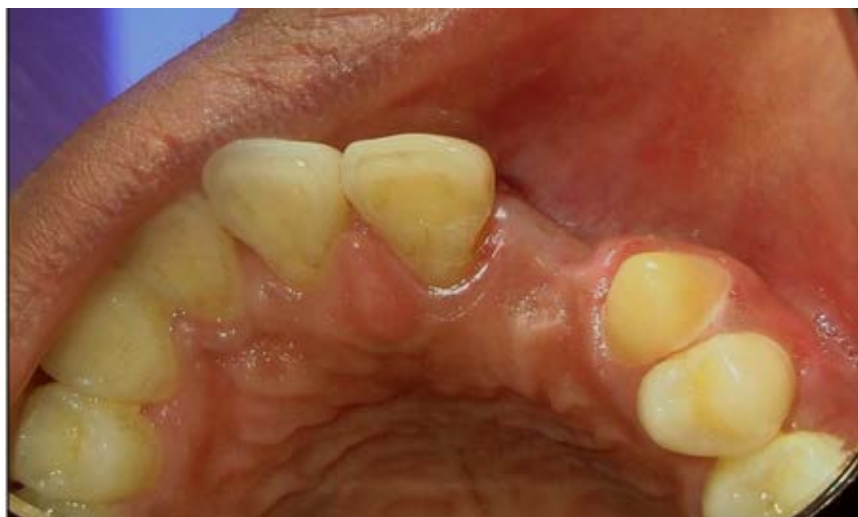

Figure 1. Seibert class I ridge defect with loss of tissue in buccolingual direction.

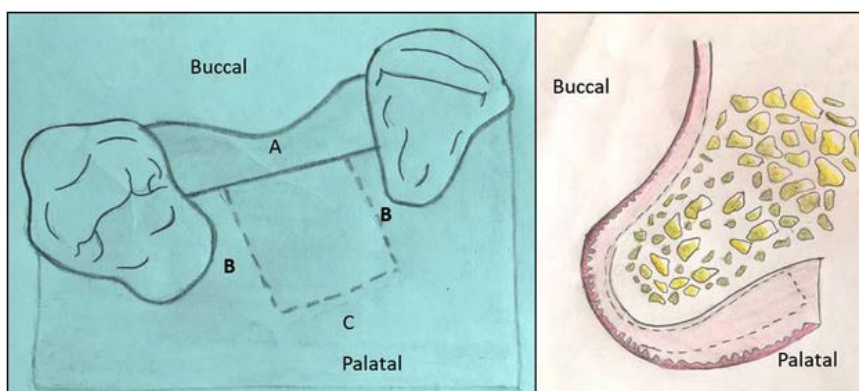


Figure 2. Design of incision and flap to harvest pedicle connective tissue graft.

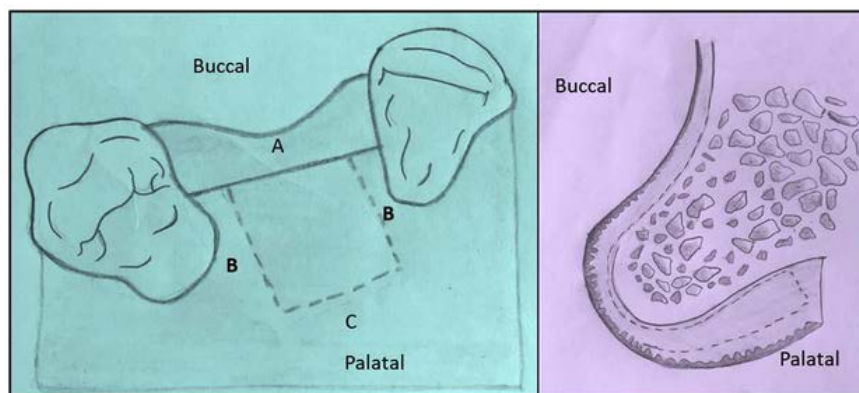


Figure 3. Pedicle soft connective tissue elevated till the level of the alveolar crest.

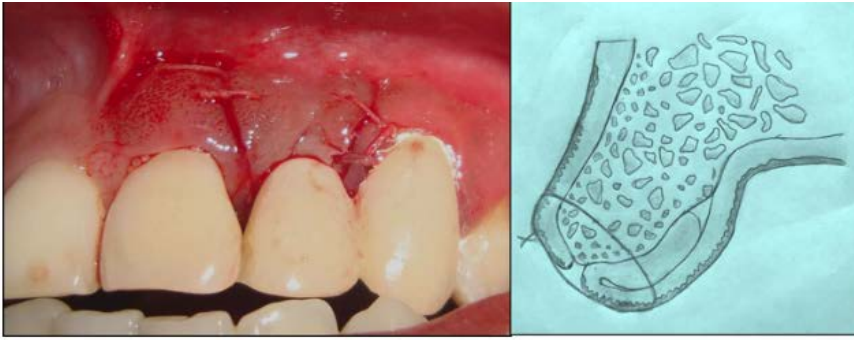


Figure 4. Flap suture with simple loop suture using 4-0 vicryl.

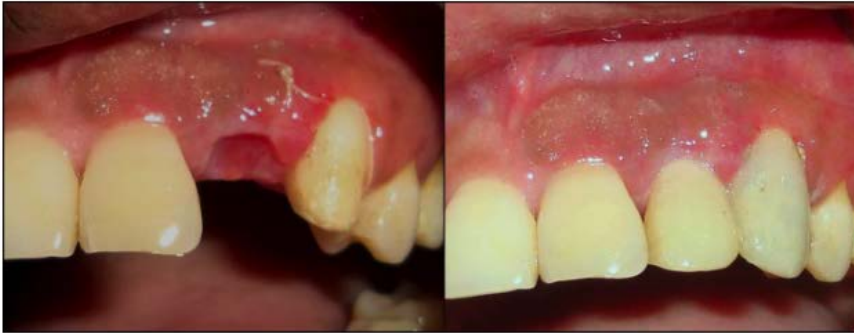

Figure 5. Temporary placed in active contact with a ridge to mold the soft tissue.

only a single horizontal incision to access underlying connective tissue; ii) maintenance of proper blood flow to the palatal graft tissue; iii) less number of sutures; iv) No need for stents on the palate; v) Healing by primary intention at donor site, which has less post-operative pain and discomfort.¹³

Conclusions

Augmentation of the lost portion of the alveolus and related soft tissue is one of the critical aspects of prosthetic rehabilitation. The technique discussed in this case report is indicated for augmentation of mild to moderate Seibert class I defects in the max-

illary anterior region. The above technique overcomes the shortcoming of the other soft tissue augmentation procedures with a better healing and stable result.

References

1. Miller PD Jr. Ridge augmentation under existing fixed prosthesis. Simplified technique. *J Periodontol* 1986;57:742-45.
2. Lewis S. Anterior single-tooth implant restorations. *Int J Periodont Restor Dent* 1995;15:30-41.
3. Askary AS. Multifaceted aspects of implants aesthetics: the anterior maxilla. *Implant Dent* 2001;101:82-91.

4. Seibert JS. Reconstruction of deformed, partially edentulous ridges, using full thickness onlay grafts. Part 1. Technique and wound healing. *Compend Cont Ed Gen Dent* 1983;4:437.
5. Allen EP, Gainza CS, Farthing GG, Newbold DA. An improved technique for localized ridge augmentation. A report of 21 cases. *J Periodontol* 1985;56:195-9.
6. Seibert JS, Salama H. Alveolar ridge preservation and reconstruction. *Periodontol* 2000 1996;11:69-84.
7. Abrams L. Augmentation of the deformed residual edentulous ridge for fixed prosthesis. *Compend Contin Educ Gen Dent* 1980;1:205-13.
8. Scharf DR, Tarnow DP. Modified roll technique for localized alveolar ridge augmentation. *Int J Periodontics Restorative Dent* 1992;12:415-25.
9. Wennstrom J, Pini Prato GP. Mucogingival therapy periodontal plastic surgery. In: Lindhe J, Karring T, Lang NP, eds. *Clinical Periodontology and Implant Dentistry*. Oxford, UK: Blackwell Munksgaard; 2003.
10. Studer S, Kadl P, Glauser R, Scharer P. Semi-quantitative short-term results of three different soft tissue augmentation procedures in multiple tooth defects. *Acta Med Dent Helv* 1998;3:68-74.
11. Harris RJ. Root coverage with connective tissue grafts: An evaluation of short- and long-term results. *J Periodontol* 2002;73:1054-9.
12. Sclar A. Vascularized interpositional periosteal – connective tissue (VIP-CT) flap. In: Sclar A, ed. *Soft Tissue and Esthetic Considerations in Implant Dentistry*. Chicago: Quintessence Publishing; 2003. pp 163-187.
13. Kulkarni MR, Bakshi VP, Kavlekar SA, Thakur LS. Applications of a modified palatal roll flap in peri-implant soft-tissue augmentation – A case series. *J Indian Soc Periodontol* 2017;21:333-6.