

Chronic Intake of Green Propolis Negatively Affecting the Rat Testis

Grasiela Dias de Campos Severi-Aguiar, Suellen Josine Pinto¹, Cristina Capucho, Camila Andrea Oliveira², Maria Aparecida Diamante, Renata Barbieri¹, Fabricia Souza Predes³, Heidi Dolder

Reproductive Biology Laboratory, Department of Structural and Functional Biology, Biology Institute, State University of Campinas – UNICAMP, Campinas, ¹Health Sciences Nucleus, Hermínio Ometto University Center, UNIARARAS, Araras, ²Graduate Program in Biomedical Sciences, Hermínio Ometto University Center, UNIARARAS, Araras, São Paulo, Brazil, ³Department of Biological Sciences, State University of Paraná (UNESPAR), Paranaguá, Paraná, Brazil

ABSTRACT

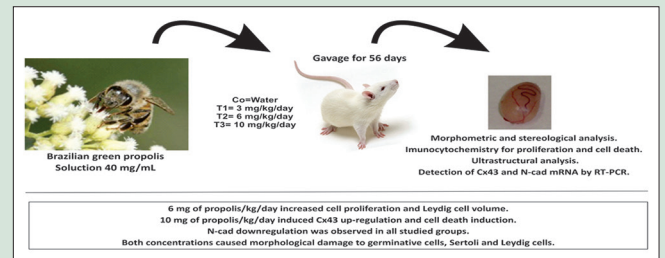
Background: Human and animal evidence suggests that environmental toxicants may have an adverse impact on male reproductive health, reducing the population's reproductive output. Owing to the renewed attraction for natural products, some of them constitute effective alternatives to mitigate these effects. Propolis is a candidate for this use because of its intrinsic properties. In many situations, it improved the testicular damage and alleviated the toxic effects induced by environmental contaminant exposure.

Objective: The aim of this study was to investigate possible alterations of testicular parameters and certify if its use is really advantageous to the testis, since this could affect rat reproductive function. **Materials and Methods:** Forty-eight adult male Wistar rats were divided into four groups (Co = control, T1 = 3 mg propolis/kg/day, T2 = 6 mg/kg/day, T3 = 10 mg/kg/day) and were exposed during 56 days. The testes were assessed with morphometrical, stereological, and ultrastructural analyses. Cell proliferation and death were diagnosed, respectively, by immunocytochemistry. Connexin 43 (Cx43) and N-cadherin transcript levels were determined by reverse transcription-polymerase chain reaction. **Results:** Increased cell proliferation and Leydig cell volume were observed in T2, and in contrast, Cx43 upregulation and cell death were observed in T3. Both T2 and T3 showed ultrastructural abnormalities in testicular parenchyma. **Conclusion:** We recommend a cautious intake of propolis to avoid deleterious effects.

Key words: Cell death and proliferation, connexin 43, morphometry, N-cadherin, stereology, ultrastructure

SUMMARY

- Chronic intake of Brazilian green propolis induced N-cadherin downregulation and decreased on seminiferous tubule volume
- Increase on connexin 43 expression and cell death and decrease in Leydig cell (LC) number/testis with the concentration of 10 mg/kg/day were observed
- Increase on cell proliferation, cytoplasmic proportion, and volume of LC with the concentration of 6 mg/kg/day was detected
- The presence of empty spaces between spermatids and malformed spermatozoa in the lumen of seminiferous tubule was showed
- This male reproductive disruption can be linked to phenolic compounds present in Brazilian green propolis.



Abbreviation Used: AEC: 3-amino-9-ethylcarbazole; AJ: Adherens junction; AME: Aromadendrin-40-methyl ether; CAPE: Caffeic acid phenethyl ester; Co: Control group; Cx43: Connexin 43; DAB: Diaminobenzidine; dNTP: Deoxyribonucleotide phosphate; DSP: Daily sperm production; FA: Ferulic acid; FSH: Follicle-stimulating hormone; GJ: Gap junction; GJIC: Gap junction intercellular communication; HPLC: High-performance liquid chromatography; LC: Leydig cell; LH: Luteinizing hormone; N-cad: N-cadherin; PCNA: Proliferating cell nuclear antigen; PCR: Polymerase chain reaction; RT-PCR: Reverse transcription-polymerase chain reaction; SDM: Standard deviation of mean; T1: Group exposed to 3 mg of propolis/kg/day; T2: Group exposed to 6 mg of propolis/kg/day; T3: Group exposed to 10 mg of propolis/kg/day; TUNEL: Terminal deoxynucleotidyl transferase-mediated dUTP nick-end labeling; WB-ras 2 cells: Ras-transferred rat liver epithelial cell line.

Correspondence:

Dr. Grasiela Dias de Campos Severi-Aguiar,
Departamento de Biologia Estrutural e Funcional,
Universidade Estadual de Campinas – UNICAMP,
CP 6109, CEP 13083-863, Campinas, São Paulo,
Brasil.
E-mail: grazielaaguiar@terra.com.br
DOI: 10.4103/0974-8490.199777

Access this article online

Website: www.phcogres.com

Quick Response Code:



INTRODUCTION

There is increasing evidence from sound epidemiological studies in humans as well as from experiments with animals, to support the claim that environmental pollutants alter the regulation of puberty in males.^[1] Pubescent development in schoolboys from an Indian village where endosulfan had been aerielly sprayed for more than 20 years was compared with the development in boys from nonsprayed areas. It was shown that development of pubic hair, testes, and penis, as well as serum testosterone level, was negatively correlated to the group exposed to aerial endosulfan exposure.^[1] The connection between reproductive disorders and environmental pollution that can lead to infertility is still a highly debated issue.^[1-4]

In recent years, the therapeutic effect of natural products has been widely used to prevent or mitigate the damage of heavy metal contamination.^[5-7]

Because of the wide range of biological activities, propolis has also been extensively used in food and beverages to improve health and fight diseases.^[8,9] *Baccharis dracunculifolia* D. C. (*Asteraceae*) is a native plant

This is an open access article distributed under the terms of the Creative Commons Attribution-NonCommercial-ShareAlike 3.0 License, which allows others to remix, tweak, and build upon the work non-commercially, as long as the author is credited and the new creations are licensed under the identical terms.

For reprints contact: reprints@medknow.com

Cite this article as: Severi-Aguiar GD, Pinto SJ, Capucho C, Oliveira CA, Diamante MA, Barbieri R, *et al.* Chronic intake of green propolis negatively affecting the rat testis. *Phcog Res* 2017;9:27-33.

from Brazil, commonly known as “Alecrim do campo” or “Vassoura” that is an ingredient of green propolis and is well known for its use by insects, mainly *Apis mellifera* L. (de Sousa *et al.*, 2011).^[10]

Yousef and Salama^[11] described increased activity of 17-ketosteroid reductase and testosterone levels in rats treated with propolis after aluminum chloride exposure. They suggested that it increased steroidogenesis, improved sperm proliferation, and hence increased fertility. Similarly, ElMazoudy *et al.*^[12] and Yousef *et al.*^[13] showed an increase in testosterone levels for rats and rabbits treated with propolis, respectively, after chlorpyrifos and triphenyltin exposure. Capucho *et al.*^[14] showed that animals chronically treated with Brazilian green propolis presented higher sperm production and greater epithelium height of the epididymis initial segment.

These data point toward propolis being able to alter reproductive parameters, increasing steroidogenesis, and sperm production and suggest that this natural product could promote better male reproductive performance.

This study was designed based on the hypothesis that properties of Brazilian green propolis might be related to its ability to restore reproductive capacity. However, if propolis is able to do this, it may also be able to alter reproductive parameters. Hence, it can be asked: Which cellular mechanisms are involved in its action mode? Because there is a little information about testicular changes after chronic propolis intake, we looked for biomarkers to evaluate testicular morphological and molecular events.

Therefore, the aim of this study was to evaluate effects of propolis on morphological and molecular parameters of rat testis through morphometrical, stereological, ultrastructural, and immunocytochemical analyses. We also quantified cell proliferation and cell death with immunocytochemical assays, using, respectively, positive labeling for proliferating cell nuclear antigen (PCNA) and the terminal deoxynucleotidyl transferase-mediated dUTP nick-end labeling (TUNEL) method. Connexin 43, connexin 43 (*Cx43*) and N-cadherin (*N-cad*) mRNA levels were determined by reverse transcription-polymerase chain reaction (RT-PCR).^[15-18]

Another relevant aspect pointed by Sforcin^[9] was that propolis extracts have been used deliberately for a long time. Propolis-containing products present different recommendations according to the producers or sellers, not always mentioning the chemical composition, botanical source, and the methods of extraction. In addition, recommendations should include defined concentrations, doses, and consumption period, in view of the expected outcomes.

In this context, the understanding of the action mechanisms could help to establish an ideal dose and intake period that would ensure its beneficial activity on reproduction and avoid deleterious effects on the testis.

MATERIALS AND METHODS

Subjects of research

Forty-eight adult male Wistar rats (*Rattus norvegicus*) (90 days) were maintained throughout the experiment at the Animal Experimentation Center, Centro Universitário Hermínio Ometto (UNIARARAS) (3 animals/cage), on a 12-h light/dark cycle at a temperature of 25°C and 60% air humidity. The animals received water and Purina standard chow, *ad libitum*. The animals were randomly divided into four groups ($n = 12$): A control group (Co) receiving only filtered water and three experimental groups T1, T2, and T3 exposed to 3, 6, and 10 mg/kg/day, respectively, of the aqueous propolis extract. The study was approved by the Ethics Committee of Centro Universitário Hermínio Ometto, UNIARARAS (protocol 860/2009), and was conducted in

accordance with the ethical guidelines of the Brazilian College of Animal Experimentation (COBEA).

Substance tested

Green propolis extract was obtained according to Sforcin *et al.*^[19] and Pagliarone *et al.*^[20] Propolis was produced by *A. mellifera* L. bees in the apiary located in Araras city (region of Campinas, SP, Brazil) and harvested using plastic nets in February 2010. Green propolis was ground and prepared under sterile conditions according to Capucho *et al.*^[14] Its composition depends on its plant source, but high-performance liquid chromatography analysis detected seven phenolic compounds in propolis including caffeic acid phenethyl ester (CAPE), ferulic acid (FA), aromadendrin-40-methyl ether, isosakuranetin, artepillin C, baccarin, and 2-dimethyl-6-carboxyethenyl-2H-1-benzopyran acid (de Souza *et al.*, 2011; Abdallah *et al.*, 2012).^[10] To obtain good qualitative and quantitative results for these phenolic compounds, the best time for harvesting this plant is between December and April (de Souza *et al.*, 2011)^[10] although Sforcin^[9,21] has demonstrated that no seasonal effect was noted for Brazilian propolis composition and variations were predominantly quantitative throughout the year.

Doses and administration route

The animals were weighed and received Brazilian green propolis, by gavage, for 56 days, which is the period necessary to complete a spermatogenic cycle.^[22] Water or subacute doses of 3, 6, and 10 mg/kg/day (LD50 is 2–7.3 g/kg in mice) were applied according to previous data in literature.^[14,23] According to Burdock,^[24] multiple doses between 200 and 5000 mg/kg body weight/day did not cause deaths in laboratory animals. Applying the safety factor of 1000 for humans, the calculated safe dose would be 1.4 mg/kg body weight/day or approximately 70 mg/day. The animals received ketamine (70 mg/BW) and xylazine (10 mg/BW) before euthanasia.

Tissue preparation

Six animals of different exposed groups (24) were perfused with glutaraldehyde 4% and paraformaldehyde 4% in sodium cacodylate buffer 0.1 M (pH 7.2) for 25–30 min. Testis was removed, post-fixed in 1% osmium in the same buffer solution, overnight, and then weighed. Histo-resin (Leica) embedded testes fragments were sectioned at 3 μ m thickness and stained with toluidine blue in 1% sodium borate (TB) for structural and morphometrical evaluations.

Morphometry and stereology

The weight of the testicular parenchyma was obtained subtracting the mass occupied by the albuginea from the total right testis weight, thus providing the net weight of the organ's functional portion. Representative areas of testicular tissue were photographed with a Leica DM2000 microscope and subjected to morphometrical and stereological analyses with an imaging system Pro-Plus software version 4.5 (Media Cybernetics). The seminiferous tubule epithelium height and tubule diameter were measured in 15 tubules per animal at $\times 200$ magnification.^[22] The stereological analysis of the testis was made for 15 random testis cross-sections per animal. This analysis was performed with a 494-point grid to determine the proportion of the testis components (epithelium, lumen, and interstitium) in the experimental groups.

The volumetric proportions of the Leydig cells (LCs) were assessed using a grid mask of 494 points placed over microscope fields for each animal at $\times 1000$ magnification, counting points over nucleus and cytoplasm until completing 1000 points per animal. The volumetric proportions of the intertubular space components (lymphatic space, connective

tissue, blood vessels, macrophages, and LCs) were assessed using a grid mask of 494 points placed over microscope fields for each animal at $\times 1000$ magnification, until completing 3000 points per animal. The volume, expressed in milliliter, of each component described above was determined as the product of the testicular volume and volumetric proportions. Since the specific gravity of the testis is nearly 1.0, its volume was considered the same as its weight.^[25] To obtain a more precise liquid testis volume, 6.5% of its weight, relative to the tunica albuginea, was excluded from this organ's weight.^[22]

The proportion between nucleus and cytoplasm of LCs was assessed using a grid mask with 494 points placed over images at $\times 1000$ magnification. One thousand points over nuclei and cytoplasm of LCs was counted per animal. The nuclear diameter of LCs was obtained assessing 30 nuclei/animal. The nuclear volume was calculated and the individual volume of LCs was obtained from the nuclear volume and the proportion between nucleus and cytoplasm. The number of LCs per testis was obtained dividing the total nuclear volume of these cells by the average individual nuclear volume.^[25]

Immunocytochemistry for cell death and proliferation

Paraffin-embedded 5 μm thick testis sections were submitted to immunodetection of DNA fragmentation, indicative of cell death using the ApopTag Plus kit (Chemicon Int., Temecula, CA, USA) and *in situ* Cell Death Detection kit (ISCCDK, Roche, Germany) according to the manufacturer's instructions. Both kits use antiluorescein peroxidase-conjugated antibody and diaminobenzidine for the development of the reaction. The positive control of the kit was used and the negative control (reaction control) consisted of omission of the TUNEL reaction enzyme.

For PCNA detection, testicular sections were incubated with the primary antibody (anti-PCNA polyclonal rabbit antibody; Abcam, Cambridge, MA, USA – ab2426) (1:1000) at 37°C for 1 h and they were incubated with the secondary antibody (goat anti-rabbit IgG polyclonal secondary antibody HRP; Abcam, Cambridge, MA, USA – ab97200) (1:1000) for 2 h at room temperature in a dark chamber. Immunostaining was visualized using 0.05% (w/v) 3-amino-9-ethylcarbazole (Sigma-Aldrich, USA – a6926) in PBS and 0.01% (v/v) hydrogen peroxide. PCNA-labeled cells and TUNEL positive nuclei were identified by brown nuclear staining and counted.^[17,26] Four slides per animal were mounted with six cross-sections at different depths and 15 aleatory fields were obtained per animal ($\times 40$ objective lens), where positive nuclei were counted in tubular epithelium.

Transmission electron microscopy

After whole-body perfusion fixation, the specimen fragments were fixed in the same fixative for 24 h. Then, the specimens were rinsed 3 times with 0.1 M sodium phosphate buffer, pH 7.2, post-fixed in 1% osmium tetroxide, rinsed and dehydrated in an increasing acetone series, and embedded in epoxy resin. Ultrathin sections were cut and contrasted with 2% uranyl acetate and 2% lead citrate before observation with a transmission electron microscope (Zeiss, Leo906).

Detection of connexin 43 and N-cadherin mRNA by reverse transcription-polymerase chain reaction

Total RNA was isolated from 100 mg testicular parenchyma of six animals of each group that was not perfused (totalizing 24) with the TRIzol[®] reagent (Invitrogen, Carlsbad, CA, USA), including the digestion of contaminating DNA with DNase I, amplification grade (Invitrogen), following the manufacturers' instructions. RNA purity and concentration

were determined spectrophotometrically. cDNA was synthesized from 2 μg RNA in the presence of dithiothreitol, deoxyribonucleotide phosphate, random primers, RNaseOUT, and SuperScript[™] II Reverse Transcriptase (Invitrogen) in a final volume of 20 μl . Semiquantitative RT-PCR was used to amplify *Cx43* and *N-cad* mRNA and to compare their expression for three experimental groups exposed to the aqueous extract of propolis and the control group.

The PCR conditions were performed as reported previously by Gagliano *et al.*^[27] The signal intensities of the bands were measured densitometrically using the Scion Image analysis software (Scion Corp., Frederick, MD, USA). Each value was determined as the mean of three densitometric readings. The results were expressed as average ratios of the relative expression of transcripts normalized with β -actin as the control housekeeping gene.

Statistical analysis

Comparison of the values of control and treated groups was carried out by statistical variance analysis (one-way ANOVA), followed by Tukey's test. A value of $P < 0.05$ was considered statistically significant. For all values, the standard deviation mean (means \pm) was calculated.

RESULTS

Morphometry and stereology

According to the data presented in Table 1, lumen proportion of seminiferous tubules decreased significantly and the interstitium proportion showed a significant increase in the T3 group. Epithelium proportion increased significantly in T1 group. All exposed groups showed a significant decrease in seminiferous tubule volume, and T3 group showed reduced length. No significant alteration was observed in the interstitium component proportion when compared with the control group. However, major alterations were observed in LCs.

All treated groups presented a significant decrease in LC nuclear proportion and a significant increase in LC cytoplasmic proportion and volume when compared to the control group. LC nuclear volume was significantly increased in T3. LC volume was significantly increased in T2 and T3 groups and LC number showed a significant decrease in T3 group.

Immunocytochemistry for cell death and proliferation

Results showed no significant difference in the number of positive labeling both for cell death and proliferation [Figure 1] in all groups studied. This fact probably occurred because, among the values obtained, there are some that deviate from the average (1.41–9.7) reaching the extremities. However, an evident tendency toward cell proliferation induction can be observed at the dose of 6 mg/kg/day. Cell proliferation decreases at the highest concentration (10 mg/kg/day), and in contrast, cell death induction occurred.

Ultrastructural analysis

Ultrastructure of the control animals showed healthy Sertoli cells with large oval nuclei. Sertoli cells' cytoplasm extends from the basal lamina to the lumen of the seminiferous tubules, enveloping the adjacent germinal cells. There were numerous lipid droplets in the cytoplasm of the Sertoli cells [Figure 2a]. After propolis exposure, we can observe a dose-dependent increase in lipid content and endoplasmic reticulum swelling with the presence of an electron-dense content [Figure 3a and b]. Damage to the blood–testis barrier can be observed [Figure 3b].

A large number of spermatocytes and round spermatids occurred near the lumen of the seminiferous tubules in the control group [Figure 2b].

Table 1: Testicular morphometry and stereology of adult rats exposed to Brazilian green propolis (mean±standard deviation)

Parameters	Experimental groups			
	Co	T1	T2	T3
Epithelium (%)	71.97±1.19	74.96±2.18*	72.67±4.24	72.18±1.21*
Lumen (%)	11.89±1.60	10.15±1.42	13.10±4.68	7.71±2.63***
Interstitial (%)	16.14±2.14	14.89±2.19	14.24±2.43	20.11±1.94*#**
LC (%)	25.04±3.33	27.91±3.97	29.14±2.77	26.12±3.36
Macrophage (%)	6.86±3.79	8.10±2.43	6.57±1.43	8.70±2.32
Blood vessel (%)	16.36±9.32	21.87±2.48	14.36±1.75	13.28±3.95*
Lymphatic space (%)	46.10±6.98	37.38±7.96	41.59±3.74	47.01±5.00
Connective tissue (%)	5.65±3.63	3.52±2.43	8.75±2.49 ^f	4.90±4.02
Tubule diameter (µm)	246.42±35.01	235.72±44.96	244.82±39.70	262.85±27.74
Epithelium height (µm)	97.78±5.67	96.26±4.92	93.31±10.43	97.01±7.90
Tubule volume (mL)	1.36±0.03	1.28±0.03*	1.27±0.03*	0.95±0.02*#**
Tubule length/testis (m)	30.44±11.21	32.00±11.74	28.72±9.75	18.04±4.04*#**
Tubule length/g testis (m)	18.79±6.92	21.33±7.83	19.54±6.63	15.16±3.39
LC nuclear proportion (%)	36.17±4.24	27.47±1.69*	26.57±0.93*	27.03±2.43*
LC cytoplasmic proportion (%)	63.83±4.24	72.53±1.69*	73.43±0.93*	72.97±2.43*
LC nuclear diameter (µm)	7.45±0.32	7.38±0.56	7.26±0.46	8.14±0.48*#**
LC nuclear volume (µm ³)	217.37±26.42	213.53±49.69	201.87±34.56	284.56±51.47*#**
LC cytoplasmic volume (µm ³)	386.95±66.08	565.26±132.64*	560.37±107.52*	773.35±156.47*#**
LC volume (µm ³)	604.32±76.58	778.80±180.68	762.23±141.36*	1057.91±199.61*#**
LC number/testis	4.2E ⁺⁸ ±8.2	3.8E ⁺⁸ ±1.1	3.9E ⁺⁸ ±8.1	2.5E ⁺⁸ ±6.5*#**

*Significant difference only from the control group; *Significant difference from the T1 group; **Significant difference from the T2 group. Co: Control;

T1: 3 mg/kg/dia; T2: 6 mg/kg/dia; T3: 10 mg/kg/day of propolis; LC: Leydig cell

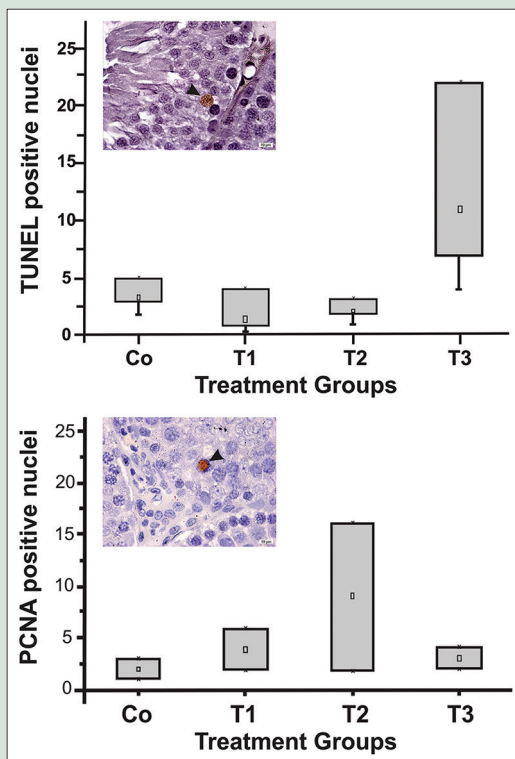


Figure 1: Testicular cross-sections submitted to terminal deoxynucleotidyl transferase-mediated dUTP nick-end labeling method and proliferating cell nuclear antigen labeling showing positive nuclei in brown (arrowhead) and a number of positive nuclei in all groups studied

The spermatocytes were round with prominent nuclei. The nuclei had a distinct chromatin network and well-defined nuclear membranes. Characteristic of the round spermatids is the well-defined nuclei with distinct nuclear membranes and filamentous chromatin and their cytoplasm occupied by a large number of mitochondria. The formation

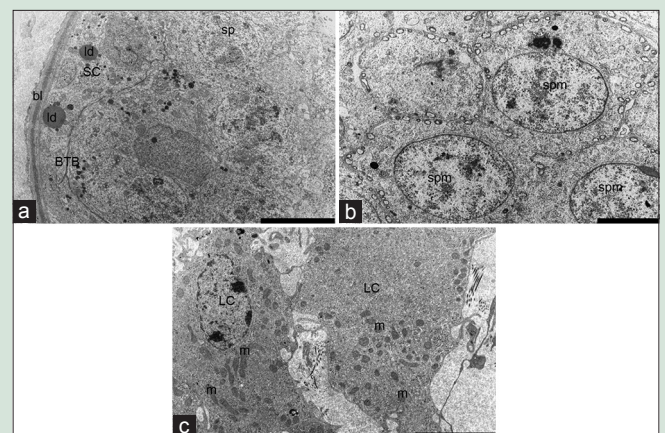


Figure 2: Ultrathin testicular sections of the control animals analyzed by transmission electron microscopy. Sertoli cell supported by a basal lamina. Numerous lipid droplets, endoplasmic reticulum swelling, and electron dense materials are observed in the cytoplasm of the Sertoli cells (a). Spermatocytes and round spermatids at seminiferous tubules are closely linked (b). Leydig cells in the testes of the control group showed lipid droplets, mitochondria, and Golgi apparatus (3c). Barr = 10 µm (a), 5 µm (b and c). SC: Sertoli cell; bl: Basal lamina; ld: Lipid droplets; ER: Endoplasmic reticulum swelling; dm: Dense materials; sp: Spermatocytes; spm: Spermatids; mi: Mitochondria; GA: Golgi apparatus

of the acrosome with a marked presence of Golgi vesicles appeared normal [Figure 2b]. Empty spaces between Sertoli cells and spermatids were clearly visible after propolis exposure [Figure 3c]. Electron micrographs showed deformed elongating spermatids undergoing phagocytosis by Sertoli cells, which resulted in engulfed spermatids and many residual bodies in the cytoplasm of Sertoli cells [Figure 3d]. The seminiferous tubule lumen contains spermatozoa with accumulated cytoplasm [Figure 3d] and head and tail abnormalities [Figure 3d].

LCs in the testes of the control group showed normal ultrastructure with intact nuclei and varied numbers of lipid droplets and organelles,

many mitochondria and a Golgi complex [Figure 2c]. Their nuclear and cytoplasmic volumes increased in the exposure groups, and both cytoplasm and nucleus were denser [Figure 3e and f].

connexin 43 and N-cadherin mRNA level in testicular tissue

To investigate whether there was a difference in the modulation of *Cx43* and *N-cad* in rat testis treated with different concentrations of Brazilian green propolis, the mRNA expression of these genes was detected by RT-PCR. As shown in Figure 4, the RT-PCR assay showed a significant increase in the expression of *Cx43* transcripts in T3 as compared to the control group. In contrast, *N-cad* transcript levels decreased significantly in all exposed groups.

DISCUSSION

Researchers demonstrated an increase in testosterone levels for rats and rabbits treated with propolis after xenobiotic exposure.^[11-13] This effect raises the following question: If propolis is able to improve androgen secretion, would it cause any deleterious effect on the testis?

To answer this question, it is necessary to understand the action mechanism of propolis in the testis. In this respect, our study constitutes an important tool to clarify cellular responses that occur in testicular parenchyma, highlighting the importance of basic cell biology in developing an integrated approach to clinical application.

In the present study, we reported that chronic intake of propolis really affects testicular homeostasis. If so, what is the underlying mechanism?

Our study demonstrated, for the 1st time, that chronic propolis intake with the concentration of 10 mg/kg/day increased *Cx43* expression in the T3 group that could lead to testicular cell death.^[28] Kameritsch *et al.* showed that *Cx* expression enhances apoptosis induction and suggested that this effect is due to the transfer of proapoptotic signals, which corroborates our results.

Apoptosis is a natural event during spermatogenesis. It selectively removes the dysfunctioning or excess germ cells and limits germ cell number to ensure that the fixed number of Sertoli cells can provide enough nutrients to nurture and substantiate the continuous germ cell generations.^[29] Spermatogenesis is a process depending on the presence of gap junction (GJ) channels between testicular cells, mainly between LCs, between Sertoli cells, and between Sertoli and germ cells.^[16]

According to Kidder and Cyr,^[30] GJ intercellular communication (GJIC) within the testis and epididymis represents a critical aspect of male reproductive function and fertility. The implications of this mode of intercellular communication for male fertility remain a poorly understood but important facet of male reproduction.

Connexins are transmembrane proteins that participate in GJs and that reside in lipid raft domains of the plasma membrane and function in this lipid environment.^[31] *Cx43* is the most highly expressed *Cx* during spermatogenesis.^[16] In contrast, reduction in *Cx43* expression and disruption of GJ were observed in various cancers and after toxicant exposures.^[17,31,32] Kidder and Cyr^[30] pointed *Cx43* as a target of environmental toxicants.

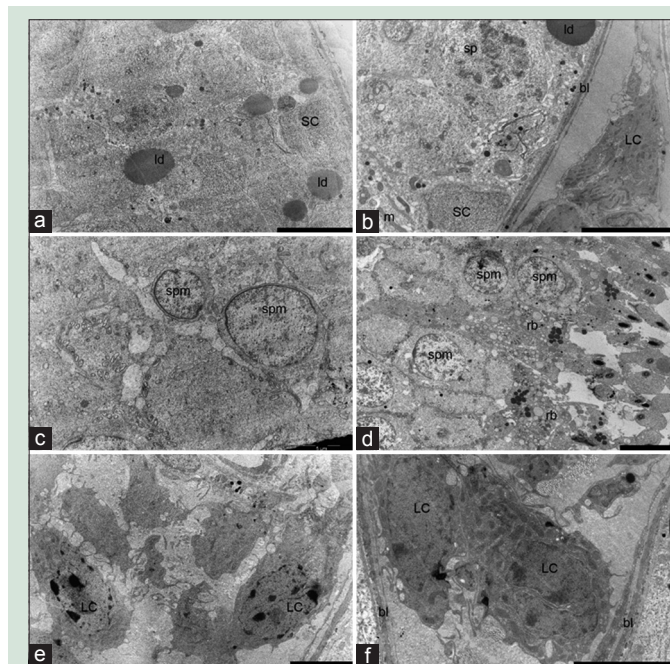


Figure 3: Ultrathin testicular sections of the exposed groups analyzed by transmission electron microscopy. Sertoli cell supported by a basal lamina. Numerous lipid droplets, endoplasmic reticulum swelling, and electron-dense materials are observed in the cytoplasm of the Sertoli cells (a and b). Damage to the structure of the blood–testis barrier can be observed in T3 (b), empty spaces between Sertoli cells and spermatids were clearly visible after propolis exposure (c and d). Residual bodies in the cytoplasm of Sertoli cells (d). Spermatozoa with accumulated cytoplasm (d) and head and tail abnormalities (d). Barr = 10 μ m (a and d), 5 μ m (b, c, and e), 2 μ m (f). SC: Sertoli cell; bl: Basal lamina; ld: Lipid droplets; ER: Endoplasmic reticulum swelling; dm: Dense materials; BTB: Blood–testis barrier; rb: Residual bodies; ac: Accumulated cytoplasm

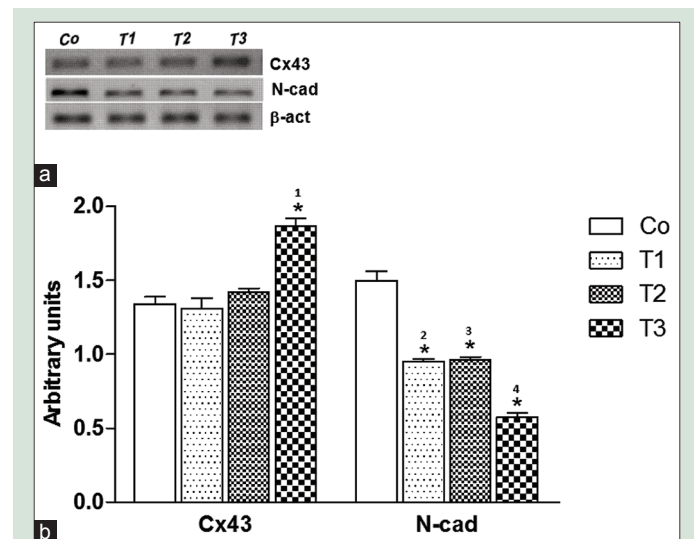


Figure 4: Analysis of mRNA expression by semiquantitative reverse transcriptase-polymerase chain reaction. (a) Bars represent densitometric analysis of connexin 43 and N-cadherin mRNA expression in control and exposed animals. (b) Changes in mRNA are expressed as normalized densitometric units relative to β -actin mRNA. Values are the mean \pm standard error of mean $P < 0.05$ indicates statistical significance. Transcriptional levels obtained by semiquantitative reverse transcription polymerase chain reaction are shown in electrophoretic images. (*) Significant difference from the control group (*1 = 0.0001, *2 = 0.0011, *3 = 0.0107, *4 = 0.021, *5 = 0.0038, *6 = 0.0047, *7 = 0.0142 and *8 = 0.0058); (#) significant difference from the T1 group (#1 = 0.002, #2 = 0.0077, #3 = 0.0075, #4 = 0.048). Co = control; T1 = 6 mg/kg/day; T2 = 10 mg/kg/day, T3 = 15 mg/kg/day

Wang *et al.*^[31] claimed that the exploration of drugs to increase GJ would be of considerable value for the treatment of tumors. We pointed out that the higher concentration of propolis (10 mg/kg/day) increased *Cx43* expression and cell death in the testis. This mechanism could avoid tumorigenesis.

Another cell junction protein that we analyzed, the *N-cad*, is implicated in various aspects of tumorigenesis including tumor cell survival, migration, and invasion. *N-cad* upregulation has been observed in many cancers.^[32] After propolis intake, we demonstrated *N-cad* downregulation.

This protein belongs to the cadherin superfamily, one of the pivotal members of the adhesion junction; it mediates calcium-dependent homotypic intercellular adhesion and has been widely associated with spermatogenesis impairment in mice and rats.^[17] Upregulation of the expression of *N-cad* was reported in response to cellular stress after phthalate exposure and neonatal exposure to bisphenol A.^[17] As hypothesized by Domke *et al.*^[33] in the seminiferous tubules, *N-cad* has an additional developmental biological role in topogenesis and specific cell–cell interactions. This includes the local stabilization of other cell–cell connection structures as has been proposed for certain synapses. Thus, it is probable that the propolis-induced mechanism to diminish *N-cad* expression would initially maintain the ideal microenvironment to guarantee the spermatogenic process. However, with a further decrease of *N-cad*, this could affect the hematotesticular barrier, or the junctions between Sertoli cell prolongations that penetrate between the germ cells, leading to their regression leaving the empty spaces observed ultrastructurally between spermatids. Corroborating our supposition, there is a study developed by Bremmer *et al.*^[34] which showed an increase of *N-cad* protein expression in LC tumors, suggesting that *N-cad* could play a role in the pathogenesis of this tumor.

However, all mechanisms activated by cells were not sufficient to avoid cellular damage. Round spermatids, released from Sertoli cells prolongations and malformed spermatozoa, were observed in the lumen although we have already demonstrated an increase of daily sperm production (DSP).^[14] LCs also were affected. These results are in contrast with other studies^[11-13] where propolis was advantageous.

Capucho *et al.*^[14] showed increased epithelium height for the initial caput segment at a dose of 10 mg/kg/day of propolis and suggested that it would be a compensatory response to help prevent tissue damage and to maintain the morphological and functional integrity of the organ and the spermatozoa. They hypothesized that the epithelium cells increase their secretion of molecules or their endocytic activity. Our results corroborated this hypothesis when malformed spermatozoa were observed arriving at the epididymis with a still uncompleted maturation process.

To understand our results, it is necessary to take into account that we used Brazilian green propolis and to review some aspects of propolis composition, mentioned in the Material and Methods section. This information is vital to further understand the role of propolis in testicular function. FA (4-hydroxy-3-methoxycinnamic acid) is a ubiquitous phenolic compound that is a bioactive ingredient of many foods as well as in propolis. Recently, a study developed by Roy *et al.*^[35] investigated the effect of FA (50 mg/kg – alternate-day administration) on postdiabetic rat testicular damage and provided evidence that FA reduced oxidative stress, proinflammatory cytokines, and apoptosis in the testes, among others parameters, and upregulated serum testosterone, contributing to its protective effects on postdiabetic complications, such as infertility. They suggested that FA inhibits testicular damage in rats by diminishing oxidative stress since its antioxidant properties are well known. However, it is known that antioxidant compounds can develop pro-oxidant activity when used for a long period and/or in high doses.^[36] This event could be responsible for our results.

A study developed by Park and Han^[37] showed that leaves and tubers of *Smallanthus sonchifolius* (Yacon, *Asteraceae*), which are rich in antioxidant compounds such as FA and CAPE, increased sperm number and serum testosterone level in rats, similarly to described for propolis.

Another plant polyphenolic compound present in propolis, CAPE, is known as an antioxidant, anti-inflammatory, antitumor, and antimetastatic agent.^[38] A study presented by Abdallah *et al.*^[38] showed CAPE alleviated the detrimental effect of pyrethroid insecticide on testicular histopathological alterations, semen quality, and antioxidant enzyme activities in the rat testis.

There is some evidence linking CAPE action and the results of the present study. First, Na *et al.*^[39] showed that CAPE restored GJ, phosphorylation of *Cx43*, and its normal location on the plasma membrane in WB-ras 2 cells (ras-transformed rat liver epithelial cell line). Second, Chen *et al.*^[40] showed that CAPE quickly entered leukemic cells and caused glutathione depletion, mitochondrial dysfunction, and caspase-3 activation and could inhibit the growth of human cancer. Thus, we suggest that CAPE could be responsible for effects induced by propolis intake at 10 mg/kg/day, such as *Cx43* upregulation, cell death induction, and reduced cell proliferation.

Another possibility to be considered is that flavonoids can increase the GJIC through the alteration of connexin protein expression. This hypothesis is in agreement with Yu *et al.*^[41] data. They demonstrated that flavonoids extracted from *litsea coreana* level which is a traditional Chinese medicine caused an increase of oxaliplatin cytotoxicity, inducing cell death and apoptosis, by enhancing GJIC through elevated *Cx43* protein expression. Subsequent studies are necessary to confirm this possibility.

CONCLUSION

Results reported herein indicate that chronic Brazilian green propolis intake during 56 days displayed different cellular events according to propolis concentration, demonstrating a dose-dependent response mechanism. Six milligrams of propolis/kg/day increased cell proliferation and LC volume, probably leading to increased DSP. On the other hand, 10 mg of propolis/kg/day induced *Cx43* upregulation and cell death induction. Both concentrations caused morphological damage to germ cells, Sertoli cells, and LCs. Our data raise the concern that male reproductive homeostasis was altered in spite of other beneficial effects of propolis. Further studies are needed to fully understand the effects of Brazilian green propolis on the reproductive system and to the establishment of an ideal dose and intake period that would ensure its beneficial activity but avoid any deleterious effect.

Acknowledgment

We thank Fundação Hermínio Ometto for financial support, Prof. Dra. Fernanda O. G. de Gaspi for providing the Brazilian green propolis extract, and Prof. Franco D. C. Pereira for compiling the images.

Financial support and sponsorship

This work was supported by the Fundação Hermínio Ometto and PIBIC/CNPq.

Conflicts of interest

There are no conflicts of interest.

REFERENCES

- Magnusson U, Ljungvall K. Environmental pollutants and dysregulation of male puberty – A comparison among species. *Reprod Toxicol* 2014;44:23-32.
- Meeker JD. Exposure to environmental endocrine disruptors and child development. *Arch Pediatr Adolesc Med* 2012;166:952-8.
- Emeville E, Giton F, Giusti A, Oliva A, Fiet J, Thomé JP, *et al.* Persistent

- organochlorine pollutants with endocrine activity and blood steroid hormone levels in middle-aged men. *PLoS One* 2013;8:e66460.
4. Zawatski W, Lee MM. Male pubertal development: Are endocrine-disrupting compounds shifting the norms? *J Endocrinol* 2013;218:R1-12.
 5. Monteiro JC, Predes FS, Matta SL, Dolder H. Heteropterys aphrodisiaca infusion reduces the collateral effects of cyclosporine A on the testis. *Anat Rec (Hoboken)* 2008;291:809-17.
 6. Leite RP, Wada RS, Monteiro JC, Predes FS, Dolder H. Protective effect of Guaraná (*Paullinia cupana* var. *sorbilis*) pre-treatment on cadmium-induced damages in adult Wistar testis. *Biol Trace Elem Res* 2011;141:262-74.
 7. Leite RP, Predes FS, Monteiro JC, Freitas KM, Wada RS, Dolder H. Advantage of Guaraná (*Paullinia cupana* Mart.) supplementation on cadmium-induced damages in testis of adult Wistar rats. *Toxicol Pathol* 2013;41:73-9.
 8. Franchi GC Jr., Moraes CS, Toreti VC, Daugsch A, Nowill AE, Park YK. Comparison of effects of the ethanolic extracts of Brazilian propolis on human leukemic cells as assessed with the MTT assay. *Evid Based Complement Alternat Med* 2012;2012:918956.
 9. Sforcin JM. Biological properties and therapeutic applications of propolis. *Phytother Res* 2016;30:894-905.
 10. de Sousa JP, Leite MF, Jorge RF, Resende DO, da Silva Filho AA, Furtado NA, *et al.* Seasonality role on the phenolics from cultivated *Baccharis dracunculifolia*. *Evid Based Complement Alternat Med* 2011;2011:464289.
 11. Yousef MI, Salama AF. Propolis protection from reproductive toxicity caused by aluminium chloride in male rats. *Food Chem Toxicol* 2009;47:1168-75.
 12. ElMazoudy RH, Attia AA, El-Shenawy NS. Protective role of propolis against reproductive toxicity of chlorpyrifos in male rats. *Pestic Biochem Physiol* 2011;101:175-81.
 13. Yousef MI, Kamel KI, Hassan MS, El-Morsy AM. Protective role of propolis against reproductive toxicity of triphenyltin in male rabbits. *Food Chem Toxicol* 2010;48:1846-52.
 14. Capucho C, Sette R, de Souza Predes F, de Castro Monteiro J, Pigoso AA, Barbieri R, *et al.* Green Brazilian propolis effects on sperm count and epididymis morphology and oxidative stress. *Food Chem Toxicol* 2012;50:3956-62.
 15. Elkin ND, Piner JA, Sharpe RM. Toxicant-induced leakage of germ cell-specific barrier from seminiferous tubules in the rat: Relationship to blood-testis barrier integrity and prospects for biomonitoring. *Toxicol Sci* 2010;117:439-48.
 16. Gilleron J, Carette D, Durand P, Pointis G, Segretain D. Connexin 43 a potential regulator of cell proliferation and apoptosis within the seminiferous epithelium. *Int J Biochem Cell Biol* 2009;41:1381-90.
 17. Salian S, Doshi T, Vanage G. Neonatal exposure of male rats to Bisphenol A impairs fertility and expression of sertoli cell junctional proteins in the testis. *Toxicology* 2009;265:56-67.
 18. Kahiri CN, Khalil MW, Tekpetey F, Kidder GM. Leydig cell function in mice lacking connexin43. *Reproduction* 2006;132:607-16.
 19. Sforcin JM, Fernandes A Jr, Lopes CA, Bankova V, Funari SR. Seasonal effect on Brazilian propolis antibacterial activity. *J Ethnopharmacol* 2000;73:243-9.
 20. Pagliarone AC, Orsatti CL, Búfalo MC, Missima F, Bachiega TF, Júnior JP, *et al.* Propolis effects on pro-inflammatory cytokine production and Toll-like receptor 2 and 4 expression in stressed mice. *Int Immunopharmacol* 2009;9:1352-6.
 21. Sforcin JM. Propolis and the immune system: A review. *J Ethnopharmacol* 2007;113:1-14.
 22. Russell LD, Ettl RA, SinhaHilin AP, Clegg ED. Mammalian spermatogenesis. In: Russel LD, Griswold, MD, editors. *Histological and Histopathological Evaluation of the Testis*. Clearwater: Cache River Press; 1990. p. 1-38.
 23. Mani F, Damasceno HC, Novelli EL, Martins EA, Sforcin JM. Propolis: Effect of different concentrations, extracts and intake period on seric biochemical variables. *J Ethnopharmacol* 2006;105:95-8.
 24. Burdock GA. Review of the biological properties and toxicity of bee propolis (propolis). *Food Chem Toxicol* 1998;36:347-63.
 25. Mori H, Christensen AK. Morphometric analysis of Leydig cells in the normal rat testis. *J Cell Biol* 1980;84:340-54.
 26. Huo S, Xu Z, Zhang X, Zhang J, Cui S. Testicular denervation in prepuberty rat inhibits seminiferous tubule development and spermatogenesis. *J Reprod Dev* 2010;56:370-8.
 27. Gagliano N, Donne ID, Torri C, Migliori M, Grizzi F, Milzani A, *et al.* Early cytotoxic effects of ochratoxin A in rat liver: A morphological, biochemical and molecular study. *Toxicology* 2006;225:214-24.
 28. Kameritsch P, Khandoga N, Pohl U, Pogoda K. Gap junctional communication promotes apoptosis in a connexin-type-dependent manner. *Cell Death Dis* 2013;4:e584.
 29. Lee NP, Leung KW, Wo JY, Tam PC, Yeung WS, Luk JM. Blockage of testicular connexins induced apoptosis in rat seminiferous epithelium. *Apoptosis* 2006;11:1215-29.
 30. Kidder GM, Cyr DG. Roles of connexins in testis development and spermatogenesis. *Semin Cell Dev Biol* 2016;50:22-30.
 31. Wang L, Fu Y, Peng J, Wu D, Yu M, Xu C, *et al.* Simvastatin-induced up-regulation of gap junctions composed of connexin 43 sensitize Leydig tumor cells to etoposide: An involvement of PKC pathway. *Toxicology* 2013;312:149-57.
 32. Su Y, Li J, Witkiewicz AK, Brennan D, Neill T, Talarico J, *et al.* N-cadherin haploinsufficiency increases survival in a mouse model of pancreatic cancer. *Oncogene* 2012;31:4484-9.
 33. Domke LM, Rickelt S, Dörflinger Y, Kuhn C, Winter-Simanowski S, Zimbelmann R, *et al.* The cell-cell junctions of mammalian testes: I. The adhering junctions of the seminiferous epithelium represent special differentiation structures. *Cell Tissue Res* 2014;357:645-65.
 34. Bremmer F, Schweyer S, Martin-Ortega M, Hemmerlein B, Strauss A, Radzun HJ, Behnes CL. Switch of cadherin expression as a diagnostic tool for Leydig cell tumours. *APMIS* 2013;121:976-81.
 35. Roy S, Metya SK, Rahaman N, Sannigrahi S, Ahmed F. Ferulic acid in the treatment of post-diabetes testicular damage: Relevance to the down regulation of apoptosis correlates with antioxidant status via modulation of TGF- β 1, IL-1 β and Akt signalling. *Cell Biochem Funct* 2014;32:115-24.
 36. Halliwell B, Gutteridge JM, editors. *Free Radicals in Biology and Medicine*. 4th ed. New York: Clarendon Press; 2007.
 37. Park JS, Han K. The spermatogenic effect of yacon extract and its constituents and their inhibition effect of testosterone metabolism. *Biomol Ther (Seoul)* 2013;21:153-60.
 38. Abdallah FB, Fetoui H, Zribi N, Fakhfakh F, Keskes L. Protective role of caffeic acid on lambda cyhalothrin-induced changes in sperm characteristics and testicular oxidative damage in rats. *Toxicol Ind Health* 2012;28:639-47.
 39. Na HK, Wilson MR, Kang KS, Chang CC, Grunberger D, Trosko JE. Restoration of gap junctional intercellular communication by caffeic acid phenethyl ester (CAPE) in a ras-transformed rat liver epithelial cell line. *Cancer Lett* 2000;157:31-8.
 40. Chen YJ, Shiao MS, Wang SY. The antioxidant caffeic acid phenethyl ester induces apoptosis associated with selective scavenging of hydrogen peroxide in human leukemic HL-60 cells. *Anticancer Drugs* 2001;12:143-9.
 41. Yu BB, Dong SY, Yu ML, Jiang GJ, Ji J, Tong XH. Total flavonoids of litsea coreana enhance the cytotoxicity of oxaliplatin by increasing gap junction intercellular communication. *Biol Pharm Bull* 2014;37:1315-22.



Grasiela Dias de Campos Severi-Aguiar

ABOUT AUTHOR

Grasiela DC Severi-Aguiar obtained her Ph.D. degree in 2001 from Universidade Estadual Paulista (UNESP) at Brazil. Currently, she is positioned as Collaborating Researcher in the Department of Structural and Functional Biology, Biology Institute, at the State University of Campinas, State of São Paulo, Brazil. Dr. Severi-Aguiar is working on understanding of effects and action mechanisms of natural products and environmental pollutants. She has experience in the area of morphology hepatic and area of male reproductive system and also in the evaluation of genotoxicity.