

Pseudoprogression and Immunotherapy Phenomena

ELIZABETH S. WAXMAN, RN, MSN, AOCN®, ANP-BC, and DONNA LEE GERBER, CNS

From The University of Texas MD Anderson Cancer Center, Houston, Texas

Authors' disclosures of conflicts of interest are found at the end of this article.

Correspondence to: Elizabeth S. Waxman, RN, MSN, AOCN®, ANP-BC, 1515 Holcombe Boulevard, Houston, TX.

E-mail: ewaxman@mdanderson.org

<https://doi.org/10.6004/jadpro.2020.11.7.6>

© 2020 Harborside™

Abstract

Traditionally, treatment responses to chemotherapy had been based on Response Evaluation Criteria in Solid Tumours (RECIST) criteria evaluating tumor shrinkage, stabilization of disease, growth, or development of new metastatic lesions. Using the same criteria to determine response in patients on immunotherapy has proven difficult, as some patients have initial growth of disease or develop new small metastatic lesions. The phenomenon of pseudoprogression is the initial growth of a primary lesion followed by latent or delayed response. Advanced practitioners need to be aware of the possibility of pseudoprogression in order to educate patients and help them stay on effective treatment.

CASE STUDY

Patricia is a Caucasian 48-year-old female who loves outdoor activities and has a history of numerous severe sunburns. Patricia did not use any type of sunscreen. During Patricia's annual physical examination with her primary physician, a dark pigmented area on her shoulder that had irregular borders was noted. Her physician recommended having this lesion biopsied. Pathology was positive for a primary melanoma, which was removed in July 2014. Based on the pathology, Patricia underwent a wide local excision and sentinel node biopsy in August 2014. One lymph node was positive for disease, and she was placed on close surveillance.

Recurrent Disease

In the beginning of 2016, Patricia began having some vague intermittent abdominal pain that increased over time, decreased appetite, and a weight loss of five pounds without dieting. After a consultation with her primary physician, a CT scan was ordered and revealed two large tumors and several small tumors in her lungs and one large tumor and several smaller tumors in her liver. The two larger tumors in her lung measured 2 × 1.7 cm and 1.5 × 2.1 cm. The large tumor in her liver measured 3 × 3.4 cm. These tumors were designated as the target lesions for measurement of tumor response. All other tumors in the lung and liver were small and designated as nontarget lesions, and would not be the primary tumors mea-

sured for tumor response but would be monitored for any growth. Patricia was placed on morphine sulfate at 15 mg po every 4 hours as needed for pain. A biopsy confirmed melanoma and testing was *BRAF* wild type (negative) and PD-L1 negative. After review by her oncologist, she underwent immunotherapy with nivolumab and ipilimumab (clinical trials showed significantly longer progression-free survival with this combination than with ipilimumab monotherapy in previously untreated melanoma patients; Larkin et al., 2015).

Patricia began treatment in June 2016. Prior to initiating treatment, she had a workup of hepatic, pancreatic, and endocrine panels, which included glucose, adrenocorticotropic hormone, cortisol, follicle-stimulating hormone, luteinizing hormone, thyroid-stimulating hormone, free T4, and dehydroepiandrosterone sulfate to establish baselines to monitor for possible toxicities. She had a creatine kinase drawn and electrocardiogram done, but as she had no cardiovascular risk factors, a troponin I was determined to be unnecessary. Her Eastern Cooperative Oncology Group performance status at the start of treatment was 0.

Patricia's pain requirements the day prior to starting treatment had increased to morphine sulfate extended-release tablets at 10 mg every 12 hours and morphine sulfate at 15 mg po every 4 hours as needed. She was taking 4 to 5 doses each day. Patricia was also using over-the-counter laxatives for constipation as needed but was told to stop these after treatment started as gastrointestinal toxicity of diarrhea is a very common occurrence. She was instructed to document all bowel movements with date, time, and consistency so that appropriate interventions could be initiated. Patricia was instructed to purchase loperamide and to take per label instructions so that she could start taking it at the first episode of diarrhea. Also, in preparation for treatment, Patricia was given a prescription for two oral antiemetics to use as needed.

Patricia received nivolumab at 1 mg/kg over 1 hour intravenously and ipilimumab at 3 mg/kg over 90 minutes intravenously on day one for 4 cycles lasting 3 weeks each (Larkin et al., 2015). Appropriate supportive medications of

antiemetics were given prior to infusion of the immunotherapy agents. As expected, Patricia had some side effects from her treatment. The most common side effects of immunotherapy are dermatologic and gastrointestinal (Jurgens et al., 2016). By the second week of treatment, Patricia noticed her bowel movements were becoming much softer and after talking with her clinician was instructed to initiate the loperamide if she had more than one bowel movement each day. In addition, at the third week of treatment, Patricia experienced pruritus located on the trunk of her torso and upper extremities. This became increasingly annoying, so much so that it interfered with her sleep. A prescription for topical steroids was given which, with diphenhydramine hydrochloride, made the pruritus tolerable. On routine laboratory surveillance, electrolytes were replaced orally as indicated.

Initial Testing for Response

Patricia completed her treatment and had her 6-week evaluation for response. Her CT scans at 6 weeks showed an increase in size of one of the lung lesions by 0.05 cm in one dimension and a decrease in the other of 0.6 cm in one dimension. The liver lesion increased by 0.06 cm in one measured dimension. The lung measurements were 2×1.75 cm and 1.5×1.5 cm and the liver lesion 3×3.47 cm. With the results of the CT scan, using RECIST criteria, Patricia would be diagnosed with progressive disease. However, her oncologist understood that responses from immunotherapy may be preceded by what appears to be disease progression especially in the early scans (de Velasco et al., 2016). The total tumor burden was calculated to have increased by approximately 16.5% from pretreatment measurements; thus, her oncologist recognized this as what is called pseudoprogression.

On examination of her clinical status at her 6-week evaluation, Patricia's performance status remained at 0. Her appetite increased and weight remained stable during her treatment, and she was no longer losing weight. Her pain requirements had also slowly decreased over the course of her treatment. She was still taking her morphine sulfate extended-release tablets

but only taking her breakthrough medication at night. After review of all clinical data, the decision was made to continue treatment, and Pa-

tricia ultimately had a complete remission of her disease and remains disease free at this time (Figure 1).

Until the latter part of the 20th century, chemotherapy was the primary treatment for cancer. Chemotherapy is cytotoxic and, when effective, results in the shrinkage of tumors; thus, the recognition of objective response is straight forward. With advances in technology and expanding knowledge of cancer biology, new treatments such as checkpoint inhibitors, tyrosine kinase inhibitors, and antiangiogenic agents were developed (Carter, Bhosale, & Yang, 2018; Gerwing et al., 2019). Many of these new therapies stimulate the immune system but are more cytostatic than cytotoxic and may require a more prolonged period of time to slow the growth of existing tumors (Hales et al., 2010).

The ability to stimulate the immune system has long been of interest to researchers in the treatment of cancer, as cancer cannot develop unless cancer cells can successfully evade the immune system (Juergens et al., 2016). Early use of cytokines such as interleukin-2 and interferon enhanced T-lymphocyte function and had low response rate (5%) and high toxicity but produced durable responses with improved survival (Juergens et al., 2016; Lijo & Cowey, 2015). Many of these new therapies, including checkpoint inhibitors, tyrosine kinase inhibitors, antiangiogenic agents, vaccines, and antibody therapies stimulate the body's immune system in some manner (Hales et al., 2010). Checkpoint blockade immunotherapy "takes the brakes off" the immune system, allowing a stronger immune response (Aide et al., 2019). Three of the most extensively used checkpoints (pathways) that stop the immune system are cytotoxic T-lymphocyte-associated protein 4 (CTLA-4), programmed cell death protein 1 (PD-1), and programmed cell death ligand 1 (PD-L1), which are negative regulators of T-cell immune functions. These inhibitors stimulate the body's own T cells to attack cancer cells (Aide et al., 2019).

Unlike chemotherapy, which can produce measurable, tangible responses on radiographic imaging studies, treatment responses with im-

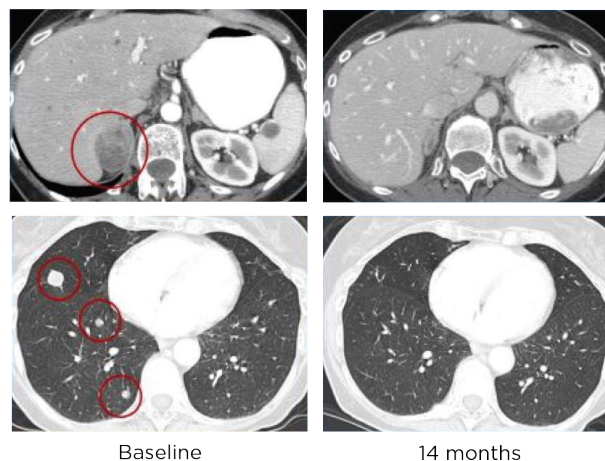


Figure 1. Patricia's scans indicating complete response.

munotherapy differ. Radiographic findings of patients treated with immunotherapy may include "disease progression" due to the growth of existing metastatic lesions, the appearance of new lesions (metastases) followed by regression or resolution of these lesions, initial stability of disease on scans followed by response (shrinkage of the tumor), and/or response after initial increase in disease burden (Wolchok et al., 2009). This is a new concept for oncology advanced practitioners to grasp, as the disease may look worse radiographically, but subsequently show a delayed response. The term "pseudoprogression" has been used to describe this immunotherapy pattern of response (Davies, 2016). Pseudoprogression is thought to be due to local inflammation (Davies, 2016). It is important for oncologists and advanced practitioners to explain to patients that they may stay on immunotherapy treatment despite what appears to be disease progression.

DESCRIPTION AND RECOGNITION OF PSEUDOPROGRESSION

The concept of pseudoprogression was first introduced when temozolomide, one of the first chemotherapy drugs that penetrated the blood-brain barrier, was combined with radiotherapy (XRT) in

the treatment of brain tumors (Atrash, Makhoul, Mizell, Hutchins, & Mahmoud, 2016). Many physicians who treated patients with glioblastoma multiforme used Macdonald criteria, which is the standard evaluation criteria for this tumor type. An increase of 25% or more is needed to determine disease progression. Later review of MRI scans of the 68 patients who had this treatment (temozolomide with XRT) showed that 60% (41) of the patients had what would have been diagnosed as progressive disease using Macdonald criteria (standard), but of those 41 patients, only 20% (14) had progressive disease on the ensuing MRIs (Gunjur, Lau, Taouk, & Ryan, 2011). The pathology of tumors that were resected in the patients who had initial growth followed by shrinkage showed a combination of necrosis, infarction, and inflammation (Qin et al., 2017). In an irradiated field, the radiotherapy releases the cancer cell antigens and makes them available to the immune system, thus allowing the infiltration of activated T cells into the tumors (Demaria, Golden, & Formenti, 2015; Yoshida, Furuta, & Hida, 2017). When immunotherapy started to be used as treatment for primary brain tumors, oncologists met and developed the immunotherapy response assessment in neuro-oncology (iRANO) to assist in determining between true disease progression and pseudoprogression (Ellingson, Chung, Pope, Boxerman, & Kaufmann, 2017; Okada et al., 2015).

In the late 1990s and early 2000s, many clinical trials were initiated with new immunotherapy and targeted therapy agents, and clinicians noted the same phenomenon of growth then regression of tumors in other disease sites. Many providers felt patients had to discontinue treatment on the clinical trials when tumor growth was seen on the first (reimaging) scans (which were used to determine response to treatment). Subsequent scans showed tumor shrinkage; unfortunately, the patients were not permitted to resume treatment with the study drug as it was only available if the patient remained on the clinical trial (Hales et al., 2010; Okada & Pollock, 2011). It is important for oncologists to recognize the phenomenon of pseudoprogression when treating patients with immunotherapy in order to avoid premature discontinuation of treatment (Hodi et al., 2014).

WHO, RECIST, AND iRECIST

For many years, clinicians have used the World Health Organization (WHO) and Response Evaluation Criteria in Solid Tumours (RECIST) criteria to determine response to treatment (Chiou & Burotto, 2015; Therasse, 2000). Measurements for tumor size, using WHO and RECIST definitions, are linear based, with the premise that tumor growth means progression and failure of treatment drugs (Hales et al., 2010; Wolchok et al., 2009). RECIST was developed in 2000 and revised in 2008 with RECIST 1.1, and again, any increase in tumor size and/or appearance of new lesions suggests failure of the treatment (Chiou & Burotto, 2015; Eisenhauer et al., 2009; Gunjur et al., 2011; Juergens et al., 2016).

With immunotherapy and checkpoint inhibitors, objective, measurable tumor response may take significant time to be radiographically appreciated because of the complexity of tumor pathway pathophysiology (Tumeh, Radu, & Ribas, 2008). Clinicians have become more aware of the phenomenon of delayed objective responses. In 2004 and 2005, over 200 oncologists convened to develop response evaluation criteria for patients on immunotherapy and checkpoint inhibitor treatments. The new response criteria would allow patients to remain on treatment and not be prematurely withdrawn from the studies and treatment due to initial disease progression on imaging studies. The conclusions from this conference were that immunologic treatments may show progression when using RECIST or WHO criteria; thus, the imaging criteria needed to be based on specific disease histology and therapy (Hales et al., 2010; Juergens et al., 2016; Okada & Pollack, 2011; Wolchok et al., 2009).

One discovery regarding early tumor growth was that stimulated immune cells infiltrate tumors, thus causing inflammation and edema (de Velasco et al., 2016; Juergens et al., 2016; Okada et al., 2015; Tumeh et al., 2008; Vrankar & Unk, 2018; Wiggenraad et al., 2014). As previously mentioned, because of the complexity of tumor pathophysiology, more time is required for immune cells to complete their function; therefore, responses may take several months before any decrease in tumor size is seen (a delayed response; de Velasco et al., 2016; Tumeh et al., 2008). Tumor growth can be seen early (pseudoprogression) but will decrease

by week 12 in patients treated with immunotherapy and is rare after this time (Tanizaki et al., 2016).

An example of pseudoprogression is a review of scans of patients treated with ipilimumab (Yervoy) that showed 19% of patients had an increase on initial scans post treatment which would have been defined as progression by RECIST criteria but subsequently had response (de Velasco et al., 2016). Pseudoprogression was also seen in patients with melanoma treated with pembrolizumab (Keytruda; Hodi et al., 2014). In another report, 9% of patients who had an increase in their tumor size and were classified as having progressive disease were subsequently found to have response on the next scans (de Velasco et al., 2016). Patients with non-small cell lung cancer (NSCLC) treated with nivolumab (Opdivo) were treated beyond what would have been termed progression with RECIST criteria and had significantly longer survival when compared to those patients who had treatment discontinued on the first set of scans that showed tumor growth (Ricciuti et al., 2019).

Modification of the WHO criteria in 2009 with the immune-related response criteria was accomplished (Carter et al., 2018; Seymour et al., 2017). However, the same tumor measurement criteria were used with the modification that new lesions would be added to the total tumor burden. If immune-related progressive disease was determined, clinical assessment of the patient would determine continuation of present treatment with confirmation of true response on the radiographic evaluation (Carter et al., 2018).

As RECIST 1.1 was being used in many clinical trials, recommendations for the modification of RECIST for use in immunotherapy treatments was requested, and immune-related RECIST (irRECIST) was developed (Seymour et al., 2017). One of the main distinctions between RECIST and irRECIST is that according to RECIST criteria, the development of new lesions meets the definition of disease progression and requires discontinuation of treatment (Seymour et al., 2017), whereas in irRECIST, the development of new target lesions and an increase in total burden of disease is permitted on the first evaluation scans (Carter et al., 2018; Seymour et al., 2017). The use of irRECIST may assist in identifying those patients who have pseudoprogression; however, a clinician's evaluation of the to-

tal clinical situation is imperative (Simard, Smith, & Chandra, 2018), thereby allowing continuation of beneficial treatment for the patient.

In the literature, the term “immune unconfirmed progressive disease” (iUPD) has been used instead of pseudoprogression. Any increase in tumor size must be followed up with scans in a few weeks especially if new lesions are present (Aide et al., 2019). Immunotherapy RECIST (iRECIST) defines iUPD based on RECIST 1.1 principles; however, iUPD requires confirmation of progression (Seymour et al., 2017). Confirmation of iUPD is accomplished by observing either a further increase in size (or number of new lesions) in target or nontarget lesions, or progression as defined by RECIST 1.1 (Seymour et al., 2017). In irRECIST, disease progression is confirmed when, on the next set of imaging studies after pseudoprogression is documented (4–8 weeks later), there is further increase in the sum of the measurements of the target disease of at least 5 mm (Seymour et al., 2017). Imaging studies after iUPD are compared to baseline studies (prior to the start of immunotherapy), and if the criteria for disease progression are not met, then the patient is able to stay on immunotherapy treatment (Seymour et al., 2017).

With pseudoprogression (iUPD), the question arises as to which imaging studies should be used for determining response to treatment. Using PET imaging is also problematic when immunologic or targeted therapy drugs are used. PET imaging cannot differentiate between active cancer cells and active immune cells; thus, its use in evaluating non-cytotoxic agents is difficult (Tumeh et al., 2008). As with CT scans, if increased activity or increase in tumor size is seen, further evaluation by the clinician is required to determine true progression vs. pseudoprogression. When MRI scans are used, especially brain MRIs for brain metastases, it has been noted that the T2-FLAIR signal abnormality and enhancing component was larger in true progression than pseudoprogression (Agarwal et al., 2013).

INCIDENCE OF PSEUDOPROGRESSION WITH TUMOR TYPE/SITE

As clinicians are recognizing that pseudoprogression can occur, and as more patients are being treated with immunotherapy, more information is coming to light. The question is whether pseudo-

progression happens with the same frequency in all tumor types and all sites. Melanoma and NSCLC have produced the most documented cases of pseudoprogession. In melanoma, rates range between 10% to 25% and in NSCLC 6% to 17%. Of interest, the three drugs used for treatment were nivolumab, pembrolizumab, and ipilimumab. The most observed areas of increase growth prior to shrinkage were the lung, liver, adrenal glands, and lymph nodes (Nishino et al., 2016; Vrankar & Unk, 2018).

Less than 6% of patients with colorectal or pancreatic cancer treated with immunotherapy were found to have results that could be classified as pseudoprogession. The occurrence of pseudoprogession was extremely rare in patients treated for metastatic bladder cancer with lung metastases (Kim et al., 2019). The incidence of pseudoprogession in head and neck squamous cell carcinoma was 1.8% (Wang, Gao, & Wu, 2018). Pseudoprogession was also rare in patients with squamous cell cancers of the head and neck area after review of limited data (Wang et al., 2018).

IMPROVED ASSESSMENT OF PSEUDOPROGRESSION

There are many challenges in differentiating true progression from pseudoprogession secondary to radionecrosis when radiation therapy is also used, and the inflammatory changes that occur as a result of immunotherapies (with or without the concurrent administration of a cytotoxic treatment; Ellingson et al., 2017; Simard et al., 2018). Novel approaches to assist in the evaluation of tumors that are being explored include diffusion, perfusion, and metabolic imaging, which show some promise but currently have high variability and/or imperfect accuracy. Thus, consensus is lacking for their use (Ellingson et al., 2017).

For glioblastomas, the use of 3D echo-planar spectroscopic imaging (3D-EPSI) was used in a clinical trial to differentiate between true progression and pseudoprogession. This testing had a 94% sensitivity and a specificity of 87% in differentiating between true progression and pseudoprogession (Verma et al., 2019).

Differentiation between expected postimmunotherapeutic effects and viable tumor requires either radiopharmaceuticals targeted to a specific tumor or novel agents that are increasingly specif-

ic for cancer cells. An example of a PET agent that has provided some advancement in this regard is F-fluorothymidine (F-FLT), a marker of cell proliferation that was developed to identify viable tumors while reducing the false positive rate related to infection or inflammation. However, there are limitations, including the fact that bone marrow can limit detection and quantification of tumor activity and recent evidence that F-FLT can accumulate at sites of infection and inflammation, although to a lesser degree than ^{18}F -fluorodeoxyglucose (^{18}F -FDG; Juergens et al., 2016). ^{18}F -FDG is another PET modality under development to assist in differentiating between activated immune T cells from metabolic active cancer cells, but the difficulty is that the uptake in active cancer cells is the same glucose analog as activated immune cells (Tumeh et al., 2008). Two other technologies under development are a dual-energy CT that shows intratumor vascularization and immuno-PET that uses labeled monoclonal antibodies specific for T-cell antigens (Vrankar & Unk, 2018).

Imaging has always been the best method for determining treatment response; however, the use of additional criteria in conjunction with radiologic techniques needs to be considered. Of promise is the use of blood-based biomarkers as adjuvant tests in some diseases to determine statuses such as circulating tumor cells in lung, breast, prostate, and colorectal cancers (Ambady, Bettegowda, & Holdhoff, 2013).

In conclusion, the current system using anatomic imaging as the main imaging biomarker needs further improvement despite ongoing refinement. Molecular imaging technology is a powerful tool that may provide a means to not only predict which patients are most likely to respond to immune-based treatment but also monitor their response (Juergens et al., 2016). The technique of molecular imaging can become cost effective if the patient population can be refined to determine those most likely to benefit or used to shorten the duration of therapy (Juergens et al., 2016).

IMPLICATIONS

Immunotherapy has become the dominant treatment modality for patients with cancer. Responses to these agents are being observed in a variety of time frames (from a few weeks to several months)

before radiologic response is seen; therefore, clinicians need to be familiar with different response patterns with drugs being used (de Velasco et al., 2016). Many oncologists may use outside facilities where their patients go to have their restaging scans performed during treatment. Radiologists may or may not be aware of the possibility of pseudoprogression and may report any increase in the size of the tumors as disease progression. Patients may read the reports with their scans and become very anxious, bringing these reports with them to their office visits. Patients must be aware that providers can and will assist them in understanding their scans results, particularly the first scans after starting treatment. It is in these first set of scans that pseudoprogression usually may be seen. Patients need to be educated about the possible variability of the scan results at the initiation of treatment. Oncology advanced practitioners are best suited for this.

An evaluation of the patient's overall clinical status can be helpful in differentiating between true progression and pseudoprogression. Gunjur, Lau, Taouk, and Ryan (2011) described pseudoprogression as a subacute treatment reaction with or without clinical deterioration that spontaneously stabilizes and recovers. A patient's performance status and symptoms most likely will have improved in pseudoprogression compared with true progression (Aide et al., 2019; Hales et al., 2010). Consensus in the literature is that performance status should not deteriorate and a transient decrease in clinical status may be due to immunologic drug side effects (Larkin et al., 2015). Inflammatory and autoimmune adverse events occur with these treatments, with the most common being dermatologic and gastrointestinal (diarrhea). These toxicities, however, only occur at a serious level (grade 3–4) in less than 25% of patients (Juergens et al., 2016).

Performance status is an important clinical tool. Studies have shown that the Karnofsky performance categories and Eastern Cooperative Oncology Group categories are equivalent in determining a patient's performance status (10–40 [ECOG 4], 50–60 [ECOG 3], 70 [ECOG 2], 80–90 [ECOG 1], 100 [ECOG 0]; Prasad et al., 2018). Performance status should be assessed with each clinic visit. An evaluation of patients' symptoms is also

of benefit, but symptoms must be distinguished between treatment side effects and increase in tumor size or burden.

Pain is also important in assisting in determining if a patient is benefitting from treatment. Pain is a sensitive indicator of treatment response and has a high correlation (Hales et al., 2010). Just as performance status needs to be documented at each visit, the patient's pain status must also be evaluated. This includes rating the pain, listing the pain medications the patient is taking, and the amount (number of pain tablets) they are currently consuming. Even if patients still require a long-acting medication, a decrease in their as-needed immediate-release medication could be a sign of treatment response. Again, the advanced practitioner is most qualified to get an accurate assessment of pain status.

Toxicities of immunotherapy must be carefully assessed for the clinician to determine whether deterioration is due to treatment or increase in disease burden. A detailed assessment of treatment side effects is imperative during the early phase of treatment so that appropriate clinical decisions can be made. Also, if the cancer type being treated has a biomarker that was elevated, it is imperative to have repeat biomarker testing along with the first set of scans, as the biomarker result (decreased, increased, stable) may help to distinguish between pseudoprogression and true disease progression.

This careful clinical review by both the physician and advanced practitioner is essential to prevent discontinuing treatment that may have clinical benefit or conversely continuing treatment that may not be effective (de Velasco et al., 2016; Simard et al., 2018). If after a review of scans and clinical assessment the provider concludes that there is pseudoprogression, follow-up scans should be done 4 to 6 weeks later to confirm no further growth (Vrankar & Unk, 2018). In addition, patients and caregivers should be instructed to notify the advanced practitioner should any new problems arise since, if it is true progression, symptoms will usually manifest quickly (Therasse et al., 2000).

As new treatments are developed, it is imperative that advanced practitioners be aware of side effects and possible treatment patterns that may

emerge, including an initial increase in tumor size that indicates pseudoprogression. Detailed documentation by clinicians will not only assist in better understanding of the phenomenon of pseudoprogression but also assist in determining treatment benefit (Carter et al., 2018). ●

Disclosure

The authors have no conflicts of interest to disclose.

References

- Agarwal, A., Kumar, S., Narang, J., Schultz, L., Mikkelsen T., Wang, S.,...Jain, R. (2013). Morphologic MRI features, diffusion tensor imaging and radiation dosimetric analysis to differentiate pseudoprogression from early tumor progression. *Journal of Neuro-Oncology*, *112*(3), 413–420. <https://doi.org/10.1007/s11060-013-1070-1>
- Aide, N., Hicks, R., LeTourneau, C., Lheureux, S., Fanti, S., & Lopci, E. (2019). PDG PET/CT for assessing tumour response to immunotherapy. *European Journal of Nuclear Medicine and Molecular Imaging*, *46*, 238–250. <https://doi.org/10.1007/s00259-018-4171-4>
- Ambady, P., Bettgowda, C., & Holdhoff, M. (2013). Emerging methods of disease monitoring in malignant gliomas. *CNS Oncology*, *2*(6), 511–522. <https://doi.org/10.2217/cns.1344>
- Atrash, S., Makhoul, I., Mizell, J. S., Hutchins, L., & Mahmoud, F. (2016). Response of metastatic mucosal melanoma to immunotherapy: It can get worse before it gets better. *Journal of Oncology Pharmacy Practice*, *0*(0), 1–5. <https://doi.org/10.1177/1078155215627503>
- Carter, B. W., Bhosale, P., & Yang, W. T. (2018). Immunotherapy and the role of imaging. *Cancer*, *124*(14), 2906–2922. <https://doi.org/10.1002/cncr.31349>
- Chiou, V., & Burotto, M. (2015). Pseudoprogression and immune-related response in solid tumors. *Journal of Clinical Oncology*, *33*(31), 3541–3543. <https://doi.org/10.1200/JCO.2015.61.6870>
- Davies, M. (2016). How checkpoint inhibitors are changing the treatment paradigm in solid tumors: What advanced practitioners in oncology need to know. *Journal of the Advanced Practitioner in Oncology*, *7*(5), 498–509. <https://doi.org/10.6004/jadpro.2016.7.5.3>
- de Velasco, G., Krajewski, K. M., Albiges, L., Awad, M. M., Bellmunt, J., Hodi, S. F., & Choueiri, T. K. (2016). Radiologic heterogeneity in responses to anti-PD1/PD-L1 therapy in metastatic renal cell carcinoma. *Cancer Immunology Research*, *4*(1), 12–17. <https://doi.org/10.1158/2326-6066.CIR-15-0197>
- Demaria, S., Golden, E. B., & Formenti, S. C. (2015). Role of local radiation therapy in cancer immunotherapy. *JAMA Oncology*, *1*(9), 1325–1332. <https://doi.org/10.1001/jamaoncol.2015.2756>
- Eisenhauer, E. A., Therasse, P., Bogaerts, J., Schwartz, L. H., Sargent, D., Ford, R.,...Verweij, J. (2009). New response evaluation criteria in solid tumours: Revised RECIST guideline (version 1.1). *European Journal of Cancer*, *45*(2), 228–247. <https://doi.org/10.1016/j.ejca.2008.10.026>
- Ellingson, B. M., Chung, C., Pope, W. B., Boxerman, J. L., & Kaufmann, T. (2017). Pseudoprogression, radionecrosis, inflammation or true tumor progression? Challenges associated with glioblastoma response assessment in an evolving therapeutic landscape. *Journal of Neuro-Oncology*, *134*, 495–504. <https://doi.org/10.1007/s11060-017-2375-2>
- Gerwing, M., Herrmann, K., Helfen, A., Schliemann, C., Wolfgang, B., Eisenblätter, M., & Wildgruber, M. (2019). The beginning of the end for conventional RECIST – novel therapies require novel imaging approaches. *Nature Reviews Clinical Oncology*, *16*, 442–458. <https://doi.org/10.1038/s41571-019-0169-5>
- Gunjur, A., Lau, E., Taouk, Y., & Ryan, G. (2011). Early post-treatment pseudo-progression amongst glioblastoma multiforme patients treated with radiotherapy and temozolomide: A retrospective analysis. *Journal of Medical Imaging and Radiation Oncology*, *55*(6), 603–610. <https://doi.org/10.1111/j.1754-9485.2011.02319.x>
- Hales, R. K., Banchemereau, J., Ribas, A., Tarhini, A., Weber, J., Fox, B. A., & Drake, C. G. (2010). Assessing oncologic benefit in clinical trials of immunotherapy agents. *Annals of Oncology*, *21*(10), 1944–1951. <https://doi.org/10.1093/annonc/mdq048>
- Hodi, S., Hwu, W. J., Kefford, R., Weber, J., Daud, A., Hamid, O.,...Wolchok, J. D. (2014). Evaluation of immune-related response criteria and RECIST v1.1 in patients with advanced melanoma treated with pembrolizumab. *American Society of Clinical Oncology*, *34*(13), 1510–1517. <https://doi.org/10.1200/JCO.2015.64.0391>
- Juergens, R. A., Zukotynski, K. A., Singnurkar, A., Snider, D. P., Valliant, J. F., & Gulenchyn, K. Y. (2016). Imaging biomarkers in immunotherapy: Supplementary issue: Biomarkers and their essential role in the development of personalised therapies (A). *Biomarkers in Cancer*, *8*(S2), 1–13. <https://doi.org/10.4137/BIC.S31805>
- Kim, E., Park, L., Kim, Y., Ahn, H., Lee, H., & Kim, J. (2019). Unusual radiologic manifestation of pseudoprogression in pulmonary metastases after durvalumab treatment in metastatic bladder urothelial cancer. *Thoracic Cancer*, *10*(4), 1016–1018. <https://doi.org/10.1111/1759-7714.12994>
- Larkin, J., Chiarion-Sileni, V., Gonzalez, R., Gobb, J. J., Cowey, C., Lao, C. D.,...Wolchok, J. D. (2015). Combined nivolumab and ipilimumab or monotherapy in untreated melanoma. *New England Journal of Medicine*, *373*(1) 23–34. <https://doi.org/10.1056/NEJMoa1504030>
- Lijo, J., & Cowey, L. (2015). The rapid emergence of novel therapeutics in advanced malignant melanoma. *Dermatologic Therapy*, *5*, 151–169. <https://doi.org/10.1007/s13555-015-0080-7>
- Nishino, M., Ramaiya, N., Chambers, E. S., Adeni, A. E., Hatabu, H., Jänne, P.,...Awad, M. (2016). Immune-related response assessment during PD-1 inhibitor therapy in advanced non-small cell lung cancer patients. *Journal for ImmunoTherapy of Cancer*, *4*, 84. <https://doi.org/10.1186/s40425-016-0193-2>
- Okada, H., & Pollack, I. F. (2011). Do we need novel radiologic response criteria for brain tumor immunotherapy? *Expert Review of Neurotherapeutics*, *11*(5), 619–622. <https://doi.org/10.1586/ern.11.49>
- Okada, H., Weller, M., Huang, R., Finocchiaro, G., Gilbert, M. R., Wick, W.,...Reardon, D. A. (2015). Immunotherapy response assessment in neuro-oncology: A report of the RANO working group. *Lancet*, *16*(15), E534–E542.

- [https://doi.org/10.1016/S1470-2045\(15\)00088-1](https://doi.org/10.1016/S1470-2045(15)00088-1)
- Prasad, K. T., Kaur, H., Muthu, V., Aggarwal, A. N., Behera, D., & Singh, N. (2018). Interconversion of two commonly used performance tools: An analysis of 5844 paired assessments in 1501 lung cancer patients. *World Journal of Clinical Oncology*, *9*(7), 140–147. <https://doi.org/10.5306/wjco.v9.i7.140>
- Qin, L., Li, X., Stroiney, A., Qu, J., Helgager, J., Reardon, D. A., & Young, G. S. (2017). Advanced MRI assessment to predict benefit of anti-programmed cell death 1 protein immunotherapy response in patients with recurrent glioblastoma. *Neuroradiology*, *59*, 135–145. <https://doi.org/10.1007/s00234-016-1769-8>
- Ricciuti, B., Genova, C., Bassanelli, M., De Giglio, A., Brambilla, M., Metro, G.,...Chiari, R. (2019). Safety and efficacy of nivolumab in patients with advanced non-small lung cancer treated beyond progression. *Clinical Lung Cancer*, *20*(3), 178–185. <https://doi.org/10.1016/j.clcc.2019.02.001>
- Seymour, L., Bogaerts, J., Perrone, A., Ford, R., Schwartz, L. H., Mandrekar, S.,...de Vries, E. G. E. (2017). iRECIST: Guidelines for response criteria for use in trials testing immunotherapeutics. *The Lancet Oncology*, *18*(3), E143–E152. [https://doi.org/10.1016/S1470-2045\(17\)30074-8](https://doi.org/10.1016/S1470-2045(17)30074-8)
- Simard, J. L., Smith, M., & Chandra, S. (2018). Pseudoprogression of melanoma brain metastases. *Current Oncology Reports*, *20*(11), 91. <https://doi.org/10.1007/s11912-018-0722-x>
- Tanizaki, J., Hayashi, H., Kimura, M., Tanaka, K., Takeda, M., Shimizu, S.,...Nakagawa, K. (2016). Report of two cases of pseudoprogression in patients with non-small cell lung cancer treated with nivolumab-including histological analysis of one case after tumor progression. *Lung Cancer*, *102*, 44–48. <https://doi.org/10.1016/j.lungcan.2016.10.014>
- Therasse, P., Arbuck, S. G., Eisenhauer, E. A., Wanders, J., Kaplan, R. S., Rubinstein, L.,...Gwyther, S. (2000). New guidelines to evaluate the response to treatment in solid tumor. *Journal of the National Cancer Institute*, *92*(3), 205–216. <https://doi.org/10.1093/jnci/92.3.205>
- Tumeh, P. C., Radu, C. G., & Ribas, A. (2008). PET imaging of cancer immunotherapy. *Journal of Nuclear Medicine*, *49*(6), 865–868. <https://doi.org/10.2967/jnumed.108.051342>
- Verma, G., Chawla, S., Mohan, S., Wang, S., Nasrallah, M., Sheriff, S.,...Poptani, H. (2019). Three-dimensional echo planar spectroscopic imaging for differentiation of true progression from pseudo-progression patients with glioblastoma. *NMR Biomedicine*, *32*(2). <https://doi.org/10.1002/nbm.4042>
- Vranker, M., & Unk, M. (2018). Immune RECIST criteria and symptomatic pseudoprogression in non-small cell lung cancer patients treated with immunotherapy. *Radiologic Oncology*, *52*(4), 365–369. <https://doi.org/10.2478/raon-2018-0037>
- Wang, Q., Gao, J., & Wu, X. (2018). Pseudoprogression and hyperprogression after checkpoint blockade. *Journal of International Immunopharmacology*, *58*, 125–135. <https://doi.org/10.1016/j.intimp.2018.03.018>
- Wiggenraad, R., Bos, P., Verbeek-de Kanter, A., Nijeholt, G. L., van Santvoort, J., Taphoorn, M., & Struikmans, H. (2014). Pseudo-progression after stereotactic radiotherapy of brain metastases: Lesion analysis using MRI cine-loops. *Journal of Neuro-Oncology*, *119*, 437–443. <https://doi.org/10.1007/s11060-014-1519-x>
- Wolchok, J., Hoos, A., O'Day, S., Weber, J., Hamid, O., Lebbé, C.,...Hodi, S. (2009). Guidelines for the Evaluation of Immune Therapy Activity in Solid Tumors: Immune-Related Response Criteria. *Clinical Cancer Research*, *15*(23), 7412–7420. <https://doi.org/10.1158/1078-0432.CCR-09-1624>
- Yoshida, T., Furuta, H., & Hida, T. (2017). Risk of tumor flare after nivolumab treatment in patients with irradiated field recurrence. *Medical Oncology*, *34*, Article number: 34. <https://doi.org/10.1007/s12032-017-0895-4>