



Since January 2020 Elsevier has created a COVID-19 resource centre with free information in English and Mandarin on the novel coronavirus COVID-19. The COVID-19 resource centre is hosted on Elsevier Connect, the company's public news and information website.

Elsevier hereby grants permission to make all its COVID-19-related research that is available on the COVID-19 resource centre - including this research content - immediately available in PubMed Central and other publicly funded repositories, such as the WHO COVID database with rights for unrestricted research re-use and analyses in any form or by any means with acknowledgement of the original source. These permissions are granted for free by Elsevier for as long as the COVID-19 resource centre remains active.

# Patients' reported experiences and outcomes following surgical excision of lower limb osteomyelitis and microvascular free tissue reconstruction under 'awake' epidural anaesthesia and sedation<sup>☆</sup>

Svetlana Galitzine<sup>a,\*</sup>, Katy Wilson<sup>b</sup>, Magdalena Edington<sup>c</sup>,  
Amisha Burumdayal<sup>a</sup>, Martin McNally<sup>d</sup>

<sup>a</sup> Nuffield Department of Anaesthetics, Oxford University Hospitals, Oxford, UK

<sup>b</sup> Anaesthetic ST6, Nuffield Department of Anaesthetics, Oxford University Hospitals, Oxford, UK

<sup>c</sup> Tennent Institute of Ophthalmology, Glasgow, UK

<sup>d</sup> Oxford Bone Infection Unit, Nuffield Orthopaedic Centre, Oxford University Hospitals, Oxford, UK

## ARTICLE INFO

### Article history:

Received 29 October 2019

Received in revised form

29 April 2020

Accepted 7 May 2020

Available online xxx

### Keywords:

Patient reported experience

Patient reported outcome

Osteomyelitis

Bone infection

Free-tissue transfer

Free muscle flap

Orthoplastic surgery

Questionnaire

Lower limb or lower extremity

Neuraxial

Epidural

Combined spinal and epidural

Anaesthesia

Sedation

## ABSTRACT

**Background:** Orthoplastic operations for lower limb osteomyelitis (LLOM) involving microvascular free tissue reconstructions ("free-flaps") are usually performed under general anaesthesia (GA), with or without epidural anaesthesia (EA) due to concerns about the discomfort associated with prolonged surgery. However, our clinical experience supports "awake" epidural anaesthesia with sedation (EA + Sed) rather than EA + GA as a technique of choice for this type of surgery.

**Methods:** We used a standardised postoperative questionnaire to formally assess the experiences and outcomes for 50 patients who underwent free-flaps for LLOM under EA + Sed. **Findings:** The mean duration of surgery was 522 min (8.7 h), range 240–875 min. There were no ITU admissions or flap failures. Postoperatively, fifty patients completed a standardised questionnaire about their experiences before the operation, in the anaesthetic room and theatre. 80% were aware of the procedure at least "some of the time". 72.5% patients and 75% respectively, did not have any concerns in the anaesthetic room and theatre. Concerns expressed by the remaining patients were manageable. 97.5% of those patients who recalled their operation reported their overall experience as "comfortable" or "very comfortable". 92% of respondents had undergone previous lower limb surgery under GA ± EA. In this subgroup, 91.3% reported the recovery after EA + Sed as "quicker" than GA, and 89.4% reported their experience with EA + Sed as "better". All fifty patients (100%) were "satisfied" or "very satisfied" with their experience and all but one (98%) would recommend this technique to others. **Conclusions:** Our study showed that despite prolonged duration, the patients' reported experiences and outcomes were excellent when EA + Sed was used for orthoplastic operations involving free-flaps for LLOM. We recommend EA + Sed as the anaesthetic technique of choice for such patients.

© 2020 Royal College of Surgeons of Edinburgh (Scottish charity number SC005317) and Royal College of Surgeons in Ireland. Published by Elsevier Ltd. All rights reserved.

<sup>☆</sup> The interim results of our study were presented in part as an e-abstract at the 33rd Annual European Society of Regional Anaesthesia & Pain Therapy (ESRA) Congress 2014. Galitzine S, Wallis A, Perera S, Burumdayal A, McNally M. Patients' reported outcomes following epidural anaesthesia and sedation for orthoplastic lower limb surgery in comparison with previous experience of general anaesthesia for lower limb surgery. *RAPM* 2014; 39(1). [https://rapm.bmj.com/content/39/Suppl\\_1](https://rapm.bmj.com/content/39/Suppl_1).

\* Corresponding author.

E-mail addresses: [svetlana.galitzine@ouh.nhs.uk](mailto:svetlana.galitzine@ouh.nhs.uk) (S. Galitzine), [Katy.Wilson@ouh.nhs.uk](mailto:Katy.Wilson@ouh.nhs.uk) (K. Wilson), [medington85@gmail.com](mailto:medington85@gmail.com) (M. Edington), [Amisha.Burumdayal@ouh.nhs.uk](mailto:Amisha.Burumdayal@ouh.nhs.uk) (A. Burumdayal), [martin.mcnally@ouh.nhs.uk](mailto:martin.mcnally@ouh.nhs.uk) (M. McNally).  
<https://doi.org/10.1016/j.surge.2020.05.001>

1479-666X/© 2020 Royal College of Surgeons of Edinburgh (Scottish charity number SC005317) and Royal College of Surgeons in Ireland. Published by Elsevier Ltd. All rights reserved.

## Introduction

Patients with lower limb osteomyelitis (LLOM) can require complex and prolonged orthopaedic procedures. Excision of OM with or without external or internal fixator is performed by the orthopaedic surgeons, followed by closure of soft tissue defects by the plastic surgeons.<sup>1,2</sup> Many patients with chronic bone infections would have had multiple previous operations and anaesthetics, often not without complications and adverse events. The plastic part of the operation frequently includes microvascular free tissue reconstruction (“free flap”): free muscle or bone transfer, or fasciocutaneous flap. Free tissue transfer in chronic bone infection is made difficult by previous trauma and surgery to the limb in addition to the chronic fibrosis elicited by the infection. This can greatly prolong the surgery<sup>3,4</sup> (see Fig. 1).

Anaesthesia for this type of surgery relies on a sound understanding of circulatory physiology<sup>5</sup> and can play a crucial role in ensuring successful outcome. Specific anaesthetic objectives for free flap surgery include avoiding situations which may jeopardise the outcome for the free flap such as vasoconstriction due to poor pain relief, hypoxaemia, or surges in blood pressure. The importance of effective and reliable analgesia cannot be overestimated.

In our tertiary referral centre for treatment of bone infection, continuous epidural anaesthesia (EA) and postoperative epidural analgesia are very much advocated for “free flap” operations, both by the surgeons and anaesthetists. In the past, EA was usually combined with general anaesthesia (EA + GA) and artificial ventilation via endotracheal tube, due to perceived discomfort to the patient and possible surgical difficulties during prolonged surgery. However, since 2007 we have growing experience of successful prolonged free flap

operations under EA + Sed with the patients being awake or lightly sedated during the surgery<sup>6,7,8,9</sup> (see Fig. 2).

The main observed benefits of EA + Sed include reliable effective neuraxial anaesthesia without risks associated with prolonged general anaesthesia and incomplete postoperative epidural analgesia. Over the years, this technique for LLOM free tissue transfer surgery has received very positive informal feedback from surgeons, nursing staff and, most importantly, the patients themselves. However, there has been no formal assessment of patients' experiences and outcomes. The aim of our study was to evaluate EA + Sed from the patients' perspective by assessing patients' experiences using a standardised postoperative questionnaire.

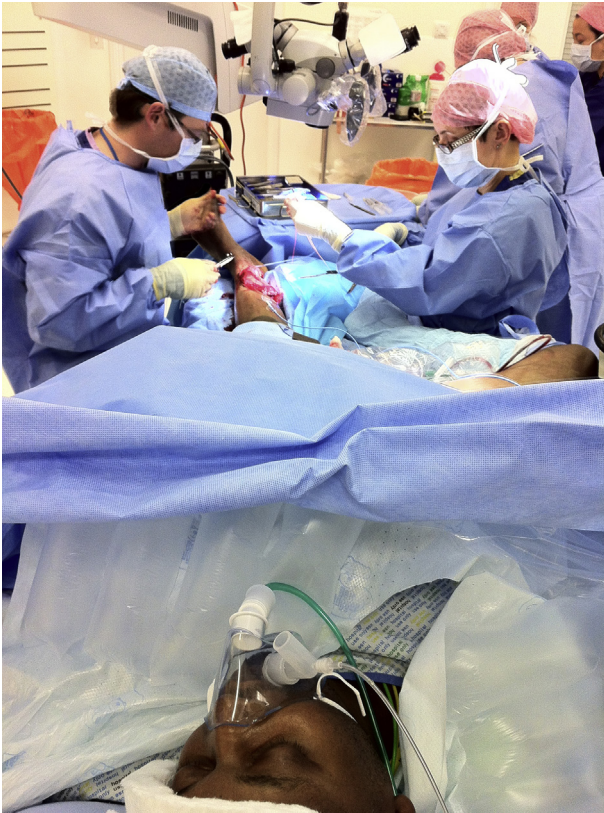
## Method

Our aim was to analyse a sample of 50 standardised postoperative questionnaires completed by the patients who underwent excision of lower limb osteomyelitis and free tissue transfer surgery under EA + Sed. Following approval by our institutional governance board, consecutive patients who satisfied the above surgical and anaesthetic criteria were invited to complete a voluntary postoperative questionnaire (Appendix 1). When the required sample of 50 returned completed questionnaires was reached, the data collection was stopped.

The questionnaire was designed, tested and revised by a multidisciplinary team of clinicians, nurses and patient representatives. It asked about patients' experiences before the operation (Part A) and in the anaesthetic room and theatre (Part B). For those patients who had undergone previous general anaesthesia for surgery for the same condition, a comparison of the two techniques was sought (Part C).

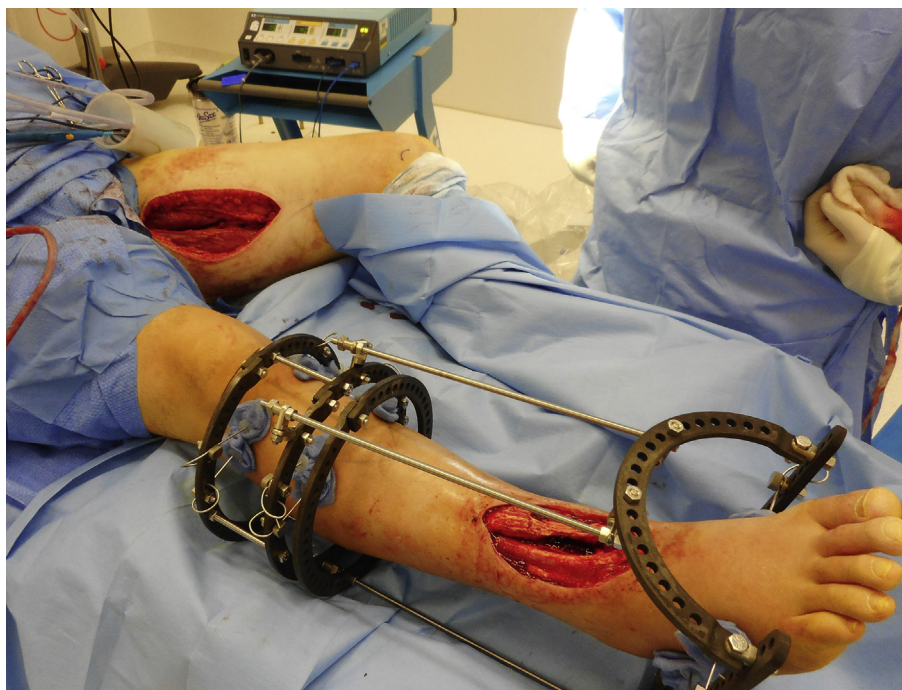

Figure 1 – Orthopaedic surgery for osteomyelitis.



**Figure 2 – Free Gracilis Flap performed under epidural anaesthesia and sedation.**

In all patients surgery was limited to the lower limb with regard to both donor and recipient sites. Intraoperatively all patients were in supine position. All operations were performed by orthopaedic and plastic surgeons who were familiar with the anaesthetic technique. The excision surgery, bony reconstruction and soft tissue coverage were all completed in a single stage, in all patients, which is a surgical treatment protocol in our centre.<sup>2,10</sup>

Adequate central neuraxial anaesthesia was established in the anaesthetic room. Continuous epidural anaesthesia (EA) was maintained intraoperatively using infusion and/or boluses of local anaesthetic, with sensory and motor blockade adequate for surgery. This was followed by postoperative patient controlled epidural analgesia (PCEA) with a standard regime used in our institution.

Intraoperative intravenous sedation (Sed) was delivered using propofol target-controlled infusion (propofol TCI), in some cases with added ketamine (1 mg of ketamine for each 5 mg of propofol), and small increments of midazolam and/or fentanyl if required. Sedation was titrated to an individual patient's preference. Patients spent the majority of the time awake and were able to communicate with the anaesthetic and surgical teams. In several patients, sedation was combined with audio-visual distraction as previously reported by our centre.<sup>8</sup> In these cases, patients were able to listen to music, play games or watch films on an internet-linked tablet or laptop computer (see Fig. 3).

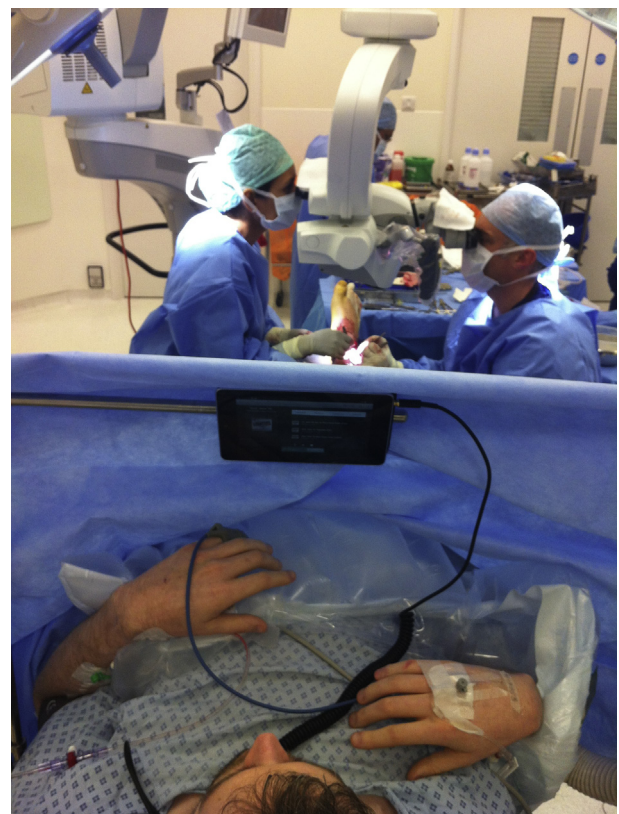## Results

Consecutive ASA Grade 1–3 patients who underwent excision of LLOM and free tissue transfer surgery under EA + Sed in the period of October 2007–June 2015 were invited to complete a standardised postoperative questionnaire. In the course of the study five patients did not return completed questionnaires, therefore it required 55 consecutive patients to reach the sample of 50 patients (91% return rate). When the required sample of 50 returned completed questionnaires, the data collection was stopped.

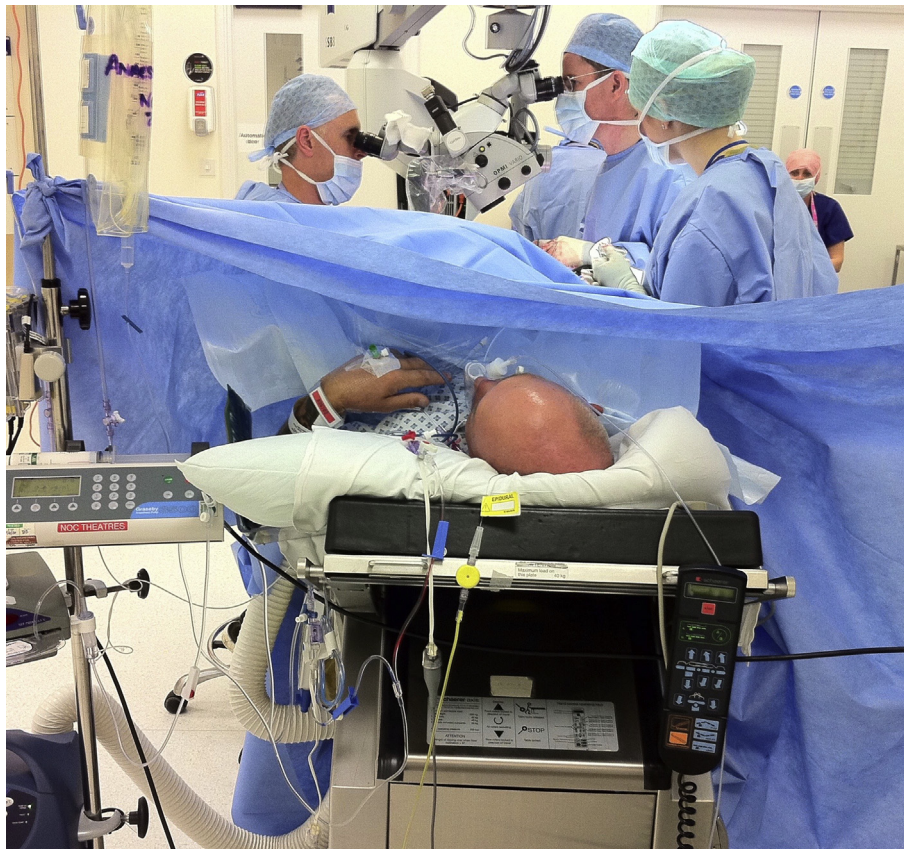All patients who were invited to complete the questionnaire had excision of infected bone, deep sampling, and management of the bone defect with insertion of a local antibiotic carrier; initial intraoperative empiric dose of intravenous antibiotics (usually Vancomycin and Meropenem) was followed by postoperative culture-specific antimicrobial therapy (usually for six weeks).

The mean duration of procedure (surgery and anaesthesia) was 522 min (8.7 h), with the range of 240–875 min. None of the 55 patients required planned or unplanned ITU admission for anaesthetic or surgical reasons. All flaps were successful. One patient had to return to theatre on the morning after surgery for revision of the venous anastomosis which was successfully achieved under an epidural “top-up” with subsequent positive flap outcome (see Fig. 4).

Of the 50 patients who returned the completed questionnaires, 46 patients received a free gracilis muscle flap, 2



**Figure 3 – Intraoperative audio-visual distraction technique.**



**Figure 4 – 14.5 h Orthoplastic operation under continuous Epidural Anaesthesia.**

free fibula grafts, 1 vastus lateralis and 1 fasciocutaneous flaps.

Patients' responses are summarised as follows:

#### A. "Before your operation"

88% of 50 respondents felt that they had received an "adequate" amount of information about their anaesthetic prior to their operation, 2% had "too much" information, and 8% felt they had "too little"; 2% did not answer the question. 90% of respondents remembered discussing the benefits of EA for their surgery prior to the operation. The benefits - as worded by the patients - included "good pain relief", "faster recovery", "less nausea", "no pain", "easier for everyone". 78% remembered discussing the risks such as "failure of epidural", "need to convert to GA", "headache", "infection", "damage to spinal nerves".

#### B. "In the anaesthetic room and theatre"

In the anaesthetic room 70% of the 50 respondents were fully aware of proceedings and another 10% were aware "some of the time". Of the patients who were aware at least "some of the time", 72.5% did not have any concerns. Concerns reported by the remaining 28.5% included "fear of needles", "feeling cold" and "pain caused by difficult epidural". All patients who reported concerns were overall "satisfied" or "very satisfied" with their anaesthetic.

In theatre, 20 (40%) patients were fully aware of the surgery, another 20 (40%) patients were aware at least "some of the time" and the remaining 10 (20%) were not aware or could not remember. Of the 40 patients who had full or some recollection of events, 75% did not have any concerns throughout the surgery; concerns reported by the remaining 25% patients included "dry mouth", "feeling cold", positional discomfort in upper limbs, and - in one patient - feeling "restricted for space". The latter patient reported their experience in theatre as "uncomfortable" but later rated their recovery as "quicker", overall experience as "better" than previous GAs and left a free text comments: "The GA required a recovery in itself. The epidural isn't an issue" and "the recovery was quicker, I didn't have a sore throat from a tube". 97.5% of patients who had full or some recollection of events rated their overall experience during the operation as "comfortable" or "very comfortable". Patients who reported any concerns during their operation also reported that they could talk to the anaesthetist intraoperatively to express their concerns.

#### C. "Comparing this operation with any previous limb surgery"

46 of the 50 studied patients had undergone previous LL surgery for the same condition, under GA with or without EA. Of those, 89% reported their experience with EA + Sed as "better" compared to previous GA, 8.8% felt there was "no

difference" and 2.2% could not remember. 91.3% of patients who had undergone previous LL surgery reported their general recovery after EA + Sed as "quicker" compared to GA, 4.3% felt there was "no difference" and 2.2% could not remember. One patient stated that his general recovery after EA + Sed was "slower" than their previous four GAs which was inconsistent with his later statement that overall experience was "better" than previous GA.

All fifty patients were either "very satisfied" (86%) or "satisfied" (14%) with their EA + Sed experience. 98% stated that they would recommend this technique to others; one patient was "not sure". 18% of patients commented that more patients' information and preoperative discussion would improve the experience.

60% of the respondents used an opportunity to add "free text" comments, amongst them were: "The longest and best op I have had. Excellent"; "Nice to be aware of what was going on in theatre"; "Would choose epidural over GA every time"; "Almost instantly regained consciousness with no hangover, no sickness, no confusion"; "Would feel more reassured if surgeon also recommended epidural"; "This is a huge improvement and the only way forward to better understanding of the recovery process"; "For a 14.5 h surgery I was very impressed", and "Before I have had general and it has taken a day or two to get over". Other benefits reported by the patients included very good pain relief, less drowsiness, no "confusion", no nausea, no sore throat and ability to eat and drink soon after surgery.

## Discussion

### *The development and evaluation of the EA + Sed technique*

Central neuraxial anaesthesia is commonly performed for a wide range of surgery and has been shown to significantly reduce complications and mortality in major joint replacement orthopaedic surgery when compared with general anaesthesia.<sup>11</sup>

It is less commonly used for prolonged orthoplastic operations involving free flap surgery. Our literature review revealed only two articles published in the last 30 years in other centres: Alam NH et al.<sup>12</sup> (UK, 2006) reported the use of this technique in 3 adult and Bjorklund KA<sup>13</sup> (India, 2015) - 20 paediatric patients, respectively. Remarkably, both case series were published in the surgical journals. While over the years we extensively presented our clinical experiences to various anaesthetic communities, we also feel that sharing patients' experiences with EA + Sed for prolonged surgery with the wider surgical audience is an important tool for disseminating positive perioperative practices and, ultimately, improving patient-centred care.

To our knowledge, our study presents the biggest published series of 55 consecutive LLOM "free flaps" performed under EA + Sed in a single European centre, with 50 patients in the series giving a formal patients' feedback on their experience with the EA + Sed technique, making a crucial impact on the development of the technique.

In our institution, implementation of EA + Sed technique for this type of surgery to a large extent has been driven by the

patients' needs or requests.<sup>6,7,8,9</sup> We first used it in 2007, for a single high-risk patient in order to avoid respiratory complications during their prolonged surgery.<sup>6</sup> A few months later an "awake" technique was requested by an elderly patient who wished to avoid a GA. This patient had a successful 8 h 50 min procedure under EA with conscious sedation. The patient's informal feedback was that they "would choose epidural over GA every time". This case has instigated the change of clinical practice in our centre. However, a formal structured investigation of patients' experiences was started in 2011 and prompted by a patient who had a particularly challenging but successful 14 h 15 min procedure under EA and minimal sedation and "was very impressed".

The limited published experience of performing prolonged microvascular surgery under EA + Sed is understandable. Few centres in the world perform this type of specialised surgery regularly and even they accumulate the numbers very slowly. In addition, not all patients are suitable or agreeable to undergo prolonged surgery "awake". The importance of good teamwork, especially between surgeons and anaesthetists, cannot be overestimated.

### *The advantages of performing prolonged microvascular surgery under EA ± sedation*

The most likely explanation behind the conventional practice of using EA + GA, usually with intubation and artificial ventilation, is that these complex cases can be unpredictably prolonged and perceived to be uncomfortable for awake or lightly sedated patients. Our data showed that the mean duration of the operations was almost nine hours; the longest procedure in this series took over 14 h.<sup>9</sup> Only one of the studied patients (with a procedure time of just under 10 h) reported their experience in theatre as "uncomfortable", whilst appreciating that their recovery was "quicker" and overall experience "better" compared to their previous GAs ("The [previous]GA required a recovery in itself. The epidural isn't an issue").

The most significant benefit of EA + Sed from the microvascular surgery perspective is that it provides steady physiology and reliable neuraxial analgesia with minimal use of opioids during and after the procedure. EA + Sed avoids the risks associated with prolonged GA and artificial ventilation and because there is no need for extubation, there is no associated risk of hypoxia, coughing and surges in blood pressure which can adversely affect blood flow to flaps. Prolonged surgery under GA with ventilation over 3 h is now recognised as an independent factor for re-intubation and unplanned postop ventilation.<sup>14</sup> In our stand-alone orthopaedic centre, this would also mean an ITU transfer to another site in an ambulance, with all the associated hazards for the patient and the flap, as well as cost implications. In our study there were no anaesthesia-related complications, none of the patients required postoperative ITU admission.

Another important advantage is that with a well working continuous epidural in place, any immediate/early postoperative problems can be sorted out without a GA, with the patient remaining pain-free. Although all flaps in our study were successful, one patient developed occlusion of the venous anastomosis within a few hours of completion of the

surgery. It was a simple matter to return to theatre for revision of the anastomosis with 'epidural top-up' only (i.e. no GA). We believe that the choice of anaesthetic technique was a significant factor in the positive surgical outcome.

The "free text" comments left by the patients were very encouraging. It would appear that patients are not concerned about being awake during the prolonged and intricate procedure, providing they are reassured that sedation can be given at a level they request. 20% of patients in the study had no recollection of the events in the anaesthetic room and theatre and we speculate that they were those who preferred deeper level of sedation with corresponding amnesia. While modern sedation is fairly safe, we are continuously looking for anxiety and pharmacological sedation reducing strategies such as use of audio-visual distraction.<sup>8</sup>

Crucially, the COVID-19 pandemic has made us all re-appraise certain benefits of regional anaesthesia over GA.<sup>15</sup> For us as clinicians and researchers, it has emphasised how valuable it is to champion an anaesthetic technique for prolonged complex lower limb surgery that both optimises patient satisfaction and minimises the need for aerosol generating procedures, with their corresponding risks of viral transmission. Even post-COVID we should not forget the newly re-discovered advantages of high quality regional anaesthesia.

#### **Comparison of EA + Sed with previous GA in the same patients**

Due to previous trauma, multiple operations and anaesthetics, patients with chronic osteomyelitis often present specific issues such as increased preoperative anxiety and previous "bad" anaesthetic experience e.g. poor pain control or postoperative nausea/vomiting. The majority of our patients (94%) had required previous operations for the same condition, under GA. More than one third had experience of seven or more GAs.

It was striking that these patients (acting as self-controls) described a very positive comparison, with 90% preferring EA + Sed to GA.

EA + Sed for this type of orthoplastic surgery requires specific anaesthetic expertise of managing EA for prolonged microvascular surgery. While this technique may be more labour intensive and demands closer teamwork between anaesthetists and surgeons, it offers many advantages to the patients, especially to those with "bad" experience with previous GAs. The benefits in terms of reduced complications and better patient experience has encouraged colleagues in our centre and beyond to adopt this technique.

#### **The importance of studying patient reported outcomes and experiences**

Learning from patient reported experiences, especially when the findings are analysed in conjunction with the outcomes, is vital for improving patient-centred service.<sup>16</sup> The 2010 NHS White Paper called for NHS care which 'moves away from centrally driven process targets and focuses on delivering outcomes which matter to people'.<sup>17</sup> What really matters to patients is the outcome of an intervention and the effect it has

on their wellbeing and life expectancy.<sup>16</sup> Measuring quality and outcomes in anaesthesia can be difficult for many reasons, appropriate ways of assessing patient satisfaction can include structured patient reported outcome and experience measures (PROMs & PREMs).<sup>18</sup>

Validating a patient questionnaire as a research tool can be very challenging,<sup>19</sup> especially as it targets a relatively small group of patients with osteomyelitis who undergo very specialised infrequently performed surgery for which a commonly used anaesthetic technique is applied under uncommon conditions (unpredictably prolonged microvascular surgery). Our questionnaire was designed by a multidisciplinary team of clinicians and nurses, with the first test version amended following patient feedback.

While designing the questionnaire we made every effort to phrase the questions in the language understandable to general public. When sent/given to the patient, the questionnaire was accompanied by a cover letter with contact details in case of any queries. While the patients completed the questionnaire on their own, they also had an opportunity to add comments about the questionnaire itself, at the end. Of the 50 questionnaires, 49 (98%) were answered in a consistent way suggesting that the questions were clear and understandable. None of the respondents commented on any difficulties in filling out the questionnaire, although we recognise potential limitations of this research tool. The five non-respondents may have had issues with the questionnaire or parts of it; however, there may have been other reasons for not returning them (i.e. change of address, poor compliance, etc).

Macario et al.<sup>20</sup> found that the most undesirable outcomes of anaesthesia from patients' points of view were vomiting, gagging on the tracheal tube, incisional pain, nausea, recall without pain, residual weakness, shivering, sore throat, and somnolence, i.e. those negatives outcomes which can be avoided when Epi + Sed is used as opposed to GA. The patients' "free text" comments, as well as standardised responses can provide valuable information on what patients perceived as important to them. We certainly received some very valuable insights from the patients in our study, especially by a large subgroup (46 of 50 patients) with previous experience with GA. Not surprisingly, all fifty patients in the study were either "very satisfied" (86%) or "satisfied" (14%) with their anaesthetic experience and 98% stated that they would recommend this technique to others (the technique has passed a "friends and relatives" test!).

Finally, most of our patients (90%) felt that preoperative information was adequate or "too much". However, in the free comments section, 18% of patients suggested the need for more information or time to discuss the technique. This study has allowed us to focus on improving the elements of the procedure which may cause discomfort or anxiety for some patients and will allow development of better patient information package.

## **Conclusion**

Our study demonstrated excellent patients' reported experiences and outcomes when EA + Sed technique was used for complex orthoplastic surgery involving excision of lower limb

osteomyelitis and free tissue transfer (“free flap” surgery). It provides important standardised positive feedback for the multidisciplinary teams involved in the care of such patients in our centre.

Prolonged duration of the procedures did not affect patients' positive experience and outcomes. None of the patients required planned or unplanned ITU admission nor developed any significant anaesthetic complications. All flaps in the studied group were successful, and it is likely that the anaesthetic technique had a positive impact on the outcomes.

Based on our data, we recommend EA + Sed as an anaesthetic technique of choice for orthoplastic lower limb surgery in all suitable patients with donor and recipient site for free tissue transfer below the waist, regardless the duration of surgery. Wider dissemination of our positive findings among surgeons, anaesthetists and other relevant health care professionals will allow improving and developing further patient-centred care, from preoperative discussions and decision-making to theatre and postoperative recovery.

Further detailed evaluation of this anaesthetic technique is required and is underway.

## Acknowledgements

We would particularly like to acknowledge the late Marion Sutherland (Specialist Nurse) for the outstanding care she gave to the patients and the huge positive contribution she made to this paper; Drs Matthew Sainsbury, Rachel Pollard, Nita George, Vassiliss Athanassoglou, Mr Alex Ramsden, Mr Paul Critchley, Mr Henk Giele and Miss Lucy Cogswell for adapting to and supporting the technique, and Sally Ryan for assistance with the literature search.

## Appendix. Supplementary data

Supplementary data to this article can be found online at <https://doi.org/10.1016/j.surge.2020.05.001>.

## REFERENCES

- McNally MA, Nagarajah K. Osteomyelitis. *Orthop Trauma* 2010;24(6):416–29.
- McNally MA, Ferguson JY, Lau ACK, Diefenbeck M, Scarborough M, Ramsden AJ, et al. Single-stage treatment of chronic osteomyelitis with a new absorbable, gentamicin-loaded, calcium sulphate/hydroxyapatite biocomposite. *Bone Joint Lett J* 2016;98-B:1289–96.
- Cierny III G, Mader JT, Penninck JJ. The classic: a clinical staging system for adult osteomyelitis. *Clin Orthop Relat Res* 2003;414:7–24.
- Smith IM, Austin OMB, Batchelor. The treatment of chronic osteomyelitis: a 10 year audit. *J Plast Reconstr Aesthetic Surg* 2006;59:11–5.
- Quinlan J. Anaesthesia for reconstructive surgery. *Anaesth Intensive Care Med* 2006;7(1):31–5.
- Bayshev F, Rutter S. Combined spinal-epidural anaesthesia for prolonged free muscle transfer surgery. *Reg Anesth Pain Med* 2007;5(S1):39.
- Galitzine S, Burumdayal A, Sinczak M, Giele H, McNally M. Combined spinal-epidural anaesthesia with sedation for orthoplastic free gracilis flap surgery with duration of over eight hours: review of 10 successful cases. *Eur J Anaesthesiol* 2012;29 S50:121–2.
- Athanassoglou V, Wallis A, Galitzine S. Audiovisual distraction as a useful adjunct to epidural anaesthesia and sedation for prolonged lower limb microvascular orthoplastic surgery. *J Clin Anesth* 2015;27(7):606–11.
- Burumdayal A, Sinczak M, Ramsden A, McNally M, Galitzine S. Successful epidural anaesthesia with conscious sedation for a 14h15min lower limb orthoplastic procedure involving free gracilis flap: was it worth the trouble? *Br J Anaesth* 2012;108.
- Chan J, Ferguson J, Scarborough M, McNally MA, Ramsden A. Management of post-traumatic osteomyelitis in the lower limb: current state of the art. *Indian J Plast Surg* 2019;52:62–72.
- Memtsoudis SG, Cozowicz C, Bekeris J, Bekere D, Liu J, Soffin EM, et al. Anaesthetic care of patients undergoing primary hip and knee arthroplasty: consensus recommendations from the International Consensus on Anaesthesia-Related Outcomes after Surgery group (ICAROS) based on a systematic review and meta-analysis. *Br J Anaesth* 2019 Sep;123(3):269–87.
- Alam NH, Haeney JA, Platt AJ. Three episodes of gracilis free muscle transfer under epidural anaesthesia. *J Plast Reconstr Aesthetic Surg* 2006;59:1463–6.
- Bjorklund KA, Venkatramani H, Venkateshwaran G, Boopathi V, Raja Sabapathy S. Regional anaesthesia alone for pediatric free flaps. *J Plast Reconstr Aesthetic Surg* 2015;68(5):705–8.
- Rujirojindakul P. Risk factors for reintubation in the post-anaesthetic care unit: a case-control study. *Br J Anaesth* 2012;109(4):636–42.
- Practice recommendations on neuraxial anaesthesia and peripheral nerve blocks during the COVID-19 pandemic. [https://mcusercontent.com/8cf3dbc6dd8663ea7c2d00035/files/724b498c-e852-4370-a525-753fb52537a6/RA\\_COVID19\\_ESRA\\_ASRA\\_Recommendations.01.pdf](https://mcusercontent.com/8cf3dbc6dd8663ea7c2d00035/files/724b498c-e852-4370-a525-753fb52537a6/RA_COVID19_ESRA_ASRA_Recommendations.01.pdf); March 31, 2020.
- Murphy PJ. Measuring and recording outcome. *Br J Anaesth* 2012;109(1):92–8.
- Equity and excellence: liberating the NHS. Department of Health; 2010. [www.gov.uk/government/news/equity-and-excellence-liberating-the-nhs](http://www.gov.uk/government/news/equity-and-excellence-liberating-the-nhs).
- Moonesinghe SR, Tomlinson AA. Quality improvement and revalidation: two goals, same strategy. *Br J Anaesth* 2011;106(4):447–50.
- Kingsley C, Patel S. Patient-reported outcome measures and patient reported experience measures. *Br J Anaesth Educat* 2017;17(4):137–44.
- Macario A, Weinger M, Carnie S, Kim A. Which clinical anaesthesia outcomes are important to avoid? The perspective of patients. *Anaesth Analg* 1999;89:652–8.