


better understanding of the underlying immunological mechanism would shed light on the pathogenesis of SARS-CoV-2 and could have relevant implications for the development of an effective vaccine.

S. Recalcati <sup>1</sup>, S. Tonolo,<sup>2</sup> F. Luzzaro<sup>2</sup> and F. Fantini<sup>1</sup>

<sup>1</sup>Dermatology Unit; and <sup>2</sup>Microbiology and Virology Unit, ASST Lecco, Alessandro Manzoni Hospital, Lecco, Italy  
Email: sebastianorecalcati@gmail.com

## References

- 1 Caselli D, Chironna M, Loconsole D et al. No evidence of SARS-CoV-2 infection by polymerase chain reaction or serology in children with pseudo-chilblain. *Br J Dermatol* 2020; **183**:784–5.
- 2 Colmenero I, Santonja C, Alonso-Riaño M et al. SARS-CoV-2 endothelial infection causes COVID-19 chilblains: histopathological, immunohistochemical and ultrastructural study of seven paediatric cases. *Br J Dermatol* 2020; **183**:729–37.
- 3 Recalcati S, Barbagallo T, Frasin LA et al. Acral cutaneous lesions in the time of COVID-19. *J Eur Acad Dermatol Venereol* 2020; **34**:e346–7.
- 4 Cegolon L, Pichiari J, Mastrangelo G et al. Hypothesis to explain the severe form of COVID-19 in Northern Italy. *BMJ Glob Health* 2020; **5**:e002564.

Funding sources: none.

Conflicts of interest: The authors declare they have no conflicts of interest.

## Response to ‘No evidence of SARS-CoV-2 infection by polymerase chain reaction or serology in children with pseudo-chilblain’. Reply from the authors

DOI: 10.1111/bjd.19563


**Linked Articles:** Recalcati et al. *Br J Dermatol* 2020; **183**:1154–1156. Caselli et al. *Br J Dermatol* 2020; **183**:784–785. Colmenero et al. *Br J Dermatol* 2020; **183**:729–737.

DEAR EDITOR, Recalcati et al. conclude that chilblain-like lesions (CLLs) are part of the spectrum of COVID-19 based on reports of SARS-CoV-2 in endothelial cells of skin biopsies assessed by immunohistochemistry and electron microscopy (EM).<sup>1–3</sup> Nevertheless, the conclusion does not seem to be adequately supported by the data. Recalcati et al. expand their previously reported case series to include 32 patients with CLLs. In 21 of 32 cases, no nasopharyngeal swab (NPS) was tested for SARS-CoV-2. Two of 11 patients subjected to molecular testing were positive for SARS-CoV-2, but no serological test was performed to verify the seroconversion. Three patients tested pos-

itive for IgM and negative for IgG antibodies without any confirmation of infection through NPS. Again, taken together the diagnostic studies performed confirm that the vast majority of their patients did not test positive for the SARS-CoV-2 genome or for specific IgG. To et al. demonstrated that patients with SARS-CoV-2 infection showed an earlier seroconversion for IgG than for IgM. Moreover, they also found a 100% seroconversion for IgG 14 days after the onset of symptoms, but not for IgM.<sup>4</sup> In addition, Van Elslande et al. in their study concluded that including IgM antibodies did not improve the diagnostic performance in relation to COVID-19.<sup>5</sup> Therefore, in light of currently available information, the presence of IgM should not be taken as a diagnostic standard given the insufficient level of specificity. The presence of IgM antibodies, not supported by positive NPS and/or seroconversion for specific anti-SARS-CoV-2 IgG antibodies, could be a false-positive result.

To support the conclusion that CLLs are associated with COVID-19, Recalcati et al.<sup>1</sup> cite Colmenero et al.<sup>3</sup> However, a substantial limitation of that study was the lack of any serological assay performed in their patients. The use of EM morphology is certainly of interest but cannot be taken as a completely satisfactory state-of-the-art assessment of a novel virus. Detection of SARS-CoV-2 using molecular methods in biopsies would certainly offer much more stringent evidence of the presence of the virus in the lesional tissue.

Although we may agree that the cluster of chilblains in children occurred during the pandemic peak and this suggests some correlation, this has not been sufficiently clarified so far and remains intriguing.

D. Caselli <sup>1</sup>, M. Chironna,<sup>2</sup> D. Loconsole<sup>2</sup> and M. Aricò<sup>3</sup>

<sup>1</sup>Pediatric Infectious Diseases; <sup>2</sup>Department of Biomedical Sciences and Human Oncology-Hygiene Section, University of Bari, Piazza G. Cesare 1170124, Bari, Italy; and <sup>3</sup>COVID Emergency Task Force, Giovanni XXIII Children's Hospital, Azienda Ospedaliero Universitaria, Consorziato Policlinico, Bari, Piazza G. Cesare 1170124, Bari, Italy  
Email: desiree.caselli@policlinico.ba.it

## References

- 1 Recalcati S, Tonolo S, Luzzaro F et al. Response to ‘No evidence of SARS-CoV-2 infection by polymerase chain reaction or serology in children with pseudo-chilblain’. *Br J Dermatol* 2020; **183**:1154–56.
- 2 Caselli D, Chironna M, Loconsole D et al. No evidence of SARS-CoV-2 infection by polymerase chain reaction or serology in children with pseudo-chilblain. *Br J Dermatol* 2020; **183**:784–5.
- 3 Colmenero I, Santonja C, Alonso-Riaño M et al. SARS-CoV-2 endothelial infection causes COVID-19 chilblains: histopathological, immunohistochemical and ultrastructural study of seven paediatric cases. *Br J Dermatol* 2020; **183**:729–37.
- 4 To KK-W, Tsang OT-Y, Leung W-S et al. Temporal profiles of viral load in posterior oropharyngeal saliva samples and serum antibody responses during infection by SARS-CoV-2: an observational cohort study. *Lancet Infect Dis* 2020; **20**:565–74.

- 5 Van Elslande J, Houben E, Depypere M et al. Diagnostic performance of seven rapid IgG/IgM antibody tests and the Euroimmun IgA/IgG ELISA in COVID-19 patients. *Clin Microbiol Infect* 2020; **26**:1082–7.

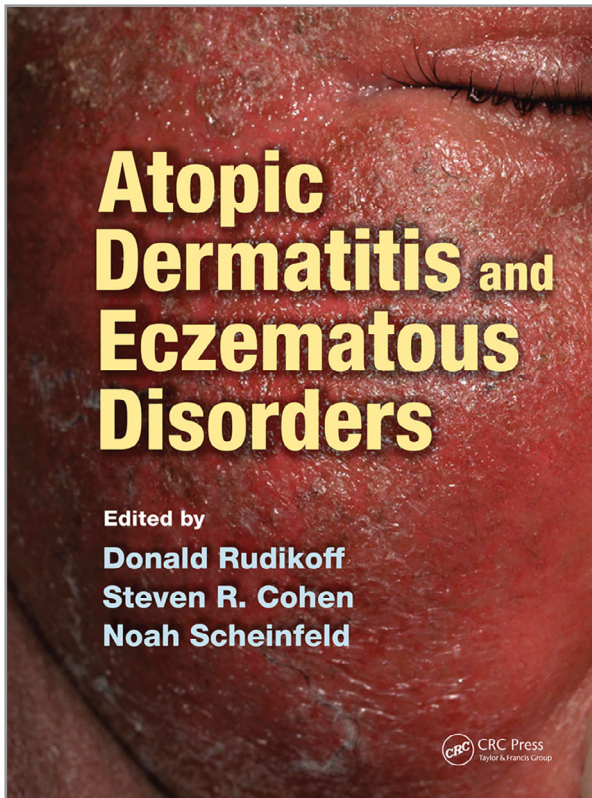
Funding sources: none.

Conflicts of interest: The authors declare they have no conflicts of interest.

## Book Review

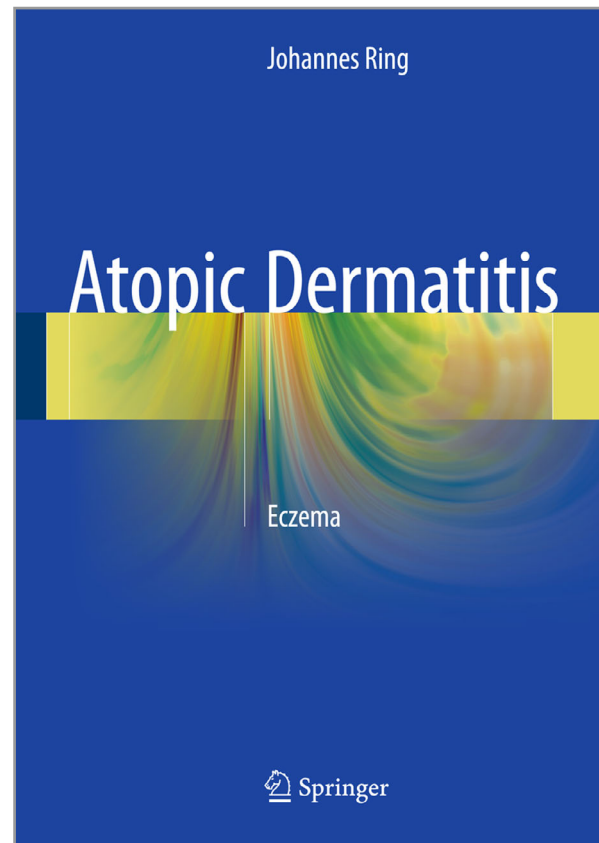
DOI: 10.1111/bjd.19533

**Atopic Dermatitis.** Johannes Ring. Cham, Switzerland: Springer International Publishing, 2016; 244 pp. ISBN: 978-3-319-22242-4. Price: eBook £63.99, Hardcover £109.99, Softcover £79.99.



**Atopic Dermatitis and Eczematous Disorders.** Donald Rudikoff, Steven R. Cohen, Noah Scheinfeld, eds. Boca Raton, FL: CRC Press, 2014; 456 pp. ISBN: 978-1-84076-195-5. Price: eBook £54.99, Hardcover £155.00, Paperback £54.99.

The increasing interest and developments in the field of atopic dermatitis (AD) are reflected in the publication of two recent textbooks. *Atopic Dermatitis* is a 244-page text written by



Professor Johannes Ring from Munich, whose interest in AD arose from a research project that combined both of his clinical specialties of immunology and dermatology. Written predominantly for healthcare professionals, it is also intended for patients and caregivers. The book has a sense of a lecture series, being a factual account of AD mixed with a more personal element. The single-author narrative presents a clear view with no redundancy. There are six main sections: a general introduction and epidemiology, clinical symptoms, pathophysiology, management, special therapeutic options and substances, and prevention, with a single page of concluding remarks. Each chapter is subdivided into short paragraphs that are detailed in the contents pages.

*Atopic Dermatitis and Eczematous Disorders* is an impressive 456-page text and the combined work of an editorial team of three US dermatologists and 45 expert contributors, predominantly US based, but also from Europe and New Zealand. Its 24 chapters are divided into smaller subsections, followed by an extensive reference list and index. It is intended as a comprehensive text covering the historical, aetiological, pathological and clinical aspects of AD and other related conditions. While it is primarily written for experienced dermatologists, the target audience also includes dermatology trainees, primary care doctors and allergists.

Both texts set the scene by discussing the history of the disease. In *Atopic Dermatitis and Eczematous Disorders*, the opening chapter contains an interesting discussion of eczema from a