

Comparison of hinged and contoured rods for occipitocervical arthrodesis in adults: A clinical study

ABSTRACT

Introduction: A rigid construct that employs an occipital plate and upper cervical screws and rods is the current standard treatment for craniovertebral junction (CVJ) instability. A rod is contoured to accommodate the occipitocervical angle. Fatigue failure has been associated these acute bends. Hinged rod systems have been developed to obviate intraoperative rod contouring.

Object: The aim of this study is to determine the safety and efficacy of the hinged rod system in occipitocervical fusion.

Materials and Methods: This study retrospectively evaluated 39 patients who underwent occipitocervical arthrodesis. Twenty patients were treated with hinged rods versus 19 with contoured rods. Clinical and radiographic data were compared and analyzed.

Results: Preoperative and postoperative Nurick and Frankel scores were similar between both groups. The use of allograft, autograft or bone morphogenetic protein was similar in both groups. The average number of levels fused was 4.1 (± 2.4) and 3.4 (± 2) for hinged and contoured rods, respectively. The operative time, estimated blood loss, and length of stay were similar between both groups. The occiput to C2 angle was similarly maintained in both groups and all patients demonstrated no movement across the CVJ on flexion-extension X-rays during their last follow-up. The average follow-up for the hinged and contoured rod groups was 12.2 months and 15.9 months, respectively.

Conclusion: Hinged rods provide a safe and effective alternative to contoured rods during occipitocervical arthrodesis.

Key words: Craniovertebral; fusion; hinged; instrumentation; occipitocervical; occiput; rod.

Introduction

Occipitocervical fusion is used for the treatment of biomechanical instability of the craniovertebral junction (cvj).^[1-9] Rigid constructs have been shown in biomechanical studies to provide superior fixation to semi-rigid constructs.^[4,7,9-15] Rods are contoured to connect an occipital plate and upper cervical spine screws,^[4,7,9] inviting biomechanical fatigue failure of the rod.^[8] Hinged rod systems, comprised two rods connected to each other at a hinge, allow fixation without rod bending [Figure 1]. No clinical comparison between contoured and hinged rod constructs has been previously conducted.

KINGSLEY O ABODE-IYAMAH, BRIAN J DLOUHY, ALEJANDRO J LOPEZ¹, ARNOLD H MENEZES, PATRICK W HITCHON, NADER S DAHDALEH¹

Department of Neurological Surgery, The University of Iowa, Carver School of Medicine, Iowa City, IA 52242, ¹Department of Neurological Surgery, Northwestern University, Feinberg School of Medicine, Chicago, IL 60611, USA

Address for correspondence: Dr. Nader S Dahdaleh, Department of Neurological Surgery, Northwestern University, Feinberg School of Medicine, 676 N. St. Clair Street, Suite 2210, Chicago, IL 60611, USA.
E-mail: nader.dahdaleh@northwestern.edu

This is an open access article distributed under the terms of the Creative Commons Attribution-NonCommercial-ShareAlike 3.0 License, which allows others to remix, tweak, and build upon the work non-commercially, as long as the author is credited and the new creations are licensed under the identical terms.

For reprints contact: reprints@medknow.com

How to cite this article: Abode-Iyamah KO, Dlouhy BJ, Lopez AJ, Menezes AH, Hitchon PW, Dahdaleh NS. Comparison of hinged and contoured rods for occipitocervical arthrodesis in adults: A clinical study. J Craniovert Jun Spine 2016;7:171-5.

Access this article online	
Website: www.jcvjs.com	Quick Response Code 
DOI: 10.4103/0974-8237.188415	

Materials and Methods

We retrospectively reviewed the medical records of patients, 18 years of age and older who underwent posterior occipitocervical fusions by the two senior authors (PWH, NSD) between January 2007 and January 2014 at two tertiary care and level I trauma centers. The permissions of the Institutional Review Board at these two institutions were obtained. Patients with a minimum follow-up of 6 months were included in the study. Patients who were lost to follow-up or followed up for <6 months were excluded from the study. Thirty-nine patients were identified. Hinged rod systems were used in 19 patients whereas twenty patients received contoured rods. All patients were braced with a rigid collar for 3 months following surgery except for one in the contoured rod group who was placed in a crown halovest for 6 weeks.

Basic demographics, indications, use of C1 and C2 screws, bone graft, the length of stay, estimated blood loss, surgical time, and complications were noted. Clinical outcomes measures included pre- and post-operative Frankel and Nurick scores. Radiological assessment was conducted by measuring the occiput-C2 (OC2) angles pre- and post-operatively. Flexion and extension cervical spine X-rays during the last follow-up were used to assess fusions. When the occurrence of fusion was in question, computed tomography scans were obtained. The OC2 angle was defined as the Cobb angle formed by the intersection of McGregor's line and the inferior endplate of C2.

Variables were expressed as means \pm standard deviations. The unpaired Student's *t*-test was employed for continuous variables whereas the Chi-square test was used for categorical variables. The values of *P* < 0.05 were considered statistically significant.

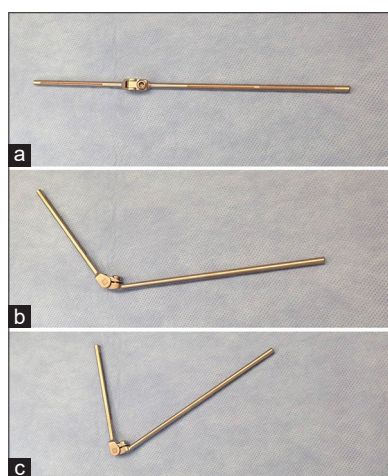


Figure 1: Photographic depiction of a hinged rod (a). The rod can accommodate obtuse angles (b) as well as acute angles (c)

All analyses were performed using Statistical Package for Social Sciences, version 22.0 (IBM, Armonk, NY, USA).

Results

We identified 39 patients who underwent occipitocervical fusion. Hinged rods were placed in 19 (48.7%) patients and 20 (51.3%) patients received contoured rods. The average age was 56.3 (\pm 26.7) and 48.5 (\pm 23.8) for patients receiving hinged and contoured rods, respectively. The average number of levels fused was 4.1 (\pm 2.4) and 3.4 (\pm 2) for hinged and contoured rods, respectively. There were no C1 screws placed in the hinged rod group whereas two (10%) of those who received contoured rods had bilateral C1 lateral mass screws placed. In 94.7% and 95% of patients, bilateral C2 pars interarticularis screws were placed in the hinged and contoured groups, respectively. There was no difference between both groups pertaining to the use of bone allograft, autograft, or bone morphogenetic protein. The average follow-up for the hinged and contoured rod groups was 12.2 months and 15.9 months [Table 1].

Clinical outcomes

The overall average operative time for hinged and contoured rods group was 303.9 (\pm 75.8) and 318 (\pm 87.7), which did not achieve statistical significance. The estimated blood loss was 242 ml for the hinged rod group compared to 311 ml for the contoured rod (*P* = 0.5). The average length of stay was 14.7 days for both groups.

Pre- and post-operative Nurick and Frankel scores were similar for both contoured and hinged rod groups [Table 2].

Table 1: Demographics of hinged and contoured rod groups

	Hinged rods	Contoured rods	<i>P</i>
Age years (SD)	56.3 (26.7)	48.5 (23.8)	0.3
Gender (% male)	32	45	0.4
Levels (SD)	4.1 (2.4)	3.4 (2.0)	0.3
C1 screws %	0	10	0.2
C2 screws %	94.7	95	1.0
Length of stay days (SD)	14.7 (8.9)	14.7 (10.0)	1.0
Follow-up months (SD)	12.2 (5.1)	15.9 (12.6)	0.2

SD - Standard deviation

Table 2: Clinical outcomes of hinged and contoured rod groups

	Hinged rods	Contoured rods	<i>P</i>
Frankel preoperative (SD)	4.5 (0.7)	4.8 (0.6)	0.2
Frankel postoperative (SD)	4.7 (0.6)	4.8 (0.6)	0.7
Nurick preoperative (SD)	1.6 (0.8)	1.3 (0.9)	0.2
Nurick postoperative (SD)	1.6 (1.1)	1.2 (0.5)	0.2
Estimated blood loss, ml (SD)	241.8 (269.3)	310.5 (354.8)	0.5
Length of surgery, min (SD)	303.9 (75.8)	318.3 (87.7)	0.6

SD - Standard deviation

Radiographic outcomes

Preoperative, postoperative, and last follow-up OC2 angles were obtained [Table 3]. There was no statistical difference in both OC2 angle at the different points of measurement with the maintenance of the preoperative OC2 angles. All patients received flexion and extension X-rays during their last follow-up that showed no motion across the CVJ. None of the patients required hardware revision or had postoperative complications. The use of bone autograft, allograft, and BMP were similar in both groups [Table 4].

Discussion

Most of the motion in the cervical spine occurs at the CVJ, and fusions across the CVJ result in at least 50% of the loss of motion in all planes.^[3,16] Fixation across the CVJ is occasionally necessary in the face of CVJ instability that may result from trauma, syndromic anomalies, osteoarthritis, rheumatoid arthritis, Down’s syndrome, neoplasm, and many other conditions.^[2,3,5,6,17-22]

The use of a plate, screw, and rod system, when feasible, has been shown to be superior to traditional semi-rigid fixation methods.^[4,7,9] Rods are typically contoured to accommodate the craniovertebral angle. Depending on the anatomy, intraoperative rod bending may be required. This is at times cumbersome, can add stress on the screws (if the bends are not sufficient), and potentially invites rod fatigue failure.^[8] To address these challenges, hinged rod systems were developed. These systems are comprised of two rods connected to each other with a hinge. Following rod engagement into the occipital and upper cervical screw heads, the hinge is then locked, obviating the need for intraoperative contouring.

In all measures of clinical and radiographic outcomes, both fixation devices were found to be similar. There was no

Table 3: Radiographic outcomes of hinged and contoured rod groups

	Hinged rods	Contoured rods	P
OC angle preoperative° (SD)	29.2 (10.0)	25.5 (12.8)	0.3
OC angle direct postoperative° (SD)	27.2 (7.7)	22.7 (8.7)	0.1
OC angle last follow-up° (SD)	25.8 (6.3)	23.3 (10.3)	0.4

SD - Standard deviation; OC - Occipitocervical

Table 4: Bone allograft and biologics used in hinged and contoured rod groups

	Hinged rods	Contoured rods	P
Bone allograft (%)	18 (95)	19 (95)	1.0
Demineralized bone matrix (%)	18 (95)	19 (95)	1.0
Bone morphogenetic protein (%)	1 (5)	3 (15)	0.3
Bone autograft (rib) (%)	5 (26)	3 (15)	0.4

difference in the operative time, estimated blood loss, or length of stay between both cohorts. All patients achieved fusion, as assessed by lack of motion on flexion-extension X-ray at the last follow-up and OC2 angles were maintained throughout the observed clinical course.

The rate of fusion was found to be slightly higher in both hinged and contoured rod groups than has been reported in the literature for contoured rods, which is 93–96%.^[12,23] No previous study isolating the rate of fusion using hinged rods has been reported. Our increased fusion rate likely reflects a selection bias of the retrospective study as patients who were unable to complete 6 months of follow-up, either from loss to follow-up or death, were excluded from the study. These patients represent the most ill and noncompliant candidates, the inclusion of whom may have negatively impacted the observed fusion rate.

The rate of adverse events related to OC instrumentation procedures has been reported to be 11.79%, although this figure included many different OC instrumentation technologies. These events were most commonly caused by errors in placement of instrumentation, vascular injury, and thecal sac injury.^[12] No such complications were encountered in our study for either hinged or contoured rods, implying that the implantation of hinged rods invited no additional morbidities compared to contoured rods. In addition, we found employing hinged rods to be simpler and more expedient than contouring.

Dysphagia is a concerning sequela to the inappropriate alignment of the neck during OC fusion, either from excessive flexion or extension and occasionally mandates reoperation to restore mechanical function. OC2 and posterior occipitocervical angle are two measurements employed to approximate preoperative physiology of this region of the spine.^[24,25] In this study, the OC2 angle after fusion did not differ significantly from preoperative values and no patient went on to experience chronic dysphagia or require reoperation.

The presence of the rod’s hinge usually coincides with the location of posterior arch and lateral masses of C1, and hence, it is often difficult to place C1 lateral mass screws when the hinged rod system is used [Figures 2 and 3]. For that reason, none of the patients undergoing OC fusion with hinged rods received C1 lateral mass screws. Similarly, only two patients (10%) undergoing OC fusions with contoured rods had their C1 instrumented. In both cohorts, skipping C1 in OC fusion constructs did not impact radiological outcomes or fusion rates.

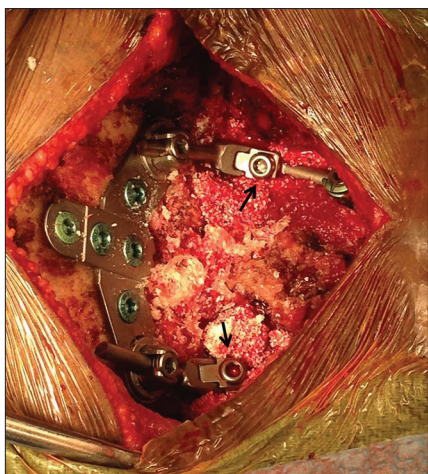

Figure 2: Intraoperative photograph showing occipitocervical arthrodesis using a hinged rod system. Note the location of the hinge (arrow) coinciding with the location of the C1 lateral mass (precluding the placement of a C1 lateral mass screw)

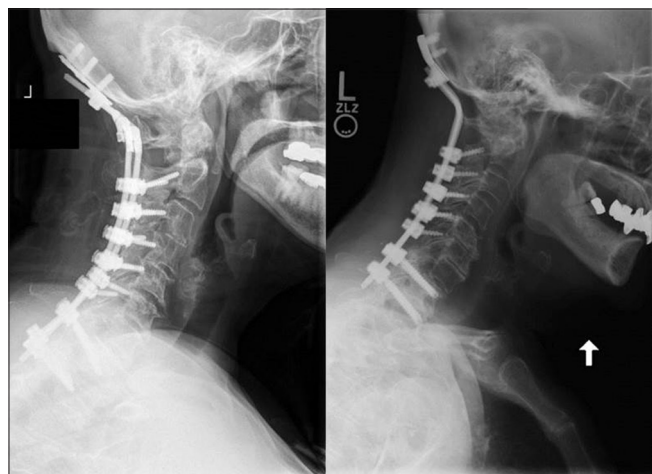


Figure 3: Lateral radiographs demonstrating occipitocervical fusions using hinged rods (left) and contoured rods (right)

While our study is limited by small sample size and retrospective analyses, it demonstrates the efficacy and safety of a new spinal technology in human subjects that potentially reduces the risk of construct fatigue associated with intraoperative rod contouring.

Conclusion

Hinged rods provide a safe and effective alternative to contoured rods during occipitocervical arthrodesis.

Financial support and sponsorship

Nil.

Conflicts of interest

There are no conflicts of interest.

References

- Ahmed R, Traynelis VC, Menezes AH. Fusions at the craniovertebral junction. *Childs Nerv Syst* 2008;24:1209-24.
- Ames CP, Acosta F, Nottmeier E. Novel treatment of basilar invagination resulting from an untreated C-1 fracture associated with transverse ligament avulsion. Case report and description of surgical technique. *J Neurosurg Spine* 2005;2:83-7.
- Dlouhy BJ, Dahdaleh NS, Menezes AH. Evolution of transoral approaches, endoscopic endonasal approaches, and reduction strategies for treatment of craniovertebral junction pathology: A treatment algorithm update. *Neurosurg Focus* 2015;38:E8.
- Hurlbert RJ, Crawford NR, Choi WG, Dickman CA. A biomechanical evaluation of occipitocervical instrumentation: Screw compared with wire fixation. *J Neurosurg* 1999;90 1 Suppl:84-90.
- McAfee PC, Cassidy JR, Davis RF, North RB, Ducker TB. Fusion of the occiput to the upper cervical spine. A review of 37 cases. *Spine (Phila Pa 1976)* 1991;16(10 Suppl):S490-4.
- Menezes AH, VanGilder JC. Transoral-transpharyngeal approach to the anterior craniovertebral junction. Ten-year experience with 72 patients. *J Neurosurg* 1988;69:895-903.
- Oda I, Abumi K, Sell LC, Haggerty CJ, Cunningham BW, McAfee PC. Biomechanical evaluation of five different occipito-atlanto-axial fixation techniques. *Spine (Phila Pa 1976)* 1999;24:2377-82.
- Steinmetz MP, Mroz TE, Benzel EC. Craniovertebral junction: Biomechanical considerations. *Neurosurgery* 2010;66 (3 Suppl):7-12.
- Sutterlin CE 3rd, Bianchi JR, Kunz DN, Zdeblick TA, Johnson WM, Rapoff AJ. Biomechanical evaluation of occipitocervical fixation devices. *J Spinal Disord* 2001;14:185-92.
- Helenius I, Crawford H, Sponseller PD, Odent T, Bernstein RM, Stans AA, et al. Rigid fixation improves outcomes of spinal fusion for C1-C2 instability in children with skeletal dysplasias. *J Bone Joint Surg Am* 2015;97:232-40.
- Vender JR, Rekito AJ, Harrison SJ, McDonnell DE. The evolution of posterior cervical and occipitocervical fusion and instrumentation. *Neurosurg Focus* 2004;16:E9.
- Winegar CD, Lawrence JP, Friel BC, Fernandez C, Hong J, Maltenfort M, et al. A systematic review of occipital cervical fusion: Techniques and outcomes. *J Neurosurg Spine* 2010;13:5-16.
- Bollo RJ, Riva-Cambrin J, Brockmeyer MM, Brockmeyer DL. Complex Chiari malformations in children: An analysis of preoperative risk factors for occipitocervical fusion. *J Neurosurg Pediatr* 2012;10:134-41.
- Goel A. Is atlantoaxial instability the cause of Chiari malformation? Outcome analysis of 65 patients treated by atlantoaxial fixation. *J Neurosurg Spine* 2015;22:116-27.
- Sinha S, Jagetia A, Aher RB, Butte MK. Occiput/C1-C2 fixations using intra-laminar screw of axis – A long-term follow-up. *Br J Neurosurg* 2015;29:260-4.
- Lopez AJ, Scheer JK, Leibl KE, Smith ZA, Dlouhy BJ, Dahdaleh NS. Anatomy and biomechanics of the craniovertebral junction. *Neurosurg Focus* 2015;38:E2.
- Dickman CA, Locantoro J, Fessler RG. The influence of transoral odontoid resection on stability of the craniovertebral junction. *J Neurosurg* 1992;77:525-30.
- Chopra JS, Sawhney IM, Kak VK, Khosla VK. Craniovertebral anomalies: A study of 82 cases. *Br J Neurosurg* 1988;2:455-64.
- Maeda T, Saito T, Harimaya K, Shuto T, Iwamoto Y. Atlantoaxial instability in neck retraction and protrusion positions in patients with rheumatoid arthritis. *Spine (Phila Pa 1976)* 2004;29:757-62.
- Milhorat TH, Bolognese PA, Nishikawa M, McDonnell NB, Francomano CA. Syndrome of occipitoatlantoaxial hypermobility, cranial settling, and chiari malformation type I in patients with hereditary

- disorders of connective tissue. *J Neurosurg Spine* 2007;7:601-9.
21. Fenoy AJ, Menezes AH, Donovan KA, Kralik SF. Calcium pyrophosphate dihydrate crystal deposition in the craniovertebral junction. *J Neurosurg Spine* 2008;8:22-9.
 22. Menezes AH. Primary craniovertebral anomalies and the hindbrain herniation syndrome (Chiari I): Data base analysis. *Pediatr Neurosurg* 1995;23:260-9.
 23. Fehlings MG, Errico T, Cooper P, Benjamin V, DiBartolo T. Occipitocervical fusion with a five-millimeter malleable rod and segmental fixation. *Neurosurgery* 1993;32:198-207.
 24. Izeki M, Neo M, Takemoto M, Fujibayashi S, Ito H, Nagai K, *et al.* The O-C2 angle established at occipito-cervical fusion dictates the patient's destiny in terms of postoperative dyspnea and/or dysphagia. *Eur Spine J* 2014;23:328-36.
 25. Maulucci CM, Ghobrial GM, Sharan AD, Harrop JS, Jallo JI, Vaccaro AR, *et al.* Correlation of posterior occipitocervical angle and surgical outcomes for occipitocervical fusion. *Evid Based Spine Care J* 2014;5:163-5.