

Case report

Pleuroparenchymal sarcoidosis - A recognised but rare manifestation of disease

S. Walker^b, H. Adamali^a, N. Bhatt^a, N. Maskell^{a,b}, S.L. Barratt^{a,b,*}^a North Bristol Interstitial Lung Disease Service, Southmead Hospital, Bristol, UK^b Academic Respiratory Unit, School of Clinical Sciences, University of Bristol, Bristol, UK

A B S T R A C T

Pleural involvement is rare in sarcoidosis. The presence of a large symptomatic effusion in a patient with sarcoidosis should therefore prompt further investigation for an alternate aetiology. Here we present a case of confirmed pleuro-parenchymal sarcoidosis. We discuss the important differential diagnoses and review the current literature.

1. Case report

A 67-year-old Caucasian non-smoker female with a past medical history of hypertension and hypothyroidism presented to our clinic with a 12-month history of exertional dyspnoea and dry cough. She was otherwise well with no systemic, nasal or gastro-oesophageal symptoms. Her prescribed medications were levothyroxine, aspirin and losartan and these had not changed in recent years. She denied atopy, exposure to previous TB or recent travel and systems enquiry did not reveal any eye, genitourinary or gastrointestinal symptoms. She had worked throughout her career in administration.

Vital signs were recorded as pulse 80 bpm, blood pressure 130/50 mmHg, respiratory rate 17 and oxygen saturations of 97% air. Cardiorespiratory examination was normal. Lung function revealed: FEV1 1.14 (57% predicted), FVC 1.60 (67% predicted), FEV1/FVC ratio 71%, TLC0 3.30 (71% predicted), TLCO 5.48 (79% predicted) and KCO 1.95 (131% predicted). ECG showed sinus rhythm with no evidence of heart block. Chest X-ray showed blunting of the costophrenic angles with scattered peribronchial thickening predominantly within the mid and lower zones (Fig. 1a). High resolution computed tomography (HRCT)-Chest demonstrated bilateral hilar and central mediastinal nodal calcification, in the absence of significant lymphadenopathy, with perilymphatic nodularity in the upper and mid zones of the lungs and bilateral pleural effusions, left larger than right (Fig. 1bi). Echocardiogram was normal.

Laboratory investigations revealed a mildly elevated ACE level (summarised in Fig. 2). Left sided chest ultrasound demonstrated an anechoic effusion, with an exudative lymphocytic yellow aspirate (lymphocytes 70%), with a normal adenosine deaminase (ADA) level that was negative to TB culture (summarised in Fig. 2).

Given the suspicion of pulmonary sarcoidosis, flexible bronchoscopy was undertaken to obtain a tissue diagnosis. Bronchoalveolar lavage samples demonstrated 90% macrophages and 10% lymphocytes. Cultures were negative for TB and fungi. Endobronchial biopsies (Fig. 1 ci) demonstrated discrete non-necrotising epithelioid granulomas consistent with sarcoidosis. Transbronchial biopsies were non-diagnostic.

Sarcoidosis was considered the most likely overarching diagnosis and thus the patient was commenced on a tapering course of oral prednisolone therapy over the following 9 months. Initial clinical improvement was followed by progressive breathlessness. HRCT demonstrated stable parenchymal appearances but worsening right effusion (Fig. 1 a and bii). MRI excluded cardiac sarcoidosis, demonstrating mild diastolic dysfunction only. Attempted diuresis, a repeat trial of tapering doses of prednisolone then introduction of methotrexate (12.5mg weekly) in conjunction with prednisolone 10mg had no significant benefit, with gradual worsening of bilateral effusions and symptoms over the subsequent 12 months (Fig. 1a). In light of this deterioration a definitive diagnosis was sought. Medical thoracoscopy was not technically feasible and thus she proceeded to right-sided video-assisted thoracoscopic (VATS) wedge lung biopsy and pleural biopsy with planned therapeutic drainage and talc pleurodesis.

Pleural biopsies showed features of chronic pleuritis with associated granulomata (Fig. 1c ii-iii). The lung VATS biopsy sections (Fig. 1 c iv) showed pleural and subpleural granulomatous inflammation. A small interstitial granuloma was also noted. Ziehl-Neelsen stain was negative. Overall, these features are most suggestive of pleuro-parenchymal sarcoidosis.

A further trial of combination therapy (hydroxychloroquine (200mg bd), azathioprine (150mg daily) and prednisolone (10mg)) was attempted, stabilising the parenchymal disease over a 6-month period,

* Corresponding author. North Bristol Interstitial Lung Disease Service, Southmead Hospital, Bristol, UK.
E-mail address: Shaney.Barratt@nbt.nhs.uk (S.L. Barratt).

Abbreviations used

FEV1	Forced expiratory volume in 1 second
FVC	Forced vital capacity
TLCO	Transfer factor for carbon monoxide
KCO	Transfer coefficient

ECG	Electrocardiogram
HRCT	High Resolution Computed Tomography
PE	Pleural effusion
ACE	Angiotensin converting enzyme
MRI	Magnetic resonance imaging

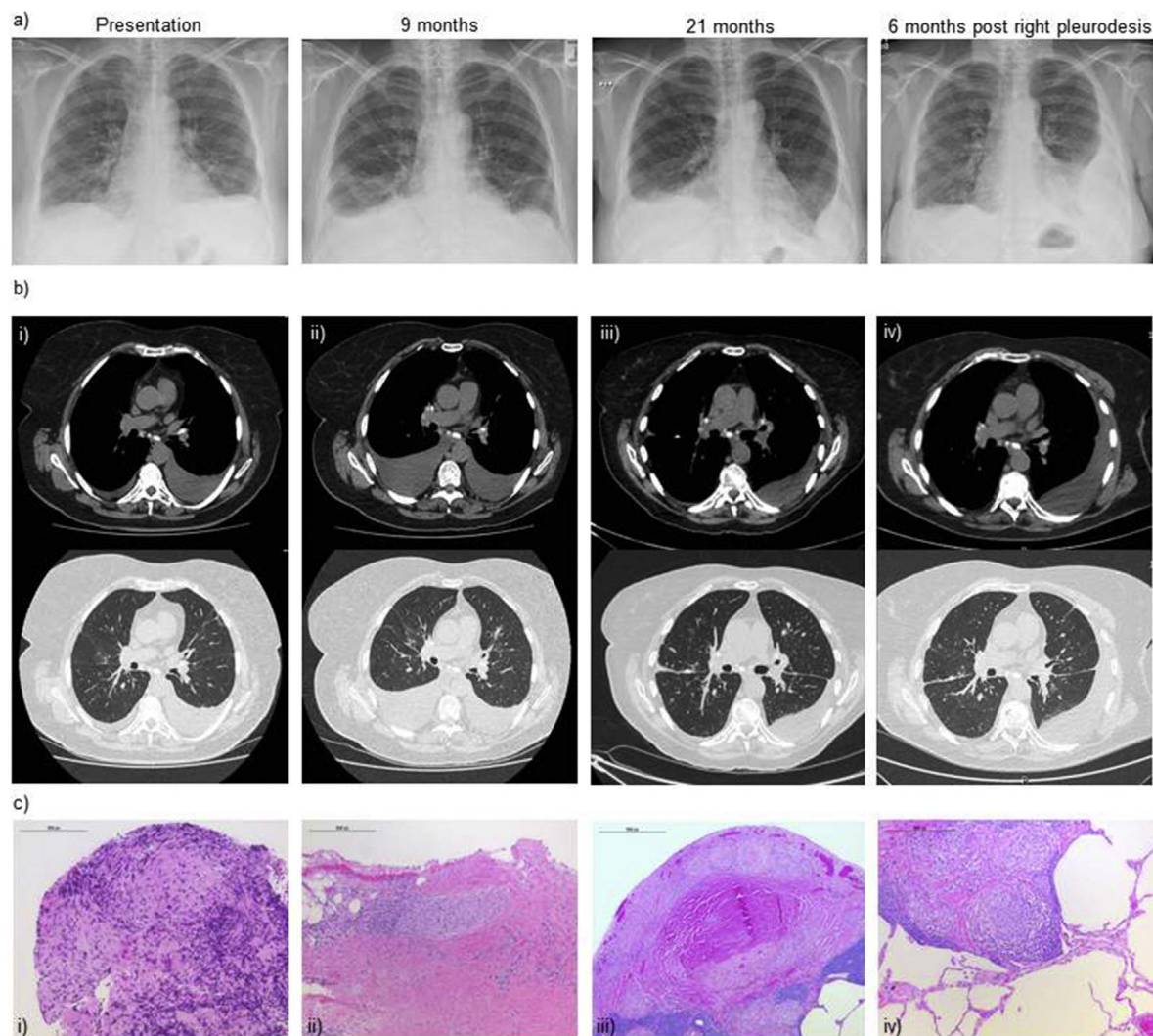


Fig. 1. a) CXR and representative HRCT images taken at presentation, 9 months and 21 months and 6 months post right talc pleurodesis. (i) CXR at presentation demonstrates blunting of the costophrenic angles with scattered peribronchial thickening in the mid and lower zones. (ii) CXR 9 months later following a tapering course of prednisolone therapy and maintenance of 10mg daily, demonstrating blunting of the costophrenic angles with worsening of the right sided effusion. (iii) CXR at 21 months following repeated trials of tapering prednisolone, attempted diuresis and trial of methotrexate therapy in conjunction with 10mg prednisolone: CXR demonstrates persistent pleural effusions with apparent worsening of both right and left effusions. (iv) CXR 6 months' post pleurodesis on prednisolone 10mg once daily, hydroxychloroquine 200mg twice daily and azathioprine 150mg once daily. No reaccumulation of right effusion. b) Representative HRCT images taken at presentation and 9 months later: Soft tissue windows above and lung windows below of i) HRCT images taken at presentation demonstrating mediastinal and hilar nodal calcification, perilymphatic nodularity and bilateral pleural effusions, left larger than right. ii) Nine months later following a tapering course of prednisolone therapy and maintenance of 10mg daily. Stable mediastinal and hilar nodal calcification and perilymphatic nodularity with bilateral pleural effusions, worsening on the right. (iii) Four weeks post right talc-pleurodesis. Worsening nodularity in the context of slight increase of left sided-effusion. (iv) Six months after right-talc pleurodesis. Stable appearances of lung nodularity in the context of worsening left effusion on prednisolone, hydroxychloroquine and azathioprine. c) Histological analysis i) Endobronchial biopsy demonstrates non-caseating granuloma. ii) Right sided VATS pleural biopsy demonstrating pleural and iii) subpleural based non-caseating granulomatous inflammation with surrounding lymphocytic infiltration and accompanying fibrosis. iv) Concurrent VATS lung wedge biopsy demonstrates an additional interstitial sarcoidal granuloma. ZN and Wade-Fite stains were negative excluding tuberculosis. No malignancy was seen. Scale bar indicates 500 μ m.

but was associated with continued pleural fluid accumulation on the left, in the absence of re-accumulation on the right. The patient was subsequently referred for left-sided talc pleurodesis with a proposed plan to seek funding for anti-Tumour Necrosis Factor- α biological therapy if this failed.

2. Discussion

Sarcoidosis is a multisystem disease characterised by non-caseating granulomas. Whilst it most frequently affects the lungs and lymph nodes, extrapulmonary presentations of the skin and eyes are also common. The differential diagnosis for nodal calcification and

Laboratory tests		Pleural Fluid Analysis	
Variable	Result	Variable	Result
Full Blood Count	Normal	Nature	Exudative
Renal function	Normal	Appearance	Serous, yellow
Liver function tests	Normal	pH	7.40
Serum Calcium	Normal	ADA (U/L)	15
ACE (nmol/mL/min)	60 (mildly elevated)	Cytological analysis	No malignant cells seen.
Immunoglobulin levels	Normal	Flow cytometry	Normal B and T cell ratios
Auto-immune profile	Negative	Chylomicrons	None seen
NT-proBNP level (pg/ml)	145 (normal)	Differential cell count	Lymphocytes 70%, macrophages 25% and neutrophils 5%.
24 hour excreted urinary calcium	Normal	Mycobacterial smear and culture	Negative

Fig. 2. Laboratory investigations and pleural fluid analysis results. Abbreviations: ACE angiotensin-converting enzyme, ADA adenosine deaminase, NT-Pro-BNP N-terminal pro b-type natriuretic peptide.

parenchymal nodularity in this patient includes sarcoidosis, tuberculosis (TB) and occupational lung disease. The perilymphatic distribution of nodules would be suggestive of sarcoidosis and could account for the lymph node calcification. There has been no exposure to TB or silica making the latter diagnoses less likely.

Pleural involvement is a rare manifestation with variable reported incidence of effusion on chest radiograph as low as 0.16% in the largest retrospective cohort analysed to date [1]. Studies using thoracic ultrasound, with its superior sensitivity in detecting effusions indicate a higher incidence of 2.8% [2]. The limited data available from small case series of sarcoidosis-related pleural effusions (PEs) suggests they are often exudative and lymphocytic [2], typically with a CD4+/CD8+ ratio between 2.61 and 8.6 [3]. They are also more commonly right-sided (45%) and less frequently bilateral (22%) [4]. The largest case series has demonstrated that 60% of PEs in such cases were not related to sarcoidosis itself [2], and were attributable other processes such as ischaemic cardiomyopathies or infection. Serum amyloid A, soluble interleukin-2 receptor (sIL-2R), lysozyme and the glycoprotein KL-6 have all been proposed as potential serum biomarkers for sarcoidosis but each lacks specificity and sensitivity for clinical usage and to the authors knowledge have not been validated in pleural fluid [5]. The identification of pleural effusions (PEs) in this patient therefore prompted thorough investigation of the aetiology of both the interstitial lung disease and PEs.

The differential diagnosis of a lymphocytic PE includes; carcinoma, TB, lymphoma, chronic heart failure, autoimmune diseases and sarcoidosis. As the effusion was cytologically negative and CT showed no evidence of nodular or mediastinal thickening, malignancy was less likely. It is important to exclude tuberculosis and this was effectively achieved with normal pleural ADA levels in a Caucasian female. Lymphoma should also be considered and assessment of fluid lymphocyte subsets is useful to exclude this possibility. Finally, as the effusions were bilateral and lymphocytic, the chances of this being due to an autoimmune process or heart failure were increased. The patient was

investigated accordingly with autoimmune profile, ECHO and cardiac MRI.

The significant, bilateral pleural involvement at initial presentation in this case is atypical for pleural sarcoidosis, as is the worsening of pleural disease control despite immunomodulatory therapy (Fig. 3 [6–15]). The vast majority of sarcoidosis-related PEs reported in the literature have been small and spontaneously resolve [16], whilst patients with larger symptomatic effusions have received corticosteroid therapy alone or in combination with hydroxychloroquine, with a good response (see Fig. 3) [6–15].

Current paradigms suggest PEs may develop in the context of sarcoidosis due to inflammation of the visceral and parietal pleura secondary to peripheral lung granulomas [2]. The histology presented in this case certainly supports this hypothesis. Whilst PEs can occur in any of the Scadding radiological stages of sarcoidosis [4], there is a tendency to form during acute exacerbations [2]. Suppressing the immune response should therefore decrease net pleural fluid formation. The failure to do so in this case either suggests suboptimal control or an alternative mechanism behind fluid formation.

3. Conclusion

In summary, the presence of a large symptomatic PE in a patient with sarcoidosis is uncommon and should prompt further investigation for an alternate aetiology. In refractory cases, such as the one illustrated, invasive pleural intervention and immunomodulatory therapies may be required.

Declarations

None declared.

Author	Demographics	CT findings	Pleural fluid characteristics	Treatment
Fontecha Ortega et al. 2017.	38 yr male African	Bilateral, predominantly right PE with mediastinal and hilar lymphadenopathy and patchy alveolar infiltrates.	Lymphocytic, exudative. ADA 72U/L. CD4+/CD8+ ratio >3.5.	Good response to oral corticosteroids.
Jha et al. 2016.	65 yr male	Multiple discrete and conglomerating heterogeneous mediastinal and bilateral hilar lymphadenopathy. Right lower lobe ground glass opacities with minimal pleural right PE.	Haemorrhagic : Haematocrit 1.4%. Lymphocytic, exudative. ADA 53.2U/L.	Drainage of effusion via medical thoracoscopy. Good response to oral corticosteroids.
Jenkins et al. 2016.	46 yr male African American	Moderate right PE with moderate to large pericardial effusion	PE not sampled.	Good response to oral corticosteroids
Joshi et al. 2015.	42 yr male	Diffuse micronodules with predilection for fissures and bronchovascular bundles and associated mediastinal lymphadenopathy. Multiple subcentimetric focal lesions diffusely scattered in liver, spleen and renal parenchyma. Subsequently developed large left PE.	Lymphocytic, exudative. ADA 5.93 U/L.	PE developed whilst on oral corticosteroids (prednisolone 30mg). PE drained by pleuroscopy. No reaccumulation on prednisolone and hydroxychloroquine.
Seashore et al. 2015.	63 yr female African American	Large pericardial effusion with numerous right parenchymal lung nodules, intrathoracic lymph node calcification and large left PE.	Lymphocytic, exudative. ADA 18.6U/L. CD4+/CD8+ ratio >5.	Good response to 12 months of oral corticosteroids.
Kumagai et al. 2015.	64 yr female Japanese	Bilateral hilar and multiple mediastinal lymphadenopathy, multiple parenchymal nodules, multiple skin nodules and bilateral PEs.	Lymphocytic exudative. ADA 50.4U/L. CD4+/CD8+ ratio >5.62.	Thoracentesis initially. Good response to oral corticosteroids.
Enomoto et al. 2015.	69 yr male	Bilateral PEs associated with numerous lung parenchymal and pleurally based micronodules.	Lymphocytic exudative. ADA right, 46.7 U/L; left, 42.6 U/L.	Good response to corticosteroids 0.5mg/kg for one month.
Wang et al. 2014.	1) 39 yr male	Bilateral diffuse parenchymal nodules and hilar lymph node enlargement, pericardial effusion and bilateral moderate PEs.	Lymphocytic, exudative. ADA 37U/L.	Good response to oral corticosteroids over 3 months.
	2) 49 yr female	Right middle lobe atelectasis, right hilar lymphadenopathy and right moderate PE.	Lymphocytic, exudative. ADA 14U/L.	Good response to oral corticosteroids over 3 months.
	3) 51 yr female	Multiple nodules in upper zones, bilateral hilar lymphadenopathy, and bilateral moderate PE.	Lymphocytic, exudative ADA 17U/L.	Good response to oral corticosteroids. Complete resolution at 6 months.
Shin et al. 2014.	52 yr female	Bilateral mediastinal and hilar lymphadenopathy, left-sided PE, diffuse parenchymal infiltrates. Endobronchial mass at bronchoscopy.	Lymphocytic, transudative.	Good response to oral corticosteroids over 3 months.
Ferreiro et al. 2014.	1) 45 yr male	Bilateral hilar lymphadenopathies, right PE, micronodular disease and probable massive fibrosis in the right side.	Lymphocytic, exudative. ADA 36U/L. Milky: Chylomicrons present, Triglycerides 251 mg/dl.	Good response to ocreotide and oral corticosteroids. PE reaccumulated when prednisolone tapered to <10mg/day.
	2) 83 yr female	Multiple bilateral hilar and paratracheal mediastinal lymphadenopathies, moderate left PE and suspected micronodular disease.	Lymphocytic. ADA 45U/L.	Good response to oral corticosteroids.
	3) 39 yr male	Bilateral hilar lymphadenopathies, small left PE and bilateral interstitial disease.	PE not sampled.	Good response to oral corticosteroids.

Fig. 3. Literature review of small case series and case reports of pleural effusion attributable to sarcoidosis between 2014 and 2017. Abbreviations: PE Pleural effusion, yr year, ADA adenosine deaminase.

Contributorship

All authors have contributed to the manuscript and management of the patient equally.

Appendix A. Supplementary data

Supplementary data related to this article can be found at <http://dx.doi.org/10.1016/j.rmcr.2018.01.007>.

References

- [1] A. Tommasini, G. Di Vittorio, F. Facchinetti, G. Festi, V. Schito, A. Cipriani, Pleural effusion in sarcoidosis: a case report, *Sarcoidosis* 11 (2) (1994) 138–140.
- [2] J.T. Huggins, P. Doelken, S.A. Sahn, L. King, M.A. Judson, Pleural effusions in a series of 181 outpatients with sarcoidosis, *Chest* 129 (6) (2006) 1599–1604.
- [3] N. Rodríguez, C. Rábade, L. Valdés, Sarcoid pleural effusion, *Med. Clin.* 143 (2014) 502–507.
- [4] N.T. Soskel, O.P. Sharma, Pleural involvement in sarcoidosis, *Curr. Opin. Pulm. Med.* 6 (5) (2000) 455–468.
- [5] H. Ahmedzai, W.S.J. Loke, S. Huang, C. Herbert, D. Wakefield, P. Thomas, Biomarkers in sarcoidosis: a review, *Curr. Biomark. Find.* 4 (2014) 93–106.
- [6] M. Fontecha Ortega, S.J. Rodríguez Álvarez, J.L. García Satué, Pleural effusion: a rare manifestation of sarcoidosis, *Arch. Bronconeumol.* 53 (3) (2017 Mar) 170–171.
- [7] O. Jha, V. Nair, D. Talwar, Hemorrhagic sarcoid pleural effusion: a rare entity, *Lung India* 33 (5) (2016 Sep-Oct) 532–536.
- [8] D.N. Jenkins, K.V. Bean, M.S. Malik, 'Idiopathic' effusions get a proper name, *Respiration* 92 (2) (2016) 114–117.
- [9] S. Joshi, P. Periwal, V. Dogra, D. Talwar, Sarcoidosis as unusual cause of massive pleural effusion, *Respir. Med. Case Rep.* 16 (2015 Oct 13) 143–145.
- [10] J.B. Seashore, J.J. Silbiger, O. Epelbaum, Uncovering the diagnosis, *Thorax* 70 (12) (2015 Dec) 1205–1208.
- [11] T. Kumagai, Y. Tomita, T. Inoue, J. Uchida, K. Nishino, F. Imamura, Pleural sarcoidosis diagnosed on the basis of an increased CD4/CD8 lymphocyte ratio in pleural effusion fluid: a case report, *J. Med. Case Rep.* 9 (2015 Aug 14) 170.
- [12] Y. Enomoto, K. Yokomura, T. Suda, Bilateral pleural effusion associated with miliary sarcoidosis, *Am. J. Respir. Crit. Care Med.* 191 (4) (2015 Feb 15) 474–475.
- [13] F. Wang, Z. Tong, Z. Wang, X. Wang, X. Zhan, H. Shi, Application of medical thoracoscopy in diagnosis of sarcoidosis-related pleural effusion, *Respirol. Case Rep.* 2 (3) (2014 Sep) 99–101.
- [14] K.H. Shin, K.U. Kim, G. Lee, H.K. Park, Endobronchial mass and ipsilateral pleural effusion as presenting features of sarcoidosis, *J. Formos. Med. Assoc.* 113 (12) (2014 Dec) 974–975.
- [15] L. Ferreiro, E. San José, F.J. González-Barcala, J. Suárez-Antelo, M.E. Toubes, L. Valdés, Pleural effusion and sarcoidosis: an unusual combination, *Arch. Bronconeumol.* 50 (12) (2014 Dec) 554–556.
- [16] M. Cohen, S.A. Sahn, Resolution of pleural effusions, *Chest* 119 (5) (2001) 1547–1562.