

## ORIGINAL ARTICLE

# Usefulness of Decapolar catheter via femoral approach on CS cannulation during CRT device implantation

Rajeev Sharma | Archit Dahiya  | Piyush Joshi | Tushar Wadhawan | Harsh Wardhan

Department of Cardiology, Mahatma Gandhi Medical College and Hospital, Jaipur, Rajasthan, India

**Correspondence**

Archit Dahiya, Department of Cardiology, Mahatma Gandhi Medical College and Hospital, Jaipur, Rajasthan, India.  
Email: [dahiya.archit@gmail.com](mailto:dahiya.archit@gmail.com)

**Funding information**

None.

**Abstract**

**Introduction:** Cardiac resynchronization therapy (CRT) device insertion comprises of a transvenous pacing lead implanted in posterolateral branch of the coronary sinus (CS) for left ventricular (LV) pacing, in addition to leads in the right ventricle and right atrium. In patients undergoing CRT device implantation, failure of CS cannulation was earlier reported to be around 10% but has come down to about 4% in recent years. Although the use of electrophysiology (EP) catheter has been reported during CRT procedures but femoral approach to place decapolar catheter as fluoroscopic guide for CS ostium cannulation during LV lead implantation has not been evaluated.

**Materials and methods:** The aim of the study was to compare fluoroscopy time during CRT procedure between conventional technique and using decapolar EP catheter via femoral approach as fluoroscopic marker to cannulate CS.

**Results:** This study included 21 patients. Group 1 (using decapolar catheter) had 12 patients and group 2 (using the conventional technique) had 9 patients. CS cannulation was successful in all 21 cases. The mean fluoroscopy time for the CS cannulation and LV lead placement in group 1 was 10.7 ( $\pm 1.03$ ) min and in group 2 was 19.1 ( $\pm 1.51$ ) min. This difference in mean fluoroscopy time for the CS cannulation and LV lead placement was statistically significant with  $p < .05$ .

**Conclusion:** This study highlights the usefulness of decapolar catheter via femoral approach as a fluoroscopic guide for CS cannulation during CRT device implantation. The decreased fluoroscopic time results in decreased radiation exposure to not only the patient but also to the operator.

**KEYWORDS**

coronary sinus, CRT, electrophysiology catheter, heart failure, LBBB

## 1 | INTRODUCTION

Cardiac resynchronization therapy (CRT) has represented a revolution in the treatment of heart failure (HF). Cardiac resynchronization therapy is generally indicated for patients with HF who despite

receiving optimal pharmacologic therapy for HF are symptomatic and who meet the following criteria: left ventricular ejection fraction (LVEF)  $\leq 35\%$  with either left bundle branch block (LBBB) morphology with QRS duration  $\geq 130$  ms or non-LBBB morphology with QRS duration  $\geq 150$  ms.

This is an open access article under the terms of the [Creative Commons Attribution-NonCommercial-NoDerivs](https://creativecommons.org/licenses/by-nc-nd/4.0/) License, which permits use and distribution in any medium, provided the original work is properly cited, the use is non-commercial and no modifications or adaptations are made.

© 2022 The Authors. *Journal of Arrhythmia* published by John Wiley & Sons Australia, Ltd on behalf of Japanese Heart Rhythm Society.

Cardiac resynchronization therapy device insertion comprises of a transvenous pacing lead implanted in posterolateral branch of the coronary sinus (CS) for left ventricular (LV) pacing, in addition to leads in the right ventricle and right atrium. In patients undergoing CRT device implantation, failure of CS cannulation was earlier reported to be around 10% but has come down to about 4% in recent years.<sup>1-5</sup> Although the use of electrophysiology (EP) catheter has been reported during CRT procedures but femoral approach to place decapolar catheter as fluoroscopic guide for CS ostium cannulation during LV lead implantation has not been evaluated.<sup>6</sup> Hence, the need for this study to compare fluoroscopy time during CRT procedures between conventional technique and using decapolar catheter as guide to CS cannulation.

## 2 | MATERIALS AND METHODS

The aim of the study was to compare fluoroscopy time during CRT procedure between conventional technique and using decapolar EP catheter via femoral approach as a fluoroscopic marker to cannulate CS.

This single operator retrospective analysis study was conducted at the Department of Cardiology, Mahatma Gandhi Medical College and Hospital, Jaipur, India and included all patients who underwent CRT implantation between March 2019 and April 2022.

Inclusion criteria were adult patients (age  $\geq 21$  years) who underwent CRT implantation with HF with reduced ejection fraction (LVEF  $\leq 35\%$ ), sinus rhythm, LBBB with a QRS duration greater than or equal to 130ms or non-LBBB with a QRS duration greater than or equal to 150ms, and NYHA class II-IV symptoms in patients whose medical therapy has been optimized. Exclusion criteria included patients who did not give written consent.

In all, 21 patients underwent this procedure between March 2019 and April 2022. Patients in group 1 ( $n = 12$ ) underwent CRT procedure using decapolar EP catheter via femoral approach to

cannulate CS and patients in group 2 ( $n = 9$ ) underwent CRT procedure via conventional technique. In the conventional technique, one decapolar EP catheter was used via axillary approach to cross sheath into the CS. However, in group 1 we used two decapolar catheters, first one was used via femoral approach to cannulate CS to act as a fluoroscopic marker and the second one was similar to conventional technique, that is, via axillary vein to cross sheath in CS.

All patients underwent coronary angiography before the CRT procedure, during which CS was seen in LAO view during levo-phase of left coronary angiogram. In this study, all patients received CRT-D devices (Boston scientific). Decapolar EP catheters were 6F Inquiry Steerable Diagnostic Catheters (St. Jude Medical). Out of all the LV Leads during procedures, six were straight leads, eight were short spiral leads, and seven were long spiral leads. Acuity Pro Lead Delivery System using Acuity Pro CS outer catheters were used in all procedures. No inner catheter was used for LV lead placement. All the data were recorded in a Microsoft Excel spreadsheet and analyzed. The student's t-test was used to calculate the  $p$ -value.

## 3 | RESULTS

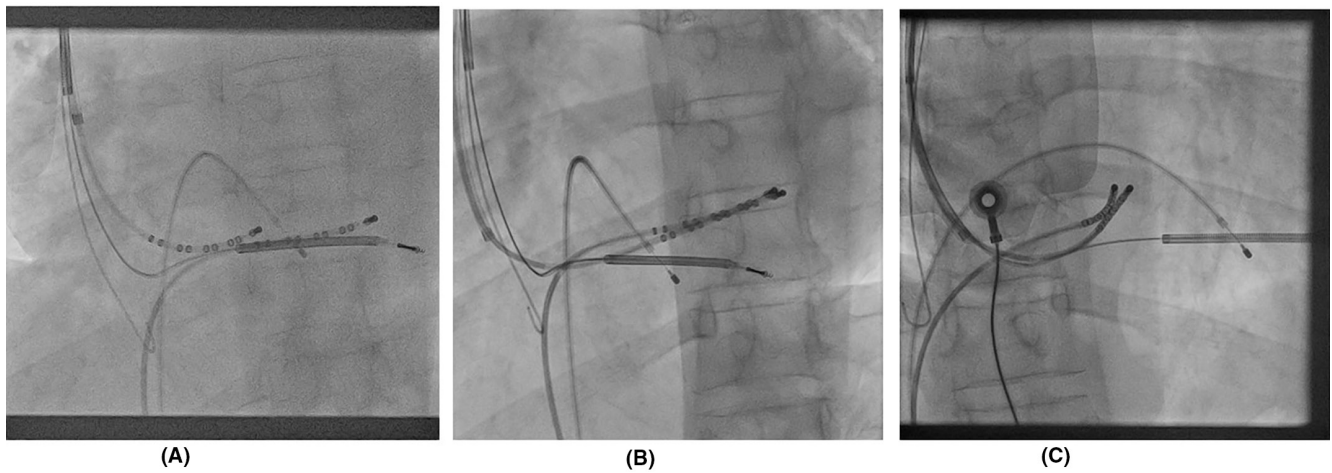
This study included 21 patients. Group 1 (using decapolar catheter) had 12 patients and group 2 (using the conventional technique) had 9 patients. CS cannulation was successful in all 21 cases. The mean age in group 1 was 64.2 years while in group 2 mean age was 65.4 years. Out of 12 patients in group 1, 9 were males and 3 females. In group 2, 5 were males and 4 females. All patients in this study had LBBB morphology on electrocardiogram. Mean LVEF in group 1 was 23.5% and in group 2 was 22.4% (Table 1).

The fluoroscopic views depicting position of decapolar catheter in our study is shown in Figure 1 for group 1 and in Figure 2 for group 2.

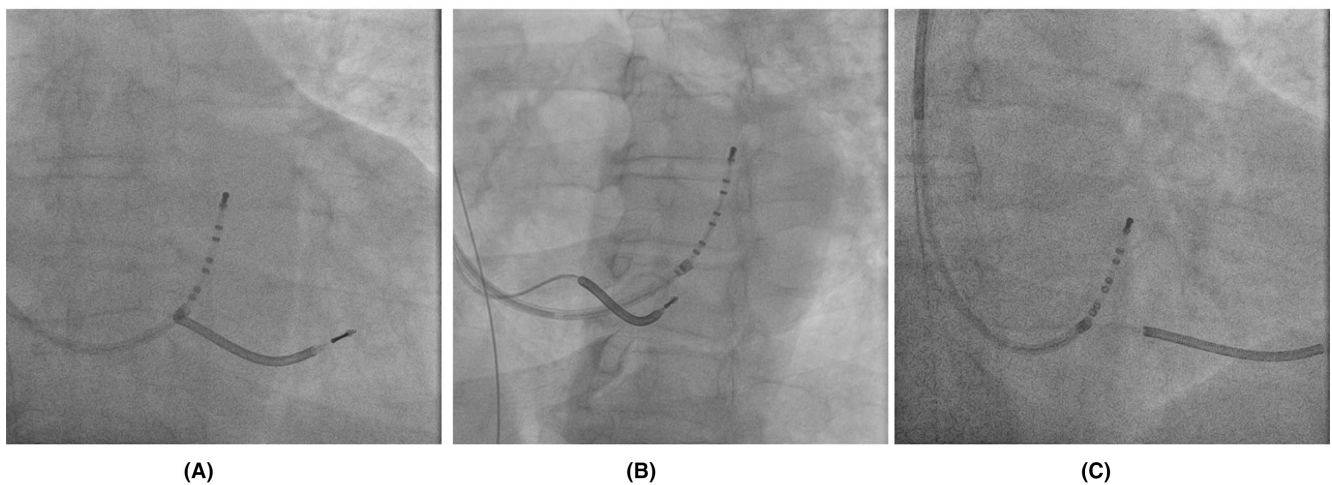
TABLE 1 Baseline characteristics

	Group 1 (using decapolar catheter via femoral approach) ( $n = 12$ )	Group 2 (using the conventional technique) ( $n = 9$ )
Mean age	64.2 years	65.4 years
Sex	9 males (75%) 3 females (25%)	5 males (56%) 4 females (44%)
CAD/ischemic cardiomyopathy	4 (33%)	3 (33%)
Non-ischemic cardiomyopathy	8 (67%)	6 (67%)
LBBB	12 (100%)	9 (100%)
Non-LBBB	0	0
LVEF (mean %)	23.5 $\pm$ 4.5	22.4 $\pm$ 5.2
CRT-D	12 (100%)	9 (100%)
CRT-P	0	0
NYHA	NYHA II-3 (25%) NYHA III-7 (58%) NYHA IV-2 (17%)	NYHA II-1 (11%) NYHA III-5 (56%) NYHA IV-3 (33%)

Abbreviations: CAD, coronary artery disease; CRT, Cardiac resynchronization therapy; LBBB, left bundle branch block; LVEF, left ventricular ejection fraction; NYHA, New York Heart Association Functional Classification.



**FIGURE 1** Fluoroscopic views showing femoral approach to cannulate coronary sinus (CS) to act as marker and second electrophysiology (EP) catheter via axillary vein to cross sheath in CS: (A) AP fluoroscopic view, (B) LAO view, and (C) RAO view. AP, anteroposterior; LAO, left anterior oblique; RAO, right anterior oblique.



**FIGURE 2** Fluoroscopic views showing cannulation of coronary sinus (CS) using conventional technique with electrophysiology (EP) catheter via axillary vein to cross sheath: (A) AP fluoroscopic view, (B) LAO view, and (C) RAO view. AP, anteroposterior; LAO, left anterior oblique; RAO, right anterior oblique.

The mean fluoroscopy time for the CS cannulation and LV lead placement in group 1 was 10.7 ( $\pm 1.03$ ) min and in group 2 was 19.1 ( $\pm 1.51$ ) min. The difference in mean fluoroscopy time was statistically significant with  $p < 0.05$  (Table 2). Also, the mean total fluoroscopy time and the surgery time in our study were statistically significant. In this study, we were able to cannulate CS on the first try itself in all patients without changing hardware/catheter.

#### 4 | DISCUSSION

Implantation of CRT devices is technically difficult and is even challenging to the most experienced operators. The optimal placement of an LV lead in a tributary of the CS is one of the most challenging technical aspects of CRT device implantation and can often lead to increased fluoroscopy times. Various trials have reported failure

rates of up to 10% due to unsuccessful cannulation of CS or unsuccessful placement of the LV lead into a targeted branch.<sup>7</sup>

Generally, guiding catheters are used via axillary approach for LV sheath cannulation of CS ostium. Using guiding catheters is not only technically demanding but also time-consuming.<sup>8</sup> Electrophysiologists tend to use EP catheters instead of guiding catheters for LV sheath cannulation of CS ostium. In our study, patients in group 2 underwent conventional technique of using only one EP catheter via axillary vein for LV sheath cannulation of CS ostium, whereas patient in group 1 had decapolar EP catheter in CS via femoral vein as fluoroscopic guide to subsequent cannulation of the CS via axillary approach similar to conventional technique. After LV pacing lead placement to the posterolateral branch of CS, the decapolar EP catheter introduced via the femoral vein is withdrawn and the rest of the CRT implantation procedure is completed in the usual fashion.

TABLE 2 Mean fluoroscopy time and surgery time

	Group 1 (using decapolar catheter) (n = 12)	Group 2 (using the conventional technique) (n = 9)	p-value (significant if p < .05)
Mean fluoroscopy time for the CS cannulation and LV lead placement (SD)	10.7 ( $\pm$ 1.03) min	19.1 ( $\pm$ 1.51) min	<.05
Mean total fluoroscopy time (SD)	18.4 ( $\pm$ 2.53) min	26.4 ( $\pm$ 1.95) min	<.05
Surgery time (SD)	84.3 ( $\pm$ 9.68) min	94.7 ( $\pm$ 9.01) min	<.05

Abbreviations: CS, coronary sinus; LV, left ventricle.

This novel approach via femoral vein not only acts as fluoroscopic marker, but also helps in straightening of CS for easier cannulation subsequently via axillary vein. The mean fluoroscopy time in our study was lower in group 1 than in group 2 and was statistically significant with  $p < .05$ . Patients in group 1 had mean fluoroscopy time of 10.7 ( $\pm$ 1.03) min. Whereas patients in group 2 had mean fluoroscopy time of 19.1 ( $\pm$ 1.51) min.

Manolis AS et al. reported about using the EP catheter in a prospective series of 138 consecutive HF patients undergoing CRT system implantation. They achieved 95% success rate in LV lead placement using this technique.<sup>9</sup> However, they only used decapolar catheter via subclavian vein/axillary vein to insert sheath for LV lead placement.

Fikret Er et al reported comparison on 176 consecutive patients undergoing CRT implantation at the University Hospital of Cologne and concluded that total fluoroscopy time was significantly reduced with use of steerable EP catheter for CS cannulation.<sup>10</sup> However, similar to Manolis AS et al. study, they only used decapolar catheter via subclavian vein/axillary vein to insert sheath for LV lead placement.

In study published by De Martino G and colleagues in 2004, 34 patients were randomly assigned to the guiding catheter alone positioning strategy (18 patients) or EP catheter aided positioning strategy (16 patients) for CS cannulation. They showed that cannulation of CS with the adjunct of an EP catheter to dedicated delivery systems significantly reduces procedural time, fluoroscopy time, and contrast dye volume compared to a conventional strategy.<sup>11</sup>

In study published by Thomas E. Watts et al in 2015, patients undergoing femoral vein approach were compared with those undergoing a standard approach. Out of 135 patients, 60 were included in the femoral vein group and 75 in the non-femoral vein group. There was no significant difference in fluoroscopy time between the two groups.<sup>12</sup>

In case reported by Motallebi M in 2018, CRT upgrade was performed in a patient with dextrocardia and situs inversus totalis and was facilitated by CS cannulation with EP catheters from both femoral and axillary venous approaches. This case illustrated that the CS can be cannulated from a femoral approach with an EP catheter as a fluoroscopic landmark, if one anticipates difficult or abnormal anatomy for the CS cannulation from the subclavian approach.<sup>13</sup>

In case reported by Daniel Hofer and Alexander Breitenstein in 2020, dual approach from the subclavian vein using a snare through a sheath and from the femoral vein using a steerable EP catheter was performed. They presented an alternative approach as a bail-out strategy if all conventional options for CS cannulation have failed.

CS cannulation with a steerable catheter from a femoral approach may be easier due to variation in curve, push and bending of the catheter compared to a pectoral approach.<sup>14</sup>

## 5 | CONCLUSION

This study highlights the usefulness of decapolar catheter via femoral approach as a fluoroscopic guide for CS cannulation during CRT device implantation. The decreased fluoroscopic time results in decreased radiation exposure to not only the patient but also to the operator. However, larger randomized controlled trials are needed to corroborate the findings of this study and to apply it to a larger subset of the population needing CRT implantation.

## AUTHORS' CONTRIBUTIONS

All authors contributed to the study conception, design, material preparation, data collection, and analysis. All authors have read and approved the final manuscript.

## CONFLICT OF INTEREST

None.

## ETHICS APPROVAL

This study was approved by Institutional Ethics Committee.

## ORCID

Archit Dahiya  <https://orcid.org/0000-0003-2956-1795>

## REFERENCES

1. Gras D, Bocker D, Lunati M, et al. Implantation of cardiac resynchronization therapy systems in the CARE-HF trial: procedural success rate and safety. *Europace*. 2007;9:516–22.
2. DeRose JJ, Ashton RC, Belsley S, et al. Robotically assisted left ventricular epicardial lead implantation for biventricular pacing. *J Am Coll Cardiol*. 2003;41:1414–9.
3. Fernandez AL, Garcia-Bengochea JB, Ledo R, et al. Minimally invasive surgical implantation of left ventricular epicardial leads for ventricular resynchronization using video-assisted thoracoscopy. *Rev Esp Cardiol*. 2004;57:313–9.
4. Uhm JS, Park JW, Lee H, et al. Cardiac vein accessibility according to heart diseases and sex: implications for cardiac resynchronization therapy. *Pacing Clin Electrophysiol*. 2016;39(6):513–21. <https://doi.org/10.1111/pace.12843>
5. Hummel JD, Coppess MA, Osborn JS, et al. Real-world assessment of acute left ventricular lead implant success and complication rates: results from the attain success clinical trial. *Pacing Clin*

- Electrophysiol. 2016;39(11):1246–53. <https://doi.org/10.1111/pace.12939>
6. Bongiorno MG, Proclemer A, Dobrea D, Marinkis G, Pison L, Blomstrom-Lundqvist C, et al. Preferred tools and techniques for implantation of cardiac electronic devices in Europe: results of the European heart rhythm association survey. *Europace*. 2013;15:1664–8.
  7. Anh DJ, Chen HA, Eversull CS, Mourlas NJ, Mead RH, Liem LB, et al. Early human experience with use of a deflectable fiberoptic endocardial visualization catheter to facilitate coronary sinus cannulation. *Heart Rhythm*. 2006;3(8):875–8.
  8. Leon AR. New tools for the effective delivery of cardiac resynchronization therapy. *J Cardiovasc Electrophysiol*. 2005;16(Suppl 1): S42eS47.
  9. Manolis AS, Koulouris S, Tsiachris D. Electrophysiology catheter-facilitated coronary sinus cannulation and implantation of cardiac resynchronization therapy systems. *Hellenic J Cardiol*. 2018;59(1):26–33. <https://doi.org/10.1016/j.hjc.2017.07.008>
  10. Er F, Yüksel D, Hellmich M, et al. Comparison of conventional versus steerable-catheter guided coronary sinus Lead positioning in patients undergoing cardiac resynchronization device implantation. *PLoS One*. 2015;10(11):e0143292. <https://doi.org/10.1371/journal.pone.0143292>
  11. De Martino G, Sanna T, Dello Russo A, et al. A randomized comparison of alternative techniques to achieve coronary sinus cannulation during biventricular implantation procedures. *J Interv Card Electrophysiol*. 2004;10:227–30.
  12. Watts TE, Singh D, Sewani A, et al. Novel approach for biventricular pacing: utilizing temporary coronary sinus catheter guidance via a femoral vein approach. *J Innovat Cardiac Rhythm Manag*. 2015;6. <https://doi.org/10.19102/icrm.2015.060105>
  13. Motallebi M, Feizabadi N. Cardiac resynchronization therapy upgrade in a patient with dextrocardia and situs inversus Totalis, facilitated by coronary sinus cannulation with electrophysiology catheters from both femoral and axillary venous approaches. *J Innovat Cardiac Rhythm Manag*. 2018;9(4):3084–9. <https://doi.org/10.19102/icrm.2018.090401>
  14. Hofer D, Breitenstein A. Snare technique for coronary sinus cannulation in cardiac resynchronization therapy. *Indian Pacing Electrophysiol J*. 2020;20(6):293–5. <https://doi.org/10.1016/j.ipej.2020.09.004>

**How to cite this article:** Sharma R, Dahiya A, Joshi P, Wadhawan T & Wardhan H. Usefulness of Decapolar catheter via femoral approach on CS cannulation during CRT device implantation. *J Arrhythmia*. 2022;38:743–747. <https://doi.org/10.1002/joa3.12762>