




Contents lists available at ScienceDirect

Epilepsy & Behavior Reports

journal homepage: www.elsevier.com/locate/ebcr

Case Report

Aphasic status epilepticus of frontal origin treated by resective surgery

Yukie Nakayama, Hiroki Nishibayashi *, Mitsunori Ozaki, Toshikazu Yamoto, Yasuo Nakai, Naoyuki Nakao

Department of Neurological Surgery, Wakayama Medical University, 811-1 Kimiidera, Wakayama 641-0012, Japan

ARTICLE INFO

Article history:

Received 2 October 2019

Received in revised form 11 January 2020

Accepted 12 February 2020

Available online 23 March 2020

Keywords:

Aphasic status epilepticus

Resective surgery

Frontal lobe

ABSTRACT

Aphasic status epilepticus (SE) is a clinical entity of SE, but it has not been well recognized. We report a 43-year-old female with a chronic drug-resistant epilepsy with aphasic SE, treated by resective surgery. The patient showed long-lasting weekly episodes of hypokinesia, slow verbal response, and dysphasia, which were diagnosed as symptoms of aphasic SE. Magnetic resonance imaging showed encephalomalacia in the left frontal lobe with a hemosiderin rim. Intracranial electroencephalography revealed continuous spikes, predominantly on the left superior frontal gyrus with hemosiderin deposit. The aphasic symptoms were seen when ictal discharges gradually spread to the wide area of the left anterior frontal lobe, including the language area. The episodes of recurrent aphasic SE had disappeared by one year after the left anterior frontal resection. We should consider aphasic SE when language impairment is episodic, and consider surgical intervention in cases where it repeatedly occurs despite appropriate medical therapy.

© 2020 Published by Elsevier Inc. This is an open access article under the CC BY-NC-ND license (<http://creativecommons.org/licenses/by-nc-nd/4.0/>).

1. Introduction

A definition had been proposed for non-convulsive status epilepticus (NCSE): a change in behavior and/or mental status associated with 30 min of continuous epileptiform discharges in the electroencephalogram (EEG) [1]. A recent report proposed that emergency treatment should be initiated for focal status epilepticus (SE) with impaired consciousness at 10 min from onset [2]. NCSE is not able to be diagnosed from clinical signs alone. Therefore, emergent EEG is indispensable. Improvement of both clinical and EEG features with the administration of intravenous antiseizure medication may suggest a diagnosis of NCSE [3]. NCSE could be caused by various etiologies, including cerebral stroke [4], infection [5], metabolic disease [6,7], neurological disease [8], or epileptic syndrome as absence epilepsy [9]. It has a higher prevalence in the elderly population and in those with post-stroke epilepsy [4,10]. Aphasia may appear as a focal seizure [11], or as a symptom of SE. Aphasic SE has recently been included in the category of NCSE without coma, and sub-classified in focal SE [2]. Most reported cases with aphasic SE showed *de novo* onset and improved seizure outcomes with medical therapy [5,7,8,12–18]. However, to the best of our knowledge, no surgical cases *via* intracranial EEG recording have been reported for repeat aphasic SE. We report the case of a patient with weekly aphasic SE of

frontal origin, in which a resective surgery was effective in controlling the aphasic SE.

2. Case presentation

A 43-year-old right-handed female was admitted to our hospital with a 10-year history of drug-resistant seizures. She showed normal mental and physical development. She reported severe headaches during the postpartum period, seven years previous to the seizure onset; although, no neuroimaging examinations were performed. Her seizures began at the age of 33. Her habitual seizures manifested as the following: a focal aware cognitive seizure (aphasia) with abrupt onset; a focal aware clonic seizure, lasting for over 30 min, on the right-side of her face and arm, followed by post-ictal paralysis; and a long-lasting loss of spontaneous speech and hypokinesia with obscure onset, which occurred intermittently for one to two days. During the long-lasting symptom, she often lay in bed throughout the day without eating. This occurred weekly in the last one year before admission to the hospital, despite polytherapy with carbamazepine, levetiracetam, clobazam and perampanel. Neurological examination revealed no abnormality. The *Wechsler Adult Intelligence Scale - Third Edition* revealed a low intelligence quotient (IQ) (full IQ: 69, verbal IQ: 69, performance IQ: 74). The *Standard Language Test of Aphasia* disclosed disturbances in word fluency, semantic comprehension, and calculation (Table 1). Long-term scalp video-EEG showed the patient's indifferent face impression, hypokinesia, decreased spontaneous speech, slow verbal response, and dysphasia with no obvious ictal onset. This occurred approximately when the bilateral frontal dominant continuous slow

Abbreviations: SE, status epilepticus; EEG, electroencephalogram; NCSE, non-convulsive status epilepticus; MRI, magnetic resonance imaging.

* Corresponding author.

E-mail address: hirokin@wakayama-med.ac.jp (H. Nishibayashi).

<https://doi.org/10.1016/j.ebr.2020.100359>

2589-9864/© 2020 Published by Elsevier Inc. This is an open access article under the CC BY-NC-ND license (<http://creativecommons.org/licenses/by-nc-nd/4.0/>).

Table 1
Preoperative and postoperative results of the *Standard Language Test of Aphasia (SLTA)*.

SLTA (standard language test of aphasia)		Pre-test	Post-test
I. Hearing	Auditory word recognition	10/10	10/10
	Auditory sentence comprehension	10/10	10/10
	Verbal sequential commands	10/10	6/10
II. Speaking	Speech sound-kana letter choice matching	10/10	10/10
	Picture naming	18/20	10/20
	Word repetition	10/10	10/10
	Action naming	10/10	5/10
	Picture story description	Stage 6	Stage 4
	Sentence repetition	5/5	5/5
	Animal category fluency	13	7
	Oral reading of kanji word	5/5	5/5
	Oral reading of kana letter	10/10	10/10
	Oral reading of kana word	5/5	5/5
III. Reading	Written kanji word-picture choice matching	10/10	10/10
	Written kana word-picture choice matching	10/10	10/10
	Written sentence-picture choice matching	9/10	9/10
	Written sequential commands	10/10	8/10
	Writing kanji names of pictures	4/5	1/5
IV. Writing	Writing kana names of picture	5/5	4/5
	Writing picture story	Stage 6	Stage 4
	Writing kana letter to dictation	10/10	10/10
	Writing kanji word to dictation	4/5	2/5
	Writing kana word to dictation	5/5	5/5
	Writing dictated sentences	4/5	4/5
	V. Calculation	13/20	10/20

waves were recorded superimposed by spikes on Fp1, F3, C3 and F7. She could eat and perform activities of daily living during this time, however, this was done slowly. Her EEG findings and her verbal response markedly improved after an intravenous injection of diazepam. As this altered cognitive function continued for over 30 min, we diagnosed this long-lasting symptom as aphasic SE. Magnetic resonance imaging

(MRI) showed encephalomalacia with a hemosiderin rim around the left superior frontal sulcus (Fig. 1 upper right). Interictal [¹²³I]-iomazenil single-photon-emission computed tomography showed hypo-accumulation in the left frontal lobe, coincident with the MRI abnormality.

Considering the patient's seizure frequency and drug-resistance, we subsequently pursued epilepsy surgery localized by intracranial EEG monitoring using subdural electrodes. Intracranial EEG showed frequent spikes on the cortex around the cavity, as well as in the middle and inferior frontal gyri, and the orbitofrontal cortex (apparently without symptoms) (Fig. 2A). Subsequently, continuous spikes in these area were seen to coincide with unpleasant moods (Fig. 2B). The discharges then gradually spread to the posterior middle and inferior frontal gyri, at which she showed indifferent face impression, hypokinesia, decreased spontaneous speech, slow verbal response, and dysphasia (Fig. 2C). The clinical symptoms and EEG findings improved by oral administration of diazepam (Fig. 2D). The anterior language area was detected by direct electrical stimulation (rectangular biphasic 50 Hz, 0.2-millisecond pulse width, 1–5-second duration under 7 mA bipolar stimulation) (Fig. 1, left). With consideration of the extent of sustained spikes and the results of functional mapping, we performed the left anterior frontal resection beyond the MRI abnormality (Fig. 1, upper right). Aphasic SE and the other focal seizures have not been seen as of one year after surgery. However, one week after surgery, the *Standard Language Test of Aphasia* revealed decreased vocabulary, dysphasia and impaired semantic comprehension with dysgraphia, but she retained normal repetition ability (Table 1). Her speech disturbance was assessed as transcortical sensory aphasia, which improved with speech therapy over one month.

3. Discussion

Aphasia may be due to a focal seizure or as a symptom of SE. Epileptic aphasia was defined by Rosenbaum et al. with several criteria as

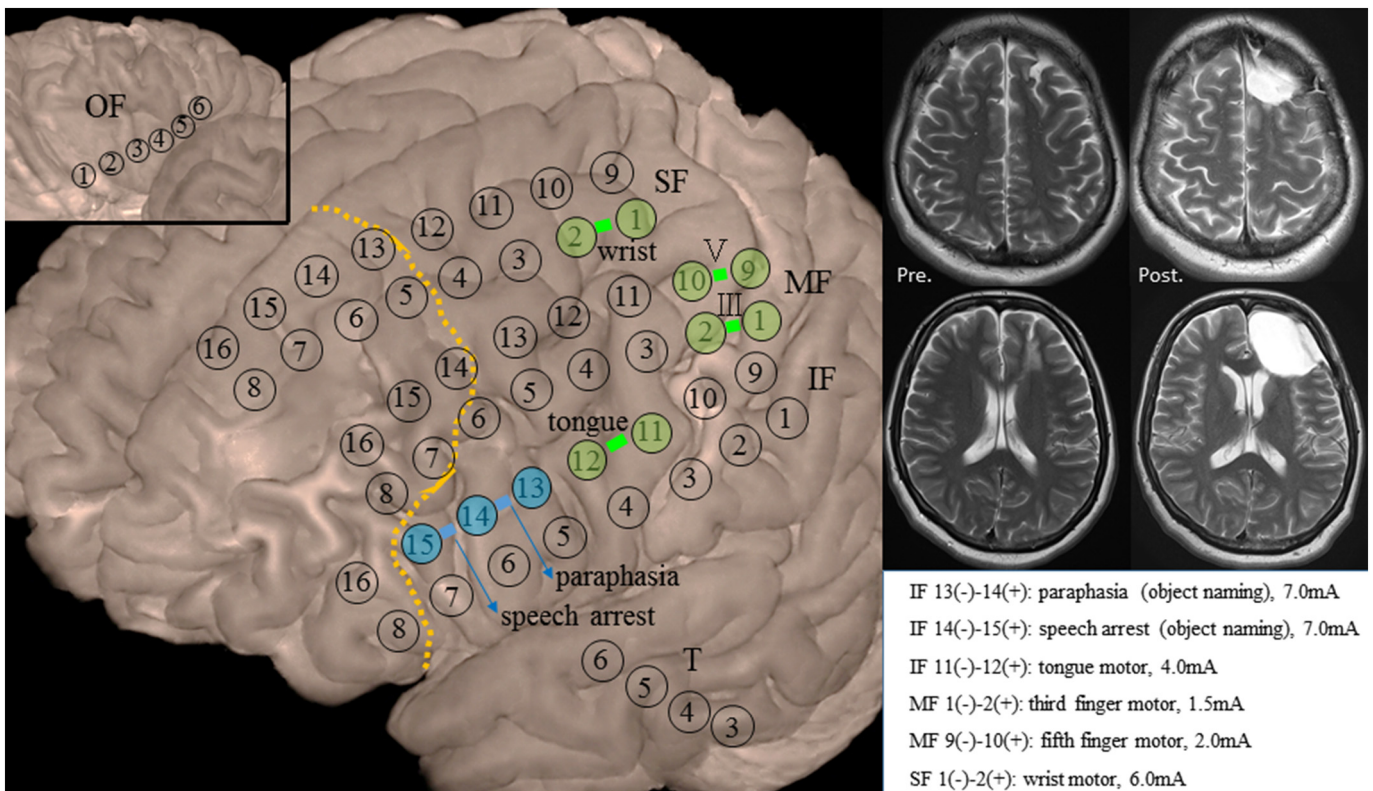


Fig. 1. Left anterior frontal resection with preserved language related area. Resection line (dotted line) and results of functional mapping. III: third finger, V: fifth finger, SF: superior frontal, MF: middle frontal, IF: inferior frontal, OF: orbitofrontal, T: temporal. Preoperative and postoperative MRI.

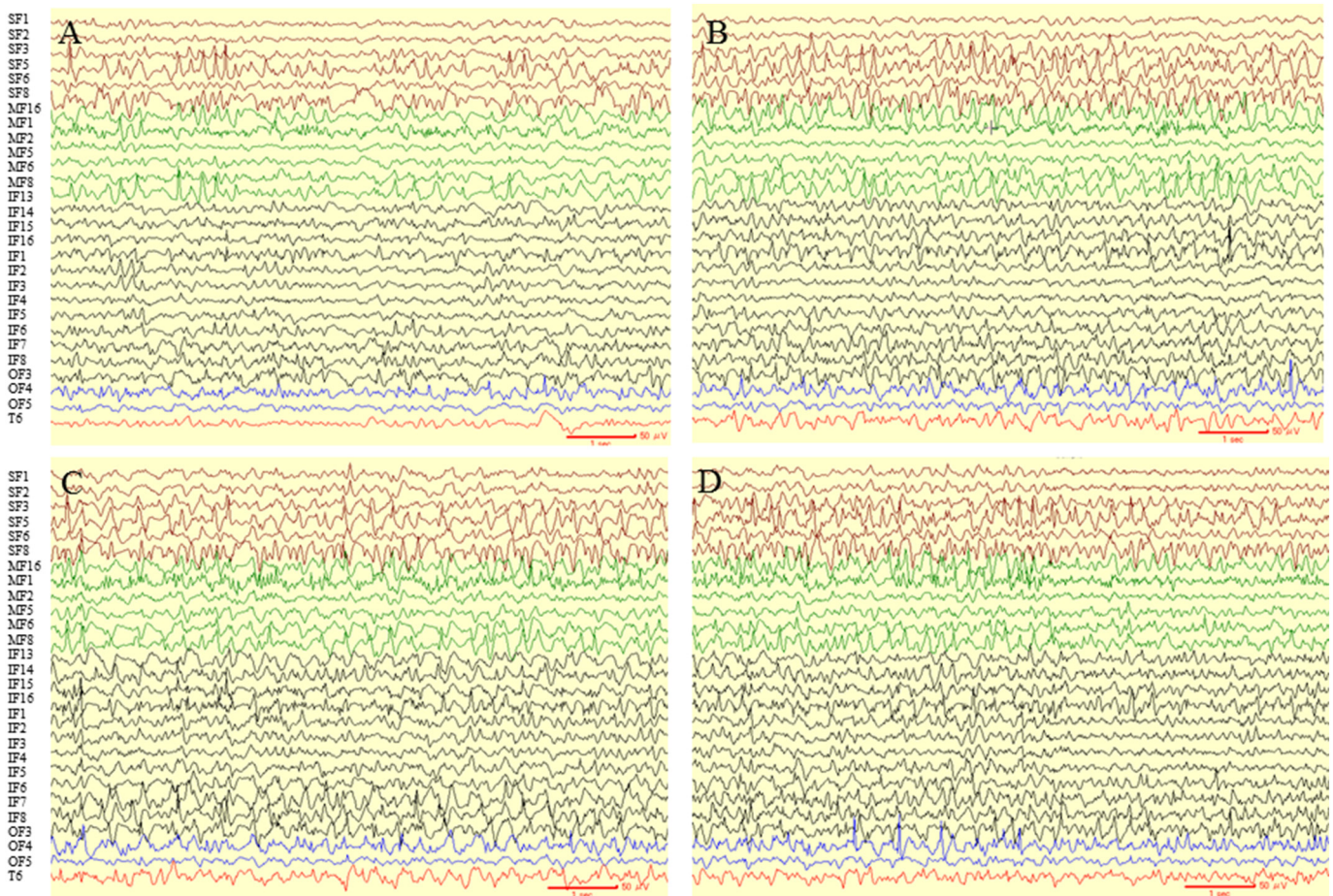


Fig. 2. Intracranial EEG showed frequent spikes on the cortex around the cavity, also in the middle and inferior frontal gyri, and the orbitofrontal cortex (A), then continuous spikes in these area caused her unpleasant moods (B). The discharges then gradually spread to the posterior middle and inferior frontal gyri (C). An oral administration of diazepam led to improvement of clinical symptoms and EEG findings over time (D).

follows: speaking during the seizure, aphasic features, alertness, and simultaneous EEG demonstrating seizure activity [19]. Grimes and Guberman reported a case of *de novo* aphasic SE and proposed a modification of this criteria including that aphasia should be resolved following successful treatment [17]. Recently, aphasic SE was classified in NCSE and sub-classified in NCSE without coma, focal type [2], although the duration of aphasic SE has not been precisely defined. In the present case, we documented the patient's long-lasting slow verbal response and dysphasia during the scalp Video-EEG monitoring. We diagnosed it as aphasic SE because her language fluency and facial impression recovered, corresponding with EEG improvement, due to an intravenous injection of diazepam.

Regarding aphasic SE, various symptoms have been reported as follows: aphemia/stuttering [12], Wernicke type aphasia [13], severe aphasia [14], and global aphasia [20]. NCSE of frontal origin could manifest as affective indifference [21]. The results of intracranial EEG demonstrated her symptoms (*e.g.*, decreased spontaneous speech, slow verbal response, dysphasia with accompanying indifferent facial impression, and hypokinesia), were of frontal origin. Meanwhile, her preserved consciousness could be explained by the thalamus or brainstem being spared from seizure propagation [22]; although, no depth electrodes were implanted in these deeper brain structures.

The majority of reported cases with aphasic SE showed *de novo* onset with various etiologies, such as a structural lesion, infection, metabolic disease, neurological disease, or upon antiseizure medication taper [5–8,12–14,15–18,23,24]. Most of these cases had improved seizure outcomes with only medical therapies, if the underlying diseases were well treated. With our patient, however, epilepsy surgery was

considered necessary because weekly aphasic SE had occurred over the last one year, despite appropriate use of medications. Recently, a child with drug-resistant epilepsy due to focal cortical dysplasia was successfully treated by complete lesionectomy; this was performed soon after the definite diagnosis of NCSE. Rapid cognitive decline of the patient in the last one year was considered to be related to frequent seizures and NCSE [25]. This clinical entity of aphasic SE is noteworthy; it presents the potential benefit from surgical intervention when disabling recurrent episodes are drug-resistant.

We performed intracranial EEG recordings as widespread epileptogenicity was suspected, involving language-related areas. It was challenging to decide the precise extent of the resection with the intracranial EEG findings alone during aphasic SE. Continuous spikes were recorded in the wide area of the left anterior frontal lobe, including the language area; although, precise time correlations between the aphasic symptoms and ictal discharges were at times less apparent. According to prior reports, electro-clinical correlation is sometimes unclear in aphasic SE [26], and aphasia may not correspond directly with the epileptiform activity [27]. Deciding on the border of resection considerably depended on the results of the brain anatomy and functional mapping.

Regarding the etiology of encephalomalacia with hemosiderin deposit, a peripartum intracerebral hemorrhagic stroke was suspected at the previous hospital [28]; however, there was no brain computed tomography evidence to provide radiographic support. NCSE occurs more prevalently in the elderly population [4]. It may also develop in middle-aged adults, similar to our patient, due to cerebral stroke as cerebral strokes are the main cause of adult NCSE [4,10].

4. Conclusion

Our patient presented with unique symptoms due to aphasic SE of frontal origin. This was verified by intracranial EEG. A tailored left anterior frontal resection was effective to control the recurrent episodes of aphasic SE. This case of aphasic SE is remarkable and supports a successful approach from surgical intervention, which may be necessary in cases where aphasic SE is difficult to treat and repetitive resulting in patient disability.

Declaration of competing interest

All the authors have no conflict of interest.

References

- [1] Meierkord H, Holtkamp M. Non-convulsive status epilepticus in adults: clinical forms and treatment. *Lancet Neurol* 2007;6:329–39.
- [2] Trinka E, Cock H, Hesdorffer D, Rossetti AO, Scheffer IE, Shinnar S, et al. A definition and classification of status epilepticus –report of the ILAE Task Force on classification of status epilepticus. *Epilepsia* 2015;56(10):1515–23.
- [3] Beniczky S, Hirsch LJ, Kaplan PW, Pressler R, Bauer G, Aurlien H, et al. Unified EEG terminology and criteria for nonconvulsive status epilepticus. *Epilepsia* 2013;54 (Suppl. 6):28–9.
- [4] Knake S, Rosenow F, Vescovi M, Oertel WH, Mueller HH, Wirbatz A, et al. Incidence of status epilepticus in adults in Germany: a prospective, population-based study. *Epilepsia* 2001;42(6):714–8.
- [5] Ozkaya G, Kurne A, Unal S, Oguz KK, Karabudak R, Saygi S. Aphasic status epilepticus with periodic lateralized epileptiform discharges in a bilingual patient as a presenting sign of “AIDS-toxoplasmosis complex”. *Epilepsy Behav* 2006;9:193–6.
- [6] Monti G, Pugnaghi M, Ariatti A, Mirandola L, Giovannini G, Scacchetti S, et al. Non-convulsive status epilepticus of frontal origin as the first manifestation of Hashimoto's encephalopathy. *Epileptic Disord* 2011;13(3):253–8.
- [7] Kye MS, Lee JJ, Kim BK, Kwon O, Park JM, Kang K, et al. Aphasic status epilepticus associated with uremia. *J Epilepsy Res* 2017;7:115–7.
- [8] Trinka E, Unterberger I, Spiegel M, Niedermuller U, Benke T, Berger T, et al. De novo aphasic status epilepticus as presenting symptom of multiple sclerosis. *J Neurol* 2002;249:782–3.
- [9] Scholtes FB, Renier WO, Meinardi H. Non-convulsive status epilepticus: causes, treatment, and outcome in 65 patients. *J Neurol Neurosurg Psychiatry* 1996;61:93–5.
- [10] Power KN, Gramstad A, Gilhus NE, Engelsen BA. Adult nonconvulsive status epilepticus in a clinical setting: semiology, aetiology, treatment and outcome. *Seizure* 2015;24:102–6.
- [11] Fisher RS, Cross H, D'Souza C, French JA, Haut SR, Higurashi N, et al. Instruction manual for the ILAE 2017 operational classification of seizure types. *Epilepsia* 2017;58(4):531–42.
- [12] Kaplan PW, Stagg R. Frontal lobe nonconvulsive status epilepticus: a case of epileptic stuttering, aphemia, and aphasia– not a sign of psychogenic nonepileptic seizures. *Epilepsy Behav* 2011;21:191–5.
- [13] Patil B, Oware A. De-novo simple partial status epilepticus presenting as Wernicke's aphasia. *Seizure* 2012;21:219–22.
- [14] Dinner DS, Luders HO, Lederman R, Gretter TE. Aphasic status epilepticus: a case report. *Neurology* 1981;31:888–90.
- [15] Chung PW, Seo DW, Kwon JC, Kim H, Na DL. Nonconvulsive status epilepticus presenting as a subacute progressive aphasia. *Seizure* 2002;11:449–54.
- [16] Caboclo LO. De novo aphasic status epilepticus presenting with frontal periodic lateralized epileptiform discharges. *Clin Neurophysiol* 2016;127:973–5.
- [17] Grimes DA, Guberman A. De novo aphasia status epilepticus. *Epilepsia* 1997;38(8):945–9.
- [18] Hamilton NG, Matthews T. Aphasia: the sole manifestation of focal status epilepticus. *Neurology* 1979;29:745–8.
- [19] Rosenbaum DH, Siegel M, Barr WB, Rowan AJ. Epileptic aphasia. *Neurology* 1986;36:822–5.
- [20] Flugel D, Kim OCH, Felbecker A, Tettenborn B. De novo status epilepticus with isolated aphasia. *Epilepsy Behav* 2015;49:198–202.
- [21] Thomas P, Zifkin B, Migneco O, Lebrun C, Darcourt J, Andermann F. Nonconvulsive status epilepticus of frontal origin. *Neurology* 1999;52:1174–83.
- [22] Takaya S, Matsumoto R, Namiki C, Kiyosu H, Isono O, Hashikawa K, et al. Frontal nonconvulsive status epilepticus manifesting somatic hallucinations. *J Neurol Sci* 2005;234:25–9.
- [23] Wells CR, Labar DR, Solomon GE. Aphasia as the sole manifestation of simple partial status epilepticus. *Epilepsia* 1992;33(1):84–7.
- [24] Pasquet EG, Gaudin ES, Bianchi A, Mendilaharsu S. Prolonged and monosymptomatic dysphasic status epilepticus. *Neurology* 1976;26:244–7.
- [25] Timer E, Charsouei S, Bebek N, Baykan B, Bilgic B, Sabanci PA, et al. Neurosurgical treatment of nonconvulsive status epilepticus due to focal cortical dysplasia. *Epilepsy Behav Case Rep* 2018;10:4–7.
- [26] Erikson EJ, Gerard EE, Macken MP, Schuele SU. Aphasic status epilepticus: electroclinical correlation. *Epilepsia* 2011;52(8):1452–8.
- [27] Quintas S, Rodriguez-Carrillo JC, Toledano R, Toledo M, Barrero FN, Berbis MA, et al. When aphasia is due to aphasic status epilepticus: a diagnostic challenge. *Neurol Sci* 2018;39:757–60.
- [28] Ohno Y, Kawai M, Morikawa S, Sakakibara K, Tanaka K, Ishikawa K, et al. Management of eclampsia and stroke during pregnancy. *Neurol Med Chir (Tokyo)* 2013;53:513–9.