

Dopamine Agonist-Induced Cerebrospinal Fluid Rhinorrhoea: A Case Report

Hira Irfan¹, Ahmed Imran Siddiqi¹, Umal Azmat¹, Waqas Shafiq¹, Irfan Yousaf², Muhammad Atif Naveed³

¹Department of Internal medicine, Shaukat Khanum Memorial Cancer Hospital and Research Centre, Lahore, Pakistan, ²Department of Surgical Oncology, Shaukat Khanum Memorial Cancer Hospital and Research Centre, Lahore, Pakistan, ³Department of Radiology, Shaukat Khanum Memorial Cancer Hospital and Research Centre, Lahore, Pakistan

Received: 09 December 2020/Accepted: 31 December 2020



OPEN ACCESS

Correspondence:

Hira Irfan, 7A Block R-3, Phase 2, M.A. Johar Town, Lahore, Punjab - 54782, Pakistan.

E-mail: hirairfan_@hotmail.com

Citation: Irfan H, Siddiqi AI, Azmat U, Shafiq W, Yousaf I, Naveed MA. Dopamine Agonist-Induced Cerebrospinal Fluid Rhinorrhoea: A Case Report. J Cancer Allied Spec [Internet]. 2021 Jan 6;7(1):1-6.

<https://doi.org/10.37029/jcas.v7i1.389>

Copyright: © 2021 Irfan, et al.

This is an open access article distributed under the terms of the [Creative Commons Attribution-NonCommercial-ShareAlike 4.0 International License](https://creativecommons.org/licenses/by-nc-sa/4.0/), which permits unrestricted use, distribution, and reproduction in any medium, provided the original author and source are credited.

Funding: The authors received no financial support for the research, authorship and/or publication of this article.

Competing interest: Nil.

Introduction

Prolactinoma is a benign growth of lactotrophs of the anterior pituitary gland causing excessive production of prolactin (PRL). The predominant biologically active form of PRL is a single-chain polypeptide of 198 amino acids and a molecular

Abstract

Introduction: Prolactinomas are the most common pituitary adenomas. Medical therapy with dopamine agonists (DAs) is the mainstay of treatment and rarely requires surgical manipulation. Patients may rarely present with cerebrospinal fluid (CSF) rhinorrhoea after starting therapy with DA in case of massive or invasive prolactinomas. **Case Description:** We present a case of a 29-year-old lady with invasive prolactinoma who presented with CSF rhinorrhoea after a month of starting bromocriptine therapy with the development of meningitis and warranting early surgical repair. **Practical Implications:** Patients with macroprolactinoma should be closely monitored initially after starting on DA to avoid life-threatening complications.

Key words: Cerebrospinal fluid, Dopamine agonists, meningitis, prolactinoma, rhinorrhoea, sphenoid sinus, trans-sphenoidal surgery

weight of 22 kDa.^[1] Its secretion from the anterior pituitary gland is under the inhibitory effect of dopamine. Prolactinomas are often detected earlier in women secondary to PRL inhibitory effects on gonadotropins and subsequent menstrual abnormalities and galactorrhoea. On the contrary, the diagnosis is often delayed in men, and tumour

size is usually bigger when patients seek medical attention. Symptoms in men are mostly due to mass effects on surrounding structures such as optic chiasm causing visual disturbance and headache. Likewise, they may also present with erectile dysfunction.^[2]

Despite being considered benign, many prolactinomas are invasive (30–45%),^[3] with up to 15% being clinically aggressive.^[4,5] Aggressive and invasive adenomas can invade the floor of the pituitary fossa extending into the sphenoid sinus. The pituitary gland lies outside the meningeal covering of the brain with cerebrospinal fluid (CSF) in arachnoid space. Erosion of sphenoidal sinus by invasive pituitary adenoma creates communication between arachnoid space and sphenoidal sinus, and CSF could potentially leak from these sites. This channel is blocked by an invading tumour, which serves as a plug, thus preventing CSF escape. Depending on the type of tumour and extent of invasion, some patients may experience CSF leakage from arachnoid space to sphenoid sinus that then finds its way to the nasal cavity through the sphenoid sinus opening in the nasal cavity. This unwanted, pathological and potentially life-threatening communication between the nasal cavity and intracranial cavity can be iatrogenic in patients with large invasive or malignant prolactinomas treated with pharmacological agents.^[4,6]

Dopamine agonists (DAs) have proven to be excellent pharmacological agents in the treatment of prolactinomas. The response of the therapy is quick, and the response rates are good to excellent. Pituitary surgeries are seldom required, even in patients with the impending risk of visual loss due to tumour pressure on optic chiasm or optic tracts. The reduction in tumour size and regression of tumours from the sphenoid sinus can potentially leave a catastrophic communication between the intracranial cavity and sphenoid sinus in cases of large invasive prolactinomas.^[6]

In this report, a clinical case of large invasive prolactinoma with CSF rhinorrhoea has been

presented. The informed consent for publication of this case report was waived by the local Institutional Review Board (IRB# Ex-04-12-20-01).

Case Report

A 29-year-old lady presented to the endocrinology clinic with a history of galactorrhoea and amenorrhoea for the past 7 months. Furthermore, she reported the presence of headache and visual disturbances for 1 month. Physical examination revealed bilateral galactorrhoea with normal vital signs, no signs of hypo or hyperthyroidism and normal visual fields. Her magnetic resonance imaging (MRI) brain study showed a 4.5 cm × 3.8 cm × 2.8 cm sellar and suprasellar mass [Figure 1]. Her PRL level was raised with low follicular-stimulating hormone and luteinising hormone levels [Table 1]. Based on history, laboratory workup and MRI findings, it was diagnosed as a case of pituitary macroadenoma-PRL secreting. Her case was discussed in the multidisciplinary tumour meeting, and the board decided that the patient should be started on medical treatment with DA. She was

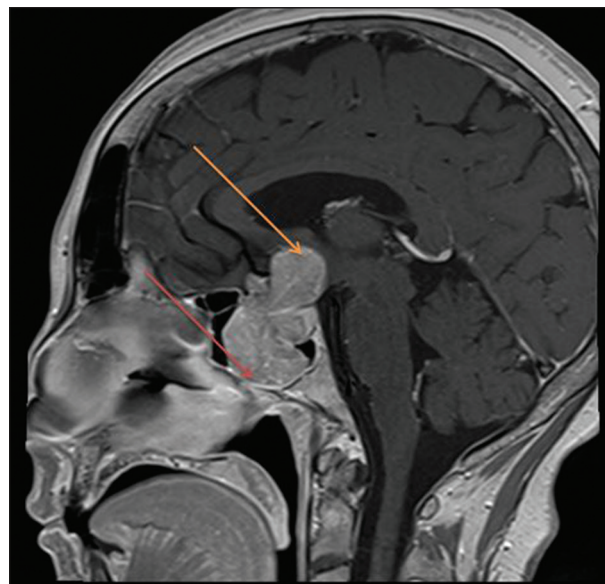


Figure 1: T1 post-gadolinium sagittal magnetic resonance image is demonstrating large sellar and suprasellar enhancing mass which is eroding and expanding the sellar floor and extending to the sphenoid sinus (red arrow) inferiorly and cranially it is extending to the hypothalamic region (yellow arrow)

Table 1: Investigations of the patient at the time of presentation, pre-procedure, post-procedure and at the 6-month follow-up

Investigations	At the time of presentation	Pre-procedure	Post-procedure	6-month follow-up
Prolactin (1.90–25 ng/ml)	188 ng/ml	14.3 ng/ml	2.61 ng/ml	10 ng/ml
Thyroid-stimulating hormone (0.55–4.78 uIU/ml)	0.934 uIU/ml	-	0.714 uIU/ml	0.67 uIU/ml
Free T4 (0.89–1.76 ng/dl)	1.17 ng/dl	1 ng/dl	1.76 ng/dl	0.77 ng/dl
Cortisol	15.66 ug/dl	12.3ug/dl	11.09 ug/dl	0.53 ug/dl
Luteinising hormone	0.168 mIU/ml	-	-	-
Follicle-stimulating hormone	0.423 mIU/ml	-	-	-
Insulin-like growth factor-1 (88–537 ng/ml)	210 ng/ml	-	-	-
Serum sodium (136–145 mmol/L)	142 mmol/L	140 mmol/L	150 mmol/L	143 mmol/L

prescribed bromocriptine 7.5 mg 3 times a day and called for a follow-up in a month.

At 1-month follow-up, the patient reported a 2-day history of a clear, watery nasal discharge from her left nostril. This was not associated with flu-like symptoms, such as fever, watery eyes, blocked nose, post-nasal drip, fatigue or lethargy. The discharge increased in volume on bending forward.

Diagnosis and management

The patient's history and recent development of nasal discharge were suspected to be CSF rhinorrhoea. The diagnosis was confirmed on computerised tomography (CT) scan [Figure 2] of her brain. The images suggested erosion of the sella turcica, tuberculum sellae and right-sided roof of the posterior ethmoidal cells with the extension of the tumour into the sphenoid sinus. The patient was prescribed acetazolamide 500 mg 2 times a day until she could undergo the bony defect's surgical repair.

While the patient was waiting for her surgery, she presented with altered sensorium and neck rigidity. Her clinical and biochemical features confirmed the diagnosis of meningitis. She was managed along these lines, and she made a full recovery. Her MRI brain [Figure 3] at this stage confirmed stable pituitary mass involving seller, suprasellar and parasellar regions with an invasion of the sphenoid sinuses and mass effect on the third ventricle causing hydrocephalus.

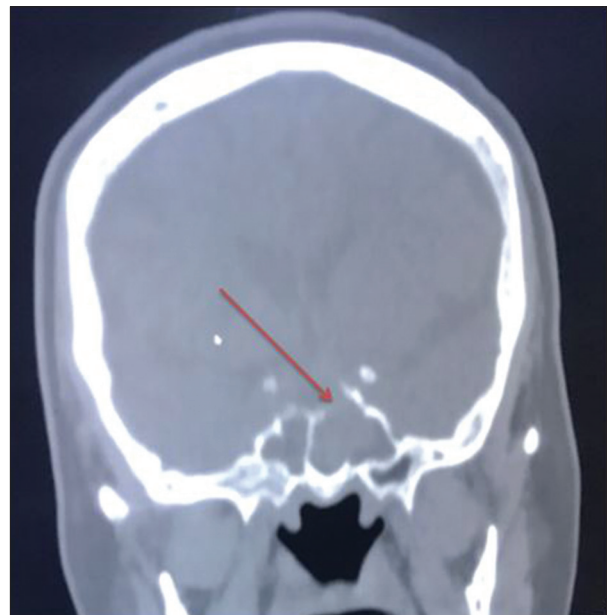

Figure 2: Coronal unenhanced computerised tomography image in the bone window at the level of the anterior clinoid process reveals a bony defect in the sellar floor/superior wall of the sphenoid sinus (arrow) through which sellar tumour is making its way to the sphenoid sinus

She underwent surgery to insert a lumbar drain for ventricular decompression followed by endoscopic trans-sphenoidal resection of the pituitary macroadenoma and repair the dural defect responsible for the CSF leak with fascia lata graft from the right thigh. Histopathology revealed benign pituitary adenoma and stained positive for synaptophysin stain. Postoperatively,

she developed diabetes insipidus and secondary hypothyroidism and was started on desmopressin and thyroxine.

On follow-up visits, the patient had improvement in her symptoms with no recurrence of CSF rhinorrhoea. She continued with her treatment of bromocriptine 7.5 mg 3 times daily. After a few months, her PRL levels dropped to 10 ng/ml, and an MRI brain revealed a residual stable pituitary lesion [Figure 4].

Discussion

CSF rhinorrhoea is a relatively uncommon complication of prolactinoma treatment. In one series of 114 macroprolactinoma patients, the incidence of DA-induced CSF rhinorrhoea was 6.1%.^[7] It was reported that CSF rhinorrhoea was more common in men than women, and there was no age predominance. Similar findings were reported by de Lacy *et al.*^[8] The investigators found the occurrence of CSF rhinorrhoea in 38 men,

18 women and 4 unspecified gender cases. Skull base defects were reported in 43 (out of 60) cases. The time from DA therapy to the occurrence of rhinorrhoea was approximately ranging from 1 week to 4 years, with a median of 6 weeks.^[8] This is similar to the findings of the present case report. This patient presented with rhinorrhoea after nearly 1 month of starting bromocriptine therapy. It has been proposed that volume reduction following DA therapy leads to exposure of the previously created pathological opening in the skull base, which was plugged by the tumour itself (until shrinkage of the tumour decompensated it). Similarly, in this case, the patient had evidence of skull erosion and sinus invasion on initial imaging.

There is no definite consensus in literature at a molecular level to suggest the cause of tumour aggressiveness. Some have suggested that the upregulation of protease-activated receptor 1 is a key factor in cellular invasiveness and tumour

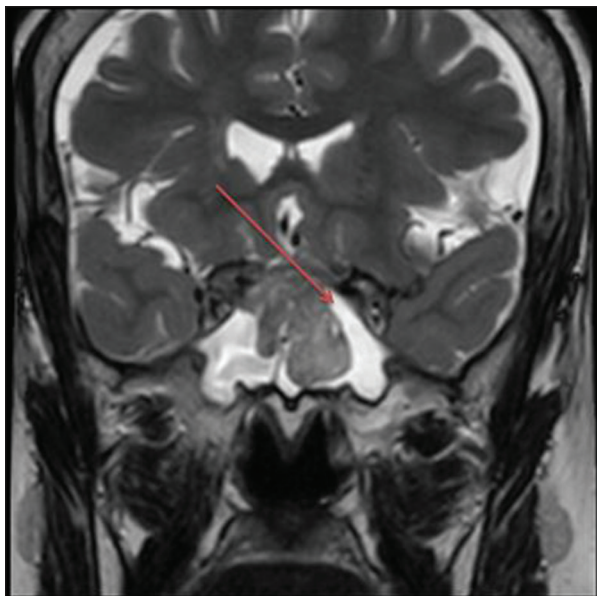


Figure 3: Coronal T2-weighted magnetic resonance image of the brain at the level of the sphenoid sinus with pituitary protocol shows T2 hyperintense fluid in the sphenoid sinus with similar intensity as cerebrospinal fluid (CSF) (arrow) worrisome of CSF leak through defect in sellar floor

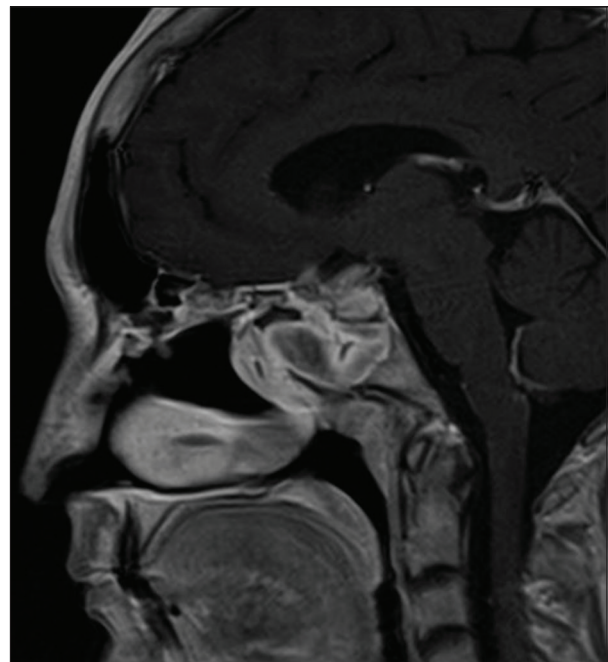


Figure 4: Post-trans-sphenoidal resection of the sellar/suprasellar tumour. Follow-up sagittal T1 post-gadolinium magnetic resonance image in midline shows residual changes in the sphenoid sinus with residual mucosal thickening, surgical defect in the sellar floor and residual enhancing tissue in the sellar/suprasellar cistern

progression.^[9] However, others have hypothesised that the loss of epithelial cadherin expression on prolactinomas is a cause of invasion and erosion of the sphenoidal bone.^[10]

Patients with CSF rhinorrhoea can present to the clinic with a watery discharge from the nose in the absence of common cold or flu-like symptoms. This can be the initial presenting symptom in patients with a pituitary tumour.^[11] Diagnosis can be delayed in such patients following the misdiagnosis of cold or flu. However, in some patients, the discharge is blood stained, which results in patients seeking immediate medical attention and subsequent investigations sooner. This communication between the nasal cavity and the intracranial cavity can lead to catastrophic consequences in some patients, such as meningitis, pneumocephalus or intracranial abscesses.^[12]

Although CSF is transparent, thin in consistency, watery and sweet compared to salty, thick and sticky nasal discharge, it may be challenging to differentiate between CSF and nasal discharge on clinical findings alone if the two are mixed. The laboratory investigations for this purpose are relatively reliable and straightforward. Beta-2-transferrin protein (tau protein) is unique to CSF and is produced by the loss of sialic acid due to the presence of neuraminidase in the central nervous system. Detection of beta-2-transferrin protein has shown to be highly sensitive and specific. Similarly, glucose detection has been suggested to detect the difference between persistent rhinorrhoea and otorrhoea. However, this test has shown to be unreliable. Alternatively, imaging investigations such as nuclear medicine CSF cisternography, CT cisternography or CT of the skull base can assist in diagnosing if laboratory testing is not available.^[13]

Recommended initial treatment for the management of DA-induced CSF rhinorrhoea is surgical repair, and it should be offered as soon as possible.^[14] The preferred approach is endoscopic endonasal surgical repair. The communication between the

nasal cavity and the intracranial cavity must be closed. It is recommended to discontinue DA while waiting for surgery to let the tumour regrow and fill the gap. However, this is a temporary measure because DAs have to be used to treat prolactinoma. On the contrary, this may be the treatment of choice in patients not fit for surgical intervention. The dose of DA may need to be carefully titrated and then monitored with imaging to prevent modification in the size of the tumour.

Debulking of adenoma is often considered before reconstruction of skull defect in some cases. However, a complete removal is usually not advisable, with tumours usually invading surrounding bones and dura mater that will require a more extensive surgical procedure. Debulking of the pituitary tumour will also provide space for the insertion of the graft, which is used for the repair of the bony defect. Following tumour debulking, repairing the skull base can be done using dural substitutes or fibrin glue for smaller leaks and autologous fat or fascia for larger leaks.^[15] This patient underwent tumour debulking with the dural defect restoration using a fascia graft from the thigh.

This case highlights the importance of follow-up after initiation of DAs in patients with prolactinomas. Even though DAs have simplified the treatment of prolactinomas, close surveillance of the patients is still necessary. Patients that develop CSF rhinorrhoea should undergo urgent definitive treatment to avoid life-threatening complications such as meningitis.

Conflicts of Interest

The authors declare that they have no conflicts of interest.

References

1. Sabharwal P, Glaser R, Lafuse W, Varma S, Liu Q, Arkins S, *et al.* Prolactin synthesized and secreted by human peripheral blood mononuclear cells: An autocrine growth factor for lymphoproliferation. *Proc Natl Acad Sci USA* 1992;89:7713-6.

2. Siddiqi AI. See your endocrinologist for a pituitary tumour; you may not need surgery. *J Cancer Allied Spec* 2017;3:2.
3. Meij BP, Lopes MB, Ellegala DB, Alden TD, Laws ER. The long-term significance of microscopic dural invasion in 354 patients with pituitary adenomas treated with transsphenoidal surgery. *J Neurosurg* 2002;96:195-208.
4. Raverot G, Castinetti F, Jouanneau E, Morange I, Figarella-Branger D, Dufour H, *et al.* Pituitary carcinomas and aggressive pituitary tumours: Merits and pitfalls of temozolomide treatment. *Clin Endocrinol (Oxf)* 2012;76:769-75.
5. Trouillas J, Roy P, Sturm N, Dantony E, Cortet-Rudelli C, Viennet G, *et al.* A new prognostic clinicopathological classification of pituitary adenomas: A multicentric case-control study of 410 patients with 8 years post-operative follow-up. *Acta Neuropathol* 2013;126:123-35.
6. Landolt AM. Cerebrospinal fluid rhinorrhea: A complication of therapy for invasive prolactinomas. *Neurosurgery* 1982;11:395-401.
7. Česák T, Poczós P, Adamkov J, Náhlovský J, Kašparová P, Gabalec F, *et al.* Medically induced CSF rhinorrhea following treatment of macroprolactinoma: Case series and literature review. *Pituitary* 2018;21:561-70.
8. de Lacy P, Benjamin S, Dixon R, Stephens JW, Redfern R, Price DE. Is surgical intervention frequently required for medically managed macroprolactinomas? A study of spontaneous cerebrospinal fluid rhinorrhea. *Surg Neurol* 2009;72:461-3; discussion 463.
9. Even-Ram S, Uzieli B, Cohen P, Grisaru-Granovsky S, Maoz M, Ginzburg Y, *et al.* Thrombin receptor overexpression in malignant and physiological invasion processes. *Nat Med* 1998;4:909-14.
10. Qian ZR, Li CC, Yamasaki H, Mizusawa N, Yoshimoto K, Yamada S, *et al.* Role of E-cadherin, alpha-, beta-, and gamma-catenins, and p120 (cell adhesion molecules) in prolactinoma behavior. *Mod Pathol* 2002;15:1357-65.
11. Nutkiewicz A, DeFeo D, Kohut R, Fierstien S. Cerebrospinal fluid rhinorrhea as a presentation of pituitary adenoma. *Neurosurgery* 1980;6:195-7.
12. Aarabi B, Leibrock LG. Neurosurgical approaches to cerebrospinal fluid rhinorrhea. *Ear Nose Throat J* 1992;71:300-5.
13. Chan DT, Poon WS, Ip CP, Chiu PW, Goh KY. How useful is glucose detection in diagnosing cerebrospinal fluid leak? The rational use of CT and beta-2 transferrin assay in detection of cerebrospinal fluid fistula. *Asian J Surg* 2004;27:39-42.
14. Lam G, Mehta V, Zada G. Spontaneous and medically induced cerebrospinal fluid leakage in the setting of pituitary adenomas: Review of the literature. *Neurosurg Focus* 2012;32:E2.
15. Schmalbach CE, Webb DE, Weitzel EK. Anterior skull base reconstruction: A review of current techniques. *Curr Opin Otolaryngol Head Neck Surg* 2010;18:238-43.

Authorship Contributions

Conceived and designed the analysis: HI, AIS, UA, WS, IY and MAN; collected the data: HI, AIS and MAN; performed the analysis: N/A; and wrote the paper: HI, AIS, UA, MAN, IY and MAN.