

Case Report

Radiculopathy as Delayed Presentations of Retained Spinal Bullet

Bang Ryu, M.D.,¹ Sung Bum Kim, M.D.,¹ Man Kyu Choi, M.D.,¹ Kee D Kim, M.D.²

Department of Neurosurgery,¹ Kyung Hee University Hospital, Seoul, Korea

Department of Neurosurgery,² University of California Davis, CA, USA

Bullet injuries to the spine may cause injury to the anatomical structures with or without neurologic deterioration. Most bullet injuries are acute, resulting from direct injury. However, in rare cases, delayed injury may occur, resulting in claudication. We report a case of intradural bullet at the L3–4 level with radiculopathy in a 30-year-old male. After surgical removal, radicular and claudicating pain were improved significantly, and motor power of the right leg also improved. We report the case of intradural bullet, which resulted in delayed radiculopathy.

Key Words : Bullet injury · Delayed presentation · Claudication · Radiculopathy.

INTRODUCTION

Gunshot wounds to the spine account for approximately 13 to 17% of all spinal cord injuries each year⁵. Spinal cord injury after gunshot usually results in complete injury, such as paraplegia, which is highly associated with thermal tissue injury^{3,4}. However, neurological deficits can be variable, ranging from radiculopathy to spinal cord injury.

Bullet injuries without any neurological deficits are relatively rare. Although neurological deficits might be absent initially, most patients eventually develop deficits that require surgical intervention⁶.

We describe a rare case of delayed onset of neurological symptoms after a bullet injury to the flank; the bullet migrated and became lodged in the spinal canal. We also review the relevant literature and compare the current case with other clinical case reports.

CASE REPORT

A 30-year-old man presented to our outpatient clinic with radiating pain both legs. The pain in both legs was aggravated with walking and relieved with rest, symptoms typical of neurogenic claudication. The patient reported that he had been shot in the left lateral side of the back on 1 year ago. We determined on physical examination that the wound on the left flank had already

healed (Fig. 1). At the time that he was shot, the patient had no other complaints, except for pain at the entrance wound. At that time of gun shot, he had to have absolute bed rest and conservative treatment because of a liver injury caused by the gunshot. After several months of treatment, his liver was healed enough to ambulate and walk; however, he needed a cane to walk. After he started walking, he began to experience continuous radiating pain on both lower extremities.

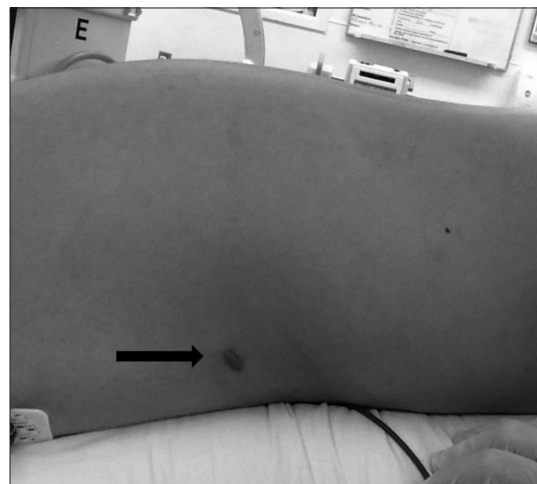


Fig. 1. The wound on the left flank that had already healed (black arrow).

• Received : March 3, 2015 • Revised : September 1, 2015 • Accepted : September 3, 2015

• Address for reprints : Sung Bum Kim, M.D.

Department of Neurosurgery, Kyung Hee University Hospital, 23 Kyungheedaero, Dongdaemun-gu, Seoul 02447, Korea

Tel : +82-2-958-8389, Fax : +82-2-958-8380, E-mail : sungbumi7@hanmail.net

• This is an Open Access article distributed under the terms of the Creative Commons Attribution Non-Commercial License (<http://creativecommons.org/licenses/by-nc/3.0>) which permits unrestricted non-commercial use, distribution, and reproduction in any medium, provided the original work is properly cited.

On neurologic examination, dorsiflexion of the ankle and big toe on the right leg revealed mild motor weakness (Grade IV). The patient also complained of numbness on the right lower limb; however, patellar and Achilles reflexes were normal. On admission, his ESR and CRP were elevated slightly. Other laboratory findings were normal. A mild degree of voiding difficulty was detected, although that symptom did not bother the patient.

Plain radiographs revealed a round, radiopaque mass in the spinal canal at the L3-4 level (Fig. 2). Non-contrast reconstructed CT images of the lumbar spine were taken after admission, which revealed that the bullet-shaped mass was within the spinal canal, pointing cephalic at the L3-4 interspace (Fig. 3). The bullet

within the spinal canal was located in the intradural space, compressing the nerve root (Fig. 3).

Because of his claudication and pain, we decided to surgically remove the bullet from the spinal canal. With the patient prone on a Wilson frame, fluoroscopic guidance was used to plan an incision over the L3-4 spinous process. The L3 lamina was carefully and completely removed with a drill, and a dural incision was made. After dural incision, bullet was identified and removed with forceps. We could not find out any root or rootlet injury in operative field. Both intraoperative and postoperative motor-evoked potential and somatosensory-evoked potential were normal. Significant inflammatory response in the sur-

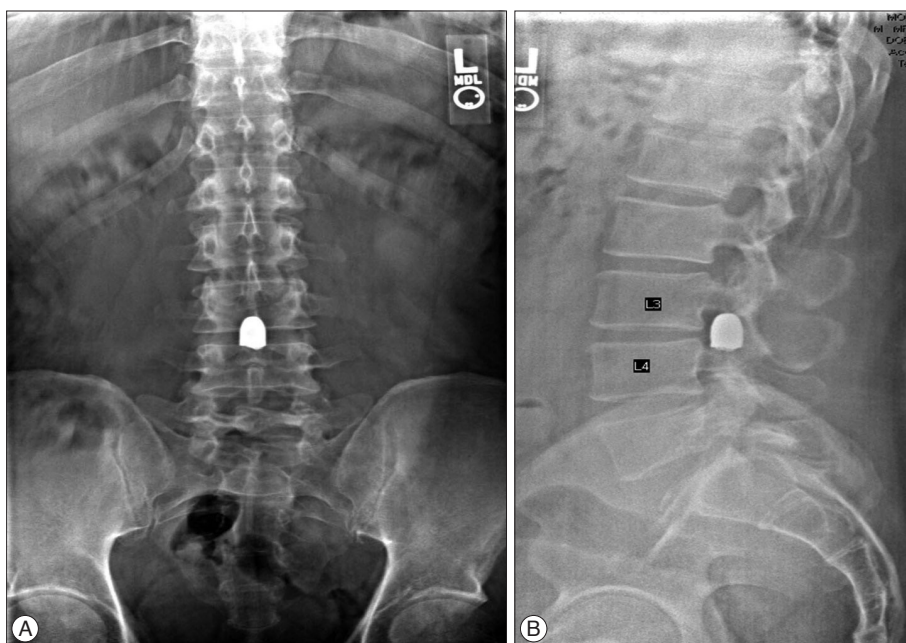


Fig. 2. Pre-operative A-P (A) and lateral (B) plain radiographs of the lumbar spine revealed a round, radiopaque mass in the spinal canal at the L3-4 level.

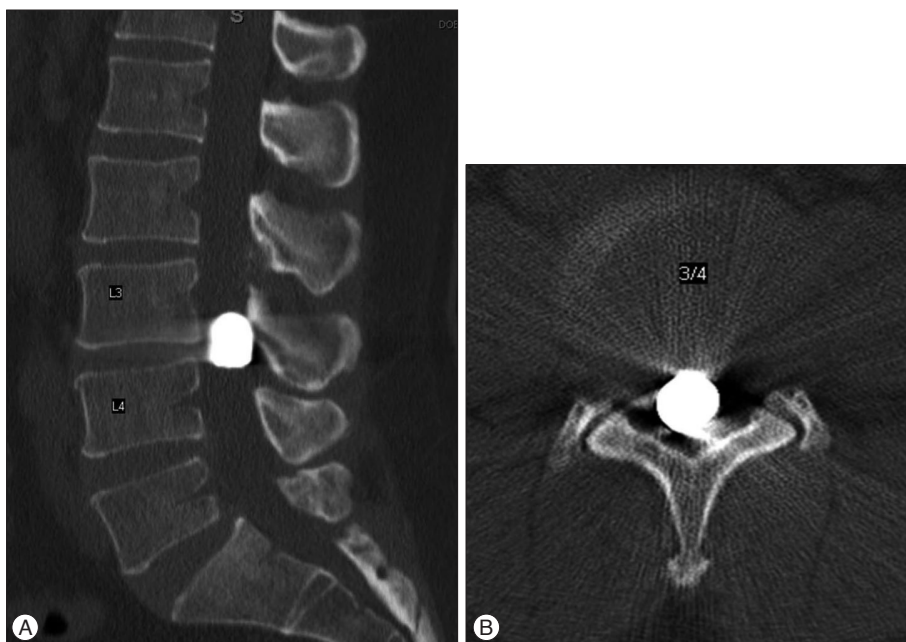


Fig. 3. Noncontrast CT reconstructed sagittal (A) and axial (B) images of the lumbar spine. The bullet within the spinal canal was pointed cephalad at the L3-4 interspace.

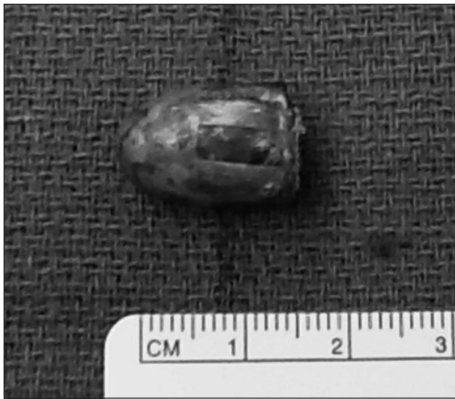

Fig. 4. The removed bullet was 1.5 cm long and weighed 11 g.

rounding area where the bullet was lodged was noted. There was also abundant reactionary epidural fibrosis. The removed bullet was 1.5 cm long and weighed 11 g (Fig. 4). We closed the skin wound after meticulous close of dura.

The patient ambulated the day after surgery and reported that the radicular pain and claudicating pain were greatly improved. He was discharged 1 week after surgery. On his follow-up visit at 4 weeks, the pain had nearly resolved, and oral medications, including pain killers, were completely stopped. He showed definitive improvement in motor power of the right leg; however, independent ambulation without a cane was not achieved.

DISCUSSION

The annual incidence of spinal cord injuries is 10.4 and 83 per million people, and the most common cause of spinal cord injuries is motor vehicle accident^{9,10}. Spinal cord injuries due to gunshot wounds are very rare, and the absence of acute neurological symptoms after gunshot-related spinal injury is even rarer.

Our case report is particularly interesting because intradural localization and our patient developed radiating pain in both lower extremities 1 year after the initial injury. In additions; to our knowledge, only a few cases with similar characteristics have been reported^{2,7}. Most bullet injuries are accompanied by acute neurologic symptoms, and if initially the patient might be neurologically intact fortunately, neurological symptoms gradually appear over time. There are two possible explanations for the delayed appearance of neurological symptoms in the literatures : First, compression of the spinal cord or the thecal sac and impingement of the nerve root as a result of migration of the bullet and second, reactionary epidural fibrosis. According to a paper by Ajmal et al.¹, there have been only 7 reported cases of delayed neurological symptoms caused by epidural fibrosis after gunshot injury. Our case is unique for two reasons. First, our patient developed radiating pain in both lower extremities 1 year after the initial injury, and the cause was thought to be epidural fibrosis due to the injury itself. Second, it is unique that our case is intradural bullet injury

In the surgical field, there was a significant inflammatory re-

sponse in the area where the bullet was lodged. There was also abundant reactionary epidural fibrosis. However, since serial images were unavailable, we could not compare images taken when the patient incurred the injury with the images taken in our clinic; as a result, we were unable to completely exclude true bullet migration or potential stenosis because of degenerative changes. We presumed that bullet might enter the body of left flank, which would be the level of thoraco-lumbar junction (Fig. 1), because of the entrance skin wound. After penetrating skin on left flank of thoraco-lumbar junction, bullet might penetrate the vertebra and dura, which was finally found with adhesion on L3-4 level. We assumed that bullet might be located at intradural thoraco-lumbar junction at first injury, which migrated on L3-4 level after ambulation. After migration on L3-4 level, bullet was stuck to L3-4 level, because of its size and diameter. And epidural fibrosis and intra dural adhesion might follow.

When determining the surgical treatment for patients with bullet injury, surgeons should assess neurological damage and abnormalities, instability, the position of bony fragments, age, and systemic complaints. Surgical treatment of intraspinal bullets remains controversial. Ajmal et al.¹ opposed surgical removal of intraspinal bullets because the injury is caused neurological deficit in the end, but surgical treatment should be considered when patients have instability and neurological damage or abnormalities, whether delayed or immediate. In an acute setting, the indications for exploration include, but are not limited to, cerebrospinal fluid leak, infection, and partial or progressive deficits. Risk of bullet migration and development of fibrosis and stenosis over time should be considered in other patients. These patients should therefore be informed about late complications if a decision is made to manage them conservatively. Regular follow-ups with radiographs may also be required to monitor bullet migration^{1,8}.

In contrast, Ben-Galim and Reitman² recommend early surgical intervention even if the patient has no neurological symptoms initially because of the risk that neurological deficits will develop as a result of intrathecal bullet migration and inflammatory reaction. In our case, after healing of the internal organs, the patient began walking with a cane, after walking he discovered that he had continuous radiating pain in both lower extremities. We presumed that a claudication patient needed bed rest for healing of internal organ injury, which masked the walking symptom of claudication and radicular pain. We decided on surgical treatment because the patient had neurologic abnormalities and neurological symptom aggravation. After surgery, he showed definite improvement of motor power in the right leg; however, independent ambulation without a cane was not achieved.

Our current case report has shortages. Firstly we found the inflammatory changes in surgical field, however we missed taking pictures. Proof and evidence are important factor for case report. In additions, we could not find and get the initial radiology of initial gun shot, which would be the good evidence of the pathophysiology in this case, whether symptom develop form migra-

tion of bullet or inflammation, however we presumed that both would be related with symptom.

CONCLUSION

We documented an extremely rare case of intradural location of a bullet, which was treated surgically with a satisfactory outcome. We need to be cautious, if you see the non-symptomatic gunshot patients without penetration of bullet, which means absence of outlet of bullet. From current case and reviews of literatures, we need to think about possibility of intradural migration of bullet or chronic inflammation and adhesion to surrounding tissue.

References

1. Ajmal S, Enam SA, Shamim MS : Neurogenic claudication and radiculopathy as delayed presentations of retained spinal bullet. *Spine J* 9 : e5-e8, 2009
2. Ben-Galim P, Reitman CA : Intrathecal migratory foreign body without neurological deficit after a gunshot wound. *Spine J* 8 : 404-407, 2008
3. de Barros Filho TE, Cristante AF, Marcon RM, Ono A, Bilhar R : Gunshot injuries in the spine. *Spinal Cord* 52 : 504-510, 2014
4. DeVivo MJ, Vogel LC : Epidemiology of spinal cord injury in children and adolescents. *J Spinal Cord Med* 27 Suppl 1 : S4-S10, 2004
5. Hossin J, Joorabian M, Pipelzadah M : A firearm bullet lodged into the thoracic spinal canal without vertebral bone destruction : a case report. *J Med Case Rep* 5 : 289, 2011
6. Jaiswal M, Mittal RS : Concept of gunshot wound spine. *Asian Spine J* 7 : 359-364, 2013
7. Park JH, Kim HS, Kim SW, Do NY : Gunshot injury to the anterior arch of atlas. *J Korean Neurosurg Soc* 51 : 164-166, 2012
8. Scuderi GJ, Vaccaro AR, Fitzhenry LN, Greenberg S, Eismont F : Long-term clinical manifestations of retained bullet fragments within the intervertebral disk space. *J Spinal Disord Tech* 17 : 108-111, 2004
9. Seçer M, Ulutaş M, Yayla E, Cınar K : Upper cervical spinal cord gunshot injury without bone destruction. *Int J Surg Case Rep* 5 : 149-151, 2014
10. Wyndaele M, Wyndaele JJ : Incidence, prevalence and epidemiology of spinal cord injury : what learns a worldwide literature survey? *Spinal Cord* 44 : 523-529, 2006