



Dermatologic surgery on the chest wall in patients with a cardiac surgery history: a review of material that may be encountered intraoperatively, including potential complications and suggestions for proceeding safely[☆]

Elizabeth Foley Bucher, MD^a, Andrew Kim, BA^b, Jason Givan, MD^c, Mary E. Maloney, MD^{d,*}

^a The Skin Surgery Centre, Metairie, LA

^b Department of Dermatology, University of Connecticut Health Center, Farmington, CT

^c RidgeView Dermatology, Lynchburg, VA, USA

^d Department of Medicine, Division of Dermatology, UMass Memorial Healthcare, Worcester, MA

ARTICLE INFO

Article history:

Received 6 October 2015

Received in revised form 29 November 2015

Accepted 4 December 2015

Keywords:

dermatologic surgery
electrosurgery
pacemaker
pacer wire
steel suture

ABSTRACT

Background: Thoracic surgical procedures and the use of cardiac devices such as pacemakers are becoming increasingly prevalent in the population. As such, dermatologists may have a greater likelihood of encountering previously implanted or abandoned surgical material in the course of dermatologic surgery on the chest wall. A basic understanding of the wire types and the tunneling paths utilized in such procedures is important in accurately anticipating the presence of these wires to effectively manage any chance encounters.

Objective: We present a review on temporary epicardial pacing wires, temporary transvenous pacing wires, pacemaker leads, and surgical steel sutures in the context of dermatologic surgery.

Methods: A literature review was performed on frequently used wire material in patients with a history of cardiac surgery as well as related dermatologic complications from these materials.

Results & Conclusion: Dermatologic surgeons should particularly be aware that temporary epicardial pacing wires and pacemaker leads are not uncommonly abandoned in the chest wall of many patients. All patients with a cardiac surgery history should be questioned about possible retained wires. If wire material is encountered intraoperatively, immediately stop the procedure and do not attempt further manipulation of the wire until suggested steps are taken to ascertain the wire type.

© 2016 The Authors. Published by Elsevier Inc. on behalf of Women's Dermatologic Society. This is an open access article under the CC BY-NC-ND license (<http://creativecommons.org/licenses/by-nc-nd/4.0/>).

Introduction

As cardiac surgery is becoming more common due to an aging population and new advances in the diagnosis and treatment of cardiac conditions, dermatologists and dermatologic surgeons encounter many patients with cardiac surgery history. These patients may have had implanted cardiac devices such as pacemakers and implantable cardioverter-defibrillators (ICDs). Previous literature has outlined potential complications that can arise and precautions to be taken when performing dermatologic surgery with concomitant use of electrosurgery in these patients. However, the literature on problems that can arise from retained, temporary cardiac device equipment is severely lacking.

The authors recently encountered wire material encased in tumor during Mohs micrographic surgery on the chest wall in a patient with an active pacemaker and history of cardiac surgery. The wire was encountered as the tumor was traced. When it became clear that this wire was of a conducting nature, a chest x-ray (CXR) and cardiology consultation were

obtained. In this case, the wire was determined to be of a retained nature, from a temporary epicardial pacer placed after cardiac surgery and intentionally abandoned when no longer needed. We searched the literature for reports of similar findings during cutaneous surgery or guidelines on how to proceed after such an unsettling discovery and found none. We discovered that beyond ICDs and pacemakers—which are usually obvious due to the presence of a visible implanted generator on the chest wall—other types of material used in the course of open heart surgery may be encountered by dermatologists and dermatologic surgeons. We aim to provide a review of these materials to help our colleagues identify and manage foreign material that may be encountered, minimize potential hazards to patients during procedures, and diagnose cutaneous lesions that may occur secondary to retained material post-cardiac procedure.

Description of wire types and indications for use

Temporary epicardial pacer wires

Many cardiac surgeons routinely insert temporary epicardial pacer wires (TEPWs) after open heart surgery (e.g., valve replacement or repair, coronary artery bypass graft surgery, or heart transplant) for

[☆] Conflict of interest: The authors have no conflicts of interest to report.

* Corresponding author.

E-mail address: Mary.Maloney@umassmemorial.org (M.E. Maloney).

both therapeutic and diagnostic purposes due to an increased postoperative risk for myocardial dysfunction (Reade, 2007). TEPWs are usually monofilament stainless steel wires with an insulating coating (Fig. 1) passed from a starting point of the epicardium percutaneously to the right and left of the sternum for atrial and ventricular wire pairs, respectively. They are typically removed 2 to 7 days after surgery using gentle traction. If excessive resistance is encountered during wire withdrawal or the patient has an increased bleeding risk from a coagulopathy, the wires may be left in place at the discretion of the surgeon. TEPWs may also be purposefully sutured tightly in place by some surgeons for better contact with the epicardium and more reliable impulse conduction in critical situations, sometimes even with the intention of purposefully abandoning the wire.

Temporary transvenous pacing wires

Temporary transvenous pacing wires (TTPWs) are also used for short-term pacing but are typically only employed as a temporary bridge to permanent pacing in acute conditions such as symptomatic high-grade heart block. Although TTPWs and (transvenous) permanent pacing or ICD leads (discussed later) are very similar in placement, minor differences exist regarding insertion method and final placement of the ends interfacing with the pulse generators. TTPWs are directly placed into central veins—most commonly the internal jugular or subclavian—via a catheter and contain an inflatable balloon tip to help anchor the exposed conductive tip in the right atrium or ventricle before being connected to an external pulse generator. Similar to TEPWs, they also consist of a stainless steel core with an insulating plastic sleeve, but they have a larger caliber due to the additional channel needed to inflate the balloon anchor (Fig. 2). TTPWs are replaced with more permanent pacing wires during ICD or pacemaker placement. A review of the literature is negative for reports of abandoned TTPWs.

Permanent pacemakers and ICDs

Permanent pacemakers and ICDs are comprised of three components: the pulse generator, electrodes, and wires (the latter two forming the connecting leads). In contrast to TTPW, ICD or permanent pacer leads are inserted into the subclavian but are first tunneled subcutaneously to create space for the pulse generator to be buried under the skin. Although they are most commonly placed in the left upper quadrant of the chest wall due to anatomical considerations,




Fig. 2. Temporary transvenous pacing wire (TTPW): bipolar balloon pacing electrode catheter with deflated balloon tip.

pulse generator (and wires) can sometimes be found on the right as well. The implanted generator, or pacer box, is visible under the skin on the chest wall and therefore heralds the presence of adjacent subcutaneous pacing wires. The implanted pulse generators may be removed in special circumstances such as infection, host rejection, or equipment malfunction, but the leads are typically left in place unless infected (Love et al., 2000). For patients who have had a long history with a pacemaker or ICD, it may not be uncommon for them to have multiple “abandoned” nonfunctional pacer leads due to lead failure or changes of the pace generator (Bracke et al., 2001).

Steel suture wires

Most invasive cardiac surgeries require a median sternotomy for access that must later be closed with a high tensile material to aid in sternal edge reapproximation. Steel sutures are most commonly placed transternally to achieve this approximation, but they may occasionally be placed in a parasternal or paracostal fashion as well. Alternatives to traditional sternal wire closure include the use of stainless steel bands, polymer tapes (e.g., Ethicon), or absorbable sutures (typically in younger patients) either alone or in conjunction with sternal wires (Losanoff et al., 2002). Sternal wires are composed of bare surgical stainless steel attached to a suture needle for easier threading (Fig. 3). Wires are typically left in once placed but are




Fig. 1. Temporary epicardial pacing wire (TEPW) with ends flayed for increased traction when placed on the epicardial surface. The example shows an orange insulating coating, but actual colors may vary depending on the wire manufacturer.



Fig. 3. Steel suture: size 6 (0.8 mm diameter) monofilament surgical stainless steel suture with V-40 (tapercut 1/2 circle) needle.

Table 1
Reported Cutaneous Findings Due to Retained and Migrating Wire Material.

Cutaneous nodule
Hematoma
Infection
Foreign body granuloma
Fistula

occasionally removed for reasons such as irritation, infection, or wire failure. These wires can break and/or migrate to a more superficial location, where they are occasionally found in the dermis or even extruding through the epidermis (Weber and Peters, 1986).

Complications from pacing wires

The various temporary pacing wires and permanent or semipermanent wires have a well-documented history of infrequent, but not rare, adverse outcomes. Common to all the wire types are risk for infection, migration, or breakage, with effects ranging from local irritation and abscess formation to significant cardiopulmonary events including arrhythmias, hemothorax, cardiac tamponade, and subclavian vein occlusion or thrombosis (Al Halees et al., 2007; Bhavani et al., 2006; Bracke et al., 2001; Levisman et al., 2010; Love et al., 2000; Schreffler and Rumisek, 2001; Worth et al., 2011).

With these migration events, the occurrence of external fragment migration, causing associated cutaneous findings, are of particular interest to dermatologists. Documented cutaneous complications can be seen in Table 1. A high degree of suspicion should be present in any post-open heart surgery patient when presenting with dermatologic changes in areas tracking along the various wire paths. A basic understanding of the wire types and tunneling paths utilized and explained previously can provide insight into the potential etiology of such cutaneous findings in these patients. In one case report, a 77-year-old male presented with an expanding right neck mass near the inferior attachment of the sternocleidomastoid muscle, determined to be a hematoma caused by a migrating sternal wire fragment, 6 years after an aortic valve repair (Rungatscher et al., 2011). Another report describes a 77-year-old male with a history of open heart surgery 8 years prior complaining of a 19-month history of an intermittently bleeding, irritated cutaneous nodule on the left mid-lower chest, later discovered to be the result of a migrating retained TEPW (Matwiyoff et al., 2000). Likewise, foreign body granulomas, fistulas, and local infections have been described as a direct result of TEPWs, pacemaker/defibrillator leads, and sternal wires (Table 1) (Al Halees et al., 2007; Bhavani et al., 2006; Viraben et al., 1995).

Dermatologic surgeons should also be aware of these commonly utilized cardiac wires as they may be encountered during cutaneous surgical procedures on the chest wall of post-cardiac surgery patients. Current literature has addressed general surgical considerations when operating on individuals with pacemakers or ICDs, offering logical recommendations for perioperative monitoring due to concerns for pacemaker malfunctioning, device reprogramming, or the very serious potential complication of asystole (Dawes et al., 2006; Riordan et al., 1997). A survey by El-Gamal et al. (2001) found that though no major adverse outcomes were reported by cutaneous surgeons using electrosurgical equipment, cardiac complications such as skipped beats or improper firing of an ICD were each seen at rates between 10 and 30% during dermatological procedures on the chest wall. Matzke et al. (2006) performed a retrospective review at the Mayo Clinic of 173 patients with pacemakers and 13 with ICDs who underwent dermatologic surgery; the authors concluded that there were no documented complications related to bipolar electrosurgery.

We propose that, although an excellent safety record exists, the acknowledged risk of performing cutaneous surgery with electrosur-

gical equipment applies not only to patients with implanted active cardiac devices but also includes patients with any cardiac surgery history and possible retained pacer wires. Whereas cardiac wires are often anticipated in those with implanted cardiac devices, they are not anticipated in those with only a history of cardiac surgery without implanted device placement. Further complicating this problem, many postsurgical patients with retained wire often have no knowledge of such retained material. In the authors' experience with encountering retained pacing wire intraoperatively, the presence of the wire was neither recorded in any available medical records, nor was the patient educated about the wire in order to provide a verbal report of its presence. These wires can pose a clear danger to patients during cutaneous procedures utilizing electrosurgery because they present a conductive path leading directly to the myocardium, specifically at the exposed wire tip or anywhere along the course of the wire where the insulating coating may be broken or compromised.

Wire removal complications

Caution can be exercised when operating around known wire tract locations, but encountering wire may be inevitable in the cases of cutaneous neoplasms either overlying or encasing a segment of retained wire. Pacing wires left in for more than 1 week (whether temporary or permanent) become more difficult to remove, with increased risk of complications such as atrial or ventricular laceration, hemorrhage, tamponade, and damage to coronary vasculature (Carroll et al., 1998; Reade, 2007). Therefore, the threshold for abandoning pacer wires is fairly low because retained wires are generally very well tolerated and the risk profile for removal is often unacceptably high.

Removal of pacer wires beyond the normal window period for temporary wires is not generally done except in rare circumstances such as systemic infection, lead related endocarditis, or thrombotic complications (i.e., superior vena cava syndrome with transvenous leads) wherein the risk involved with complete removal is warranted (Bracke et al., 2001). Removal in such cases is carried out in a highly controlled setting with telemetry, specialized tools for removal, and the necessary equipment to manage any of the complications noted (Love et al., 2000; Smith and Love, 2008).

When the decision is made to abandon pacer wires, excess slack is removed before cutting the wire flush with the skin while simultaneously providing counter traction with downward pressure on the surrounding skin. This causes the retained portion to retract under the skin and allows the tract to heal, providing a greater degree of protection against infection following the wire to the myocardium.

Sternal wire removal is usually done once the sternal plate is stable. In rare instances of broken and retained fragments causing irritation, these pieces can be removed to prevent further damage to surrounding tissues in the same fashion as any other small foreign body removal. Removal of sternal wires does not pose the same cardiac concerns as pacer wires because sternal wires do not carry the same potential myocardial injury or for conducting electrical charge to the myocardium.

Wire identification

A major differentiating factor between pacing wires and sternal wires is the presence of an insulating sheath over a conductive core (typically stainless steel) with TEPW, TTPW, and ICD or pacemaker leads. Despite sternal wires also being comprised of stainless steel, these wires lack an insulating sheath and typically do not extend to the myocardium. A side-by-side comparison of TEPW, TTPW, and sternal wire is provided in Fig. 4 to show the relative sizes of the wires




Fig. 4. Size comparison of temporary epicardial pacing wire (TEPW) (top), temporary transvenous pacing wire (TTPW) (middle), and steel suture (bottom).

with TEPWs and TTPWs demonstrating the smallest and largest diameter wires, respectively.

Discussion

Cardiac devices such as pacemakers and cardiothoracic procedures including valve repair or replacement, coronary artery bypass graft, and cardiac transplant surgery are becoming increasingly prevalent in the population. It is important to be aware that TEPW are routinely inserted after these surgeries and are sometimes purposefully abandoned and retained in the chest wall where they may be encountered during dermatologic procedures (Reade, 2007). The presence of a pacemaker or ICD heralds the presence of pacer wires, but the status of many individuals post-cardiac surgery without any such devices may still have retained wire capable of causing cutaneous symptoms or complications during dermatologic procedures in the area of the wire. Thus, one should maintain a high degree of suspicion for anyone with a history of open heart surgery, presence of sternotomy scar, or pacemaker/ICD insertion scar. Sternal wires, while not posing the same cardiovascular risks as conducting pacing wires, must still be correctly identified as different from pacer wires based on appearance and anatomical location to be managed confidently in the course of cutaneous procedures.

Patients with a history of cardiac surgery can easily be questioned regarding retained wire material before dermatologic surgery on the chest wall. However, most patients will not know if such a wire was used or abandoned. Though CXR may be performed to confirm the presence and tract of abandoned wire, if there are sternal wires and/or other pacer wires, full tracing of the course of any one wire may be difficult or impossible (Fig. 5).

Unexpectedly discovering retained pacing wire during cutaneous procedures is a rare and unsettling finding. General preoperative suggestions include taking a complete history with patient screening and anticipating the types and locations of potentially retained wire in individuals in whom this may be the case. In the event of encountering wire in the chest wall intraoperatively, the authors suggest the following steps:

1. Do not pull forcefully on the wire or try to extract it.
2. Immediately stop the procedure until the type of wire is ascertained.
3. Review the chart for any mention of abandoned, nonfunctional pacer wire and question the patient regarding past cardiac procedures.
4. Obtain a CXR to evaluate the course and nature of the wire.
5. Obtain cardiology or cardiac surgery consultation if chart review and CXR do not define the wire nature and course.

We also strongly recommend to our colleagues in cardiology and cardiothoracic surgery chart documentation for any abandoned wire in the patient problem list and informing the patient of abandoned wire so he or she may be an important source of clinical information.

Attempting to pull out retained pacing wires carries severe risks, and therefore, dermatologic surgeons should under no circumstances attempt to do so. If wire material is encountered, the type and course of the material must be identified before any manipulation or attempted pulling. Once determined to be of a nonfunctional, abandoned nature, the correct removal technique is to apply gentle traction and clip the wire at the exit point. Accurate identification of the material is imperative to neither interfere with an active device nor forgo surgery unnecessarily.

References

- Al Halees Z, Abdoun F, Canver CC, Kharabsheh S. A right ventricle to aorta fistula caused by a fractured sternal wire. *Asian Cardiovasc Thorac Ann* 2007;15:453–4.
- Bhavani SS, Slisatkorn W, Rehm SJ, Petterson GB. Deep sternal wire infection resulting in severe pulmonary valve endocarditis. *Ann Thorac Surg* 2006;82:1111–3.
- Bracke FA, Meijer A, van Gelder LM. Pacemaker lead complications: when is extraction appropriate and what can we learn from published data? *Heart* 2001;85:254–9.

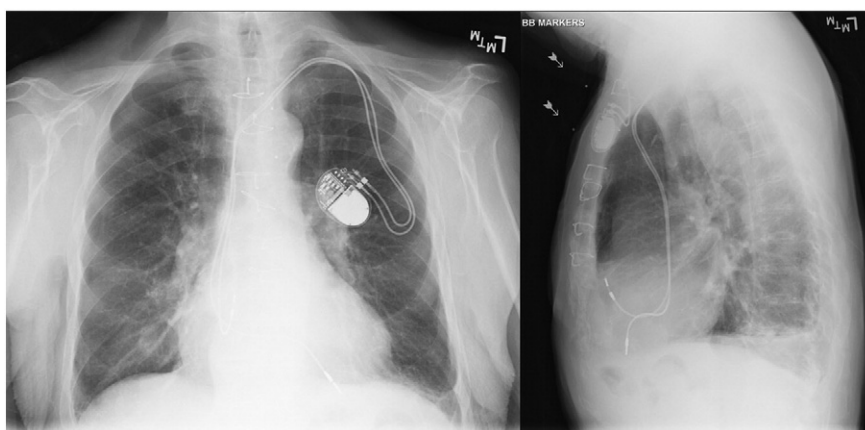


Fig. 5. Posterioranterior (PA) and lateral chest x-rays (CXRs) highlighting sternal wires and permanent pacer wires. Temporary epicardial pacing wires are also present, but not discernible.

- Carroll KC, Reeves LM, Andersen G, Ray FM, Clopton PL, Shively M, et al. Risks associated with removal of ventricular epicardial pacing wires after cardiac surgery. *Am J Crit Care* 1998;7:444–9.
- Dawes JC, Mahabir RC, Hillier K, Cassidy M, de Haas W, Gillis AM. Electrosurgery in patients with pacemakers/implanted cardioverter defibrillators. *Ann Plast Surg* 2006;57:33–6.
- El-Gamal HM, Dufresne RG, Saddler K. Electrosurgery, pacemakers and ICDs: a survey of precautions and complications experienced by cutaneous surgeons. *Dermatol Surg* 2001;27:385–90.
- Levisman J, Shemin RJ, Robertson JM, Pelikan P, Karlsberg RP. Migrated sternal wire into the right ventricle: case report in cardiothoracic surgery. *J Card Surg* 2010;25:161–2.
- Losanoff JE, Jones JW, Richman BW. Primary closure of median sternotomy: techniques and principles. *Cardiovasc Surg* 2002;10:102–10.
- Love CJ, Wilkoff BL, Byrd CL, Belott PH, Brinker JA, Fearnot NE, et al. Recommendations for extraction of chronically implanted transvenous pacing and defibrillator leads: indications, facilities, training. North American Society of Pacing and Electrophysiology Lead Extraction Conference Faculty. *Pacing Clin Electrophysiol* 2000;23:544–51.
- Matwiyoff GN, McKinlay JR, Miller CH, Graham BS. Transepidermal migration of external cardiac pacing wire presenting as a cutaneous nodule. *J Am Acad Dermatol* 2000;42:865–6.
- Matzke TJ, Christenson LJ, Christenson SD, Atanashova N, Otley CC. Pacemakers and implantable cardiac defibrillators in dermatologic surgery. *Dermatol Surg* 2006;32:1155–62 [discussion 62].
- Reade MC. Temporary epicardial pacing after cardiac surgery: a practical review: part 1: general considerations in the management of epicardial pacing. *Anaesthesia* 2007;62:264–71.
- Riordan AT, Gamache C, Fosko SW. Electrosurgery and cardiac devices. *J Am Acad Dermatol* 1997;37:250–5.
- Rungatscher A, Morjan M, Faggian G. Sternocleidomastoid muscle hematoma due to sternal wire migration. *J Card Surg* 2011;26:296.
- Schreffler AJ, Rumisek JD. Intravascular migration of fractured sternal wire presenting with hemoptysis. *Ann Thorac Surg* 2001;71:1682–4.
- Smith MC, Love CJ. Extraction of transvenous pacing and ICD leads. *Pacing Clin Electrophysiol* 2008;31:736–52.
- Viraben R, Boulinguez S, Alba C. Granulomatous dermatitis after implantation of a titanium-containing pacemaker. *Contact Derm* 1995;33:437.
- Weber LD, Peters RW. Delayed chest wall complications of median sternotomy. *South Med J* 1986;79:723–7.
- Worth PJ, Conklin P, Prince E, Singh AK. Migration of retained right ventricular epicardial pacing wire into the pulmonary artery: a rare complication after heart surgery. *J Thorac Cardiovasc Surg* 2011;142:e136–8.