



Received: 2015.02.05  
Accepted: 2015.03.03  
Published: 2016.09.14

**Authors' Contribution:**

- A** Study Design
- B** Data Collection
- C** Statistical Analysis
- D** Data Interpretation
- E** Manuscript Preparation
- F** Literature Search
- G** Funds Collection

## Urethroscrotal Fistula: A Rare Cause of Scrotal Swelling

Selcuk Parlak<sup>ABCEG</sup>, Aysun E. Okay<sup>ABD</sup>

Radiology Clinic, Numune Education and Research Hospital, Ankara, Turkey

**Author's address:** Selcuk Parlak, Radiology Clinic, Numune Education and Research Hospital, Ankara, Turkey,  
e-mail: selcukparlakdr@gmail.com

**Background:**

Urethroscrotal fistula (USF) is an abnormal communication between the urethra and the scrotum. This rare abnormality may be iatrogenic or secondary to perforation of the urethra by a stone. After the passage of urine to the scrotum through the fistula, painless scrotal swelling develops, which disappears completely with manual compression, and voiding can be maintained in this way. Retrograde urethrography (RU) and voiding cystourethrography (VCU) are traditional diagnostic methods, but they have limitations, such as technical difficulties and inability to evaluate the surrounding tissues. Multidetector CT (MDCT), together with reformatted images, can provide valuable information about the surrounding tissues and associated pathologies.

**Case Report:**

We present a case of a 36-year-old male patient who had painless scrotal swelling after cystolithotomy and urethral stone surgery. The patient indicated that the swelling disappeared after manual compression. A fistula between the bulbous urethra and the scrotum was discovered by MDCT. In our case, we believe that the fistula developed iatrogenically during stone excision or secondary to perforation of the urethra by a stone.

**Conclusions:**

As a rare pathology, urethroscrotal fistula should be considered in men with a history of urethral stone surgery and symptoms, including painless scrotal swelling, which can be manually compressed after voiding.

**MeSH Keywords:**

Fistula • Multidetector Computed Tomography • Scrotum • Urethra

**PDF file:**

<http://www.polradiol.com/abstract/index/idArt/897937>

### Background

Urethroscrotal fistula is a rarely-seen pathology in men [1]. It is frequently iatrogenic or secondary to urethral stones [2]. These causes lead to the perforation of the urethra and fistula formation between the urethra and the scrotum [1,2].

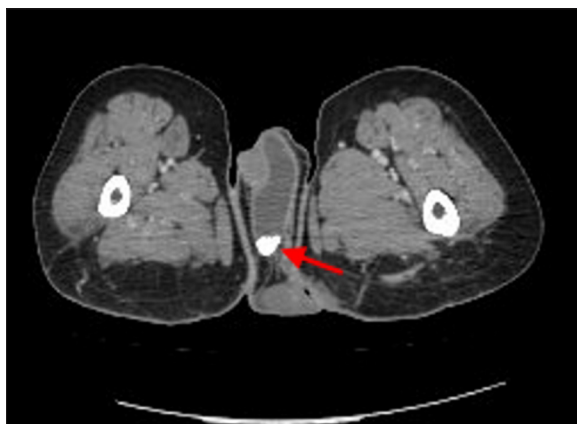### Case Report

A 36-year-old male patient underwent bladder calculi surgery in 2003. The patient was followed for urinary incontinence as a result of congenital lumbosacral meningocele. Bladder and urethra calculi occurred over time. The patient underwent cystolithotomy and urethral stone excision in 2013. Six months later, he returned to hospital with painless scrotal swelling, which he indicated had disappeared after manual compression. Urinary leakage

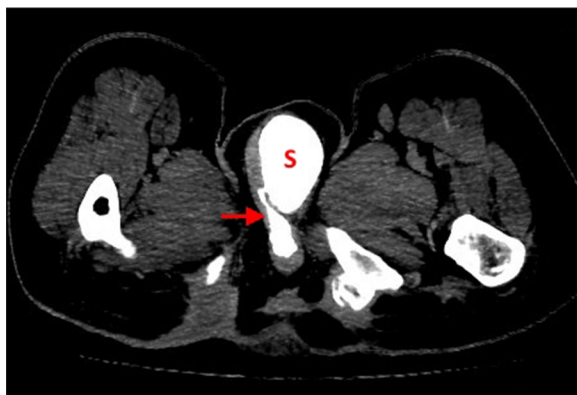
had also been seen. Ultrasonography showed a huge fluid-filled sac with multiple calculi inside (no figure available). The patient was referred to the MDCT unit. On unenhanced sections, stones in the fluid-filled scrotal sac were observed (Figure 1). The late pyelogram phases showed that contrast media filled the scrotal sac and the contrast leakage arose through a thin fistula from the bulbous urethra (Figures 2, 3). An operation was recommended but the patient refused it and left hospital with normal vital signs.

### Discussion

Genitourinary tract fistulas may develop between the urethra and the rectum, perineum, bladder, and genital structures. They may be congenital or acquired, and possible causes include infection, inflammatory disease, neoplasms, congenital conditions, trauma, and iatrogenic injury. There may be an anomalous communication between the urethra



**Figure 1.** Stone in the fluid-filled scrotal sac (arrow).

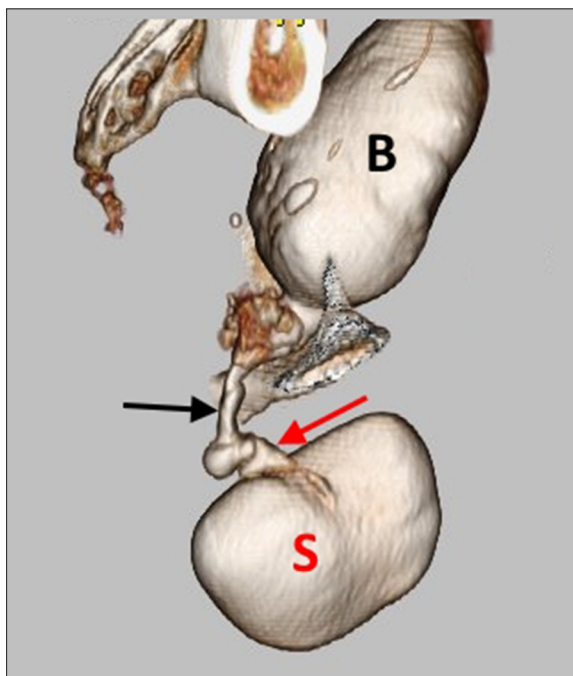


**Figure 2.** Urethroscrotal fistula (arrow) and scrotal sac filled with contrast agent in the late pyelogram phase (S – scrotal sac).

and the scrotum in males iatrogenically [1]. Although it is a very rare, urethral stones may move to the scrotum, perforating the urethra [2]. In our case, we believe that the fistula could have developed iatrogenically during stone excision or secondary to perforation of the urethra by a stone, as described above.

There are many case reports on urethral diverticulum (UD), which involves sac-like dilatations of the urethra, in the literature [3–5]. UD is a very rare condition in men and in 90% acquired in origin. Trauma, infection, stricture, urethral surgery, and iatrogenic wounds are among the causes [3,4]. Urethral stones can also be added to the etiopathogenesis [5,6]. Paraplegic patients have a higher risk of UD due to long-term urethral catheterizations [3]. UDs may be complicated by stone formation [7]. Stricture of the anterior urethra and chronic voiding symptoms cause the development of a diverticulum, in which stones may occur [8]. Urine stasis predisposes patients to infection and formation of calculi within the diverticulum [6]. Urethral diverticulum is a condition similar to USF; however, there is a fistulous tract between the urethra and urine-filled scrotal sac in USF.

Urinary incontinence, obstructive flow pattern and scrotal swelling are significant clinical symptoms. Scrotal mass and urinary leakage after manual compression are the findings in physical examination [4,9].



**Figure 3.** 3D image. The fistula between the urethra and scrotum (black arrow – urethra; red arrow – fistula; B – bladder; S – scrotal sac).

Retrograde urethrography and voiding cystourethrography are considered the standard radiologic techniques for the morphology of the urethra. We can visualize the fistula, accompanying cavities, and passage of the contrast agent into the neighboring organs by retrograde urethrography. But there are some limitations to this technique as it can only visualize the urethral lumen similar to urethroscopy. It is possible for MRI, CT, and US to evaluate periurethral tissues and adjacent anatomic structures that cannot be assessed with VCU, RU, and urethroscopy [10]. MDCT is an important diagnostic tool that can be used as an alternative to traditional radiographic methods. It has many advantages: only one position is enough for the examination, no distortion, 3D images can be created, and associated pathologies can be diagnosed [11].

Diverticulectomy with urethrotomy and end-to-end anastomosis are the surgical procedures most commonly used for treatment [4]. As non-operative management, manual compression is adequate in patients who can empty the scrotal swelling [12].

## Conclusions

Not all scrotal swellings are secondary to hydrocele, epididymal cyst, or hernia. Urethroscrotal fistula, a very rare cause of scrotal swelling, is a distinctive abnormality with its etiology and clinical findings. Therefore, MRI and CT play an important role in delineating the anatomy and extent of the fistulous tract.

## Competing interests

The authors declare that they have no competing interests.

---

**References:**

---

1. Yu NC, Raman SS, Patel M, Barbaric Z: Fistulas of the genitourinary tract: A radiologic review. *Radiographics*, 2004; 24: 1331-52
2. Moralioglu S, Afsarlar C, Ozen IO et al: A rare complication after augmentation cystoplasty: A case report of scrotal calculi. *Turkiye Klinikleri J Med Sci*, 2010; 30: 772-74
3. Stephan-Carlier A, Facione J, Gervaise A et al: A 24-year-old patient with paraplegia and acquired urethral diverticulum: A case report. *Ann Phys Rehabil Med*, 2011; 54: 48-52
4. Peralta JP, Reis M, Rabaça C, Sismeiro A: Acquired male urethral diverticulum: A complication following artificial urethral sphincter implantation. *BMJ Case Rep*, 2013; 2013: pii: bcr2013201542
5. Alphs HH, Meeks JJ, Casey JT, Gonzalez CM: Surgical reconstruction of the male urethral diverticulum. *Urology*, 2010; 76: 471-75
6. Parker WR, Wheat J, Montgomery JS, Latini JM: Urethral diverticulum after endoscopic urethrotomy: Case report. *Urology*, 2007; 70: 1008.e5-7
7. Ho CH, Yu HJ, Huang KH: Scrotal mass with bladder outlet obstruction. *Urology*, 2008; 72: 66-67
8. Prakash J, Sharma P, Sankhwar S, Goel A: Large anterior urethral calculus presented as scrotal mass with urethrocutaneous fistula. *BMJ Case Rep*, 2013; 2013: pii: bcr2013200805
9. Bohnen NJ, Shapiro B: Urethro-scrotal fistula presenting as massive scrotal "bladder" on radionuclide bone scan. *Clin Nucl Med*, 1997; 22: 864-65
10. Pavlica P, Barozzi L, Menchi I: Imaging of male urethra. *Eur Radiol*, 2003; 13: 1583-96
11. Zhang XM, Hu WL, He HX et al: Diagnosis of male posterior urethral stricture: Comparison of 64-MDCT urethrography vs. standard urethrography. *Abdom Imaging*, 2011; 36: 771-75
12. Cinman NM, McAninch JW, Glass AS et al: Acquired male urethral diverticula: Presentation, diagnosis and management. *J Urol*, 2012; 188: 1204-8