



Contents lists available at ScienceDirect

International Journal of Surgery Case Reports

journal homepage: www.casereports.com

Laparoscopic approach to ureteroinguinal hernia

Praveen Lakshmi Narayanan, C.D. Narayanan*, Vishnu Sekar, Akshita Reddy Vadyala

Department of General Surgery, Sri Ramachandra Institute of Higher Education and Research, No.1, Ramachandra Nagar, Porur, Chennai, 600116, India

ARTICLE INFO

Article history:

Received 28 September 2020
 Received in revised form 27 October 2020
 Accepted 27 October 2020
 Available online 2 November 2020

Keywords:

Uretero-inguinal hernia
 Laparoscopic approach
 Hydro-ureteronephrosis

ABSTRACT

INTRODUCTION: Herniation of the ureter into the inguinal canal is a rare occurrence. There have been reports of inadvertent injury to the ureter during routine inguinal hernia repair. After an extensive search of the literature, we believe that this is the first case to be managed via laparoscopic Trans Abdominal Pre-Peritoneal Repair and would like to highlight the technical details of the laparoscopic procedure and is presented in line with SCARE 2018 Guidelines [1].

PRESENTATION OF CASE: A 60-year-old male presented with left inguinal hernia. He also complained of an increase in frequency of micturition, with an occasional radiating pain from loin to the groin. Imaging revealed the left ureter coursing into the left inguinal canal, descending into the scrotum, and looping back to enter the bladder with mild hydroureteronephrosis. Patient underwent a laparoscopic repair of the inguinal hernia with reduction of ureter under ureteroscopy guidance and stent placement.

DISCUSSION: The presence of ureter buried in a large amount of fat can be mistaken for a lipoma of the cord or extraperitoneal fat and injured with blind clamping and division. Presence of fat without an obvious sac should alert the surgeon to the possibility of ureter being a content.

CONCLUSION: Laparoscopy is safe, technically feasible, offers good visualization of all hernial orifices, demonstrates complete reduction of ureter from inguinal canal under vision, allows manipulation of ureter under the vision for ureteroscopy and stenting, making sure there are no loops or kinking and allows placement of mesh in the preperitoneal space.

© 2020 Published by Elsevier Ltd on behalf of IJS Publishing Group Ltd. This is an open access article under the CC BY-NC-ND license (<http://creativecommons.org/licenses/by-nc-nd/4.0/>).

1. Introduction

Herniation of the ureter into the inguinal canal is a rare occurrence. It was first reported in 1880 as an autopsy finding [2]. Since then, there have been reports of inadvertent injury to the ureter during routine inguinal hernia repair. It has been associated with congenital anomalies like renal agenesis [3] or crossed renal ectopia [4] and has also known to be acquired following renal transplant [5]. It may remain asymptomatic and present as a surprise to the hernia surgeon or present with abdominal pain and obstructive uropathy. Men are most commonly affected and presents in the fifth decade of life [2]. Two anatomical variants of uretero-inguinal hernia have been described, para-peritoneal and extraperitoneal. The para-peritoneal type (80%) has a peritoneal indirect sac which pulls the ureter, where the bladder forms the wall, similar to a sliding hernia to some extent. This hernia has expansile impulse on coughing and is well visualized on laparoscopy as a peritoneal defect. The extraperitoneal type (20%) occurs without a peritoneal sac, as in our case; There is no expansile impulse, and it does not

reduce completely, by non-communication with peritoneal cavity. The ureter slides along with the retroperitoneal fat into the scrotum and this is thought to be due to the failure of separation of Wolffian duct from the ureteric bud [6]. There have been varied presentations and management of this unique condition. Majority of the cases where the preoperative diagnosis was not available have resulted in injury to ureter; most often presenting in the postoperative period. Management ranged from percutaneous nephrostomy to nephrectomy, exploratory laparotomy and resection of the ureter with reimplantation [7]. Due to delay in recognition of ureteric injury following hernia repair, mortality has been described in paediatric age group [8]. In cases where a preoperative diagnosis has been made, the management ranged from a simple reduction in open hernia surgery to a complex procedure like ureteroneocystostomy to deal with the redundant ureter [7,9]. Laparoscopy has gained wide acceptance and popularity in the management of hernia and has the benefit of decreased postoperative pain and neuralgic complications. Our patient presented with a groin swelling, and the preoperative imaging confirmed the diagnosis of ureteroinguinal hernia. He had obstructive uropathy and the extraperitoneal variant of ureteral herniation. This was successfully managed by laparoscopy, which offers good visualization of the redundant ureter, helps in removal of adhesions and kinks, assists in straightening the ureter under vision, and has an added advantage of guiding ureteroscopy and stenting. After an extensive

* Corresponding author.

E-mail addresses: lpaveenkapv@gmail.com (P. Lakshmi Narayanan), cdnarayan24@yahoo.com (N. C.D.), vishnusekar97@gmail.com (V. Sekar), akshita.reddy@gmail.com (A.R. Vadyala).

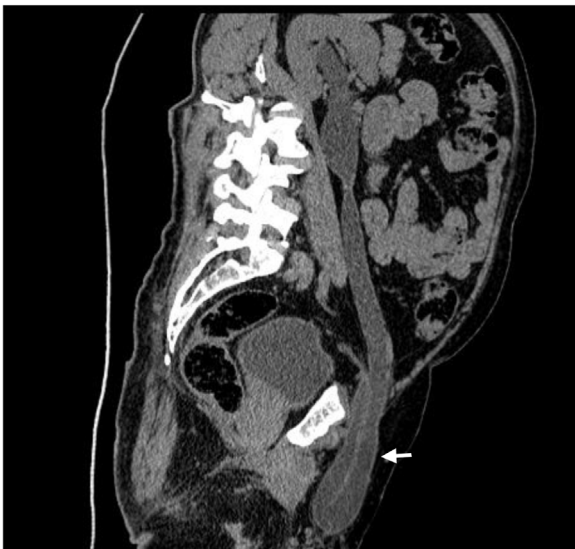

Fig. 1. A plain CT of KUB showing the left ureter coursing into the left inguinal canal, descending into the scrotum, and looping back to enter the bladder (arrow).

search of the literature, we believe that this is the first case to be managed via laparoscopic Trans-Abdominal Pre-Peritoneal Repair and would like to highlight the technical details of the procedure. This case report is presented in line with SCARE-2018 Guidelines [1].

2. Patient information

A 60-year-old male presented to outpatient department with complaints of swelling on the left groin for eight months with associated discomfort, and a noticeable increase in the size of the swelling upon straining, which reduced spontaneously on lying down. He complained of an increased frequency of micturition, with an occasional radiating pain from loin to groin which was not associated with any nausea or vomiting. Clinical examination revealed a boggy swelling in the left inguinal region which seemed to partially decrease in size on compression. A non-expansile impulse was noted on coughing. The other hernial orifices were normal. Clinically, the patient was diagnosed to have a left inguinal hernia. He has no relevant personal or family medical history.

3. Diagnostic assessment

Because of increased frequency of micturition, and renal colic, an Ultrasound KUB was requested, which showed a tubular fluid-filled structure looping around the left inguinal canal, and passing back into the abdominal cavity. A plain CT-KUB showed the left ureter coursing into the left inguinal canal, descending into the scrotum, and looping back to enter the bladder (Fig. 1). There was also a left proximal hydroureteronephrosis. Renal function tests were within normal range.

4. Therapeutic intervention

The patient was planned for a Laparoscopic Trans-Abdominal Pre-Peritoneal repair for ureteric herniation by laparoscopic surgeons. Under General anaesthesia, with patient in supine Trendelenburg position, one 10 mm camera port, and two 5 mm working ports were created. Upon entering the peritoneal cavity, there was no hernial sac. The peritoneum was incised 2 cm above the internal ring and extended medially up to the medial umbilical ligament and laterally up to the anterior superior iliac spine. The peritoneal

flap was raised as in routine Inguinal hernia repair. The Bogros and retropubic space were dissected. The Inferior Epigastric artery was identified and preserved. At the level of the internal ring, there was a large tubular structure extensively covered by fat (Fig. 2), which was dissected slowly by traction and counter-traction utilizing both blunt and sharp dissections, till the apex of the U-shaped sling. There was extensive retroperitoneal fat which had herniated along with the ureter, similar to lipoma of cord. After dissection, the ureter was found grossly dilated and redundant as a sigmoid ureter. To straighten the ureter and to keep it in position, the plan was made to stent the ureter by urologist. A Ureteroscope was passed over the double guidewire and stenting was done. The redundant and tortuous ureter made it extremely difficult for stenting and often an alpha loop would form (Fig. 3) akin to a colonoscopy. Ultimately, this could be achieved by laparoscopic guidance and visualization and endoscopic stenting was done. Once the stent reached the renal pelvis, the ureter straightened out and remained in place. The Bogros space was dissected as in conventional hernia repair. A 12 × 10 cm polypropylene mesh was placed and the peritoneum was closed using 3-0 v-loc sutures. Post-operative period was uneventful. Patient was discharged on post-operative day-2 with ureteric catheter in-situ.

5. Outcomes and follow-up

The patient was followed up at 1 week, 1 month and 12 months by both urologist and laparoscopic surgeons. The ureteric catheter was removed in 4 weeks. At 12-months follow-up, patient was symptom free and had no urinary complaints.

6. Discussion

Inguinal hernia repair is among the commonest surgeries performed. The contents of the hernia are usually small bowel, colon, omentum or urinary bladder which happens commonly in a direct sac or as a part of a sliding hernia. One may encounter the appendix (Amyand's hernia) and Meckel's diverticulum (Littre's hernia) as content in an inguinal hernia, albeit rarely [6]. These may pose a technical difficulty concerning decision-making, regarding placement of mesh when they are infected. In contrast, a rare content that might surprise the surgeon and maybe inadvertently injured is the ureter. The first intraoperative diagnosis was by Reichel and the preoperative diagnosis was by Dourmashkin [2]. High morbidity and even mortality are encountered in cases where a preoperative diagnosis was not made. The presence of ureter, buried in a large amount of fat, can be mistaken for lipoma of the cord or extraperitoneal fat and injured with blind clamping and division. Presence of fat without an obvious sac should alert the surgeon to the possibility of ureter being a content [6]. Considering the volume of hernia surgeries globally, a routine CT scan is not justified but advisable in patients with urinary complaints and deranged renal function tests. Laparoscopy has never been attempted in the uretero-inguinal hernia [6]. Laparoscopy offers a tremendous advantage in the visualization of anatomy before division. In the extraperitoneal type, there is no sac on entering, but on raising a peritoneal flap, a large tubular structure was seen entering the inguinal canal from the retroperitoneum forming a loop, and returning to the bladder. Our management was made easier by preoperative diagnosis with imaging. Once the ureter was mobilized along with the retroperitoneal fat into the abdominal cavity, we could appreciate a redundant sigmoid ureter, and prone for a kink or volvulus. Ureteroscopy with stenting was achieved by a combination of laparo-endoscopy, albeit with difficulty as the ureter was very tortuous. Zarif Vahya Et al. reported a patient who had to undergo stenting followed by repair and required a second sit-

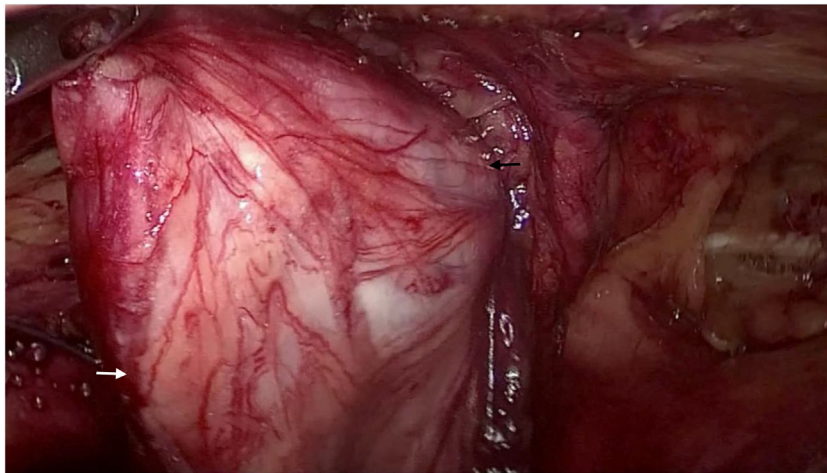


Fig. 2. At the level of the internal ring, there was a large tubular structure extensively covered by fat.
I. White arrow showing the extraperitoneal fat surrounding the ureter.
II. Black arrow showing tortuous ureter.

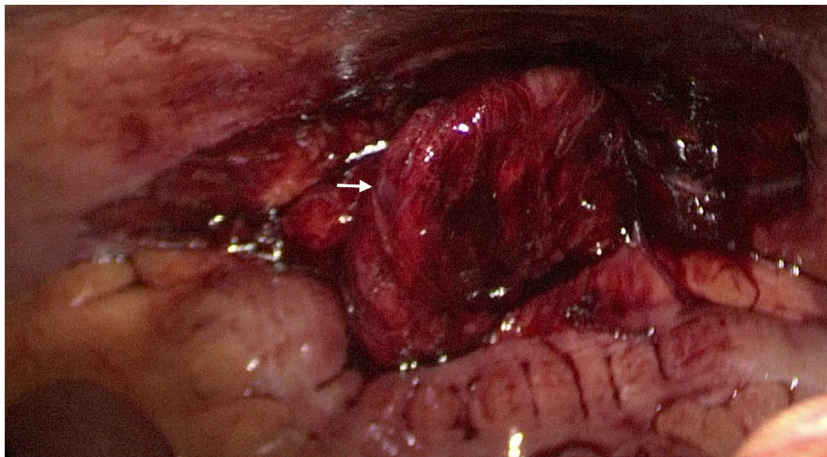


Fig. 3. Figure showing tortuous ureter. (arrow).

ting for stone retrieval once the ureter was straightened out [6]. Laparoscopy offers the advantage of a combined laparo-endoscopy, in dealing with the redundant ureter. The decision to stent was based on the urologist, to keep the ureter in place till adhesions form, to straighten out the ureter and also relieve the obstruction caused by kinking. This anomaly of extraperitoneal type has also been documented in association with other congenital abnormalities (agenesis of the gall bladder and left kidney) [3]. Another association of ureter herniation is in post-renal transplant, possibly due to neopositioning without any adhesions [2]. Majority of inguinal hernia is dealt by general surgeons without imaging as it is cost-effective. Ultrasound or CT-KUB should be considered in patients with urinary complaints, altered renal function tests, and also in groin swellings which are irreducible. Unilateral hydronephrosis or tubular fluid-filled loop in the inguinal canal must nudge the surgeon for a preoperative assessment which includes CT-Urogram.

7. Conclusion

Finally, laparoscopy is safe, technically feasible, offers good visualization of all hernial orifices, demonstrates complete reduction of ureter from inguinal canal under vision, allows manipulation of ureter under the vision for ureteroscopy and stenting, making sure

there are no loops or kinking and allows placement of mesh in the preperitoneal space.

Declaration of Competing Interest

The authors report no declarations of interest.

Funding

Nil source of funding.

Ethical approval

No ethics required for this case report. An ethics approval from the institution is exempt.

Consent

Written informed consent was obtained from the patient for publication of this case report and accompanying images. A copy of the written consent is available for review by the Editor-in-Chief of this journal on request.

Author contribution

Praveen Lakshminarayanan: Conceptualization, Methodology, Software, Formal analysis, Data curation, Writing – review and editing, Project administration.

C.D. Narayanan: Conceptualization, Methodology, Validation, Formal analysis, Data curation, Writing – original draft, Writing – review and editing, Visualization, Supervision.

Akshita Reddy Vadyala: Conceptualization, Software, Validation, Formal analysis, Data curation, Writing – review and editing, Visualization.

Vishnu Sekar: Conceptualization, Software, Validation, Data curation, Writing – review and editing, Investigation, Resources, Data curation.

Registration of research studies

1. Name of the registry: RESEARCH REGISTRY
2. Unique identifying number or registration ID: researchregistry6158
3. Hyperlink to your specific registration (must be publicly accessible and will be checked): <https://www.researchregistry.com/browse-the-registry#home/registrationdetails/5f958697e0d0d70015951a4d/>

Guarantor

C.D. Narayanan.

Provenance and peer review

Not commissioned, externally peer-reviewed.

References

- [1] R.A. Agha, M.R. Borrelli, R. Farwana, K. Koshy, A. Fowler, D.P. Orgill, For the SCARE Group, The SCARE 2018 statement: updating consensus surgical CAse REport (SCARE) guidelines, *Int. J. Surg.* 60 (2018) 132–136.
- [2] M. Masood Sidiqi, Geoffrey Menezes, Asymptomatic herniation of ureter in the routine inguinal hernia: a dangerous trap for general surgeons, *Int. J. Surg. Case Rep.* 49 (2018) 244–246, <http://dx.doi.org/10.1016/j.ijscr.2018.07.013>.
- [3] Ronaldo de Carvalho Neiva, Carlos Eduardo, Garcia Westin, et al., Inguinal hernia with ureter in patient with single kidney, *AME Case Rep.* 2 (5) (2018), <http://dx.doi.org/10.21037/acr.2018.01.05>.
- [4] Marc S. Rocklin, Keith N. Apelgren, et al., Scrotal incarceration of ureter with crossed renal ectopia: case report and literature review, *J. Urol.* 142 (1989) 366–368, [http://dx.doi.org/10.1016/S0022-5347\(17\)38761-X](http://dx.doi.org/10.1016/S0022-5347(17)38761-X).
- [5] Sameer Vyas, Neha Chabra, et al., Inguinal herniation of bladder and ureter: an unusual cause of obstructive uropathy in a transplant kidney, *Saudi J. Kidney Dis. Transpl.* 25 (1) (2013) 153–155, <http://dx.doi.org/10.4103/1319-2442.124549>.
- [6] Zarif Yahya, Yahya Al-Habbal, Sayed Hassen, Ureteral inguinal hernia: an uncommon trap for general surgeons, *BMJ Case Rep.* 2017 (2017), <http://dx.doi.org/10.1136/bcr-2017-219288>.
- [7] Erik Anderson, Anthony Corcoran, Obstructive uropathy due to incarcerated ureteroinguinal hernia, *World J. Nephrol. Urol.* 4 (3) (2015) 237–239, <http://dx.doi.org/10.14740/wjnu218w>.
- [8] Ralph L. Dourmashkin, Scrotal hernia of ureter, associated with a unilateral fused kidney: a case report, *J. Urol.* 38 (5) (1937) 455–467, [http://dx.doi.org/10.1016/S0022-5347\(17\)71975-1](http://dx.doi.org/10.1016/S0022-5347(17)71975-1).
- [9] E.S. Allam, D.Y. Johnson, S.G. Grewal, F.E. Johnson, Inguinoscrotal herniation of the ureter: description of five cases, *Int. J. Surg. Case Rep.* 14 (2015) 160–163, <http://dx.doi.org/10.1016/j.ijscr.2015.06.044>.

Open Access

This article is published Open Access at [sciencedirect.com](https://www.sciencedirect.com). It is distributed under the [IJSCR Supplemental terms and conditions](#), which permits unrestricted non commercial use, distribution, and reproduction in any medium, provided the original authors and source are credited.