

Nasofrontal dermoid with sinus tract upto the tip of the nose: A case report with review of the literature

Ashok Gandhi, I. Vijay Sundar, Achal Sharma, R. S. Mittal, Sapna Gandhi¹

Departments of Neurosurgery, ¹Pathology, SMS Medical College and Hospital, Jaipur, Rajasthan, India

ABSTRACT

Nasofrontal dermoid with sinus tract extending to the nasal tip is rare in adults. It is unique in its embryological origin, presentation, and management. Pathogenesis involves the incomplete obliteration of the developing neuroectoderm. A sinus opening with intermittent oily discharge is characteristic. Associated intracranial extension may lead to meningitis and brain abscess. We present a case of a 21-year-old adult having a nasofrontal sinus tract with intracranial extension who presented with recurrent episodes of meningitis and discuss the physical findings with relevance to embryology, elaborating on the importance and means of addressing the intracranial as well as extracranial components for complete treatment.

Key words: Adult, nasofrontal dermoid, recurrent meningitis

Introduction

Nasal dermoid cyst accounts for 1-3% of all dermoid cysts and unlike other craniofacial dermoids, these lesions can present as cyst, sinus, or fistula and may have an intracranial extension.^[1] The incidence is estimated at 1 in 20,000 to 1 in 40,000 births.^[2] Progressive enlargement of the nasal dermoid can lead to soft tissue or skeletal deformity, local infection, or intracranial complications such as meningitis or abscess. A timely diagnosis and complete surgical excision is essential to avoid such complications. Most of the cases are diagnosed in first 3 years of life, but in some cases diagnosis may be delayed. The oldest case in the literature was 56 years old. We present a 21-year-old male with a nasofrontal sinus tract and intracranial extension who presented with recurrent episodes of meningitis.

Case History

A 21-year-old male presented with recurrent episodes of headache and oily discharge from a dimple at the tip of

the nose since childhood. Each episode of headache was accompanied by dizziness, neck stiffness, irritability, and photophobia. There was no h/o fever, nausea, vomiting, or seizure. Patient's neurological examination revealed nothing abnormal. There was a small dimple on the tip of the nose [Figure 1]. There was no spontaneous watery discharge from the dimple but there was a formation of a droplet on compressing the nose. A contrast CT head showed a small hypodense lesion at the anterior basifrontal region [Figure 2]. A hyperintense lesion was noted in the same location on MRI [Figure 3] with a small tract going up to the nasal tip [Figure 4]. The patient was diagnosed as intracranial basifrontal dermoid cyst with extracranial nasal sinus tract.

A combined single-stage craniofacial approach was planned and the plastic surgery team was consulted. After much deliberation including consideration of patients' fears of a facial scar and urgent need for intracranial surgery in view of recurrent meningitis, it was decided to proceed with surgery of the intracranial component first.

A bifrontal craniotomy was performed and orbitonasal ridge was removed. The dura opened horizontally along the cranial base and then extended in a 'T' shape upto the crista galli. Both frontal lobes were separated to expose the basifrontal dermoid. The lesion and involved falx was removed. Crista galli was removed after separating the dura on either side. A small cyst with sinus tract was penetrating the crista galli and going into the bony septum. The sinus tract was excised all the way upto the osteocartilagenous junction. The dura was closed primarily and reinforced with a pericranial patch. The bone flap was replaced and secured. The plastic surgery team was present during the surgery and were satisfied with

Access this article online	
Quick Response Code:	Website: www.asianjns.org
	DOI: 10.4103/1793-5482.145344

Address for correspondence:

Dr. Ashok Gandhi, Department of Neurosurgery,
SMS Medical College and Hospital, Jaipur, Rajasthan, India.
E-mail: gandhineuro@gmail.com

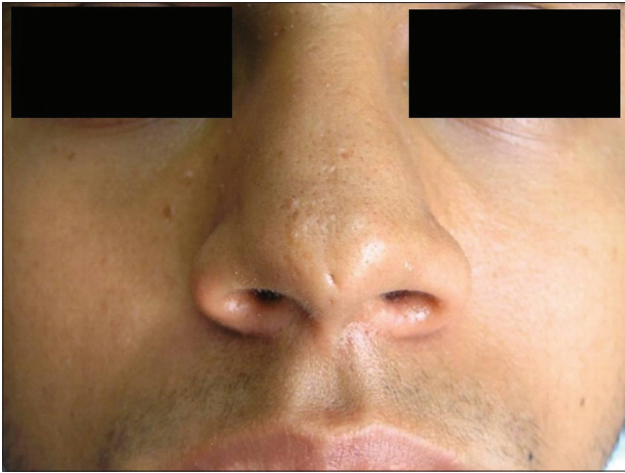


Figure 1: Clinical photograph showing a dimple at the tip of the nose

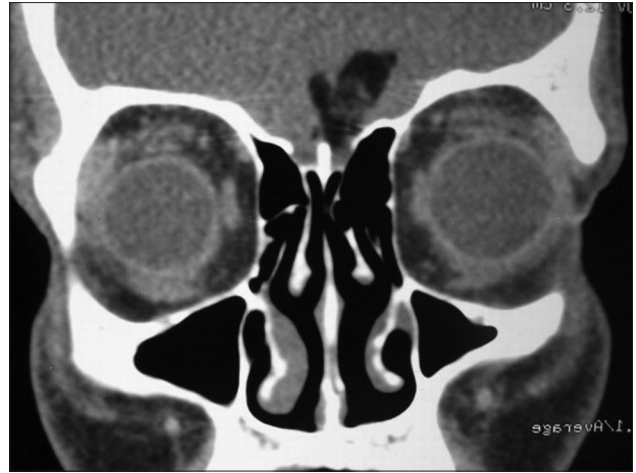


Figure 2: CT scan showing a hypodense lesion

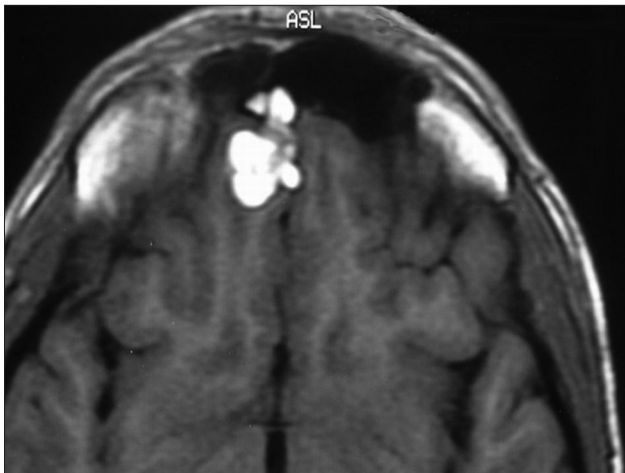


Figure 3: Axial T1 MRI image showing a hyperintense lesion

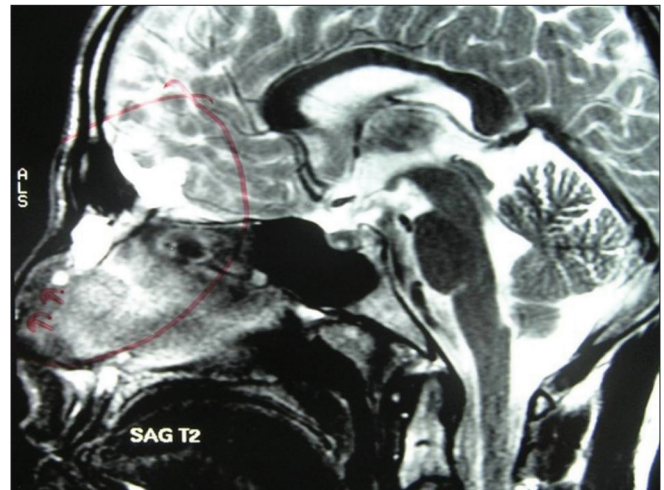

Figure 4: Sagittal T2 MRI image showing sinus tract up to the nasal tip

the extent of removal of the sinus tract that was achieved through a bifrontal craniotomy alone.

The postoperative course was uneventful. Histopathology was reported as dermoid. The patient is in follow-up since last 5 years and has had no episode of headache, photophobia, or watery discharge, and his sense of smell is intact. He is still reluctant for surgical removal of the remaining tract.

Discussion

Nasal dermoid is a rare developmental anomaly.^[3] Although first described by Cruveleir in 1817. Sessions first coined the term nasal dermoid cyst.^[1] Nasal dermoid is an uncommon congenital anomaly with an incidence of 1 per 20,000 to 40,000 births.^[4] It makes up 1-3% of all dermoids and 4-12 % of head and neck dermoids.

The nose is formed by ectoderm, mesoderm, and a deeper layer of the cartilage. During the eighth and ninth week

of gestation, the nasal and frontal bone develop by means of intramembranous ossification in the mesoderm but remain separated by a potential space known as fonticulus nasofrontalis.^[4] At around the same time, prenasal space is formed and there is small dural extension from the frontal region to the nasal skin. As the nasal process of the frontal bone grows, the skin and dura become separated and projection of the dura gets encircled by the foramen cecum. Normally the dura gets obliterated, fonticulus nasofrontalis and foramen cecum fuse, while the cribriform plate is formed.

Nasal dermoid cyst either arises from a cluster of epithelium trapped during the embryological development or failure of obliteration of the ectodermal extension. Sutton's superficial sequestration theory suggests entrapped ectoderm as the cause but it cannot explain its intracranial extension.^[1,4] Littlewood's trilaminar theory suggests persistence of the central ectodermal layer. Pratt's prenasal theory is most widely accepted and suggests that the receding dura pulls up the nasal ectoderm to form cyst or sinus.^[2]

The nasofrontal dermoid may present as a non-tender swelling on the dorsum of the nose, as a dimple on the tip of the nose with or without protruding hair and sebaceous discharge, as a glabellar swelling or as nasal widening with hypertelorism. The dimple at the tip of the nose with or without protruding hair and sebaceous discharge is pathognomic for nasal dermoid cyst/sinus.

The intracranial portion usually remains extra-axial involving the dura and falx cerebri. Intraparenchymal extension is uncommon and tends to be limited to the frontal lobes. Intracranial complications may include a Mollaret's type of chemical meningitis, infectious meningitis, abscess formation, osteomyelitis, seizures, and personality changes.^[5,6]

In most reported cases, the transcranial tract courses through the foramen cecum, and less commonly through crista galli or cribriform plate. In our case, the tract was passing through the crista galli.

MRI, though valuable for defining the intracranial as well as extracranial extent,^[7,8] does not help identify the exact site of a sinus tract. CT is more useful in identifying the sinus tract. Findings of enlarged foramen cecum and bifid crista galli, if present, suggest intracranial extension.^[9] Associated findings include glabellar destruction, inter ethmoid space widening, disruption of the nasal vault, and increased interorbital distance. Patients presenting with a nasal dimple should undergo coronal CT scan with thin slices. The presence of any of the above features warrants an MRI. Conversely patients with anterior cranial fossa dermoid should have a close examination of the nasal surface and thin slice coronal CT scan should be obtained.

Nasofrontal dermoid has not been attributed to the any genetic defect although familial clustering has been described.^[10,11] Concomitant congenital anomalies described are an absent third ventricle and septum pellucidum, spinal anomalies, agenesis of the corpus callosum, tracheoesophageal fistula, preauricular sinuses, and midline facial defect such as cleft lip and cheileognathopalatoschiasis. The incidence of multiple anomalies is 5-41%.^[11,12] The presence of associated anomalies increases the likelihood of intracranial extension.^[13]

A bifrontal craniotomy with the removal of orbitonasal ridge allows the removal of the intracranial component as well as most of the nasal component through the same incision without the need of the lateral rhinotomy. Coronal approach is preferred over transfacial approach as it causes less scarring.^[14] A single-stage combined craniofacial approach^[14,15] is generally recommended for minimal morbidity and to prevent recurrence. Incomplete excision of nasofrontal dermal sinus is likely to increase the rate of recurrence which can be as high as 50-100%.^[4,16] Alternative surgical options described

are subcranial approach, extracranial approaches using endoscopic techniques, and parasagittal osteotomies through the supraorbital bar.^[15]

The remaining nasal tract can also be removed by a small incision through the nares or columella. Careful removal of the crista galli and primary closure of the dura without damaging the olfactory bulb is important for the preservation of the sense of smell.

Conclusion

Nasofrontal dermoid with sinus tract upto the tip of the nose is a rare condition with unique embryological and pathogenetic mechanisms that warrant meticulous evaluation by CT and MRI along with operative planning by a combined team of neurosurgeons and plastic surgeons. Single-stage-combined complete craniofacial excision offers the best and safest way to cure the condition and prevent recurrence. Various surgical options exist but preservation of olfactory apparatus is vital to all procedures to preserve the sense of smell.

Declaration of patient consent

The authors certify that they have obtained all appropriate patient consent forms. In the form the patient(s) has/have given his/her/their consent for his/her/their images and other clinical information to be reported in the journal. The patients understand that their names and initials will not be published and due efforts will be made to conceal their identity, but anonymity cannot be guaranteed.

Acknowledgment

All the authors participated equally in the preparation of this manuscript.

References

1. Sessions RB. Nasal dermal sinuses--new concept and explanation. *Laryngoscope* 1982;92 (8 Pt 2 Suppl 29):1-28.
2. Pratt LW Midline cyst of the nasal dorsum: Embryological origin and treatment. *Laryngoscope* 1965;75: 968-80.
3. Zerries A, Annino D, Heilman CB Nasofrontal dermoid sinus cyst: Report of two cases. *Neurosurgery* 2002;51:811-14.
4. Rahbar R, Shah P, Mulliken JB, Robson CD, Perez-Atayde AR, Proctor MR, *et al.* The presentation and management of nasal dermoid: A 30-year experience. *Arch Otolaryngol Head Neck Surg* 2003;129:464-71.
5. Manglia AJ, Goodwin J, Arnold JE, Ganz E Intracranial abscesses secondary to nasal, sinus, and orbital infection in adult and children. *Arch Otolaryngol Head Neck Surg* 1989;115:1424-9.
6. Mount LA Congenital dermal sinuses as causes of meningitis, intraspinal abscess and intracranial abscess. *J Am Med Assoc* 1949;139:1263-8.
7. Barkovich J, Vandermarck P, Edwards M, Cogen PH Congenital nasal masses CT and MR imaging features in 16 cases. *AJNR Am J Neuroradiol* 1991;12:105-16.
8. Lusk RP, Lee PC Magnetic resonance imaging of congenital midline nasal masses *Otolaryngol Head Neck Surg* 1986;95 (3 Pt 1):303-6.
9. Pensler JM, Baur BS, Naidich TP Craniofacial dermoid. *Plast Reconstr*

- Surg 1988;82:953-8.
10. Plewes JL, Jacobson I Familial frontonasal dermoid cyst: Report of four cases. *J Neurosurg* 1971;34:683-6.
 11. Bratton C, Suskind DL, Thomas T, Kluka EA Autosomal dominant familial frontonasal dermoid cyst: A mother and her identical twin daughters. *Int J Pediatr Otorhinolaryngol* 2001;57:249-53.
 12. Morgan DW, Evans JN Developmental nasal anomalies. *J Laryngol Otol* 1990;104:394-403.
 13. Wardinsky TD, Pagon RA, Kropp RJ, Hayden PW, Clarren SK Nasal dermoid sinus cyst: Association with intracranial extension and multiple malformation. *Cleft Palate Craniofac J* 1991;28:87-95.
 14. Holzmann D, Huisman TA, Holzmann P, Stoeckli SJ. Surgical approaches for nasal dermal sinus cysts. *Rhinology* 2007;45:31-5.
 15. Hanikeri M, Waterhouse N, Kirkpatrick N, Peterson D, Macleod I. The management of midline transcranial nasal dermoid sinus cysts. *Br J Plast surg* 2005;58:1043-50.
 16. McCaffrey TV, McDonald TJ, Gorenstein A. Dermoid cyst of the nose: Review of 21 cases. *Otolaryngol Head Neck Surg* 1979;87:52-9.

How to cite this article: Gandhi A, Sundar IV, Sharma A, Mittal RS, Gandhi S. Nasofrontal dermoid with sinus tract upto the tip of the nose: A case report with review of the literature. *Asian J Neurosurg* 2016;11:178.

Source of Support: Nil, Conflict of Interest: None declared.

