


Contents lists available at [ScienceDirect](https://www.sciencedirect.com)

JPRAS Open

journal homepage: www.elsevier.com/locate/jpra



Case Report

A rare complication of radiofrequency treatment for cellulite of the lower leg

F. Ulrich^{a,*}, L. Elahi^a, L. Schiraldi^a, A. Grobbelaar^b, W. Raffoul^a

^a Department of Plastic, Reconstructive and Hand Surgery, University Hospital of Lausanne (CHUV), Rue du Bugnon 46, 1011, Lausanne, Switzerland

^b Department of Plastic, Reconstructive and Hand Surgery, University Hospital of Bern, Switzerland

ARTICLE INFO

Article history:

Received 5 November 2021

Revised 13 March 2022

Accepted 21 April 2022

Available online 6 May 2022

Keywords:

Radiofrequency treatment

3rd degree burning injury

Aesthetic medicine

Reconstructive surgery

Tattoo

ABSTRACT

Radiofrequency (RF) is increasingly used as an aesthetic treatment for a variety of purposes ranging from the treatment of acne scarring, cellulite correction and skin and soft tissue rejuvenation. The majority of patients experience no complications, and the treatment is therefore also frequently administered by non-medically trained staff. We present a patient, who developed severe 3rd degree burn after RF treatment requiring reconstructive surgery with a split thickness skin graft.

© 2022 Centre hospitalier universitaire vaudois. Published by Elsevier Ltd on behalf of British Association of Plastic, Reconstructive and Aesthetic Surgeons.

This is an open access article under the CC BY-NC-ND license (<http://creativecommons.org/licenses/by-nc-nd/4.0/>)

Introduction

Radiofrequency (RF) is a commonly used treatment in the field of aesthetic medicine.¹ Unlike lasers, RF does not target specific chromophores by selective photo thermolysis. Instead, RF generates heat resulting from different tissue resistances to the electro-magnetic current.² The very fast oscillations of one or two electrodes creates heat by friction. This heat causes the temperature in the target cells to rise to around 40–45° leading to the denaturation of proteins and collagen.

* Corresponding author.

E-mail address: franzisca.ulrich@gmail.com (F. Ulrich).

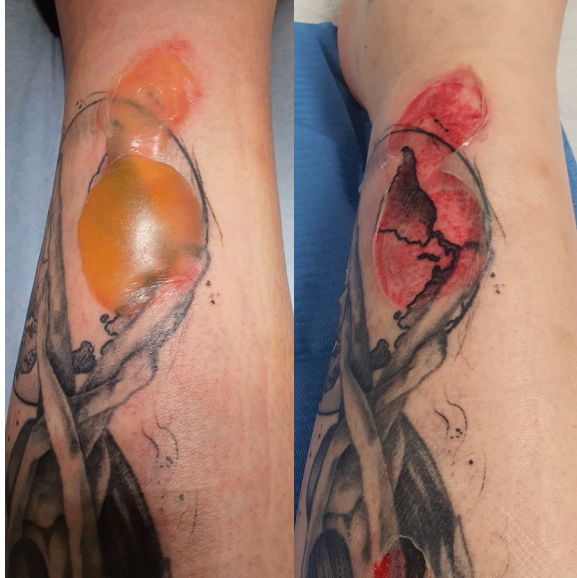

Figure 1. (a) Day 2 after the initial treatment. (b) Day 2 after blisters debridement.

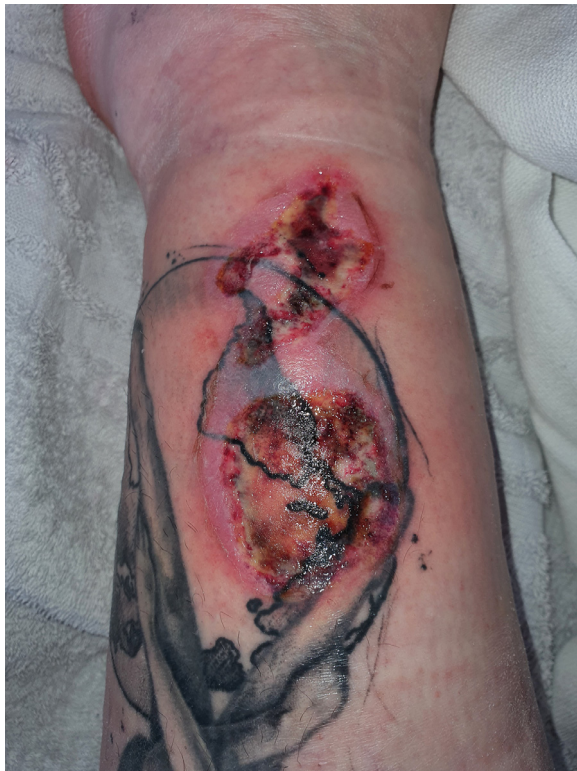

Figure 2. Week 2 after the treatment: deepening of the burn.

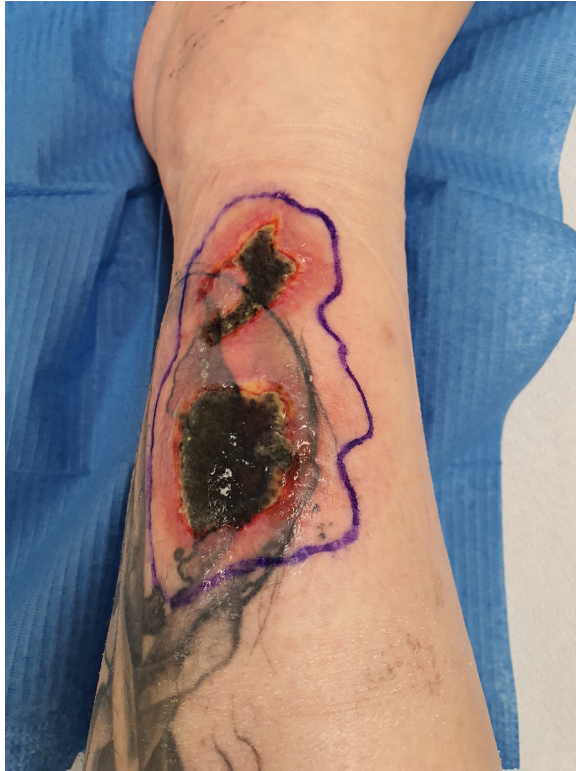

Figure 3. Week 4.

Complications like second and third degree burn injuries are usually described in percutaneous radiofrequency treatment but not with transcutaneous radiofrequency alone.³

We present a patient who underwent monopolar radiofrequency as an anti-cellulite treatment, who developed a third-degree burn injury in the left lower leg after RF treatment. To our knowledge, this progressive pattern of a burn after percutaneous radiofrequency has not previously been reported.

Case presentation

A 28-year-old woman presented with a superficial burn on her left lower leg overlying a part of a tattoo covering half of her lower leg (Figure 1). She underwent aesthetic RF therapy as an anti-cellulite treatment in a cosmetic institute for both of her lower legs two days prior to the presentation in our clinic. The same treatment has been performed in both of her legs. Only the left sided lower leg had a tattoo. The treatment has been performed by a cosmetic institute with no medical staff supervision. The approach has been within a standardized protocol and similar parameters had been used on both legs. A monopolar RF machine has been used for the treatment.

The initial treatment of the burn has been started in another hospital with an application of sulfadiazin silver cream (Flammazine®, Alliance pharmaceuticals GmbH, Uster Switzerland). The patient had no comorbidities and never had any other aesthetic treatment. On examination the patient presented two blisters, measuring about 3cm² each. We performed an initial debridement of the blisters and started a treatment with natriumhyaluronat and sulfadiazin silver cream (Ialugen plus®, ISBA institute Biochimique SA, Pambio-Noranco Switzerland) (Figure 2).

Two weeks later the burn progressed into an intermediate burn, showing already some signs of necrosis in the centre of the wound (Figure 3). We pursued our initial treatment with a regular follow

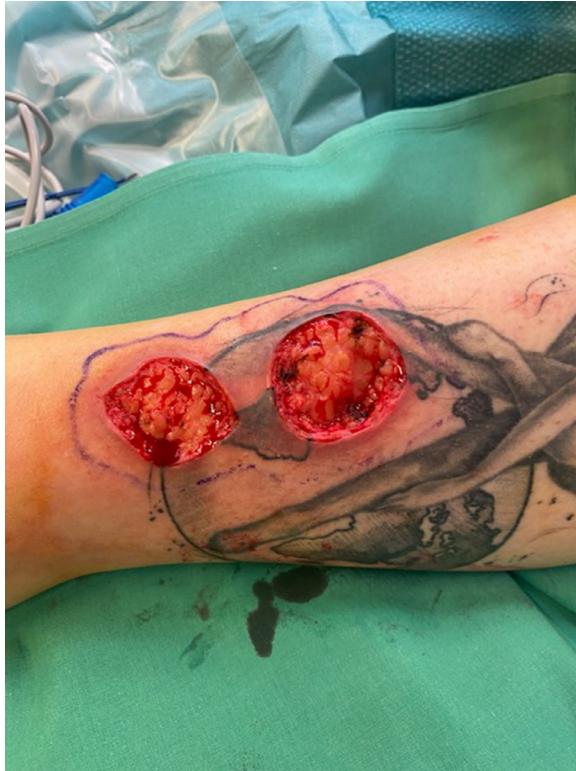

Figure 4. Week: post necrosectomy status in the operating room.

up to leave time for demarcation. 4 weeks post RF both wounds presented with a third degree burn necrosis, requiring debridement in the OR (Figure 4).

During the intervention we confirmed full thickness skin necrosis, requiring debridement down to the adipose tissue (Figure 5). We covered the wounds with a split thickness skin graft taken from her left thigh. We used a tie-over bolster dressing for 5 days.

The post-operative course has been without any complication and an excellent healing progression.

Discussion

Transcutaneous RF is known to have minimal complications. Major complications are considered to be those that require further treatment, whether that consists of a surgical revision or alternative treatment. Those complications are usually only described when using percutaneous RF.³

The burn pattern in our patient, developing from a superficial second degree burn into a deep skin necrosis is rather unusual. Normally first- and superficial second-degree burn is healing with a conservative treatment without any scar development.⁴ This might be due to the fact, that the burn has developed in the depth, causing vascular compromise to the superficial adjoined skin area.

The reason for a third-degree burn in our patient might be her tattoo, although there is no relation described in literature between RF and tattoo. However, RF-induced heating of single and multiple tattoos during magnetic resonance imaging (MRI) confirms, that factors like tattoo pigment, tattoo shape, tattoo thickness, multiple tattoos, the gap between tattoos, position of tattoos on a human phantom, and conductivity of iron oxide, may introduce higher RF-introduced heating. The radio frequency of MRI interacts with the ferromagnetic material found in tattoos, especially iron oxide.⁵ It is therefore

possible, that the different depths of the ink of the tattoo and its ferromagnetic material have caused rising temperature over 45°, leading to a denaturation of proteins and burn.

Conclusion

Severe complications with RF treatment have only been described in transcutaneous aesthetic treatment. The lack of knowledge about the exact mechanisms of burn injuries in RF, makes it a potentially more dangerous treatment than thought before. Patients with tattoos should be advised to avoid aesthetic treatments with RF. Furthermore, it seems to be important to do further research on the exact mechanisms between tattoos and percutaneous radiofrequency that can lead to important aesthetic consequences.

Declaration of Competing Interest

All authors disclose any financial and personal relationships with other people or organisations that could inappropriately influence (bias) this work.

Informed consent

The patient gave us her permission to include case details and images in the publication.

Funding

None

Ethical approval

Not required

References

1. Oliveira Paggiaro A, Pinheiro R, Soares K, Fernandes Carvalho V, Gemperli R. Evaluation of the evidence level for the use of radiofrequency in aesthetic treatments: a systematic review and meta-analysis. *J Cosmet Dermatol*. 2021;20(9). doi:[10.1111/jocd.14353](https://doi.org/10.1111/jocd.14353).
2. Dayan E, Burns AJ, Rohrich RJ, Theodorou S. The use of radiofrequency in aesthetic surgery. *Plast Reconstr Surg Glob Open*. 2020 Published online. doi:[10.1097/GOX.0000000000002861](https://doi.org/10.1097/GOX.0000000000002861).
3. Duncan DI. Complications of treatment with radiofrequency in aesthetic medicine. In: 2014. doi:[10.1159/000362750](https://doi.org/10.1159/000362750).
4. Ahuja RB, Puri V, Gibran N, et al. ISBI practice guidelines for burn care. *Burns*. 2016;42(5). doi:[10.1016/j.burns.2016.05.013](https://doi.org/10.1016/j.burns.2016.05.013).
5. Hayat S, Cho Y, Oh S, Yoo H. RF-induced heating of various tattoos at magnetic resonance imaging systems. *IEEE Access*. 2021;9. doi:[10.1109/ACCESS.2021.3097145](https://doi.org/10.1109/ACCESS.2021.3097145).