



## Case report

### A case of cystic adventitial disease of the popliteal artery: selection of incision of the cyst wall over vessel replacement

Masafumi Tanaka<sup>1</sup>, Yasuyuki Shimada<sup>2</sup>, and Yasushi Terada<sup>2</sup>

<sup>1</sup>Department of General Medicine, Shonai-Amarume Hospital, Japan

<sup>2</sup>Department of Cardiovascular Surgery, Shonai-Amarume Hospital, Japan

#### Abstract

Cystic adventitial disease (CAD), a rare arterial disorder, can cause localized arterial stenosis or obstruction. A 55-year-old man presented with a 2-month history of left lower leg pain and paleness when bending the left knee. The patient was diagnosed with CAD of the left popliteal artery based on imaging examinations. Surgery was performed with the patient placed in the prone position using an S-shaped skin incision, and the left popliteal artery was exposed. A simple incision of the cyst wall was made. There was no sign of recurrence at 1 year postoperatively.

**Key words:** cystic adventitial disease, popliteal artery, surgery

(J Rural Med 2020; 15(1): 47–49)

## Case report

A 55-year-old man presented with a 2-month history of left sural pain and paleness when bending the left knee. He works as a combine driver in his rice field. Physical examination revealed absent pulse in the left dorsalis pedis artery and the popliteal artery. The inguinal pulse was present. The ankle-brachial pressure index of the left and right side was 0.92 and 1.17, respectively. Ultrasound examination (US) showed significant stenosis in the left popliteal artery, but there were no findings of atherosclerotic change. Computed tomography (CT) showed scimitar-like stenosis (Figure 1). Magnetic resonance imaging (MRI) showed a unilocular cyst in the arterial wall and a small cysts toward the knee joint (Figure 2). The patient was diagnosed with CAD of the left popliteal artery. Considering his age and work environment, we decided to perform incision of the cyst wall

and drainage of the cyst. We had a good view of the great saphenous vein around the knee joint even under prone position; thus, we could use a vein graft, if necessary. We performed an S-shaped skin incision via a posterior approach. We exposed the left popliteal artery and cut and ligated the medial genicular artery. When the longitudinal incision of the cyst was made, translucent gelatinous material flowed out (Figure 3). After complete drainage of the gelatinous material, good pulsation of the popliteal artery was noted. The adventitia was repaired to prevent aneurysm formation. The patient had a good recovery and was discharged 1 week after the surgery. Repeated US did not reveal any recurrence after resection of the adventitia. No cysts behind the artery were noted on MRI performed 1 week, 6 months, and 1 year (Figure 4) postoperatively. The patient is symptom free and working as a farmer as before.

#### Informed consent and ethical considerations

This study was conducted in accordance with the Declaration of Helsinki.

#### Discussion

The pathogenesis of CAD is controversial. The proposed hypotheses are as follows. 1) *De novo* mucinous degeneration in CAD is associated with a generalized/systemic disorder. The number of case reports have been increasing, but

Received: August 22, 2019

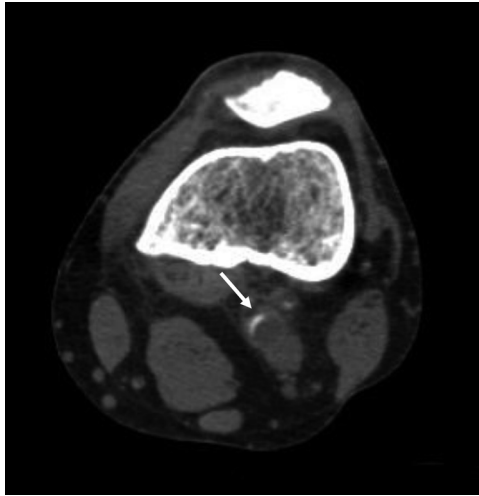
Accepted: October 21, 2019

Correspondence: Yasuyuki Shimada, Department of Cardiovascular Surgery, Shonai-Amarume Hospital, 1-1-1 Shoyo, Shonai, Higashi-Tagawa, Yamagata 999-7782, Japan

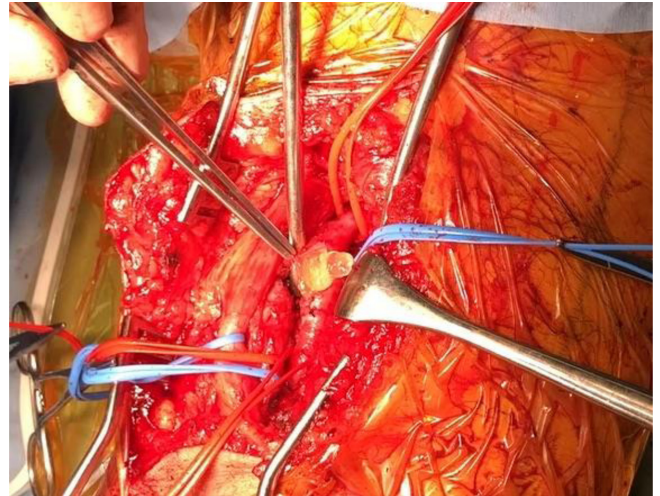
E-mail: dnpdg958@ybb.ne.jp

This is an open-access article distributed under the terms of the Creative Commons Attribution Non-Commercial No Derivatives (by-nc-nd) License <<http://creativecommons.org/licenses/by-nc-nd/4.0/>>.

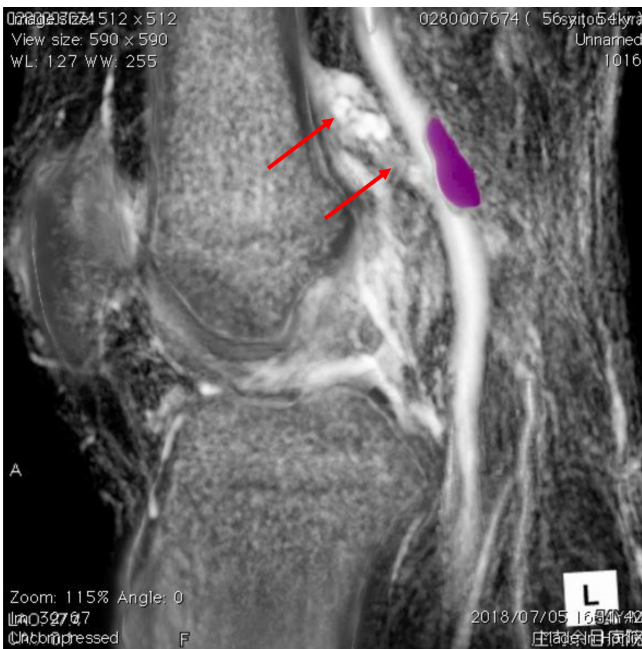




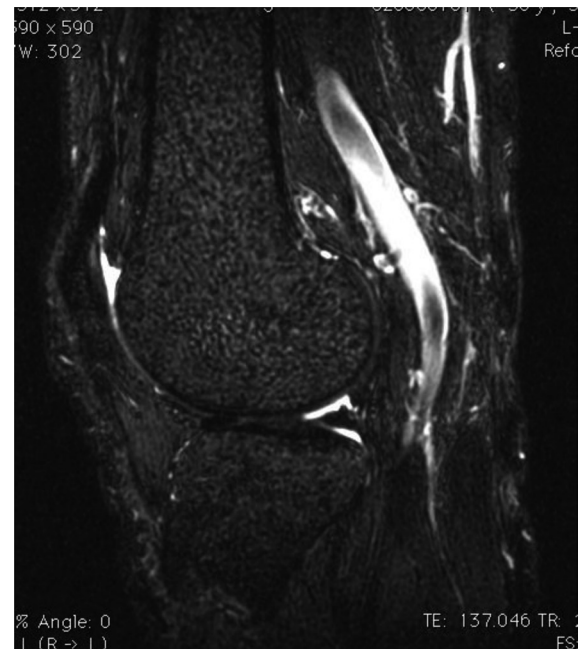
**Figure 1** Preoperative CT scan showing scimitar-like stenosis (arrow), which is characteristic of CAD.



**Figure 3** The tip of the forceps shows drainage of gelatinous material from the cyst when a longitudinal incision was made.



**Figure 2** Preoperative MRI scan showing a unilocular cyst in the arterial wall (purple area) and small cysts (arrows) toward the knee joint along the medial genicular artery.



**Figure 4** MRI scan at 1 year postoperatively showing no recurrence of CAD of the popliteal artery and reduction in small cysts toward the knee joint.

this theory is not favored because of insufficient substantiating evidence of systemic disorder<sup>1)</sup>. 2) There is embryological displacement of mucin-secreting cells to the adventitia of the artery, leading to the development of cysts. However, this theory implies that the adventitial cyst content would be characterized by epithelial secretion rather than collagen and ground substance breakdown<sup>2)</sup>. 3) Synovial ganglions migrate along the vascular branches from the knee joint capsule. This theory is supported by a surgical report describing

the connection among these cysts, the adventitial cyst, and the joint itself<sup>3)</sup>. Furthermore, the synovial theory is favored over the embryological developmental theory by the chemical nature of the cystic content<sup>2)</sup>. 4) Repeated microtrauma, such as stretch injuries, mediates cystic degeneration. This theory is supported by the predominance of disease among middle-aged men with heavy occupational activity involving the legs. The repeated shearing force may cause small detachments of the adventitia from the media, with the in-

tramural hemorrhage developing into cysts within the adventitia. However, the traumatic theory has been questioned because a history of trauma is rare in these patients<sup>1</sup>.

Angiography, US, CT, and MRI can all be performed for diagnosis<sup>1, 4</sup>. Studies emphasize the importance of MRI and show evidence of the synovial theory through careful and repeated MRI<sup>1, 3</sup>. In our case, US suggested the possibility of CAD in the first imaging examination because of the absence of atheromatous lesion. Enhanced CT showed scimitar-like stenosis, which is distinctive in CAD. MRI and three-dimensional CT angiography (3DCTA) showed the precise location of CAD in the popliteal artery and small cysts toward the knee joint. We can obtain important information from 3DCTA and MRI to determine the surgical strategy.

A review<sup>1</sup> described the treatment of CAD such as 1) CT- or US-guided aspiration, 2) replacement with a vein graft, and 3) resection of the cyst. Case reports on aspiration showed a high rate of early recurrence<sup>5, 6</sup>. Surgical treatment is recommended and performed in most cases. Replacement with a vein graft is the most recommended and preferred method<sup>4, 7</sup>. Removal of the cyst and artery should decrease the risk of recurrence in remnant mesenchymal cells. However, it should be noted that case reports on recurrence showed that new cyst developed from the vein graft<sup>8, 9</sup>. In contrast, the study supporting the synovial theory insists

that resection is the most recommended surgery<sup>3</sup>. This study showed that CAD did not reoccur when the pathway between the knee joint capsule and CAD was blocked<sup>3</sup>. The medial genicular artery serves as a conduit for the joint fluid to pass from the synovial membrane of the knee to the popliteal artery, and MRI is the best examination to show the chain of cysts<sup>3</sup>. In our case, we cut and ligated the medial genicular artery. Small cysts toward the knee joint disappeared, especially around the medial genicular artery. The content of the chained cysts was possibly drained out when the medial genicular artery was exposed. There are no small cysts even after 6 months postoperatively.

Our hospital is located in the rural area, and our patient works in the rice field. He drives a combine and bends the knee to check the combine before driving. Restriction in curvature movement of the knee joint would have restricted his work. He previously visited our hospital due to cutting injury during work in the farm. If we had selected replacement with vein graft, antiplatelet therapy would be required, which might have caused a more serious bleeding injury. The advantage of the incision technique is that the endothelium can be preserved. Our patient did not require antiplatelet therapy and limitation of knee joint movement. Hence, we believe that incision of the cyst is the best option when atheromatous lesion is ruled out, especially in young and active patients.

## References

1. Desy NM, Spinner RJ. The etiology and management of cystic adventitial disease. *J Vasc Surg* 2014; 60: 235–245, 245.e1–245.e11. [Medline] [CrossRef]
2. Jarraya M, Simmons S, Farber A, et al. Uncommon diseases of the popliteal artery: a pictorial review. *Insights Imaging* 2016; 7: 679–688. [Medline] [CrossRef]
3. Spinner RJ, Desy NM, Agarwal G, et al. Evidence to support that adventitial cysts, analogous to intraneural ganglion cysts, are also joint-connected. *Clin Anat* 2013; 26: 267–281. [Medline] [CrossRef]
4. Li S, King BN, Velasco N, et al. Cystic adventitial disease—case series and review of literature. *Ann Transl Med* 2017; 5: 327. [Medline] [CrossRef]
5. Rosiak G, Milczarek K, Cieszanowski A, et al. Ultrasound-guided percutaneous aspiration of adventitial cysts in the occluded popliteal artery—clinical results and MR findings at 5-year follow-up. *J Ultrason* 2017; 17: 212–216. [Medline] [CrossRef]
6. Seo H, Fujii H, Aoyama T, et al. A case of adventitial cystic disease of the popliteal artery progressing rapidly after percutaneous ultrasound-guided aspiration. *Ann Vasc Dis* 2014; 7: 417–420. [Medline] [CrossRef]
7. Motaganahalli RL, Smeds MR, Harlander-Locke MP, et al. Vascular Low-Frequency Disease Consortium A multi-institutional experience in adventitial cystic disease. *J Vasc Surg* 2017; 65: 157–161. [Medline] [CrossRef]
8. Flessenkaemper I, Müller KM. Early recurrence of cystic adventitial disease in a vein graft after complete resection of the popliteal artery. *Vasa* 2014; 43: 69–72. [Medline] [CrossRef]
9. Bendix S, Nasra K, Banipal S, et al. Recurrent cystic adventitial disease of the popliteal artery: case report and review of the literature. *J Vasc Surg* 2017; 65: 110S–111S. [CrossRef]