

Preoperative Prediction of Metastatic Lymph Nodes Posterior to the Right Recurrent Laryngeal Nerve in cN0 Papillary Thyroid Carcinoma

Jun Shao¹, Xiya Wang¹, Haiyuan Yu¹, Wei Ding¹, Bin Xu¹, Dongsheng Ma¹, Xuechun Huang², Hongqing Yin¹

¹Department of Medical Ultrasound, Affiliated Kunshan Hospital of Jiangsu University, Kunshan, 215300, People's Republic of China; ²Department of Medical Ultrasound, Affiliated Changzhou No. 2 People's Hospital of Nanjing Medical University, Changzhou, 213000, People's Republic of China

Correspondence: Xuechun Huang; Hongqing Yin, Email ylgc20162022@163.com; sjwwy163@163.com

Background: The advantages of the dissecting the metastatic lymph nodes posterior to the right recurrent laryngeal nerve (LN-prRLN) remain a great deal of controversies in papillary thyroid carcinoma (PTC) patients without clinical evidence. The purpose of our retrospective research was to investigate the predictive factors of the LN-prRLN in cN0 PTC patients.

Methods and Materials: Altogether 251 consecutive cN0 PTC participants accepted unilateral or bilateral thyroidectomy accompanied with LN-prRLN dissection between June 2020 and May 2023 were included in the research. Then, univariate and multivariate logical regression analysis were conducted to analyze the relationship between the LN-prRLN and these predictive factors, and a predictive model was also developed. Surgical complications of LN-prRLN dissection were also presented.

Results: The rate of LN-prRLN was 17.9% (45/251) in cN0 PTC patients after the analysis of postoperative histology. The age <55 years, multifocality, microcalcification, and BRAF^{V600E} mutation were identified to be predictive factors of LN-prRLN in cN0 PTC patients. The risk score for LN-prRLN was calculated: risk score = 1.192 × (if age <55 years) + 0.808 × (if multifocality) + 1.196 × (if microcalcification in nodule) + 0.918 × (if BRAF^{V600E} mutation in nodule). The rates of the transient hypoparathyroidism and hoarseness were 1.2% (3/251) and 2.0% (5/251), respectively.

Conclusion: The age <55 years, multifocality, microcalcification, and BRAF^{V600E} mutation are independent predictors of the LN-prRLN in cN0 PTC patients. An effective predictive model was established for predicting the LN-prRLN in cN0 PTC patients, with the aim to better guide the surgical treatment of PTC. A thorough inspection of the lateral compartment is recommended in PTC patients with risk factors. The multicenter research with long-term follow-up should be carried out to ascertain the optimal surgical approach for patients with PTC.

Keywords: papillary thyroid carcinoma, ultrasound, BRAF^{V600E} mutation, lymph nodes posterior to the right recurrent laryngeal nerve, predictive model

Introduction

The thyroid gland, made up of two joint lobes, weighs 20 to 30 grams in human, which is one of the largest endocrine glands in the body. Thyroid lesions are common in the thyroid gland and the prevalence ranges from 4% to 7%. Most these patients are asymptomatic and have normal thyroid hormone secretion.¹ Papillary thyroid carcinoma (PTC) is the most common subtype of all thyroid carcinomas with the increasing incidence worldwide, which counts for more than 85% of thyroid malignant tumors.² Despite most PTC patients have a satisfactory prognosis with 5-year survival rate of more than 90% after the suitable treatments, 20–80% patients suffer from metastatic cervical lymph nodes (LNs), particularly the central compartment lymph nodes, which contributes to an increased locoregional recurrence and distant metastasis.^{3,4} Central compartment LNs are separated into four groups of pretracheal LNs, prelaryngeal LNs, left paratracheal LNs and right paratracheal LNs.⁵ Moreover, right paratracheal LNs are further divided into anterior part (LN-arRLN) and posterior part (LN-prRLN) according to the anatomical variations.^{6,7}

Therapeutic central lymph node dissection (CLND) was recommended by the American Thyroid Association (ATA) guidelines, when the metastasis lymph nodes were found in the preoperative imaging examination.⁸ However, there is

great deal of controversies about whether prophylactic CLND should be performed in cN0 PTC patients, especially about the LN-prRLN resection. On the one hand, there is accumulating evidence indicates that approximately 26.6% of cN0 PTC patients accompany with LN-prRLN metastases, and prophylactic dissection can effectively reduce the recurrent and distant metastasis, thereby avoiding the risk of secondary operation.⁹ On the other hand, LN-prRLN dissection could increase the potential possibility of hoarseness and hypoparathyroidism, affecting the life quality of these patients.^{10,11} Individualized surgical decisions on LN-prRLN dissection based on the characteristics of PTC patients maybe a convincing approach to effectively avoid the over- or under- therapy.

High-resolution ultrasonography (US) is primary imaging method recommended for the diagnosis of malignant PTC, which provides clinicians useful information to for the selection of surgical methods.^{12,13} However, it is difficult for US to identify the LN-prRLNs because they are located at the deep position and surrounded by the trachea, esophagus, and cervical vertebrae.¹⁴ In addition, B-type Raf (BRAF) kinase mutation on exon 15 is closely related to the protein kinase pathway, which plays a critical part in tumorigenesis, proliferation, and metastasis of PTC,^{15,16} but there is few similar research conducted in the vegetation of the LN-prRLN metastasis.

In our current research, we retrospectively analyzed 251 PTC participants who accepted unilateral or bilateral thyroidectomy accompanied with prophylactic dissection of the LN-prRLN. The association between LN-prRLN and ultrasonic and clinicopathologic characterizes in cN0 PTC patients was investigated through the univariate and multivariate logical regression analysis. The aim of current study was to identify the predictive factors of LN-prRLN in cN0 PTC, which is expected to improve the preoperative estimation of LN-prRLN metastasis for guiding the appropriate therapeutic management.

Patients and Materials

The present study design followed the international regulations based on the Declaration of Helsinki and approved by the Ethical Committee of the Affiliated Kunshan Hospital of Jiangsu University (2021-03-023-K01). The need for informed consent from the patients was waived for its retrospective nature, and the information of enrolled patients was strictly confidential.

Participant Selection

Altogether 251 consecutive PTC patients accepted unilateral or bilateral thyroidectomy accompanied with prophylactic LN-prRLN dissection were reviewed retrospectively between June 2020 and May 2023 at the Affiliated Kunshan Hospital of Jiangsu University. The inclusion criteria were as follows: (1) the age of participants >18 years old, (2) the PTC confirmed by postoperative pathology, (3) the cN0 neck status confirmed by preoperative imaging examination. The exclusion criteria were as follows: (1) the history of thyroid surgery and radiation, (2) insufficient US and incomplete clinical information, (3) postoperative pathology identified as other types of thyroid carcinoma. The largest or the most suspicious PTC was selected into our study when participant has multiple malignant PTCs.

US Evaluation

Every participant was placed in the supine position with a fully exposed neck before the US examination. MyLabTwice (Esaote, Italy) with a probe frequency of 7 to 13 MHz was used for thyroid scanning. The US examination was operated by the radiologists with more than 5 years of experience in thyroid diagnosis, and the images of targeted PTC were captured by longitudinally and transversely on two-dimensional gray-scale modality. These US images were analyzed by two senior radiologists with more than 5 years of working experience. The disagreements of nodule were then re-estimated by another experienced radiologist with more than 20 years of working experience. These US features of PTC were recorded and analyzed: maximum size on US (>10 mm/ ≤ 10mm), multifocality (absent/present), solid component (absent/present), hypo-echogenicity (absent/present), microcalcification (absent/present), margin (ill-defined/well-defined), shape (irregular/regular), and taller-than-wide shape (absent/present). The multifocality was defined as two or more PTCs. The microcalcification in PTC was defined as calcifications less than 1.0 mm in diameter.

Surgical Proposal

The scope of thyroid operation was conducted according to the guidelines.^{17,18} Unilateral or bilateral thyroidectomy was conducted at the same time as unilateral or bilateral CLND (including LN-prRLN dissection). The postoperative specimens of the central LNs were often divided into five subgroups: pretracheal LN, prelaryngeal LN, left paratracheal LN, LN-arRLN, and LN-prRLN, which were further sent for pathological analysis separately.

BRAF Analysis

The samples required from preoperative fine-needle aspiration of targeted PTC were stored in preservation solution, which was then submitted to a genetic detection company for BRAF mutation analysis.

Statistical Analysis

All the statistical analysis were conducted by the SPSS software (ver. 25.0; SPSS Inc., Chicago, IL, USA). The comparison was analyzed by Student's *t*-test for continuous variables and Pearson χ^2 or Fisher's exact test for categorical variables, respectively. The multivariate logistic analysis was carried out to determine the risk predictors of the LN-prRLN. The receiver operating characteristic (ROC) curves were established to analyze the reliability of the predictive model. P value of less than 0.05 was considered as significant.

Result

Baseline Data of PTC Participants

A total of 251 cN0 PTC participants were finally enrolled into our further study after the strict screening. The rate of LN-prRLN metastasis was happened in 45 (17.9%) PTC patients, and no LN-prRLN metastasis was found in other patients. Among the PTC patients, 69 (27.5%) PTC patients were male, and 182 (72.5%) patients were female. There are 163 (64.9%) participants were less than 55 years old, and 88 (35.1%) were 55 years and older. In addition, 131 (52.2%) PTC patients have bilaterality PTC, whereas 120 (47.8%) patients did not. The maximum diameter of PTC was ≤ 10 mm was found in 96 (38.2%) PTC participants, and the PTC size larger than 10 mm was detected in 155 (61.8%) patients. Moreover, multifocality was found in 67 (26.7%) participants. Malignant US features, such as solid component, hypo-echogenicity, microcalcification, irregular shape, ill-defined margin and taller than wide shape were exhibited in 247 (98.4%), 213 (84.9%), 104 (41.4%), 130 (51.8%), 141 (56.2%), and 73 (29.1%) of PTC participants, respectively. Furthermore, 60 (23.9%) and 18 (7.2%) PTC participants were concomitant Hashimoto's thyroiditis and extrathyroidal extension (ETE), respectively. Typically, BRAF^{V600E} mutation from FNA cytologic specimen was found in 158 (62.9%) PTC participants. The demographic, ultrasonic, and clinicopathological features of included patients were summarized in [Table 1](#).

Table 1 Comparison of the Clinicopathologic and US Features Between the Absence and Presence of LN-prRLN Metastasis in cN0 PTC Patients

Characteristics	LN-prRLN Metastasis (N=251)		P value
	Positive (N=45)	Negative (N=206)	
Age			P=0.002*
<55 years	38 (84.4%)	125 (60.7%)	
≥ 55 years	7 (15.6%)	81 (39.3%)	
Gender			P=0.817
Male	13 (28.9%)	56 (27.2%)	
Female	32 (71.1%)	150 (72.8%)	
Tumor size			P=0.216
≤ 10 mm	9.93 \pm 3.35 mm 21 (46.7%)	10.60 \pm 2.70 mm 75 (36.4%)	P=0.200
>10 mm	24 (53.3%)	131 (63.6%)	

(Continued)

Table 1 (Continued).

Characteristics	LN-prRLN Metastasis (N=251)		P value
	Positive (N=45)	Negative (N=206)	
Multifocality			P<0.001*
Multifocal	23 (51.1%)	44 (21.4%)	
Unifocal	22 (48.9%)	162 (78.6%)	
Bilaterality			P=0.624
Absent	23 (51.1%)	97 (47.1%)	
Present	22 (48.9%)	109 (52.9%)	
Internal component			P=0.549
Solid	44 (97.8%)	203 (98.5%)	
Cystic	1 (2.2%)	3 (1.5%)	
Hypo-echogenicity			P=0.586
Present	37 (82.2%)	176 (85.4%)	
Absent	8 (17.8%)	30 (14.6%)	
Microcalcification			P<0.001*
Present	32 (71.1%)	72 (35.0%)	
Absent	13 (28.9%)	134 (65.0%)	
Shape			P=0.667
Irregular	22 (48.9%)	108 (52.4%)	
Regular	23 (51.1%)	98 (47.6%)	
Margin			P=0.117
Ill-defined	30 (66.7%)	111 (53.9%)	
Defined	15 (33.3%)	95 (46.1%)	
Taller than wide			P=0.694
Present	12 (26.7%)	61 (29.6%)	
Absent	33 (73.3%)	145 (70.4%)	
Hashimoto's thyroiditis			P=0.925
Concomitant	11 (24.4%)	49 (23.8%)	
Non-concomitant	34 (75.6%)	157 (76.2%)	
Extrathyroidal extension			P=0.622
Present	4 (8.9%)	14 (6.8%)	
Absent	41 (91.1%)	192 (93.2%)	
BRAF mutation			P=0.001*
Positive	38 (84.4%)	120 (58.3%)	
Negative	7 (15.6%)	86 (41.7%)	

Note: *Statistically significant.

Abbreviations: N, number of thyroid nodules; LN-prRLN, lymph nodes posterior to the right recurrent laryngeal nerve.

Univariate Analysis

As the vividly exhibited in Table 1, PTC patients <55 years of age demonstrated a higher incidence of the LN-prRLN metastasis than those 55 years or older (84.4% vs 61.2%, $P = 0.002$). Multifocality was more likely to display the LN-prRLN metastasis positive in these cN0 PTC patients ($P < 0.001$). Moreover, the US feature of microcalcification ($P < 0.001$) was significantly associated with the LN-prRLN metastasis in PTC participants. Other malignant US features, including solid component, hypo-echogenicity, irregular shape, ill-defined margin, and taller than wide shape were not obviously associated with the LN-prRLN metastasis in patients with PTC ($P = 0.549, 0.586, 0.667, 0.117, \text{ and } 0.694$, respectively). BRAF^{V600E} mutation from US-FNA specimen was also inclined to appear the LN-prRLN metastasis ($P = 0.001$). Furthermore, concomitant Hashimoto's thyroiditis and ETE were not more likely to show the metastatic LN-prRLNs in cN0 PTC patients ($P = 0.925 \text{ and } 0.622$).

Table 2 Multivariate Logistic Regression Analysis in Predicting the LN-prRLN Metastasis in cN0 PTC Patients

PTC Characteristics	β Coefficient	Odds Ratio	95% CI	P value
Age < 55 years	1.192	3.295	1.340–8.102	0.009*
Multifocality	0.808	2.243	1.042–4.828	0.039*
Microcalcification	1.196	3.308	1.539–7.112	0.002*
BRAF mutation	0.918	2.505	1.009–6.220	0.048*

Note: *Statistically significant.

Abbreviations: LN-prRLN, lymph nodes posterior to the right recurrent laryngeal nerve; PTC, papillary thyroid carcinoma; CI, confidence interval.

Multivariate Analysis

In addition, independent predictors were identified after the multivariate logical analysis. In the present research, these independent factors, such as age <55 years old (OR = 3.295, P = 0.009), multifocality (OR = 2.243, P = 0.039), microcalcification (OR = 3.308, P = 0.002), and BRAF^{V600E} mutation (OR = 2.505, P = 0.048) were determined to be risk predictors of the LN-prRLN metastasis in cN0 PTC participants (Table 2, Figure 1). Furthermore, the ROC curve was also established, and the diagnostic value of these independent factors was discriminative with areas under the curves of 0.619 (95% CI: 0.535–0.703), 0.649 (95% CI: 0.555–0.743), 0.681 (95% CI: 0.595–0.766), and 0.631 (95% CI: 0.548–0.714), respectively. Moreover, their sensitivity and specificity were 84.4% and 39.3%, 51.1% and 78.6%, 71.1% and 65.0%, and 84.4% and 41.7%, respectively (Table 3, Figure 2a). The multivariate regression equation was performed with above risk factors: $P = 1/1 + \exp\{-3.981 + 1.192 \times (\text{if age } <55 \text{ years old}) + 0.808 \times (\text{if multifocality nodule}) + 1.196 \times (\text{if microcalcification in nodule}) + 0.918 \times (\text{if BRAF mutation in nodule})\}$ (Figure 2b). The predictive model demonstrated a satisfactory predictability of LN-prRLN metastasis (AUC = 0.780, 95% CI 0.712–0.848) with the sensitivity and specificity were 62.2% and 78.6%, respectively.

Surgical Complications

There is no permanent right RLN injury or permanent hypoparathyroidism happened in our research. The rates of transient hypoparathyroidism and hoarseness were 1.2% (3/251) and 2.0% (5/251), respectively.

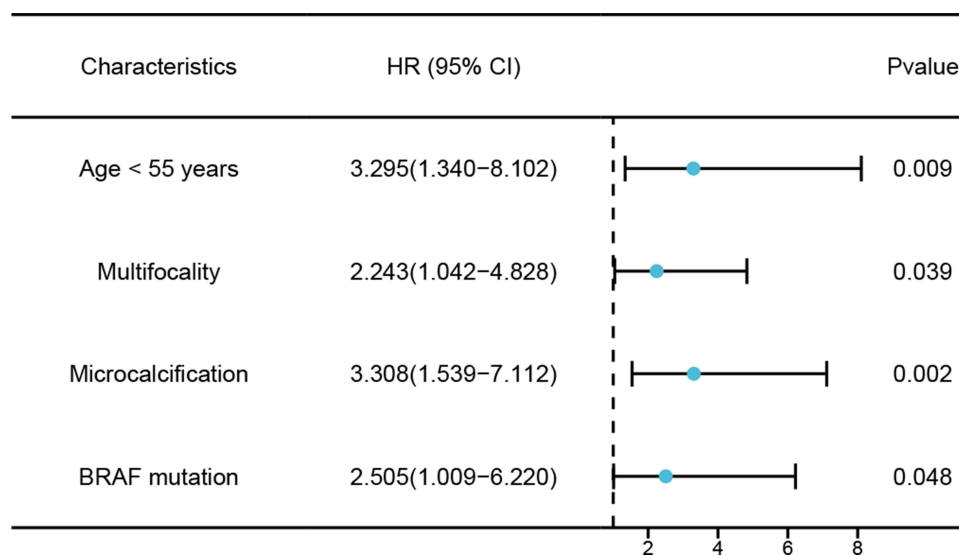


Figure 1 Forest plot of the independent predictors of the LN-prRLN metastasis in cN0 PTC patients.

Abbreviation: LN-prRLN, lymph nodes posterior to the right recurrent laryngeal nerve.

Table 3 ROC Analysis of the Independent Factors and Equation for the LN-prRLN Metastasis in cN0 PTC Patients

	Az	95% CI	Cutoff Value	Sensitivity	Specificity
Overall (N=251)					
Age < 55 years	0.619	0.535–0.703	Age < 55 years	0.844	0.393
Multifocality	0.649	0.555–0.743	Multifocality	0.511	0.786
Microcalcification	0.681	0.595–0.766	Microcalcification	0.711	0.650
BRAF mutation	0.631	0.548–0.714	BRAF mutation	0.844	0.417
Predictive equation	0.780	0.712–0.848	0.213	0.622	0.786

Abbreviations: LN-prRLN, lymph nodes posterior to the right recurrent laryngeal nerve; N, number of thyroid nodules; CI, confidence interval.

Discussion

US-guided fine needle aspiration (FNA) was often conducted to evaluate the malignant risk of PTC. According to the Bethesda system, the results of a cytological biopsy can be divided into the following six categories: I (non-diagnostic or unsatisfactory), II (benign), III (atypia of undetermined significance [AUS] or follicular lesion of undetermined significance [FUS]), IV (follicular neoplasm or suspicious for a follicular neoplasm), V (suspicious for malignancy), and VI (malignant).^{19,20}

PTC is one of the indolent malignancies with a favorable clinical prognosis, as a result, the 5-year survival rate is more than approximately 95% after the appropriate diagnosis and therapy.^{21,22} However, some PTC patients may occur the metastasis and recurrence, which are closely related to the metastatic cervical lymph nodes, especially central compartment lymph nodes.²³ Total thyroidectomy (TT) and subtotal thyroidectomy (STT) are the two mainstream surgical methods. One previous reported that TT could be safely performed in PTC patients without increasing risk of early complication.²⁴ Harmonic scalpel (HS) was performed in the thyroidectomy, which is more effective at achieving haemostasis.²⁵ There is a great deal of controversies about the routine dissection of the LN-prRLN in participants with PTC, especially in those without clinical lymph nodes.²⁶ Some point out that the dissection of LN-prRLN might destroy the parathyroid gland and right recurrent laryngeal nerve, while the others insist dissecting the LN-prRLN may reduce the possibility of recurrence and metastasis, avoiding the secondary surgery.³ The purpose of present investigation

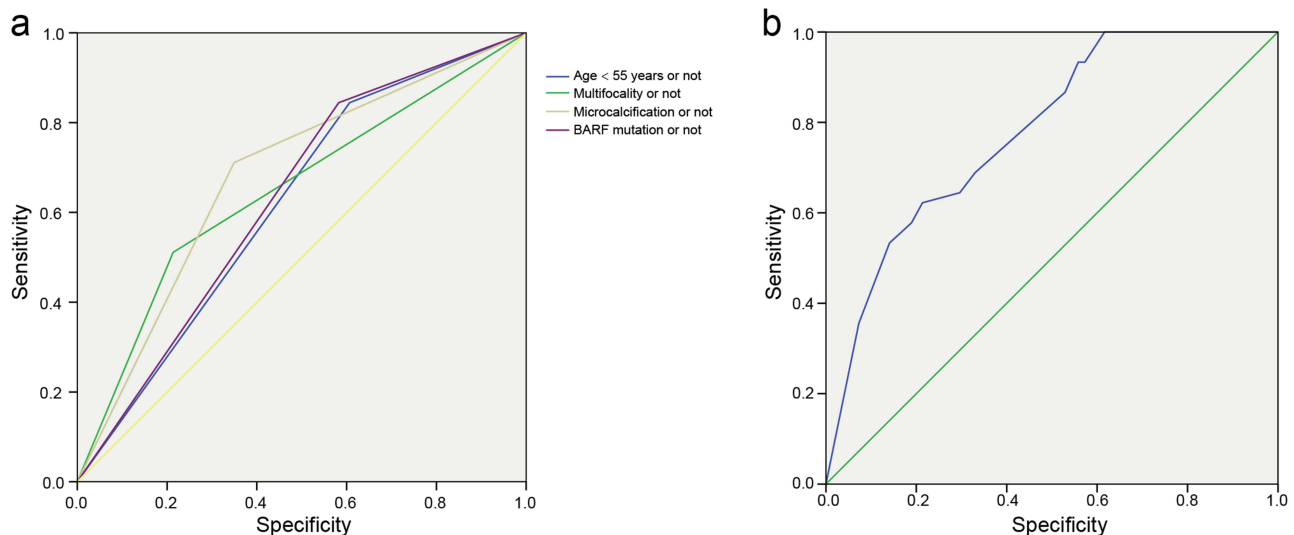


Figure 2 Receiver operating characteristic (ROC) curves of (a) age < 55 years old (area under the ROC curve [AUROC] = 0.619), multifocality (AUROC = 0.649), microcalcification (AUROC = 0.638), and BRAF^{V600E} mutation (AUROC = 0.631), respectively. (b) Equation (AUROC = 0.780) for the prediction of the LN-prRLN metastasis.

Abbreviation: LN-prRLN, lymph nodes posterior to the right recurrent laryngeal nerve.

was to investigate predictive factors of LN-prRLN and develop a prediction model in cN0 PTC patients, which is expected to provide the evidence for adequate and accurate management before the primary surgery.

The metastatic incidence of the LN-prRLN in cN0 PTC patients was 17.9% (45/251) in the present research, which was in the range between 9.36% and 31.60%.¹⁴ Thus, the LN-prRLN metastasis should not be ignored in cN0 PTC participants. The applicable management of LN-prRLN is a crucial part during the surgical operation for PTC patients. Age is a crucial variate in prognosis for patients with well-differentiated thyroid diseases. The age of 55 years was accustomed to being the cut-off value in staging based on the latest AJCC guideline.²⁷ The younger age was largely related to a higher odds ratio of the LN-prRLN in our study. Age <55 years was a predictive factor of the LN-prRLN, suggesting the LN-prRLN should be paid more attention in the younger PTC patients. Microcalcification is usually the deposition of calcium salts and the proliferation of vascular and fibrous tissue.²⁸ The microcalcification on US is typical suspicious feature of PTC, which was reported to be positively related to the invasiveness and metastasis of PTC.²⁹ Hence, cervical lymph nodes, especially LN-prRLNs, should be examined more patiently and cautiously when the microcalcification feature is found in primary PTC tissue. Multifocality is not only associated with the presence of LN-prRLN but also related to the patients' prognosis.³⁰ One meta-analysis suggested multifocality increased the risk of the PTC development and proliferation and was also a critical predictor for the metastasis and recurrence of PTC.³¹

Moreover, ultrasound-guided fine-needle aspiration biopsy (US-FNAB) is widely performed to enhance the diagnostic accuracy by cytologic and genomic detection.⁸ BRAF^{V600E} mutation-related gene alterations, such as tumor-promoting gene overexpression, tumor suppressor gene silence, and thyroid iodide-handling genes down-regulation, participate in a fundamental part in the proliferation, development, and invasiveness of PTC, which was associated with the increased probability of poor prognosis, PTC recurrence and even PTC-related mortality.^{32,33} As the our previous finding, BRAF^{V600E} mutation was more likely to display the metastatic CLNM in cN0 PTC patients.⁸ In this investigation, BRAF^{V600E} mutation from preoperative FNA was determined as a strong risk factor for the LN-prRLN metastasis after the multivariate analysis.

Last but not the least, the safety of LN-prRLN dissection is always a matter of concern. As reported by Pinyi et al, the rate of hypoparathyroidism and transient recurrent laryngeal nerve injury after the LN-prRLN dissection was around 1.7% and 1.0%, respectively, and both of which can fully recover after the follow-up.³⁴ The resemble findings of LN-prRLN dissection safety were also uncovered by the professor Yu et al and Lee et al^{35,36} Above results indicated the LN-prRLN dissection is safe approach if the operator conducted the dissection more meticulously and patiently.

Limitation

It is undeniable that there remained some drawbacks in the present research. First, our research was a retrospective investigation, so the intrinsic selection bias was inevitable. Second, the sample size of our research was relatively small, thus the results may not be applicable to general PTC population. Last, the long-term follow-up was not carried up in the research. Hence, the large sample size, prospective and multicenter research are warranted to investigate the risk factors of the LN-prRLN in cN0 PTC patients in our future research.

Conclusion

The age <55 years, multifocality, microcalcification, and BRAF^{V600E} mutations are identified to be independent predictors for the LN-prRLN in cN0 PTC patients, which is expected to provide the basis for adequate and accurate management before the primary surgery.

Data Sharing Statement

All data generated or analyzed during this study are included in this published article.

Ethics Approval and Consent to Participate

The present study design followed the international regulations based on the Declaration of Helsinki and approved by the Ethical Committee of the Affiliated Kunshan Hospital of Jiangsu University (2021-03-023-K01). The need for informed consent from the patients was waived for its retrospective nature, and the information of enrolled patients was strictly confidential.

Acknowledgments

We are indebted to all the teams and patients who participated in this trial and made it possible.

Author Contributions

All authors made a significant contribution to the work reported, whether that is in the conception, study design, execution, acquisition of data, analysis and interpretation, or in all these areas; took part in drafting, revising or critically reviewing the article; gave final approval of the version to be published; have agreed on the journal to which the article has been submitted; and agree to be accountable for all aspects of the work.

Funding

We greatly acknowledged the social development science and technology plan project of Kunshan City (KSF2021131), and the clinical medical science and technology development fund project of Jiangsu University (JLY2021067).

Disclosure

The authors declare that they have no competing interests.

References

- Mulita F, Anjum F. *Thyroid Adenoma*. Treasure Island (FL): StatPearls Publishing; 2020.
- Parad M, Fararouei M, Mirahmadizadeh A, Afrashteh S. Thyroid cancer and its associated factors: a population-based case-control study. *Int J Cancer*. 2021;149(3):514–521. doi:10.1002/ijc.33537
- Qi G, Feng J, Wu W, et al. Prediction model of lymph node metastasis posterior to the right recurrent laryngeal nerve. *Europ Archiv Oto-Rhino-Laryngol*. 2023;280(7):3429–3435. doi:10.1007/s00405-023-07946-6
- Zou M, Wang Y, Dong Y, Lai X, Li J. Clinical and sonographic features for the preoperative prediction of lymph nodes posterior to the right recurrent laryngeal nerve metastasis in patients with papillary thyroid carcinoma. *J Endocrinol Invest*. 2020;43(10):1511–1517. doi:10.1007/s40618-020-01238-0
- Gong Y, Zuo Z, Tang K, et al. Multimodal predictive factors of metastasis in lymph nodes posterior to the right recurrent laryngeal nerve in papillary thyroid carcinoma. *Front Endocrinol*. 2023;14:1187825. doi:10.3389/fendo.2023.1187825
- Zhou M, Duan Y, Ye B, et al. Pattern and predictive factors of metastasis in lymph nodes posterior to the right recurrent laryngeal nerve in papillary thyroid carcinoma. *Front Endocrinol*. 2022;13:914946. doi:10.3389/fendo.2022.914946
- Lallemant B, Reynaud C, Aloviseti C, et al. Updated definition of level VI lymph node classification in the neck. *Acta oto-laryngologica*. 2007;127(3):318–322. doi:10.1080/00016480600806299
- Chen B, Zhang Z, Wang K, et al. A multivariable model of BRAF and ultrasonographic features for predicting the risk of central lymph node metastasis in cN0 papillary thyroid microcarcinoma. *Cancer Manage Res*. 2019;11:7211–7217. doi:10.2147/cmar.s199921
- Du W, Fang Q, Zhang X, Dai L. Metastasis of cN0 papillary thyroid carcinoma of the isthmus to the lymph node posterior to the right recurrent laryngeal nerve. *Front Endocrinol*. 2021;12:677986. doi:10.3389/fendo.2021.677986
- Ito Y, Fukushima M, Higashiyama T, et al. Incidence and predictors of right paraesophageal lymph node metastasis of N0 papillary thyroid carcinoma located in the right lobe. *Endocr J*. 2013;60(3):389–392. doi:10.1507/endocrj.ej12-0362
- Li J, He G, Tong Y, et al. A novel scoring system for the risk of papillary thyroid cancer metastases in lymph nodes posterior to the right of the recurrent laryngeal nerve. *Endocr Pract*. 2021;27(1):15–20. doi:10.4158/ep-2020-0129
- Gharib H, Papini E, Paschke R, et al. American Association of Clinical Endocrinologists, Associazione Medici Endocrinologi, and European Thyroid Association medical guidelines for clinical practice for the diagnosis and management of thyroid nodules: executive summary of recommendations. *J Endocrinol Invest*. 2010;33(5):287–291. doi:10.1007/bf03346587
- Kwak J, Han K, Yoon J, et al. Thyroid imaging reporting and data system for US features of nodules: a step in establishing better stratification of cancer risk. *Radiology*. 2011;260(3):892–899. doi:10.1148/radiol.11110206
- Lu K, Zhang Y, Da J, et al. A novel scoring system for predicting the metastases of posterior right recurrent laryngeal nerve lymph node involvement in patients with papillary thyroid carcinoma by preoperative ultrasound. *Front Endocrinol*. 2021;12:738138. doi:10.3389/fendo.2021.738138
- Zhang Z, Zhang X, Yin Y, et al. Integrating BRAF mutation, ultrasonic and clinicopathologic characteristics for predicting the risk of cervical central lymph node metastasis in papillary thyroid carcinoma. *BMC Cancer*. 2022;22(1):461. doi:10.1186/s12885-022-09550-z
- Chen B, Zhang Z, Wang K, et al. Association of BRAFV600E mutation with ultrasonographic features and clinicopathologic characteristics of papillary thyroid microcarcinoma: a retrospective study of 116 cases. *Clin Hemorheol Microcirc*. 2019;73(4):545–552. doi:10.3233/ch-190568
- Gao M, Ge M, Ji Q, et al. 2016 Chinese expert consensus and guidelines for the diagnosis and treatment of papillary thyroid microcarcinoma. *Cancer Biol Med*. 2017;14(3):203–211. doi:10.20892/j.issn.2095-3941.2017.0051
- Haugen B, Alexander E, Bible K, et al. 2015 American Thyroid Association Management guidelines for adult patients with thyroid nodules and differentiated thyroid cancer: the American Thyroid Association Guidelines task force on thyroid nodules and differentiated thyroid cancer. *Thyroid*. 2016;26(1):1–133. doi:10.1089/thy.2015.0020
- Mulita F, Plachouri M, Liolis E, Vailas M, Panagopoulos K, Maroulis I. Patient outcomes following surgical management of thyroid nodules classified as Bethesda category III (AUS/FLUS). *Endokrynologia Polska*. 2021;72(2):143–144. doi:10.5603/EP.a2021.0018
- Mulita F, Iliopoulos F, Tsilivigkos C, et al. Cancer rate of Bethesda category II thyroid nodules. *Medicinski glasnik*. 2022;19(1). doi:10.17392/1413-21

21. Zhang Z, Zhao S, Wang K, et al. Identification of biomarkers associated with cervical lymph node metastasis in papillary thyroid carcinoma: evidence from an integrated bioinformatic analysis. *Clin Hemorheol Microcirc.* 2021;78(2):117–126. doi:10.3233/ch-201074
22. Chen B, Xu H, Zhang Y, et al. The diagnostic performances of conventional strain elastography (SE), acoustic radiation force impulse (ARFI) imaging and point shear-wave speed (pSWS) measurement for non-calcified thyroid nodules. *Clin Hemorheol Microcirc.* 2017;65(3):259–273. doi:10.3233/ch-16178
23. Brown R, de Souza J, Cohen E. Thyroid cancer: burden of illness and management of disease. *J Cancer.* 2011;2:193–199. doi:10.7150/jca.2.193
24. Mulita F, Verras G, Dafnomili V, et al. Thyroidectomy for the management of differentiated thyroid carcinoma and their outcome on early postoperative complications: a 6-year single-centre retrospective study. *Chirurgia.* 2022;117(5):556–562. doi:10.21614/chirurgia.2736
25. Mulita F, Theofanis G, Verras G, et al. Comparison of postoperative bleeding using harmonic scalpel and LigaSure in thyroid surgery: a 15-year single-centre retrospective study. *Medicinski glasnik.* 2023;20(2). doi:10.17392/1629-23
26. Xiao X, Wu Y, Zou L, Chen Y, Zhang C. Value of dissection of lymph nodes posterior to the right recurrent laryngeal nerve in patients with cN papillary thyroid carcinoma. *Gland Surg.* 2022;11(7):1204–1211. doi:10.21037/gS-22-337
27. Lamartina L, Grani G, Arvat E, et al. 8th edition of the AJCC/TNM staging system of thyroid cancer: what to expect (ITCO#2). *Endocrine Related Cancer.* 2018;25(3):L7–L11. doi:10.1530/erc-17-0453
28. Yin L, Zhang W, Bai W, He W. Relationship between morphologic characteristics of ultrasonic calcification in thyroid nodules and thyroid carcinoma. *Ultrasound Med Biol.* 2019;46:1.
29. Li C, Zhou L, Dionigi G, Li F, Zhao Y, Sun H. The association between tumor tissue calcification, obesity, and thyroid cancer invasiveness in a cohort study - scienceDirect. *Endocr Pract.* 2020;26(8):830–839.
30. Zhou T, Wu F, Zhao L, Jiang K, Luo D. A meta-analysis of risk factors for lymph node posterior to the right recurrent laryngeal nerve metastasis in papillary thyroid carcinoma. *Gland Surg.* 2021;2:6.
31. Joseph KR, Edirimanne S, Eslick GD. Multifocality as a prognostic factor in thyroid cancer: a meta-analysis. *Int J Surg.* 2018;3:50.
32. Kim S, Park I, Woo J, et al. Predicting factors for bilaterality in papillary thyroid carcinoma with tumor size <4 cm. *Thyroid.* 2017;27(2):207–214. doi:10.1089/thy.2016.0190
33. Park A, Son E, Kim J, et al. Associations of the BRAF(V600E) mutation with sonographic features and clinicopathologic characteristics in a large population with conventional papillary thyroid carcinoma. *PLoS One.* 2014;9(10):e110868. doi:10.1371/journal.pone.0110868
34. Pinyi Z, Bin Z, Jianlong B, Yao L, Weifeng Z. Risk factors and clinical indication of metastasis to lymph nodes posterior to right recurrent laryngeal nerve in papillary thyroid carcinoma: a single-center study in China. *Head Neck.* 2014;36(9):1335–1342. doi:10.1002/hed.23451
35. Yu Q, Ma D, Liu K, et al. Clinicopathologic risk factors for right paraesophageal lymph node metastasis in patients with papillary thyroid carcinoma. *J Endocrinol Invest.* 2018;41(11):1333–1338. doi:10.1007/s40618-018-0874-4
36. Lee B, Lee J, Wang S, Kim Y, Kim I, Son S. Metastasis of right upper para-esophageal lymph nodes in central compartment lymph node dissection of papillary thyroid cancer. *World J Surg.* 2009;33(10):2094–2098. doi:10.1007/s00268-009-0149-5