

# Late-onset Relapse of Aqueous Misdirection after Pars Plana Vitrectomy: Case Report and Literature Review

Ioannis Halkiadakis<sup>1</sup>, Vasillios Tzimis<sup>2</sup>, Ioannis Markopoulos<sup>3</sup>, Stylianos A Kandarakis<sup>4</sup>, Vasilliki Konstadinidou<sup>5</sup>, Michalis Tzakos<sup>6</sup>

Received on: 02 November 2021; Accepted on: 20 July 2022; Published on: 13 May 2023

## ABSTRACT

**Aim:** We report on an 88-year-old female patient who presented with a relapse in aqueous misdirection 15 years after being treated with pars plana vitrectomy (PPV) with hyaloidotomy-zonulectomy-iridotomy (HZI) for the same cause.

**Case description:** A 73-year-old pseudophakic woman with a history of pseudoexfoliation underwent a trabeculectomy in the left eye in our institution because of uncontrolled intraocular pressure. Days after trabeculectomy, the patient developed aqueous misdirection and was treated with PPV combined with HZI. In the following years, the patient had regular follow-up appointments in our institution, and she had normal intraocular pressures in the left eye without any treatment. A total of 15 years after the vitrectomy, the patient developed gradual swallowing in the anterior chamber and increased intraocular pressure. Neodymium (Nd): yttrium aluminum garnet (YAG) laser hyaloidotomy through the iridectomy opening was performed, the anterior chamber was immediately deepened, and the intraocular pressure was reduced to normal limits. The anterior chamber remained deep, and the intraocular pressure remained normal through the 36 months of follow-up.

**Conclusion:** Relapse of aqueous misdirection may occur many years after vitrectomy, even when HZI is performed. An Nd:YAG-laser hyaloidotomy should be attempted before a second HZI is considered.

**Clinical relevance:** A close and long-lasting follow-up of patients with aqueous misdirection is warranted, especially if the patients are treated not with complete PPV but by a limited disruption of the anterior hyaloid face along with HIZ.

**Keywords:** Aqueous misdirection, Hyaloido-zonula-iridectomy, Malignant glaucoma.

*Journal of Current Glaucoma Practice* (2023): 10.5005/jp-journals-10078-1397

## INTRODUCTION

Aqueous misdirection syndrome (malignant glaucoma) is an uncommon kind of secondary angle closure glaucoma (ACG). It has been most frequently reported after trabeculectomy in eyes with primary ACG but has also been encountered after almost any type of intraocular surgery or laser or even spontaneously.<sup>1,2</sup> The diagnosis is based on the uniform reduction of the depth of the anterior chamber with normal or increased intraocular pressure in an eye with patent iridectomy. It is generally agreed that there is an anatomical predisposition for the syndrome since it is more common in eyes with narrow angles. The term aqueous misdirection describes the mechanism of accumulation of aqueous humor secreted by the ciliary epithelium in the vitreous cavity instead of the anterior chamber. As a result, the lens-iris diaphragm is forced anteriorly, and this leads to diffuse swallowing of the anterior chamber.<sup>3</sup>

In cases of suspected aqueous misdirection, stepwise management is instituted. The interventions aim to disrupt the misdirection and restore normal aqueous flow.

A laser iridotomy, if not present, is performed. Medical treatment includes cycloplegics (for the posterior displacement of iris-lens diaphragm), aqueous suppressants, and hyperosmotic to lessen the aqueous production, diminish the vitreous volume and restore normal anatomy and finally, steroids to treat the inflammatory component and minimize the risk of peripheral anterior synechiae formation. Medical therapy may be an adequate treatment for 50% of eyes.<sup>4</sup> If medical treatment fails, an attempt to disrupt the anterior hyaloid face with neodymium: YAG

<sup>1-3,5,6</sup>Department of Ophthalmology, Ophthalmiatrion Athinon, Athens, Greece

<sup>4</sup>Department of Ophthalmology, School of Medicine, University of Athens, General Hospital of Athens "G.Gennimatas," Athens, Greece

**Corresponding Author:** Ioannis Halkiadakis, Department of Ophthalmology, Ophthalmiatrion Athinon, Athens, Greece, Phone: +306944958013, e-mail: ihalkia@gmail.com

**How to cite this article:** Halkiadakis I, Tzimis V, Markopoulos I, et al. Late-onset Relapse of Aqueous Misdirection after Pars Plana Vitrectomy: Case Report and Literature Review. *J Curr Glaucoma Pract* 2023;17(1):49-51.

**Source of support:** Nil

**Conflict of interest:** None

**Patient consent statement:** The author(s) have obtained written informed consent from the patient's parents/legal guardians for publication of the case report details and related images.

laser through the iridectomy may be useful. Surgical approaches to treating aqueous misdirection are PPV or anterior vitrectomy along with HZI and are used if other modes of treatment fail.<sup>4-6</sup> The aim of these approaches is to create an unobstructed communication between the vitreous cavity and the anterior chamber. It is important to point out that aqueous misdirection may develop or recur after conventional core PPV.<sup>2,7,8</sup> The rate of recurrence varies substantially in different studies. Debrouwere et al. reported a 75% relapse rate after conventional pars plan vitrectomy without HZI and a 66% relapse rate when anterior

vitrectomy and HZI are performed.<sup>4</sup> The most common cause of relapse is the blockade of iridectomy by an inflammatory membrane or vitreous. However, most reported cases have occurred within 1 month of vitrectomy. Herein we present the case of a patient who, 15 years after PPV with HZI, developed a relapse of aqueous misdirection.

## CASE DESCRIPTION

An otherwise healthy 88-year-old female was being followed by us for 15 years. The patient was pseudophakic in both eyes at presentation. At the age of 73, she underwent a trabeculectomy in the left eye in our institution because of uncontrolled intraocular pressure. The patient had pseudoexfoliation in both eyes, herpetic keratitis in the right eye with resultant corneal edema and a full-thickness macular hole in the left eye. Days after the trabeculectomy, she developed aqueous misdirection and was treated with PPV along with HZI. PPV was performed by a standard three-port vitrectomy technique. The vitrectomy had been extended anteriorly to remove anterior hyaloid and lens zonules, and a new iridectomy was performed with the vitrector creating a communication from the posterior to the anterior chamber. In the following years, the patient had normal intraocular pressures without any treatment. The anterior chamber had normal depth (Fig. 1). She had regular follow-up examinations twice a year. A total of 15 years after the vitrectomy, the patient developed gradual shallowing in the anterior chamber and increased intraocular pressure. The anterior chamber was uniformly shallow, and strands that looked like vitreous remnants were egressed from the iridectomy orifice (Figs 2 and 3A). An Nd: Yag- laser hyaloidotomy through the iridectomy opening was performed, the anterior chamber was deepened, and the intraocular pressure was reduced to the normal limits (Fig. 3B). The anterior chamber retained its depth, and the intraocular pressure was normal through 36 months of follow-up.

## DISCUSSION

Pars plana vitrectomy (PPV) is reserved for resistant cases of aqueous misdirection. According to various studies, it is necessary in up to 50% of cases.<sup>4</sup> The aim of PPV is to liberate the aqueous humor which is sequestered in the vitreous cavity and to provide a channel to the anterior chamber. Therefore, disruption of the anterior hyaloid face is mandatory. However, most studies agree that conventional core PPV is followed by a high relapse rate due to the difficulty in the complete removal of the anterior hyaloid and zonular fibers.<sup>9,10</sup> Therefore, in order to create a unicameral eye and facilitate anteroposterior communication, core vitrectomy is not always adequate, and the addition of hyaloid-coleectomy through the iridectomy is mandatory. Malhotra and Ray<sup>11</sup> reported a 58-year-old patient with a relapse of aqueous misdirection 6 weeks after PPV. The patient was treated with anterior zonula irido vitrectomy through preexisting iridectomy. They attributed the relapse of aqueous misdirection to incomplete vitrectomy.

Although this approach (PPV with HZI) effectively establishes anterior-posterior communication, there are several reports where further intervention was necessary because of the blockage of the tunnel by an inflammatory membrane or vitreous. In a series of 69 eyes with refractory malignant glaucoma treated with PPV and HZI, Ali et al.<sup>12</sup> reported recurrence of aqueous misdirection

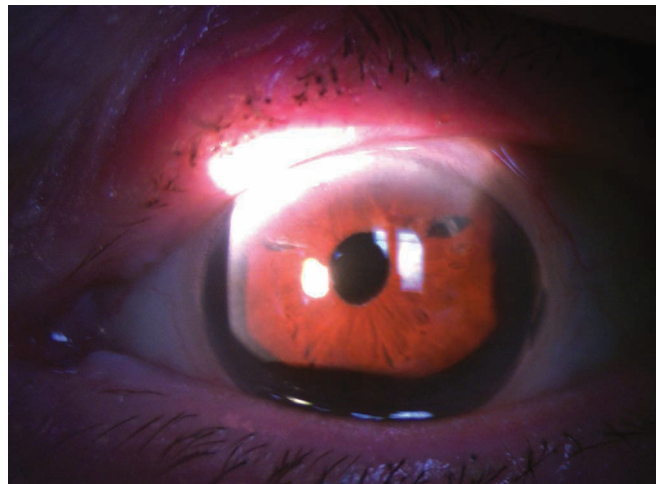
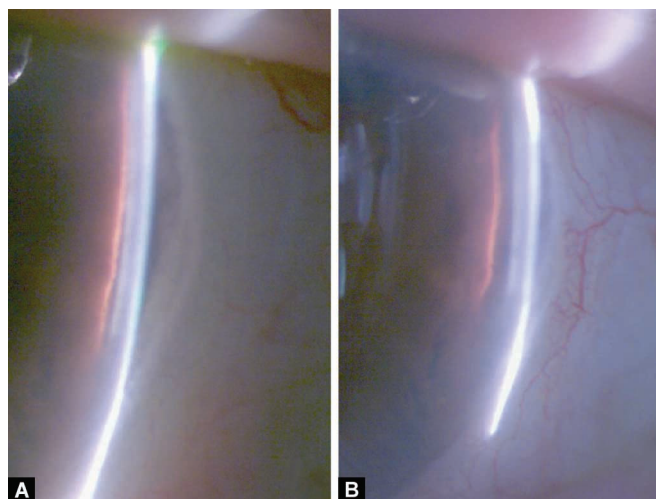


Fig. 1: Slit-lamp photograph showing the anterior chamber of the patient before an attack



Fig. 2: Slit-lamp photograph showing the iridectomy opening during the relapse of the aqueous misdirection. Strands of vitreous obliterate the opening



Figs 3A and B: (A) Slit lamp photograph showing shallowing of the anterior chamber during the relapse of the aqueous misdirection; (B) Slit lamp photograph 10 days post-laser showing deepening of the anterior chamber after laser hyaloidotomy

in 8 eyes (11%) after a mean follow-up period of  $17.6 \pm 3.8$  months (3–156 months). All of the until now described cases, however, occurred within 1 month of the PPV and HZI.

Mardelli et al.<sup>13</sup> described a 73-year-old patient who presented with aqueous misdirection relapse 4 days after a thorough PPV along with HZI. The authors removed the blockage by passing a 30-G needle across the temporal cornea, iris, and anterior capsule into the anterior vitreous cavity at the slit lamp. The authors postulate that blood or vitreous remnants blocked the channel between the anterior chamber and the vitreous, causing aqueous misdirection relapse.

Dave et al.<sup>8</sup> reported early-onset relapse of aqueous misdirection in four patients. The relapse occurred up to 1 month after PPV with HZI and was treated similarly to our case with YAG laser hyaloidomembranectomy through iridectomy. The obstruction of the aqueous flow occurred, according to the authors, either from the intraocular lens or an inflammatory membrane.

Recently, Schmidt et al.<sup>2</sup> reported a 79-year-old Caucasian, pseudophakic woman who presented with aqueous misdirection relapse 7 years after PPV without HZI. A new vitrectomy with HZI was performed, but this was followed by a blockage of the zonula-iridectomy by anterior hyaloid. Thus, a new iridectomy combined with a repeat of the vitrectomy was performed.

The present case report presents a patient who was adequately treated for malignant glaucoma with PPV and HZI 15 years prior to relapse. To our knowledge, a relapse of aqueous misdirection so many years after PPV with or without HZI has not been reported before. We think that vitreous remnants blocked the anterior-posterior communication and caused the relapse. Nd:YAG laser hyaloidotomy was an adequate treatment. The patient did not experience any relapses 3 years after the laser hyaloidotomy despite the fact that no further vitrectomy had been performed.

## CONCLUSION

Aqueous misdirection syndrome (malignant glaucoma) is a sight-threatening complication of intraocular surgery. Our case report indicates that a relapse of the syndrome may occur many years after its management with PPV-HZI. Therefore, a close and long-lasting follow-up of patients with aqueous misdirection is warranted, especially if the patients are treated not with complete PPV but by a limited disruption of the anterior hyaloid face along with HIZ.

## AUTHORSHIP

All authors attest that they meet the current ICMJE criteria for authorship.

## ORCID

Ioannis Halkiadakis  <https://orcid.org/0000-0001-8403-7721>

## REFERENCES

1. European. Glaucoma Society: Terminology and guidelines for glaucoma 5th edition 2020:117–118.
2. Schmidt DC, Kessel L, Pedersen KB, et al. Pars plana vitrectomy combined with hyaloido-zonula-iridectomy in treatment of patients with chronic aqueous misdirection: a systematic literature review and case series. *Acta Ophthalmol* 2021;99(3):251–259. DOI: 10.1111/aos.14580
3. Grzybowski A, Kanclerz P. Acute and chronic fluid misdirection syndrome: pathophysiology and treatment. *Graefes Arch Clin Exp Ophthalmol* 2018;256(1):135–154. DOI: 10.1007/s00417-017-3837-0
4. Debrouwere V, Stalmans P, Van Calster J, et al. Outcomes of different management options for malignant glaucoma: a retrospective study. *Graefes Arch Clin Exp Ophthalmol* 2012;250(1):131–141. DOI: 10.1007/s00417-011-1763-0
5. Raj S, Thattarathody F, Joshi G, et al. Treatment outcomes and efficacy of pars plana vitrectomy-hyaloidotomy-zonulectomy-iridotomy in malignant glaucoma. *Eur J Ophthalmol* 2021;31(1):234–239. DOI: 10.1177/1120672119877139
6. Lynch MG, Brown RH, Michels RG, et al. Surgical vitrectomy for pseudophakic malignant glaucoma. *Am J Ophthalmol* 1986;102(2):149–153. DOI: 10.1016/0002-9394(86)90135-2
7. Massicotte EC, Schuman JS. A malignant glaucoma-like syndrome following pars plana vitrectomy. *Ophthalmology* 1999;106(7):1375–1379. DOI: 10.1016/S0161-6420(99)00727-7
8. Dave P, Rao A, Senthil S, et al. Recurrence of aqueous misdirection following pars plana vitrectomy in pseudophakic eyes. *BMJ Case Rep* 2015;2015: bcr2014207961. DOI: 10.1136/bcr-2014-207961
9. Chaudhry NA, Flynn Jr HW, Murray TG, et al. Pars plana vitrectomy during cataract surgery for prevention of aqueous misdirection in high-risk fellow eyes. *Am J Ophthalmol* 2000;129(3):387–388. DOI: 10.1016/s0002-9394(99)00405-5
10. Bitrian E, Caprioli J. Pars plana anterior vitrectomy, hyaloido-zonulectomy, and iridectomy for aqueous humor misdirection. *Am J Ophthalmol* 2010;150(1):82.e1–87.e1. DOI: 10.1016/j.ajo.2010.02.009
11. Ray VP, Malhotra V. Management of recurrent aqueous misdirection by anterior segment surgeon after failed pars plana posterior vitrectomy. *Indian J Ophthalmol* 2019;67(7):1204–1206. DOI: 10.4103/ijjo.IJO\_1430\_18
12. Al Bin Ali GY, Al-Mahmood AM, Khandekar R, et al. Outcomes of pars plana vitrectomy in the management of refractory aqueous misdirection syndrome. *Retina* 2017;37(10):1916–1922. DOI: 10.1097/IAE.0000000000001430
13. Mardelli PG, Mardelli ME. Slit-lamp needling of the anterior capsule for aqueous misdirection after hyaloido-zonulectomy and iridectomy. *J Glaucoma* 2018;27(4):e77–e79. DOI: 10.1097/IJG.0000000000000877