

Review Article

Open Access

Wolfgang Lederer, Astrid Grams, Raimund Helbok, Martina Stichlberger, Reto Bale, Franz J. Wiedermann*

Standards of anesthesiology practice during neuroradiological interventions

DOI 10.1515/med-2016-0053

received May 7, 2016; accepted June 29, 2016

Abstract: Interventional radiology is a rapidly growing discipline with an expanding variety of indications and techniques in pediatric and adult patients. Accordingly, the number of procedures during which monitoring either under sedation or under general anesthesia is needed is increasing. In order to ensure high-quality care as well as patient comfort and safety, implementation of anesthesiology practice guidelines in line with institutional radiology practice guidelines is paramount [1]. However, practice guidelines are no substitute for lack of communication between specialties.

Interdisciplinary indications within neurosciences call for efficient co-operation among radiology, neurology, neurosurgery, vascular surgery, anesthesiology and intensive care. Anesthesia team and intensive care personnel should be informed early and be involved in coordinated planning so that optimal results can be achieved under minimized risks and pre-arranged complication management.

Keywords: Anesthesia guidelines, Anesthesia management, Interventional neuroradiology, Standard operating procedures

1 Interventional neuroradiology

Interventional neuroradiology offers therapeutic and palliative care for a wide range of diseases of the central nervous system [2]. Optimal treatment results as reflected by low patient morbidity and mortality are bound to interdisciplinary cooperation between neurology, neurosurgery, neuroradiology, anesthesiology and intensive care [3]. A wide range of digital radiological image post-processing modalities can be applied within the frame of neurointerventions. The Picture Archiving and Communication System (PACS) facilitates direct access to the enormous amount of imaging data.

In most neurointerventions, access to the vascular system is gained via the groin. Following local or general anesthesia and a small incision of the skin, a catheter introducer with side port is inserted into the femoral artery using the Seldinger wire technique. Under contrast medium-enhanced angiographic guidance and with the help of a wire, a coaxial guiding catheter is advanced through the larger proximal vessels. For the intervention, microcatheter and microwire are advanced to the target vessel using the guiding catheter. After the procedure the system is removed, in some cases vascular closure systems are applied, and a compression bandage is applied to the insertion region for four to six hours.

2 Vascular occlusive interventions

Vascular occlusive interventions provide minimally invasive treatment alternatives to conventional neurosurgical operations and are the only choice in cases that are surgically inaccessible. Cerebral aneurysm can be treated as scheduled intervention or, in case of emergency, by endovascular coiling with or without stents in order to induce thrombotic occlusion of the aneurysm. Outcome of patients treated with coiling is better than after surgical clipping (Figure 1), but early re-perfusion occurs more frequently [4]. Intravascular administration of glue (n-butyl

***Corresponding author: Franz J. Wiedermann**, Department of Anaesthesiology and Critical Care Medicine, Medical University of Innsbruck, Anichstrasse 35, 6020 Innsbruck, Austria, Tel. +43 512 504 80431, E-Mail: franz.wiedermann@i-med.ac.at

Wolfgang Lederer, Martina Stichlberger, Department of Anaesthesiology and Critical Care Medicine, Medical University of Innsbruck, 6020 Innsbruck, Austria

Astrid Grams, Department of Neuroradiology, Medical University of Innsbruck, 6020 Innsbruck, Austria

Raimund Helbok, Department of Neurology, Medical University of Innsbruck, 6020 Innsbruck, Austria

Reto Bale, Department of Radiology, Medical University of Innsbruck, 6020 Innsbruck, Austria

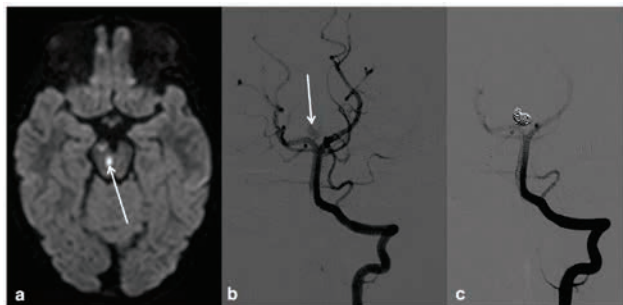


Figure 1: Unusual case of a three year old girl with an incidentally found partially thrombosed intracranial aneurysm. The girl presented with oculomotoric palsies due to small brain stem and mesencephalic (arrow) infarctions found in diffusion weighted MRI (a). Digital subtraction angiography with injection of the left vertebral artery shows the aneurysm of the right proximal posterior cerebral artery (arrow) prior (b) and after (c) endovascular occlusion with platinum coils.

cyanoacrylate), dehydrated alcohol or liquid embolics (Onyx®) into the arterial feeder vessels of arteriovenous malformations or fistulas causes vascular obliteration [5]. Combination with radiation and/or surgery is necessary in some cases. In the case of neoplasms, embolization of supply vessels with particles or coils prior to surgical removal or palliative treatment reduces bleeding complication.

3 Vascular re-operating interventions

Vascular re-opening interventions provide minimally invasive treatment alternatives to operations in vascular surgery and cardiothoracic surgery.

In the case of arterial stenosis, balloon dilatation [6] and subsequent stenting may improve vascular perfusion [7]. In scheduled interventions, patients receive dual platelet aggregation inhibitors for five to seven days and heparin immediately before the intervention [8]. In acute stenting IIb/IIIa receptor blockers can be administered in addition to heparin and rapidly switched to platelet inhibitors during the following days [9]. Thrombolytic drugs more efficiently dissolve thromboembolic clots when applied regionally by means of endovascular catheters [10,11]. For acute stroke therapy, so-called stent retrievers were recently introduced to achieve retraction of intracranial thrombi with a high recanalization rate [12]. Fibrinolytic agents such as plasminogen activators can be additionally injected into the clot or the proximal vessel

[13]. Concurrent antithrombosis with heparin and inhibition of platelet aggregation to counteract re-thrombosis are recommended [14].

4 Thermoablation of Gasserian ganglion for trigeminal neuropathy

Patients suffering from neuropathic pain of the trigeminal nerve resistant to drug therapy may be successfully treated by radiofrequency ablation of the Gasserian ganglion [15]. The patient's head is immobilized by a vacuum dental cast or a molded nosepiece. A native CT scan with skin fiducials is obtained. The pathway of the needle from the skin entrance point to the target in the trigeminal ganglion is planned on the optical 3d navigation system. The electrocoagulation needle is advanced through an aiming device to the target. After confirmation of precise needle positioning by CT and electrophysiological testing electrocoagulation is performed at a temperature of 73 degrees of Celsius for 1 minute. Thermoablation provides a minimally invasive option with lower risks than does the neurosurgical approach using microvascular decompression.

5 Anaesthesia in neurointervention

Special considerations for radiological interventions comprise long-lasting procedures with patient immobility, induced hypertension or controlled hypotension, anticoagulation or reversal of anticoagulation and management of emergencies including raised intracranial pressure and bleeding complications. Furthermore, anesthesia teams have to be used to working in remote locations with jam-packed and minimally illuminated work environment (Figure 2) frequently exposed to radiation [2]. Whereas there is plenty of digital information available concerning the region of treatment, specific patient information regarding liver and kidney function, blood chemistry and clotting system, co-existing diseases and impairments, and current health status may be scarce. Furthermore, availability of matched blood products and need for post-operative care have to be cleared prior to the intervention. In the case of life-threatening conditions, the patient needs to be rapidly and safely transferred to operating theatres of either vascular surgery or neurosurgery with advanced facilities for emergency assistance.

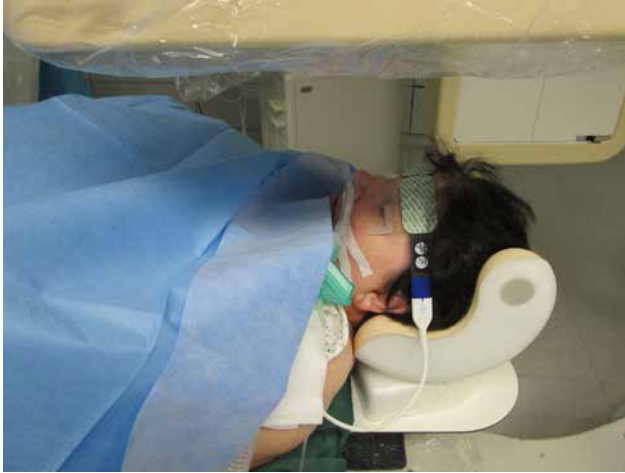

Figure 2: The frequently observed jam-packed anesthesia working place in radiology department; patient monitored with NIRS.

6 Monitoring

Hemodynamic monitoring is necessary in all patients who receive an anesthetist's attention. Minimal requirements are ECG, pulse oximetry (SpO_2) and non-invasive blood pressure [16]. In ventilated patients, repeated blood gas exams (Hb, pH, $PaCO_2$, PaO_2) are also needed. End-tidal capnometry ($PetCO_2$) is especially important for adjustment of respirator parameters without impairing brain circulation. Central venous lines via the subclavian vein are preferred to access via the internal jugular veins. Injury of the carotid artery with the potential of impaired cerebral venous circulation is particularly detrimental in neurosurgical patients. Adjustment of certain blood pressure levels is best achieved by continuous measurements via the arterial line. Controlled hypotension can be desired during embolization or positioning of the vascular stent, whereas induced hypertension is frequently applied in case of stroke. Monitoring of arrhythmias, especially bradycardia, following dilatation in the carotid region is important. In patients with a history of congestive heart failure or a history of renal insufficiency measurements of central venous pressure may be necessary. Pulmonary arterial pressures can be estimated with Swan-Ganz catheters or by pulse-induced contour cardiac output (PiCCO) via the arterial catheter. Pressure transducers and ICP system are mounted on the radiology table to avoid repeated adjustment of the level [16]. Temperature monitoring and external warming e.g. by Bair Hugger™ is obligatory in children. Hourly assessment of urine output is needed, especially in long-lasting interventions.

Neurogenic stunned myocardium or Takotsubo cardiomyopathy refers to transient left ventricular (LV)

dysfunction and is commonly observed patients with acute intracranial bleeding i.e. in poor grade SAH patients. Patients can present with cardiovascular instability, ECG abnormalities (ST-segment elevation) and cardiac enzyme elevation. Echocardiography commonly reveals regional, predominantly apical, or global left ventricular wall motion abnormality. This phenomenon is reversible and improvement of cardiac contractility in the acute phase is usually obtained with dobutamine.

Neuromonitoring of anaesthetized patients can be achieved by measuring intracranial pressure (ICP), by near infra-red spectroscopy (NIRS) or encephalographic methods. An intraventricular catheter with CSF drainage is the preferred method of ICP monitoring in cases with early hydrocephalus. Intraparenchymal sensors for ICP measurement are more easily placed bedside in the emergency situation, however excess cerebrospinal fluid cannot be removed. Currently no noninvasive device serves as reliable ICP monitor [17]. Changes in brain tissue oxygen saturation can be non-invasively and continuously estimated by NIRS to allow early detection of cerebral ischemia (Figure 2). Improvement of cerebral perfusion by adjusting respiratory and cardiac parameters can be verified [18]. Several methods based on the electroencephalogram such as bi-spectral index (BIS), Narcotrend and entropy permit the level of sedation and narcosis to be assessed in anesthetized patients and general anesthetic consumption and anesthetic recovery times to be reduced [19].

7 Sedoanalgesia (Conscious sedation)

In contrast to vascular or neurosurgical operations, patients can be safely monitored under conscious sedation during minimally invasive interventions.

In some procedures patient cooperation is advantageous, e.g. during thermoablation of the trigeminal nerve the conscious patient can respond to radiologists' questions. Together with CT guidance, patient feedback helps to precisely position the probe. Furthermore, intra-arterial thrombectomy in sedoanalgesia is associated with improved outcome if treatment delay from induction of general anesthesia can be avoided and a stable hemodynamic status maintained [4,16]. Although pain during insertion of the introducer may be tolerable for most patients, mild sedoanalgesia increases patient comfort, especially when repeated interventions are scheduled.

8 General anaesthesia

In children, non-responding patients and emergency patients neurointerventions are preferably performed in general anesthesia. This underlines the need for a fully-equipped anesthesia working place with invasive monitoring facilities. Invasive pressure measurement (arterial pressure, pulmonary arterial pressure, central venous pressure) is particularly needed in hemodynamically and medically unstable patients and whenever frequent examinations of blood gases and clotting system are requested. Strict immobilization of the patient is best achieved by general anesthesia and muscle relaxation. In long-lasting interventions and whenever hyperosmotic contrast medium is administered urinary drainage by indwelling catheter is needed. The major disadvantage of general anesthesia in neurointervention is that the neurological status cannot be continuously monitored during the procedure. For this reason, patients are weaned early so that a neurological exam can be performed immediately after recovery from anesthesia [20, 21].

9 Complication management

Generally, complication rates are low [22] and infections are rarely observed [23]. Short-term follow-up results in young patients are convincing, but so far we lack time-dependent patient outcomes [24].

Abandonment of ionic contrast media reduced the incidence of severe allergic reactions to approximately 0.04% [25]. Whereas incompatibility of contrast medium due to drops in blood pressure immediately after administration is not a rare event, minor allergic reactions e.g. rash were reported in approximately 3% of applications [25]. In the case of a known allergy preoperative combined treatment with prednisolone and H1 and H2 blockers does not guarantee event-free administration. Anesthesia monitoring is obligatory and the anesthesia team has to be prepared for treatment of severe anaphylactic shock and cardiorespiratory arrest.

Contrast-induced nephropathy (CIN) following administration of contrast media leading to renal insufficiency was observed in 20% to 30% of patients with pre-existing impairment of renal function [26]. Kidney protection by forced hydration before and after contrast media exposure and administration of N-acetylcysteine or proanthocyanidin extract is still a matter of debate [27, 28, 29].

Thromboembolic complications following neurointerventions were observed in 4%-12% of patients. Perforation

of aneurysms occurs in approximately 4% [30]. Acute intracranial bleeding may arise from inserted guide wires and microcatheters, and may follow balloon dilatation and positioning of stents. Bleeding can result in rapid increase in intracranial pressure. Adequate perfusion pressure of the brain tissue has to be maintained, with the mean arterial pressure exceeding the intracranial pressure by 60 mmHg until neurosurgical craniotomy can be performed. Close monitoring is essential, invasive arterial blood pressure must be adapted and heparin must be reversed using protamine sulfate. Elevated ICP can be treated by draining CSF through an intraventricular catheter, increased sedoanalgesia, by administering osmotherapy (mannitol, hypertonic saline) and mild to moderate hyperventilation (PCO₂ 30-35mmHg, preserved only for acute elevations of ICP). Hyperventilation is not recommended for prophylactic treatment of increased ICP because of the potential for worsening cerebral ischemia. A CPP of a least 50mmHg (CPP = MAP-ICP) should be maintained during neurointerventions. CPP estimation requires correct referencing for MAP at the level of the foramen of Monro to avoid CPP overestimation.

10 Radiation protection

Working in radiology results in a great deal of exposure to radiation. Radiation protection is paramount using full-body lead aprons, thyroid shields, eye protection and portable and static glass shields. As radiation rapidly declines with distance, anesthesia personnel should not hover over radiation sources [2, 21]. Radiation dosimeters that record the accumulated exposure to radiation are compulsory for each co-worker.

11 Standard operating procedures (SOPs)

Significant progress in the development of neurointerventional techniques has been achieved over the last twenty years, resulting in a variety of radiologic interventions for the treatment of cerebrovascular diseases [31]. Indications range from neoplasms to malformation and abnormalities of vessel walls to acute obstruction and rupture of vessels [13, 32, 33]. This partly explains the co-existence of numerous treatment modifications and recommendations at the same time and why practice guidelines differ from center to center. Quality requirements for anesthesia equipment

and supplies match the requirements prevailing in neurosurgical theatres. Specific and general standards at our university department are expressed in preoperative (Table 1), intraoperative (Table 2) and postoperative SOPs (Table 3) that can be used as check cards.

Table 1: Pre-operative SOP before neuro-intervention

I.	Anesthesiology equipment and supply
A	Check for completeness (daily prior to first administration)
	Connections to piped oxygen and air
1.	Connections to central electrical outlets
2.	Anesthesia machine, ventilator, ventilation tubes and bags
3.	Patient monitor, modules and leads
4.	Filled vapors
5.	Suction unit
6.	Motor syringes, blood warmer, cell saver
7.	Fully equipped anesthesia cart
8.	Emergency equipment
9.	Access to difficult airway cart
10.	Access to defibrillator
B.	Check for functionality
1.	Leak test for ventilation unit
2.	Leak test for ventilation bag
II.	Patient premedication and informed consent
A.	Preoperative assessment:
1.	Category (elective, urgent, emergency, ICU)
2.	Chronic infections (e.g. HCV, HBV)
3.	Patient characteristics (age, co-morbidities, current medication, venous access, cardiac and respiratory status)
4.	Clinical evidence (recent chest x-ray, recent ECG, sonography)
5.	Allergies
6.	Laboratory findings (blood chemistry, coagulation, kidney and liver function)
7.	Availability of matched blood products
8.	Consultant opinion (pediatrician, intensivist, cardiologist)
B.	Preoperative visit
1.	Case history and chief complaints
2.	Physical examination (airway inspection, auscultation of lung and heart, mobilization)
3.	Anesthesia information (method, risks, complication management)
4.	Documentation and informed consent
C.	Premedication
1.	Preoperative fasting (6 hours in adults, 2 to 4 hrs in children)
2.	Chronic medication that should be discontinued: e.g. antithrombotics
3.	Oral sedation: in adults: midazolam 3.75 to 7.5 mg in children: midazolam syrup: 0.3 to 0.5 mg/kg lidocaine/prilocaine ointment and occlusion bandage on site of venous access 30 minutes prior to anesthesia induction

Table 2: Intraoperative SOP during neurointervention

I.	Observation
A.	Characteristics Radiation protection (full-body lead aprons, thyroid shields, eye protection, lead shields) Keep dosimeter close to the body under apron No manipulation on the operating table during the procedure (avoid leaning or propping yourself on the table)
B.	Patient positioning
1.	Supine or prone position, arms parallel to the body
2.	Padding with foam rubber or gel pads
3.	Head positioning in head-contoured foam rubber frame Additional fixation with self-adhesive bandage over forehead or gel pad fixation at the root of the nose
C.	Monitoring
1.	ECG and impedance-respiratory frequency
2.	Non-invasive blood pressure
3.	Pulse oximetry
4.	CO ₂ measurement respiratory or transcutaneous
D.	Documentation Electronic or manual recording of vital signs, readings and events
II.	Sedoanalgesia (Conscious sedation)
	Characteristics, patient positioning, monitoring and documentation, see: I. Observation
A.	Preparation
1.	Venous access preferably on left forearm or back of the hand
2.	Infusion for keeping vein open or forced hydration ELO-MEL or lactated Ringer's solution
3.	Oxygen mask (remove metal bow!) or oxygen nasal probe Oxygen flow: 2-5 L/min
4.	Capnometry: side-stream measurement
B.	Medication
	Sedation
	Midazolam i.v., in 1 mg split doses
	Propofol 30 - 50 mg i.v.
	Analgesia
	Piritramide 6 - 9 mg i.v.
	S-ketamine 10 - 15 mg i.v.
	Remifentanil (2 mg/40ml) by motor syringe 0.1 - 0.25 g/kg/min
	CAVE: cumulative effects of midazolam and propofol
III.	General anaesthesia
A.	Characteristics
1.	Blood pressure must be maintained with a view to patient's neurologic status. Ideally, systolic blood pressure (SBP) should not exceed 140 mmHg unless clinical evidence of vasospasm is observed.
2.	Temporary arterial blood pressure measurement via the radiological access in the femoral artery is practicable but only as an exception.
3.	In the case of elevated intracranial pressure (ICP), administer mannitol and/or furosemide, consider short- lasting hyperventilation.
4.	In the case of threatening herniation keep mean arterial pressure (MAP) approx. 60 mm Hg above ICP to allow adequate perfusion of the brain. Cerebral perfusion pressure (CPP) = MAP - ICP
5.	ICP monitoring via intraventricular catheter, open system for CSF drainage
6.	Calibration of the drainage device 5 – 10 cm above foramen of Monro

7. Elevate blood pressure with ephedrine 5-10 mg bolus, or phenylephrine 0.1-0.2 mg bolus or (50/50) by motor syringe or noradrenalin (5/50) by motor syringe
 8. Seizure prophylaxis is generally not recommended, calcium channel block, if indicated
 9. Early provision of blood products and cell saver, if indicated
 10. Repeated blood gas analysis
 11. Confirm postoperative care at ICU (neurology, neurosurgery).
- B. Induction of general anesthesia**
- 1. Monitoring, see: I. Observation and neuromonitoring
 - 2. Fentanyl 0.02-0.05 mg/kg BW
 - 3. Propofol 2.5 mg/kg BW (in children up to 5 mg/kg BW)
 - 4. Muscle relaxation with rocuronium bromide 0.3-0.6 mg/kg BW
 - 5. Relaxometry: keep Train of Four (TOF) below 30%.
Avoid coughing and spontaneous movements by patient.
 - 6. Endotracheal intubation
 - 7. Indwelling catheters:
two large-bore peripheral intravenous lines
central venous line in acute SAH and impaired cardiopulmonary state
arterial line preferably left radial artery
urine catheter and bag for hourly measurement
 - 8. Oropharyngeal temperature probe - lower esophagus
 - 9. Bair Hugger
- C. Maintenance of general anesthesia:**
1. Balanced with sevoflurane or isoflurane in O₂/air and opioids or TIVA: propofol and remifentanyl administered by motor syringe
 2. Pressure-controlled ventilation (PCV)
Keep CO₂et between 30 and 35 mm Hg equivalent to PaCO₂ of 35 – 40 mm Hg (normocapnia)
 3. Antacids: famotidin 20mg or pantoprazole 40mg
 4. Volume replacement: cautious; crystalloid solution (ELO-MEL).
In SAH with vasospasm “triple H therapy” is recommended (hypervolemia, hypertension, hemodilution).
- D. Weaning**
- In elective cases and SAH (Hunt & Hess I) preferably in the operating theatre.
If indicated, muscle relaxation to be reversed with:
prosgimine/glycopyrronium 1-2/0.2-0.4 or sugammadex 200mg
(coughing and choking by the patient must be avoided).
In SAH (Hunt & Hess > II) weaning preferably at the ICU.
Arrange early for patient to be transferred to the ICU in intensive care bed, with respirator, continuous monitoring, medication administered by motor syringe.

Table 3: Postoperative SOP after neurointervention

-
- I. Intensive Care**
1. Course of intervention handed over directly to the intensivist in general anesthesia by the neuroradiologist and anesthetist.
 2. Transfer to ICU (neurology, neurosurgery) under continued monitoring
 3. Antithrombotic therapy with abciximab, acetylsalicylic acid and heparin is administered, if requested, by the radiologist e.g. heparin 10 000 IU/24 hrs by motor syringe after cerebral coiling.
 4. Aim is early weaning from ventilation.
 5. Early measures comprise neurological examination and laboratory exam of blood gas, electrolytes, clotting system, liver and kidney function.
 6. Follow-up investigation is scheduled in cooperation with neuroradiologist and anesthetist.
- II. Intermediate Care**
- For thermoablation of the trigeminal nerve in dissociative anesthesia with S-ketamine 0.25-0.4 mg/kgBW intermediate care in silent and shaded environment is sufficient.
-

Contributors: WL, MST, FJW searched for and selected references, created the structure of the review and prepared the first draft and subsequent versions. AG, RH, RB supplied the text for their subspecialties.

Conflict of interest statement: Authors state no conflict of interest.

Acknowledgments: The authors thank all nurses of the anesthesia and intensive care units, all radiology technicians involved in the treatment of our patients for their good multidisciplinary cooperation.

References

- [1] Steele JR, Wallace MJ, Hovsepian DM, James BC, Kundu S, Miller DL, Rose SC, Sacks D, Shah SS, Cardella JF. Guidelines for Establishing a Quality Improvement Program in Interventional Radiology. *J Vasc Interv Radiol* 2010; 21:617-625
- [2] Ard JL Jr., Huncke TK. A Trip to a Foreign Land: Interventional Neuroradiology. *ASA Monitor* 2013; 77(11):22-24
- [3] Park HS, Kwon SC, Kim MH, Park ES, Sim HB, Lyo IU. Endovascular Coil Embolization of Distal Anterior Cerebral Artery Aneurysms: Angiographic and Clinical Follow-up Results. *Neurointervention*. 2013; 8(2):87-91
- [4] Molyneux AJ, Kerr RS, Yu LM, et al. International Subarachnoid Aneurysm Trial (ISAT) Collaborative Group. International Subarachnoid Aneurysm Trial (ISAT) of neurosurgical clipping versus endovascular coiling in 2143 patients with ruptured intracranial aneurysms: a randomised comparison of effects on survival, dependency, seizures, rebleeding, subgroups, and aneurysm occlusion. *Lancet*. 2005; 366(9488): 809-817
- [5] Kim ST, Jeong HW, Seo J. Onyx Embolization of Dural Arteriovenous Fistula, using Scepter C Balloon Catheter: a Case Report. *Neurointervention*. 2013; 8(2):110-114
- [6] Alurkar A, Karanam LS, Oak S, Nayak S, Sorte S. Role of balloon-expandable stents in intracranial atherosclerotic disease in a series of 182 patients. *Stroke*. 2013; 44(7):2000-2003
- [7] Alurkar A, Karanam LS, Nayak S, Oak S. Stent-assisted coiling in ruptured wide-necked aneurysms: A single-center analysis. *Surg Neurol Int*. 2012; 3:131
- [8] Van Den Berg JC. Strategies for optimizing the safety of carotid stenting in the hyperacute period after onset of symptoms. *J Cardiovasc Surg (Torino)*. 2014; 55(2 Suppl 1):21-32
- [9] Zahn R, Ischinger T, Hochadel M, Mark B, Zeymer U, Jung J, Schramm A, Hauptmann KE, Seggewiss H, Janicke I, Mudra H, Senges J; Arbeitsgemeinschaft Leitende Kardiologische Krankenhausärzte (ALKK). *Clin Res Cardiol*. 2007;96(10):730-737
- [10] NINDS. Tissue plasminogen activator for acute ischemic stroke. The national institute of neurological disorders and stroke rt-PA stroke study group. *N Engl J Med*. 1995; 333:1581-1587
- [11] Lin DDM, Gailloud P, Beauchamp NJ, Aldrich EM, Wityk RJ, Murphy KJ. Combined stent placement and thrombolysis in acute vertebrobasilar ischemic stroke. *AJNR Am J Neuroradiol*. 2003; 24:1827-1833
- [12] Novakovic RL, Toth G, Narayanan S, Zaidat OO. Neurology. Retrieval stents, “stentriever,” for endovascular acute ischemic stroke therapy. 2012;79(13 Suppl 1):S148-157
- [13] Sacks D, Black CM, Cognard C, Connors JJ, Frei D, Gupta R, Jovin TG, Kluck B, Meyers PM, Murphy KJ, Ramee S, Rüfenacht DA, Stallmeyer MJB, Vorwerk D. Multisociety Consensus Quality Improvement Guidelines for Intraarterial Catheter-directed Treatment of Acute Ischemic Stroke, from the American Society of Neuroradiology, Canadian Interventional Radiology Association, Cardiovascular and Interventional Radiological Society of Europe, Society for Cardiovascular Angiography and Interventions, Society of Interventional Radiology, Society of NeuroInterventional Surgery, European Society of Minimally Invasive Neurological Therapy, and Society of Vascular and Interventional Neurology. *Journal of Vascular and Interventional Radiology* 2013; 24(2):151-163
- [14] Rapold HJ, Lu HR, Wu ZM, Nijs H, Collen D. Requirement of heparin for arterial and venous thrombolysis with recombinant tissue-type plasminogen activator. *Blood*. 1991; 77(5):1020-1024
- [15] Bale RJ, Burtscher J, Eisner W, Obwegeser AA, Rieger M, Sweeney RA, Dessl A, Giacomuzzi SM, Twerdy K, Jaschke W. Computer-assisted neurosurgery by using a noninvasive vacuum-affixed dental cast that acts as a reference base: another step toward a unified approach in the treatment of brain tumors. *J Neurosurg*. 2000; 93(2):208-213
- [16] Rosas AL: Anesthesia for Interventional Neuroradiology; Part I: Introduction, General Considerations, and Monitoring. *The Internet Journal of Anesthesiology* 1997; Vol 1 N 1: <http://www.ispub.com/journals/IJA/Vol1N1/articles/neuroan1.htm>
- [17] Helbok R, Olson DM, Le Roux PD, Vespa P. The Participants in the International Multidisciplinary Consensus Conference on Multimodality M: Intracranial Pressure and Cerebral Perfusion Pressure Monitoring in Non-TBI Patients: Special Considerations. *Neurocritical Care* 2014; Suppl2:S85-94
- [18] J. M. Murkin JM, Arango M. Near-infrared spectroscopy as an index of brain and tissue oxygenation. *Br. J. Anaesth*. 2009; 103 (suppl 1): i3-i13
- [19] Shepherd J, Jones J, Frampton G, Bryant J, Baxter L, Cooper K. Clinical effectiveness and cost-effectiveness of depth of anesthesia monitoring (E-Entropy, Bispectral Index and Narcotrend): a systematic review and economic evaluation. *Health Technol Assess*. 2013; 17(34):1-264
- [20] John N, Mitchell P, Dowling R, Yan B. Is general anesthesia preferable to conscious sedation in the treatment of acute ischaemic stroke with intra-arterial mechanical thrombectomy? A review of the literature. *Neuroradiology*. 2013; 55(1):93-100
- [21] Lee CZ, Young WL. Anesthesia for endovascular neurosurgery and interventional neuroradiology. *Anesthesiol Clin*. 2012; 30(2):127-147
- [22] Schulenburg E, Matta B. Anesthesia for interventional neuroradiology. *Curr Opin Anesthesiol*. 2011; 24(4):426-432
- [23] Horowitz MB, Dutton K, Purdy PD. Assessment of Complication Types and Rates Related to Diagnostic Angiography and Interventional Neuroradiologic Procedures. A Four Year Review (1993-1996). *Interv Neuroradiol*. 1998; 4(1):27-37

- [24] Kelkar PS, Fleming JB, Walters BC, Harrigan MR. Infection risk in neurointervention and cerebral angiography. *Neurosurgery*. 2013; 72(3):327-331
- [25] Park HS, Kwon SC, Shin SH, Park ES, Sim HB, Lyo IU. Clinical and radiologic results of endovascular coil embolization for cerebral aneurysm in young patients. *Neurointervention*. 2013; 8(2):73-79
- [26] Katayama H, Yamaguchi K, Kozuka Tet al. Adverse reactions to ionic and nonionic contrast media. *Radiology* 1990; 175:270-276
- [27] Davenport MS, Khalatbari SM, Cohan RH, Dillman JR, Myles JD, Ellis JH. Contrast material-induced nephrotoxicity and intravenous low-osmolality contrast material: Risk stratification by using estimated glomerular filtration rate. *Radiology* 2013; 268:719-728
- [28] Sadat U. N-acetylcysteine in contrast-induced acute kidney injury: clinical use against principles of evidence-based clinical medicine! *Expert Rev Cardiovasc Ther*. 2014; 12(1):1-3
- [29] Mahmoodi K, Sohrabi B, Ilkhchooyi F, Malaki M, Khaniani ME, Hemmati M. The Efficacy of Hydration with Normal Saline Versus Hydration with Sodium Bicarbonate in the Prevention of Contrast-induced Nephropathy. *Heart Views*. 2014; 15(2):33-36
- [30] Ulusoy S, Ozkan G, Mungan S, Orem A, Yulug E, Alkanat M, Yucesan FB. GSPE is superior to NAC in the prevention of contrast-induced nephropathy: might this superiority be related to caspase 1 and calpain 1? *Life Sci*. 2014; 103(2):101-110
- [31] Orrù E, Roccatagliata L, Cester G, Causin F, Castellan L. Complications of endovascular treatment of cerebral aneurysms. *Eur J Radiol*. 2013; 82(10):1653-1658
- [32] Jung C, Kwon BJ, Han MH. Evidence-Based Changes in Devices and Methods of Endovascular Recanalization Therapy. *Neurointervention*. 2012; 7(2): 68-76
- [33] Lee BH. Guideline for intracranial stenting of symptomatic intracranial artery stenosis: preliminary report. *Neurointervention*. 2007; 2:30-35