




Taibah University
Journal of Taibah University Medical Sciences

www.sciencedirect.com



Case Report

Cryptococcal spondylodiscitis in a non-HIV patient with CD4 lymphocytopenia

Shyamasunder N. Bhat, MS^{a,*}, Raghuraj Kundangar, MS^a, Nishanth Ampar, MS^a, Barnini Banerjee, MD^b, Chethana Babu K. Udupa, MD^c and Kavitha Saravu, MD^d

^a Department of Orthopaedics, Kasturba Medical College, Manipal, Manipal Academy of Higher Education, Karnataka, India

^b Department of Microbiology, Kasturba Medical College, Manipal, Manipal Academy of Higher Education, Karnataka, India

^c Department of Pathology, Kasturba Medical College, Manipal, Manipal Academy of Higher Education, Karnataka, India

^d Department of Infectious Diseases, Kasturba Medical College, Manipal, Karnataka, India

Received 3 November 2020; revised 1 January 2021; accepted 14 January 2021; Available online 6 February 2021



المخلص

تُعرف العدوى التي تؤثر على الأقراص الفقرية وفقراتها باسم التهاب الفقار وأقرصها. تحدث هذه العدوى عادة عن طريق المكروبات المقيحة، ولا سيما من قبل المكورات العنقودية، والطريق الأكثر شيوعاً لانتشارها هو انتشار الدم. وتشمل العدوى غير المقيحة المتفطرة السلية وداء البروسيلات. وتزداد العدوى الفطرية شيوعاً مع تزايد عدد اضطرابات نقص المناعة. ومن ضمن العدوى الفطرية عدوى المستخفية. نقدم حالة من هذه العدوى في مريض لا يعاني من نقص المناعة مع تاريخ معروف من العلاج بمضاد السل. حضر رجل يبلغ من العمر ٥٢ عاماً إلى مستشفىنا يعاني من ألم في الظهر لمدة شهر، وعجز عصبي تدريجي في الأطراف السفلية لمدة أسبوع واحد. وكانت دراساته التصويرية موحية بالتهاب الفقار وأقرصها في مستوى الفقرات الظهرية ١١-١٠ و ١٢-١١ مع خراج مجاور للفقرات أيسر. خضع المريض لتخفيف الضغط من الجهة الأمامية الوجيهة، والخزعة والاندماج الفقري الخلفي بالأدوات الجراحية. نمت المستخفية من القيح، وأكدت الهستوباثولوجيا التهاب الفقار وأقرصها بالمستخفية. وعولج المريض بالأمفوترسين ب وفلاكونازول عن طريق الوريد. يجب النظر في العدوى الفطرية في التشخيص التفريقي لالتهاب الفقار وأقرصها.

الكلمات المفتاحية: التهاب الفقار وأقرصها بالمستخفية؛ قلة اللمفاويات؛ التبدير؛ غير المصابين بفيروس نقص المناعة البشرية؛ التهاب الفقار وأقرصها

Abstract

Infections that affect the intervertebral discs and vertebrae are known as spondylodiscitis. Such infections are commonly caused by pyogenic organisms, particularly *Staphylococcus aureus*, and hematogenous spread is the most common route. Non-pyogenic infections include *Mycobacterium tuberculosis* and Brucellosis. Mycotic infections are becoming more common, in line with the growing number of immunodeficiency disorders. *Cryptococcus* is included among these mycotic infections. We present a case of such an infection in a non-immunocompromised patient with a known history of treatment with antitubercular therapy. A 52-year-old man came to our hospital with a backache of one-month duration and progressive neurological deficits of the lower limbs of one-week duration. His imaging studies were suggestive of spondylodiscitis at the D10–11 and D11–12 levels with a left paraspinal abscess. The patient underwent anterolateral decompression, biopsy, and instrumented posterior spinal fusion. The pus grew *Cryptococcus*, and histopathology confirmed *Cryptococcal* spondylodiscitis. The patient was treated with parenteral amphotericin B and fluconazole. A mycotic infection must be considered in the differential diagnosis of infectious spondylodiscitis.

Keywords: Cryptococcal spondylodiscitis; Lymphocytopenia; Management; Non-HIV; Spondylodiscitis

© 2021 The Authors.

Production and hosting by Elsevier Ltd on behalf of Taibah University. This is an open access article under the CC BY-NC-ND license (<http://creativecommons.org/licenses/by-nc-nd/4.0/>).

* Corresponding address: Department of Orthopaedics, Kasturba Medical College, Manipal, Manipal Academy of Higher Education, Karnataka 576104, India.

E-mail: shyambhat.n@manipal.edu (S.N. Bhat)

Peer review under responsibility of Taibah University.



Production and hosting by Elsevier

Introduction

Spinal infections are known to have existed since ancient times. Human skeletons from the Iron Age have shown changes suggesting tuberculosis. The French physician Lannelongue described the first case of pyogenic vertebral osteomyelitis in 1879.¹ The first series of pyogenic vertebral infections was published in the literature by Kulowski in 1936.¹ Despite advances in surgical and imaging techniques and the discovery of antibiotics, which have given patients hope, morbidity remains significant.¹

Spinal infections are classified as pyogenic, granulomatous (tuberculous, brucella, fungal), and parasitic.¹ Pyogenic spondylodiscitis can cause significant morbidity and severe long-term sequelae. Skaf et al.² conducted a literature review to understand the diagnosis, treatment, and prognosis. Appropriate management involves aggressive medical treatment and, sometimes, surgical intervention. Full recovery is expected if diagnosed early and treated appropriately. Hence, clinicians should know the clinical features to improve outcomes.²

The incidence of spondylodiscitis is on the rise, due to an increase in the susceptible population and available useful diagnostic tools. A high index of suspicion is needed for correct diagnosis to ensure better prognosis. A microbiological diagnosis is required to choose appropriate antibiotics. Surgery may be necessary to alleviate pain, correct

deformities, alleviate neural compression, and restore function.¹

Cryptococcal infection, if disseminated, has higher morbidity and mortality. Typical patients are immunosuppressed due to retroviral infection or immunosuppressive drugs given to solid organ transplant patients. Almutawa et al.³ described a case of disseminated cryptococcal disease in a non-retroviral, non-transplant patient with a good clinical outcome.

Hematogenous multifocal bony lesions have been reported in 5–10% of all cryptococcal infections.^{4–6} In a case report of disseminated cryptococcal infection, *C. neoformans* was detected in pleuritic fluid and the resected rib.⁷ Vertebral lesions need to be monitored by Magnetic Resonance Imaging (MRI), as it has high sensitivity in identifying spinal infections and helps in visualizing abscesses (paravertebral or epidural). No clear guidelines exist concerning the antifungal of choice or duration of treatment for these patients. However, if the CD4 cell count is below 100 cells/ μ L, prophylaxis has been suggested.⁷

Case report

A 52-year-old male came to us with back pain of one-month duration, with insidious onset and radiation to the lower limbs. During the previous week, there had been progressive weakness of the lower limbs and an inability to walk. There were no bladder/bowel disturbances. The patient had

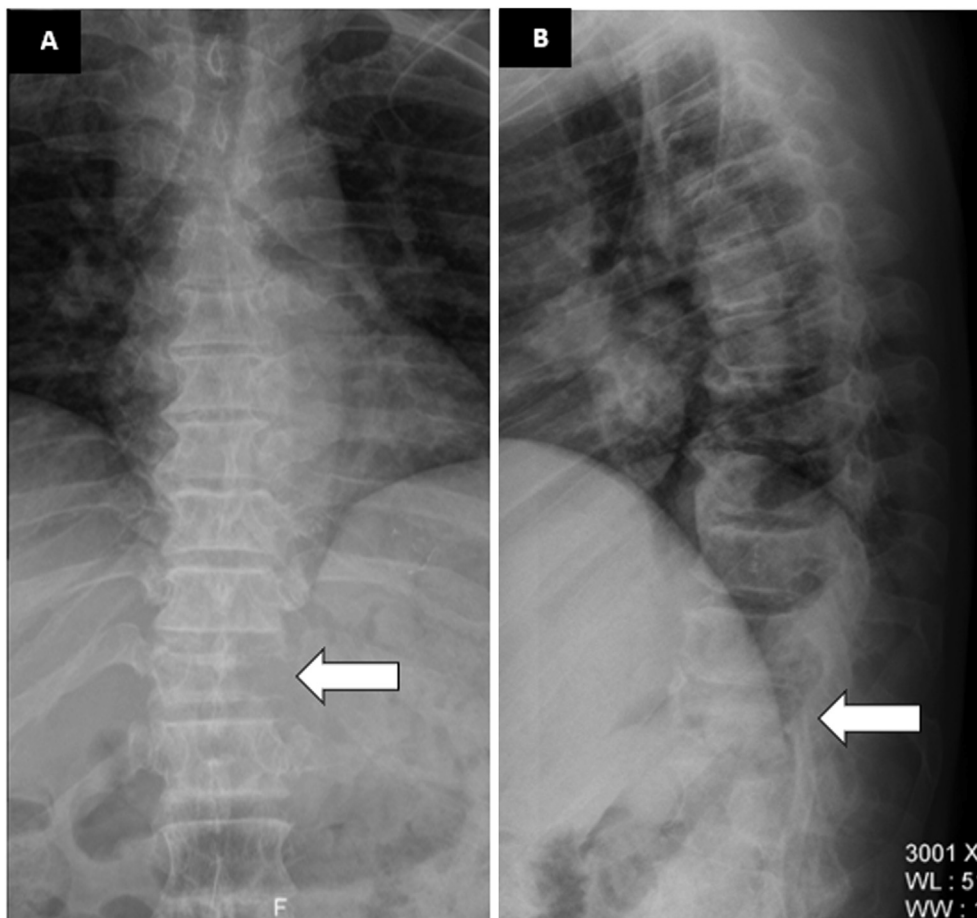


Figure 1: A. Frontal radiograph showing destruction of the left pedicle of the D11 vertebra (Winking Owl sign). B. Lateral radiograph showing collapse of the body of D11 vertebra (Arrow).

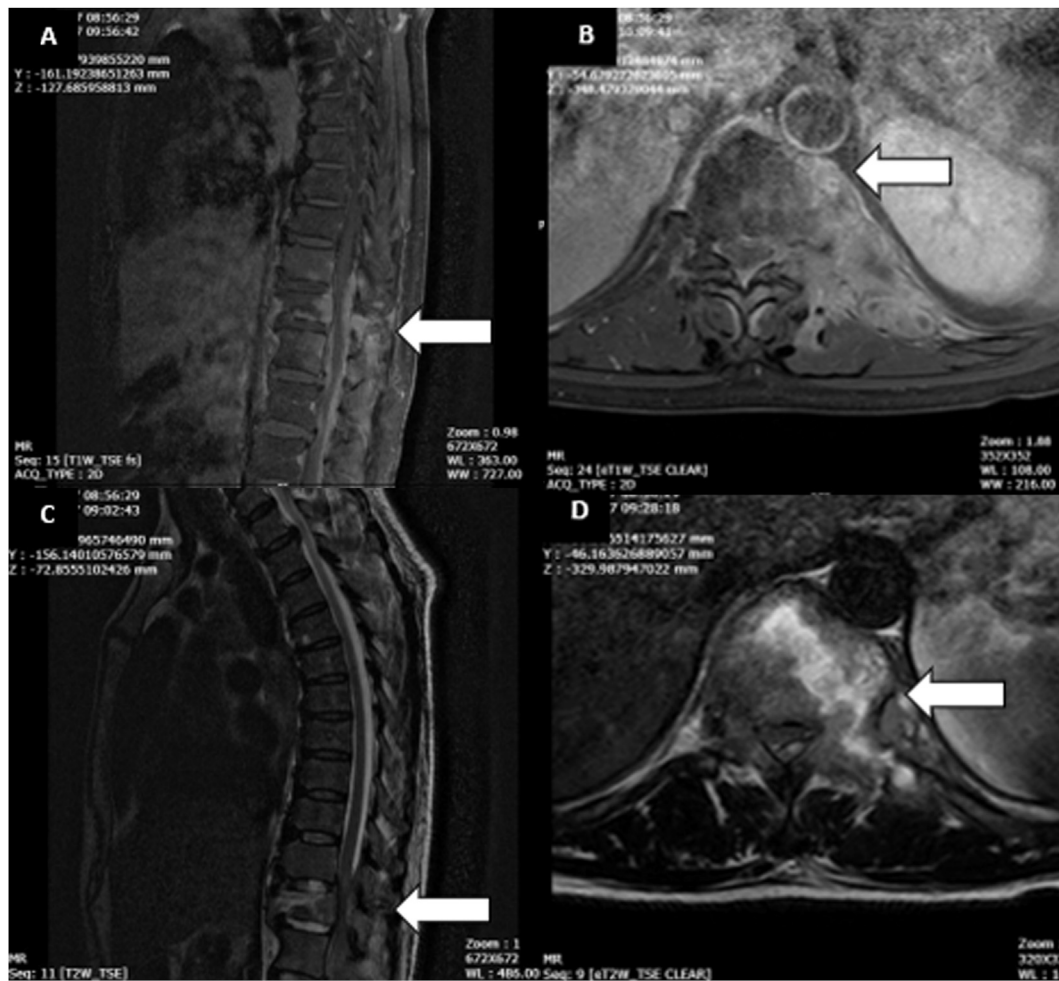


Figure 2: A. Magnetic Resonance T1-weighted sagittal image. B. T1-weighted axial image. C. T2-weighted sagittal image. D. T2-weighted axial image. Arrows show the lesion site.

lost about 3 kgs of weight over 2 months, but there were no other constitutional symptoms. He gave a history of being started with antitubercular drugs a week earlier based on radiographs.

On examination, the patient had normal vital signs (afebrile, pulse rate 86/min, and blood pressure 140/90 mmHg). There was no spinal deformity. Tenderness was present on the lower thoracic spinous processes. The higher mental functions and upper limb neurology were normal. He had a complete loss of motor power in the lower limbs with preservation of perianal sensation (American Spinal Injury Association grade B). There were mild hypertonia in the lower limbs, a flicker of contractions, exaggerated deep tendon reflexes, and extensor plantar response (Babinski sign) bilaterally.

The radiographs he brought with him showed destruction of the left pedicle of the D11 vertebra (Winking Owl sign) (Figures 1A and B).

A contrast MRI reported D10, D11, and D12 vertebral diffuse spondylitis with D10-11 and D11-12 discitis, a D11 vertebral body intra-osseous abscess with epidural extension causing significant cord compression and focal cord oedema,

and prevertebral extension with left psoas and left paraspinal intramuscular abscesses (Figure 2A–D).

The patient was anaemic (haemoglobin 12.4 g/dl) and had leucocytosis (total leucocyte count 12000/cmm), an elevated erythrocyte sedimentation rate (ESR - 65 mm/h), and raised C-Reactive Protein (CRP - 15 mg/l). Blood glucose, renal function tests (blood urea 40 mg/dL, serum creatinine 1.2 mg/dL), and liver function tests were normal. He was negative for HIV 1 and 2 antibodies by ELISA & Western Blot tests. The Brucella Serum Agglutination Test was negative. The blood culture did not grow any organisms.

Therefore, a clinico-radiologically tubercular infection was suspected, and surgical management was indicated for further confirmation and neurological decompression. The patient underwent anterolateral decompression at D11–D12, biopsy, and posterior fusion with fixation using a pedicle screw construct. Intraoperatively, we found pus and granulation tissue, which were sent for aerobic culture and anti-tubogram. Molecular diagnostic studies such as the Polymerase Chain Reaction (PCR) and GeneXpert test were negative for *M. tuberculosis*. His postoperative images are shown in Figure 3A and B.

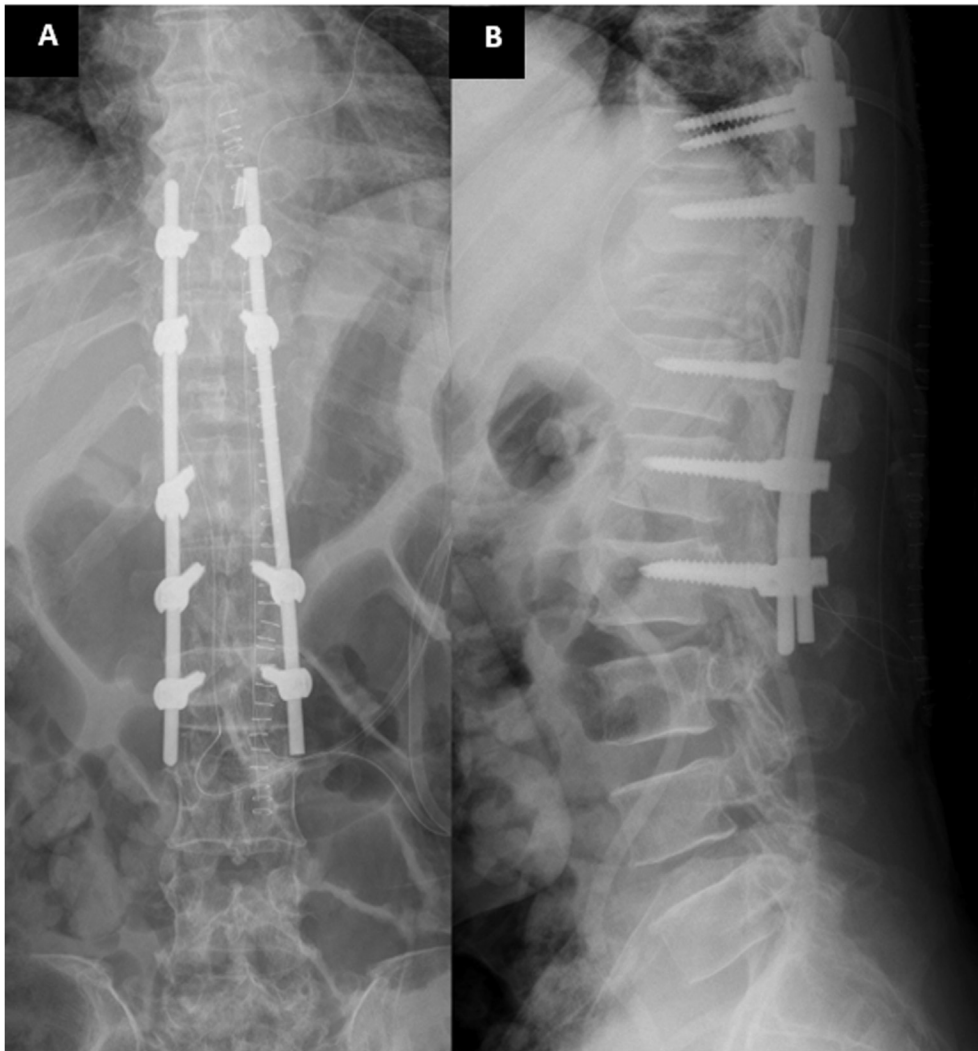


Figure 3: A. Postoperative anteroposterior radiograph. B. Lateral radiograph. Posterior instrumented fusion was done.

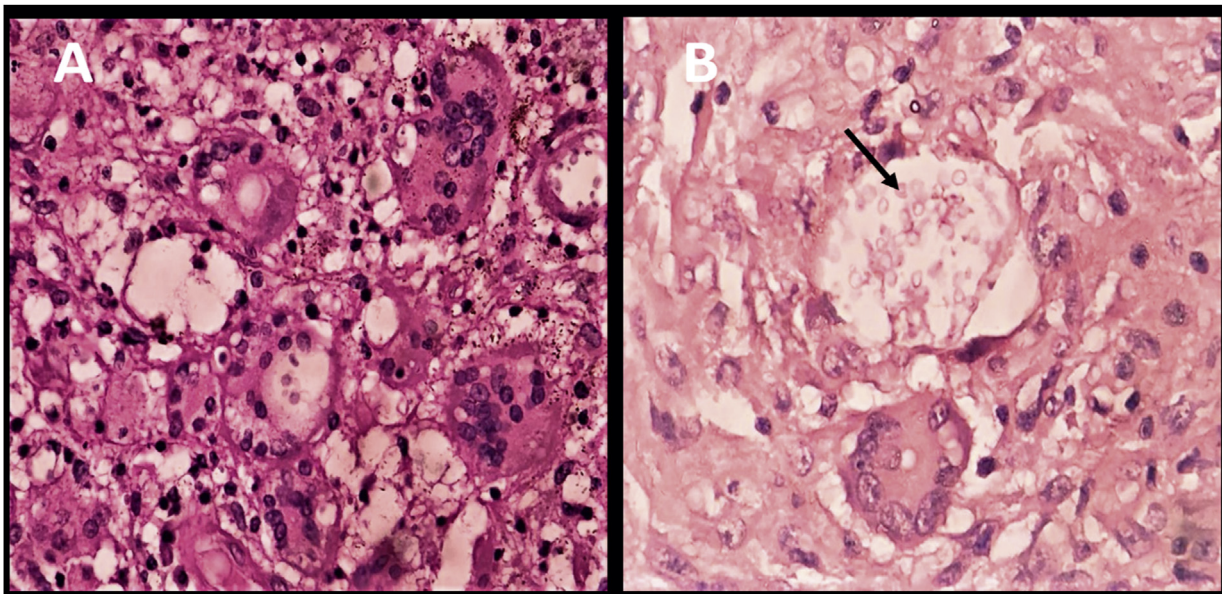


Figure 4: A. H&E, 400X Multiple foreign body giant cells reaction. B. Mucicarmine stain, 400X demonstrating the mucopolysaccharide capsule of *Cryptococcus neoformans* (Arrow).

Table 1: Serial renal function tests.

Investigation	Admission	On treatment with amphotericin				Readmission
		Day 1	Day 4	Day 9	Day 14	
Urea (mg/dL)	40	37	35	27	33	80
Creatinine (mg/dL)	1.0	0.8	1.0	1.1	1.3	2.9

Table 2: Indications for surgery in pyogenic spontaneous spondylodiscitis.²

1 No response to conservative therapy
2 Progressive/significant or neurological involvement
3 Para spinal abscess causing mass effect or septic embolus
4 Significant skeletal involvement (two adjacent vertebral bodies, or > 50% vertebral body height loss)
5 Progressive deformity ± incapacitating backache

The pus culture grew gram-positive round budding yeast cells on sabouraud dextrose agar and 5% sheep blood agar, identified as *Cryptococcus neoformans* by MALDI-TOF (bioMérieux, Inc., Durham, NC). The mycobacterial culture by the MGIT 960 method showed no growth after 6 weeks of incubation.

The histopathological report showed granulation tissue along with numerous granulomas of different sizes, consisting of plump endothelial cells, foreign body giant cells, and a few Langhan's type of giant cells. Numerous round to oval organisms were seen with thick mucinous capsules morphologically resembling *Cryptococcus neoformans* (Figure 4A). Special staining with Mucicarmine and PAS was positive for *Cryptococcus* (Capsule stained bright red) (Figure 4B).

The patient's CD4 were low twice (265 cells/ μ L and 233 cells/ μ L during the same admission). He was initiated on a combination of intravenous amphotericin deoxycholate 1 mg/kg and fluconazole 800 mg/day for a period of 2 weeks. Renal function was serially monitored (Table 1). He was clinically stable, but the lower limb weakness persisted. He was discharged on oral fluconazole 400 mg/day and warfarin (as thromboprophylaxis) and was advised to follow up after 1 month. At the time of discharge, the blood urea was 25 mg/dL, and serum creatinine was 1.3 mg/dL. However, the patient was brought to the hospital 3 weeks after discharge with a history of fever for 2 days, altered sensorium, and decreased urine output for 1 day. At presentation, he was drowsy; however, there was no neck stiffness. The total leucocyte counts were 17,100/cmm. Procalcitonin was elevated (152.7 μ g/L). Blood urea was 80 mg/dL, and serum creatinine was 2.9 mg/dL. The Prothrombin Time (PT) was 77.6 s, and the Activated Partial Thromboplastin Time (APTT) was 86.6 s. The platelet count was 3,59,000/ μ L. These parameters suggested septic shock with acute kidney injury requiring haemodialysis and coagulopathy. The focus of the infection was not apparent. The surgical site had healed externally. The patient was started on intravenous vancomycin and

meropenem and switched to intravenous fluconazole. A cerebrospinal fluid (CSF) analysis could not be done in view of coagulopathy. The patient succumbed to the illness after a short stay of 2 days. The serum cryptococcal antigen was positive, and the blood culture was sterile. However, our lab could not do cryptococcal antigen titres.

Discussion

Central nervous system cryptococcosis in non-retroviral infected patients usually affects those on immunosuppressive therapy and those who are immunocompetent. The disease can be caused by *Cryptococcus neoformans* and *Cryptococcus gattii*; conventional risk factors are patients with HIV, transplant recipients, malignancy, chronic steroid use, and intravenous drug abuse.⁸ Wagemakers⁹ reported a case of chronic relapsing cryptococcal meningitis in a patient with a low naïve CD4 cell count and low mannose-binding lectin.

Our patient was HIV negative but had CD4 lymphocytopenia. CD4 lymphocytopenia can occur transiently during various infections such as tuberculosis, bacteria sepsis, and measles. Idiopathic CD4 lymphocytopenia is a diagnosis of exclusion. The diagnosis requires that the CD4 count is < 300 cells/ μ L i.e. less than 20% of total lymphocytes on two occasions.¹⁰ In addition, there should not be other immunological abnormalities and infections that can cause lymphocytopenia. Our patient could have had idiopathic CD4 lymphocytopenia. No other infection was apparent. Idiopathic CD4 lymphocytopenia is a known predisposing condition for cryptococcal infection. However, he was not evaluated for other immunodeficiency conditions such as common variable immunodeficiency. Moreover, he had no history of recurrent infections. An infectious aetiology of idiopathic CD4 lymphocytopenia has not been identified so far.

Patients with CD4 lymphopenia are at risk of opportunistic and non-opportunistic infections, typically when CD4 is less than 200 cells/ μ L. The most common infections in one series were cryptococcal infections (26.6%) and mycobacterial infections (17%).¹¹ These pathogens can produce focal infections in any organs, including the musculoskeletal compartment, or produce disseminated disease depending on the degree of immunosuppression.

Table 2, adapted from Skaf et al.,² states the indications for surgery in a case of spondylodiscitis. The indications for surgery in this case were progressive neurological deficits due to mass effect and to obtain material for bacteriological and histopathological confirmation from the site of the lesion.

Treatment of disseminated cryptococcal diseases is challenging. In view of the poor bone concentration of fluconazole, amphotericin is a pivotal drug for treatment of cryptococcal spondylodiscitis.¹² The duration of amphotericin administration was shorter, as the patient was unwilling to take the parenteral treatment for longer. For the induction phase, we could not give flucytosine, due to non-availability. There was also an inadvertent drug-drug interaction between fluconazole and warfarin, which could partially explain the patient's coagulopathy on readmission. Although he presented with septic shock, the

aetiology, whether disseminated cryptococcal disease or bacterial infection, was not clear. In view of the suboptimal antifungal therapy and presence of fever and altered sensorium, the progression of cryptococcal disease including meningitis is a strong possibility. However, high procalcitonin pointed to a bacterial infection with sepsis.

In conclusion, cases of infective spondylodiscitis must be rigorously evaluated microbiologically for accurate diagnosis. We report this case to raise the awareness of clinicians concerning the possibility of Cryptococci as potential aetiological agents for spondylodiscitis and to highlight the therapeutic challenge. In the presence of a fungal aetiology, underlying immunosuppressive conditions such as idiopathic CD4 lymphocytopenia must be investigated. The successful treatment of CNS cryptococcal disease and cryptococcal spondylodiscitis requires the administration of a combination of antifungal drugs with careful monitoring for side effects and drug interactions.

Source of funding

This research did not receive any specific grant from funding agencies in the public, commercial, or not-for-profit sectors.

Conflict of interest

The authors have no conflict of interest to declare.

Ethical approval

The manuscript has been prepared in accordance with CARE criteria (2013). The patient had subsequently succumbed to the disease, and we learnt that the case was interesting and reportable. We could not trace the patient's family; hence, consent was not obtained. We used only clinical details and anonymized X-Ray and MRI images. For case reports, obtaining Institutional Ethics Committee permission is currently optional in our institution. Permission from the medical superintendent of the hospital was obtained to retrieve the medical records of the patient. However, the case report was approved by the Departmental Review Committee, Department of Orthopaedics for submission to the *Journal of Taibah University Medical Sciences* (KMC/Ortho/0901/2020 dated Sep 1, 2020).

Authors' contributions

SNB, RSK, NA, BB, CU, and KS: Involved in patient care including diagnosis and treatment. SNB: Conception and design, acquisition of case details and interpretation. SNB, BB, KS: Drafting the article or revising it critically for important intellectual content. SNB, RSK, NA, BB, CU, KS: Final approval of the version published. All the authors

agree to be accountable for the article and to ensure that all questions regarding the accuracy or integrity of the article are investigated and resolved. All authors have critically reviewed and approved the final draft and are responsible for the content and similarity index of the manuscript.

References

- Gouliouris T, Aliyu SH, Brown NM. Spondylodiscitis: update on diagnosis and management. *J Antimicrob Chemother* 2010; 65(Suppl. 3): 11–24. <https://doi.org/10.1093/jac/dkq303>.
- Skaf GS, Domloj NT, Fehlings MG, Bouclaousa CH, Sabbagha AS, Kanafanic ZA, et al. Pyogenic spondylodiscitis: an overview. *J Infect Publ Health* 2010; 3(1): 5–16. <https://doi.org/10.1016/j.jiph.2010.01.001>.
- Almutawa F, Leto D, Chagla Z. Case report disseminated cryptococcal disease in non-HIV, nontransplant patient. *Case Rep Infect Dis* 2016; 2016: 1–4.
- Liu P, YF. Cryptococcal osteomyelitis: case report and review. *Diagn Microbiol Infect Dis* 1998; 30(1): 33–35. [https://doi.org/10.1016/S0732-8893\(97\)00190-9](https://doi.org/10.1016/S0732-8893(97)00190-9).
- Behrman RE, Masci JR, Nicholas P. Cryptococcal skeletal infections: case report and review. *Rev Infect Dis* 1990; 12(2): 181–190. <https://doi.org/10.1093/clinids/12.2.181>.
- Corr P. Musculoskeletal fungal infections. *Semin Musculoskelet Radiol* 2011; 15(5): 506–510. <https://doi.org/10.1055/s-0031-1293496>.
- Legarth RA, Christensen M, Calum H, Katzenstein TL, Helweg-Larsen J. Cryptococcal rib osteomyelitis as primary and only symptom of idiopathic CD4 penia. *Med Mycol Case Rep* 2014; 4(1): 16–18. <https://doi.org/10.1016/j.mmcr.2014.02.002>.
- Beardsley J, Sorrell TC, Chen SC-A. Central nervous system cryptococcal infections in non-HIV infected patients. *J Fungi* 2019; 5(3): 71. <https://doi.org/10.3390/jof5030071>.
- Wagemakers A, Ang CW, Hagen F, Bot JCJ, Bomers MK, Visser MC, et al. Case report: chronic relapsing cryptococcal meningitis in a patient with low mannose-binding lectin and a low naïve CD4 cell count. *BMC Infect Dis* 2019; 19(1): 1–4. <https://doi.org/10.1186/s12879-019-4515-0>.
- Zonios DI, Falloon J, Bennett JE, Shaw PA, Chait D, Baseler MW, et al. Idiopathic CD4+ lymphocytopenia: natural history and prognostic factors. *Blood* 2008; 112(2): 287–294. <https://doi.org/10.1182/blood-2014-05-577916>. Blood 2014;124(3):463-463.
- Ahmad DS, Esmadi M, Steinmann WC. Idiopathic CD4 Lymphocytopenia: spectrum of opportunistic infections, malignancies, and autoimmune diseases. *Avicenna J Med* 2013; 3(2): 37–47. <https://doi.org/10.4103/2231-0770.114121>.
- Felton T, Troke PF, Hope WW. Tissue penetration of antifungal agents. *Clin Microbiol Rev* 2014; 27(1): 68–88. <https://doi.org/10.1128/CMR.00046-13>.

How to cite this article: Bhat SN, Kundangar R, Ampar N, Banerjee B, Udupa CBK, Saravu K. Cryptococcal spondylodiscitis in a non-HIV patient with CD4 lymphocytopenia. *J Taibah Univ Med Sc* 2021;16(3):470–475.