

Variation of Ventricular Size after Surgical Treatment of Chronic Subdural Hematoma

Abstract

Background: Surgical removal is the treatment of choice for chronic subdural hematoma (CSDH). Despite clinical improvement after surgery, computed tomography (CT) scan control often showed residual collection, which may discuss the possibility of failed surgery. The aim of this study is the assessment of ventricular size before and after surgery and to study its relation with residual hematoma. **Methods:** In this prospective study (2013-2016), 63 patients who had burr-hole drainage of CSDH were sequentially allocated to either two groups; Group 1 with CT scan control under the 3rd day of surgery and Group 2 with delayed CT scan control (from 4th to 7th day). Linear measure of ventricular size was assessed by Evans' index. We reviewed and analyzed the data between both groups. **Results:** There were 33 patients in Group 1 and 30 patients in Group 2. Preoperatively, the average thickness of hematoma was 20.5 mm in Group 1 versus 19.9 mm in Group 2 ($P = 0.67$); the mean midline shift was 8.5 mm in each group; Evans' index was 26.7% in Group 1 and 27% in Group 2 ($P = 0.7$). Postoperatively, the mean thickness of the residual hematoma was 7.7 mm in Group 1 and 8.4 mm in Group 2 ($P = 0.57$); the mean midline shift was 3.3 mm in Group 1 and 1.9 mm in Group 2 ($P = 0.08$); Evan's index was 28.5% in Group 1 and 32.1% in Group 2 ($P = 0.002$). **Conclusion:** The adoption of Evans' index, for assessing the variation of ventricular size after surgery, by neurosurgeons appears to be a good and simple method for evaluation and following the success of surgical removal of CSDH, despite the observation of some residual collection in early CT scan control.

Keywords: Chronic subdural hematoma, computed tomography scan control, Evans' index, ventricular seize

Introduction

Chronic subdural hematoma (CSDH), which generally occurs in older patients, is one of the most frequent clinical entities encountered in neurosurgery departments.^[1-3] Treatment of subdural chronic hematoma ranges from simple drainage throughout once or twice burr hole, with or without irrigation, to craniotomy.^[1,2] The burr-hole drainage could be the best modality as the initial treatment for CSDH. Recently, lower recurrence rates using a burr-hole and closed drainage system without irrigation have been reported. The intention of irrigation is to remove the hematoma completely or at least to dilute its content.^[1,3] However, despite clinical improvement after surgery, the early computed tomography (CT) scan control often showed persistence of liquid collection in the subdural space which may discuss the possibility of recurrence or failed surgery. In the aim to study the

variation of intracranial liquid compartment following surgery, we have compared the thickness of residual hematoma and the ventricular size between patients who have an early CT scan control within the 3rd day of surgery and patients who had CT scan control after that.^[4,5]

Methods

In this prospective study (2013–2016), data of sixty-three patients who were operated for CSDH were analyzed. The diagnoses of CSDH were confirmed by CT scans. Surgery involved the drilling of two burr holes on the side of the subdural hematoma and irrigation of the subdural space with normal saline. Subdural drains were all closed systems with no suction for 72 h. Among all patients, the postoperative CT scan controls were performed during the week following evacuation of hematoma. The controlled patients were sequentially allocated to either two groups; Group 1

Abad Cherif El Asri^{1,2},
Mohammed Benzagmout²,
Khalid Chakour²,
Mohamed Faiz Chaoui²,
Jawad Laaguili¹,
Miloudi Gazzaz¹,
Hassan Baallal¹,
Brahim El Mostarchid¹

¹Department of Neurosurgery, Military Hospital, Rabat, ²Department of Neurosurgery, University Hospital Hassan II, Fes, Morocco

Address for correspondence:
Prof. Abad Cherif El Asri,
Department of Neurosurgery,
Military Hospital, Rabat,
Morocco.
E-mail: abad20031@gmail.com

Access this article online

Website: www.asianjns.org

DOI: 10.4103/ajns.AJNS_298_17

Quick Response Code:



How to cite this article: El Asri AC, Benzagmout M, Chakour K, Chaoui MF, Laaguili J, Gazzaz M, et al. Variation of ventricular size after surgical treatment of chronic subdural hematoma. Asian J Neurosurg 2019;14:122-5.

This is an open access journal, and articles are distributed under the terms of the Creative Commons Attribution-NonCommercial-ShareAlike 4.0 License, which allows others to remix, tweak, and build upon the work non-commercially, as long as appropriate credit is given and the new creations are licensed under the identical terms.

For reprints contact: reprints@medknow.com

with CT scan control under the 3rd day of surgery and Group 2 with delayed CT scan control (from 4th to 7th day). Radiological evaluation for cranial CT scan and a high-speed scanner was used. The CT slices were parallel to the orbitomeatal plane, with axial slices from the foramen magnum to the vertex. Linear measure of ventricular size was assessed, by Evans' index as the linear ratio of the total width of the frontal horns of the cerebral lateral ventricles (A) to the maximum inner diameter of the skull at the level of the measurement (E). [Figure 1].^[4] We reviewed and analyzed the data, including clinical presentations, precipitating factors, CT scan findings, and outcomes. The preoperative and postoperative Evans' indexes were compared between the two groups using Mann–Whitney test. All statistical results were established significant if $P < 0.05$. The analysis was performed with the IBM SPSS Statistics for Windows, Version 19.0. (IBM Corp: Armonk, NY).

Results

There were 33 patients in the Group 1 and 30 patients in the Group 2. The mean age in all patients was 62 years [Table 1], 61.7 in Group 1 and 62.4 in Group 2 ($P = 0.54$). There were 53 males and 10 females, and the sex ratio was 30/3 in Group 1 and 23/7 in Group 2 ($P = 0.12$). History of head injury was noted in 23/63, 12/33 in Group 1 and 11/30 in Group 2 ($P = 0.98$). Five patients (2 in Group 1 and 3 in Group 2) have hypertension. Diabetes was observed in 4 patients in Group 2 and no patients in Group 1. Seven patients undertake anticoagulant or antiplatelet treatment (3 patients in Group 1 and 4 patients in Group 2). Nine patients (17%) were admitted with less of the level of consciousness, 6 patients in Group 1 and 3 patients in Group 2 ($P = 0.09$). Neurological deficit was observed in 49 patients (77%); 26 in Group 1 and 23 in Group 2 ($P = 0.84$). Headache

was reported in 45 cases (70%), 24 patients in Group 1 and 21 patients in Group 2 ($P = 81$). Vomiting was noted in 18 cases (28%), 11 patients in Group 1 and 7 in Group 2 ($P = 0.33$). The subdural chronic hematoma was unilateral in 39 cases (62%), 20 cases in Group 1 and 19 in Group 2 ($P = 0.82$).

The average of preoperative hematoma thickness was 20.4 mm [Table 2], 20.5 mm in Group 1 versus 19.9 mm in Group 2, and there was no statistical difference ($P = 0.67$). The mean midline shift was 8.5 mm in each group. The preoperative Evans' index was 26.7 in Group 1 and 27 in Group 2 ($P = 0.7$). Postoperatively, the mean thickness of the residual hematoma was 7.7 mm in Group 1 and 8.4 mm in Group 2 ($P = 0.57$). The mean midline shift was 3.3 mm in Group 1 and 1.9 mm in Group 2 ($P = 0.08$). The postoperative Evans' index was 28.5 in Group 1 and 32.1 in Group 2 ($P = 0.002$). The comparison of preoperative characters between two groups demonstrated no significant difference.

Discussion

The insidious installation of symptoms in patients with CSDH is related to the intracranial components of accommodation induced by progressive accumulation of this hematoma in the subarachnoid space.^[6-8] However, the presence of new mass in the inextended cranium led to the reduction of one or more intracranial components (brain parenchyma, cerebrospinal fluid [CSF], or vascular compartments). The reduction of intracranial CSF depends on diminution of ventricular size and/or subarachnoid spaces.^[1,2,6,9] We have compared the epidemiological,

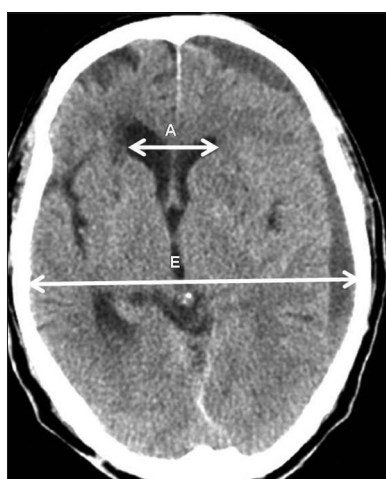


Figure 1: Axial computed tomography scan, demonstrating measurement technique for Evans' index as the linear ratio of the total width of the frontal horns of the cerebral lateral ventricles (A) to the maximum inner diameter of the skull at the level of the measurement (E).

Table 1: Summary of epidemiological and clinical data in our study and comparison of these features between two groups

	All patients (63 patients)	Group 1 (33 patients)	Group 2 (30 patients)	P
Age (years)	62	61.7	62.4	0.54
Sex ratio (male/female)	53/10	30/3	23/7	0.12
Onset of symptoms (days)	19.9	16.72	25.55	0.11
History of head trauma (%)	36.4	36.3	36.6	0.98
Hypertension (%)	7.9	6	10	0.56
Diabetes (%)	6.3	0	13	0.03
Treatment anticoagulation or antiaggregate (%)	11	12.1	10	0.78
Headache (%)	71.4	72.7	70	0.81
Vomiting (%)	28.5	33.3	23.3	0.33
Seizures (%)	3.1	3	3.3	0.94
Motor deficit (%)	77.7	78.7	76.6	0.84
Disturbance of consciousness (%)	14.2	18.1	10	0.09

Table 2: Summary of pre- and postoperative computed tomography scan finding with statistical comparison between two groups

	All patients (63 patients)	Group 1 (33 patients)	Group 2 (30 patients)	P
Bilaterality of the hematoma	24	13	11	0.82
Preoperative thickness of hematoma (mm)	20.44	20.56	19.95	0.67
Volume of hematoma (cm ³)	88.33	94.06	86.25	0.41
Preoperative midline shift (mm)	8.54	8.54	8.53	0.99
Preoperative Evans' index (%)	26.9	26.69	27.03	0.77
Postoperative thickness of hematoma (mm)	8.05	7.73	8.42	0.57
Postoperative volume of hematoma (mm)	23.2	20.15	26.67	0.21
Postoperative midline shift (mm)	2.7	3.37	1.91	0.08
Postoperative Evans' index (%)	30.2	28.58	32.21	0.002

clinical, and preoperative radiological data between two groups and we observed no statistically significant difference. Postoperatively, the thickness of hematoma in all patients was reduced from 20.4 to 8.1 mm, but there was no significant difference between Group 1 and Group 2. This finding demonstrates that some residual collection might take more time to be completely resolved. The midline shift was significantly reduced in both groups compared to preoperative status, but when it was compared between Group 1 and Group 2, the difference was not significant with a *P* value at 0.08. In this study, the Evans' index was used to evaluate the reduction of ventricular size preoperatively, in the immediate postoperative days and within the 1 week of surgery. The Evans' ratio was one of the first attempts to use an index of comparison of ventricular size in patients with large ventricles. It is measured as the ratio of the span of the frontal horn on a pneumogram or a ventriculogram to the maximum width of the skull on an AP film.^[5] With the development of CT scan, the ratio of the frontal horn span to the maximum width of the skull at the level of the frontal horn was developed as the frontal horn index.^[4] In our study, the postoperative Evans' index was 28.5 in Group 1 and 32.1 in Group 2, with a significant difference as *P* = 0.002. We conclude that despite the presence of residual hematoma in early and delayed CT scan control, the expansion of ventricle is progressive and differs between both groups. The evaluation of variation of ventricle size compared to preoperative data might be a good indicator of success of surgery. In this study, we agree that some potential methodological limitations should be noted, such as the strategy of assessing ventricular size. Some authors have argued that Evans' index represent no good measure of ventricular size as the correlation with ventricular volume was low.^[4] There are various strategies of linear measurements of ventricular size. It was advocated that computation of the frontal and occipital horn ratio correlated well with ventricular volume.^[4,10-13] Others have argued that CT-based volumetric measurements in a more sensitive way describe changes in ventricular volume.^[4,10]

Conclusion

According to our finding, postoperative residual hematoma might take more time to be resorpted while the ventricle size shows a remarkable expansion.^[12] Furthermore, the adoption of Evans' index, for assessing the variation of ventricular seize after surgery, by neurosurgeons appears to be a good and simple method for evaluation and following the success of surgical removal of subdural hematoma, despite the observation of some residual collection in early CT scan control.

Financial support and sponsorship

Nil.

Conflicts of interest

There are no conflicts of interest.

References

1. Tsai TH, Lieu AS, Hwang SL, Huang TY, Hwang YF. A comparative study of the patients with bilateral or unilateral chronic subdural hematoma: Precipitating factors and postoperative outcomes. *J Trauma* 2010;68:571-5.
2. Ko BS, Lee JK, Seo BR, Moon SJ, Kim JH, Kim SH. Clinical analysis of risk factors related to recurrent chronic subdural hematoma. *J Korean Neurosurg Soc* 2008;42:11-5.
3. Kwon TH, Park YK, Lim DJ, Cho TH, Chung YG, Chung HS, *et al.* Chronic subdural hematoma: Evaluation of the clinical significance of postoperative drainage volume. *J Neurosurg* 2000;93:796-9.
4. Toma AK, Holl E, Kitchen ND, Watkins LD. Evans' index revisited: The need for an alternative in normal pressure hydrocephalus. *Neurosurgery* 2011;68:939-44.
5. Evans WA Jr. An encephalographic ratio for estimating ventricular enlargement and cerebral atrophy. *Arch Neurol Psychiatry* 1942;47:931-7.
6. Kung WM, Hung KS, Chiu WT, Tsai SH, Lin JW, Wang YC, *et al.* Quantitative assessment of impaired postevacuation brain re-expansion in bilateral chronic subdural haematoma: Possible mechanism of the higher recurrence rate. *Injury* 2012;43:598-602.
7. Okano A, Oya S, Fujisawa N, Tsuchiya T, Indo M, Nakamura T, *et al.* Analysis of risk factors for chronic subdural haematoma

- recurrence after burr hole surgery: Optimal management of patients on antiplatelet therapy. *Br J Neurosurg* 2014;28:204-8.
8. Fukuhara T, Gotoh M, Asari S, Ohmoto T, Akioka T. The relationship between brain surface elastance and brain reexpansion after evacuation of chronic subdural hematoma. *Surg Neurol* 1996;45:570-4.
 9. Gebel JM, Sila CA, Sloan MA, Granger CB, Weisenberger JP, Green CL, *et al.* Comparison of the ABC/2 estimation technique to computer-assisted volumetric analysis of intraparenchymal and subdural hematomas complicating the GUSTO-1 trial. *Stroke* 1998;29:1799-801.
 10. Kolias AG, Coulter IC, Marcus HJ, Gray WP, Brennan PM, Hutchinson PJ, *et al.* Chronic subdural haematoma: How can we improve patient care and outcomes? *Br J Neurosurg* 2014;28:136-7.
 11. Matsumae M, Kikinis R, MR, Mi I, Lorenzo AV, Albert MS, Black PM, *et al.* Intracranial compartment volumes in patients with enlarged ventricles assessed by magnetic resonance-based image processing. *J Neurosurg* 1996;84:972-81.
 12. Adeolu AA, Rabiou TB, Adeleye AO. Post-operative day two versus day seven mobilization after burr-hole drainage of subacute and chronic subdural haematoma in Nigerians. *Br J Neurosurg* 2012;26:743-6.
 13. Anderson RC, Grant JJ, de la Paz R, Frucht S, Goodman RR. Volumetric measurements in the detection of reduced ventricular volume in patients with normal-pressure hydrocephalus whose clinical condition improved after ventriculoperitoneal shunt placement. *J Neurosurg* 2002;97:73-9.