

# Magnetic resonance imaging in heart failure, including coronary imaging: numbers, facts, and challenges

Lisa Adams<sup>1</sup>, Michel Noutsias<sup>2</sup>, Boris Bigalke<sup>3</sup> and Marcus R. Makowski<sup>1,4</sup>

<sup>1</sup>Klinik für Radiologie, Charité – Universitätsmedizin Berlin, Campus Mitte, Charitéplatz 1, D -10117, Berlin, Germany; <sup>2</sup>Department of Internal Medicine I, Division of Cardiology, Pneumology, Angiology and Intensive Medical Care, University Hospital Jena, Friedrich Schiller University Jena, Jena, Germany; <sup>3</sup>Klinik für Kardiologie, Charité – Universitätsmedizin Berlin, Campus Benjamin Franklin, Berlin, Germany; <sup>4</sup>Division of Imaging Sciences and Biomedical Engineering, King's College London, London, UK

## Abstract

Coronary artery disease (CAD) is a major risk factor for the incidence and progression of heart failure (HF). HF is characterized by a substantial morbidity and mortality and its lifetime risk is estimated at approximately 20% for men and women. As patients are in most cases identified only after developing overt clinical symptoms, detecting early stages of CAD and HF is of paramount importance. Due to its non-invasiveness, excellent soft-tissue contrast, high spatial resolution, and multiparametric nature, cardiovascular magnetic resonance (CMR) imaging has emerged as a promising radiation-free technique to assess a wide range of cardiovascular diseases such as CAD or HF, enabling a comprehensive evaluation of myocardial anatomy, regional and global function, and viability with the additional benefit of *in vivo* tissue characterization. CMR has the potential to enhance our understanding of coronary atherosclerosis and the aetiology of HF on functional and biological levels, to identify patients at risk for CAD or HF, and to enable individualized patient management and improved outcomes. Even though larger-scale studies on the different applications of CMR for the assessment of heart failure are scarce, recent research highlighted new possible clinical applications for CMR in the evaluation of CAD and HF.

\*Correspondence to: Marcus Makowski, Department of Radiology, Charité – Universitätsmedizin Berlin, Campus Mitte, Charitéplatz 1, D-10117 Berlin, Germany. Tel: +49(0)30450627345; Fax: +49(0)304507527911. Email: marcus.makowski@charite.de

## Introduction

Coronary artery disease (CAD) is the most common cause of heart failure (HF) and the leading cause of death and disability in both developed and developing countries, accounting for >17 million deaths per year.<sup>2,3</sup> HF has a mortality of up to 50% within 5 years and is associated with an additional substantial socio-economic burden.<sup>4</sup> Despite the advances in diagnostics and treatments over the past decades, acute cardiovascular events remain unpredictable and are often the first manifestation of underlying coronary atherosclerosis.<sup>5</sup> Plaque assessment provides a powerful diagnostic information on the probability of individual cardiac events, having the potential of modulating and maybe even preventing early stages of coronary atherosclerosis.<sup>6</sup>

HF, which often is the consequence of CAD but can also evolve from non-ischaemic origin, is a clinical syndrome referring to the inability of the heart to fill or eject blood.<sup>7,8</sup> It can be differentiated between clinical presentations with reduced left ventricular ejection fraction ( $\leq 40\%$ ; HFrEF), with

preserved ejection fraction (LVEF >50%; HFpEF), and with mid-range ejection fraction (40–49%, HFmrEF).<sup>4,8</sup> Since patients are currently only identified, when they already have clinical symptoms, detecting early stages of HF is of paramount importance.

Due to its non-invasiveness, excellent soft-tissue contrast, high spatial resolution, and multiparametric nature, cardiovascular magnetic resonance (CMR) has emerged as a promising radiation-free technique to assess a wide range of cardiovascular diseases such as CAD or HF.<sup>9</sup> It enables a comprehensive evaluation of myocardial anatomy, regional and global function, and viability with the additional benefit of *in vivo* tissue characterization,<sup>10,11</sup> providing information about acute tissue injury such as oedema or necrosis and myocardial perfusion deficits, and can also be used to predict the necessity of revascularization in patients with suspected CAD.<sup>12,13</sup> In non-ischaemic HF, CMR enables the assessment of fibrosis, infiltration, and iron overload. Up to now, computed tomography (CT) is the modality of choice for the assessment of CAD. CMR plays a central role in the diagnosis

of HF such as in the assessment of ventricular global and regional dysfunction, the visualization of injured myocardium and its transmural extent,<sup>13</sup> or the evaluation of the underlying aetiology, and provides insights into disease progression.<sup>14</sup> CMR techniques might not only enhance our understanding of the pathophysiology of coronary plaque formation and of the aetiology of dysfunction in HF, but also improve individual risk assessment, and they guide therapeutic interventions in individuals at highest risk for acute cardiovascular events and chronic HF.<sup>15,16</sup>

This editorial focuses on the current knowledge, challenges, and future prospects for CMR in imaging HF and coronary atherosclerosis.

## Numbers

CAD is a leading cause of death, leading to ~20% of deaths in the European Union and accounting for one in every seven deaths in the USA.<sup>17,18</sup> The lifetime risk of developing HF is estimated at ~20% for men and women,<sup>1</sup> and HF is also characterized by substantial morbidity and mortality. Timely diagnosis and effective management of CAD and HF are, therefore, of high importance. In recent years, magnetic resonance imaging (MRI) and CT have emerged as the most promising non-invasive imaging techniques in the primary diagnosis of CAD and HF. While a meta-analysis published in 2010 suggested that CT was superior to MRI, recent studies directly comparing CT and MRI or X-ray coronary angiography and MRI indicated that there was no significant difference when assessing presence or absence of >50% coronary artery stenosis.<sup>19–22</sup> For the visualization of myocardial ischaemia in HF, CMR was demonstrated to be superior to single-photon emission CT in a large prospective trial with

752 recruited patients.<sup>9</sup> The establishment of T1, T2, and T2\* mapping sequences provides a unique possibility to characterize myocardial tissue and also to determine the aetiology of non-ischaemic causes of HF.<sup>23</sup>

To date, larger-scale studies on the different applications of CMR for the assessment of HF are scarce (*Table 1*). In a study published in 2015, Bohnen *et al.* demonstrated that CMR T2 mapping enables a more accurate assessment of active myocarditis in patients with recent-onset HF with a sensitivity of 94%.<sup>24</sup> For HFpEF, a recent study by Dusch *et al.* including 80 patients who were subjected to CMR within 6 months after transthoracic echocardiography showed that diastolic dysfunction may be reliably identified by CMR by the use of midwall longitudinal fractional shortening as a correlate for long-axis systolic function.<sup>25</sup> Another recent study by Rommel *et al.*<sup>26</sup> found that CMR T1 mapping can reliably quantify diffuse myocardial fibrosis as extracellular volume fraction, which can be used as a reliable predictor of left ventricular stiffness ( $\beta = 0.75$ ;  $P < 0.01$ ).

The treatment of HF also depends on the underlying cause of the disease.<sup>27</sup> To differentiate, if HF is related to CAD, coronary angiography is routinely performed at many centres. McCrohon *et al.* demonstrated in 90 patients and 15 control subjects (0% vs. 100% enhancement) that gadolinium-enhanced CMR enables a reliable non-invasive differentiation between HF related to dilated cardiomyopathy and HF resulting from CAD.<sup>27</sup> Furthermore, they calculated that 13% of the patients would have received an incorrect diagnosis of dilated cardiomyopathy if they had not received CMR.<sup>27</sup>

With regard to a comparison of echocardiography, radionuclide ventriculography, and CMR, Bellenger *et al.* examined 52 patients and concluded that CMR should be the preferred technique for the estimation of volume and ejection fraction in HF patients.<sup>28</sup>

**Table 1** Selected studies investigating the assessment of different types and characteristics of heart failure with magnetic resonance imaging

Type of heart failure	Study	Patients	Main findings
Recent-onset heart failure with active myocarditis	Bohnen <i>et al.</i> 2015 <sup>24</sup>	31	Cardiovascular magnetic resonance (CMR) T2 mapping enables a more accurate assessment of active myocarditis with a sensitivity of 94%
Diastolic heart failure	Dusch <i>et al.</i> 2014 <sup>25</sup>	80	Transthoracic echocardiography-evidenced diastolic dysfunction can be reliably identified by CMR with use of midwall longitudinal fractional shortening
Heart failure with preserved ejection fraction	Rommel <i>et al.</i> 2016 <sup>26</sup>	24	CMR T1 mapping can correctly assess myocardial fibrosis, which independently predicts invasively measured stiffness of the left ventricle
Differentiation of heart failure related to dilated cardiomyopathy or coronary artery disease	McCrohon <i>et al.</i> 2003 <sup>27</sup>	90	Contrast-enhanced CMR enables a differentiation of heart failure related to dilated cardiomyopathy and coronary artery disease
Comparison of ejection fraction measurements in patients with heart failure using different modalities (echocardiography, radionuclide ventriculography, and CMR)	Bellenger <i>et al.</i> 2000 <sup>28</sup>	52	CMR is the preferred technique for volume and ejection fraction estimation in heart failure patients

## Facts

Typically, CAD occurs when the coronary arteries develop atherosclerosis. Atherosclerotic lesions can cause progressive vascular remodelling, which may result in sudden plaque rupture. While atherosclerotic lesions with a low-risk of rupture are linked to a thick fibrotic cap and a high proportion of fibrotic tissue, plaques that rupture often show a thin fibrous cap, a necrotic core, positive remodelling, inflammation, angiogenesis, and plaque haemorrhage.<sup>15</sup> The identification of such vulnerable plaques can help in identifying patients with an active state of disease who are at an increased risk of acute cardiovascular events.<sup>29</sup> Due to its superior soft-tissue contrast, CMR has the potential to provide detailed imaging of the coronary vessel wall.

type 1 diabetes, and hyper-IgE syndrome and in an asymptomatic multiethnic population cohort.<sup>29–34</sup> A recent study investigating 568 stable patients demonstrated a significantly higher risk of adverse cardiac events for patients with high-intensity coronary plaques on T1-weighted images (26% vs. 3%).<sup>29</sup> More recent advances have led to the development of targeted contrast agents, aimed at cell surface receptors or proteins. Fibrin and elastin represent an essential component of atherosclerotic plaques, play a key role during their development and progression, and have already been established as promising targets.<sup>35–37</sup> With targeted molecular probes, contrast-enhanced CMR can visualize and quantify proteins and cells of the atherosclerotic vessel wall, which, given clinical translation is successful, may improve assessment of vulnerable plaques and allow for better-tailored invasive and non-invasive therapies (Figure 1).

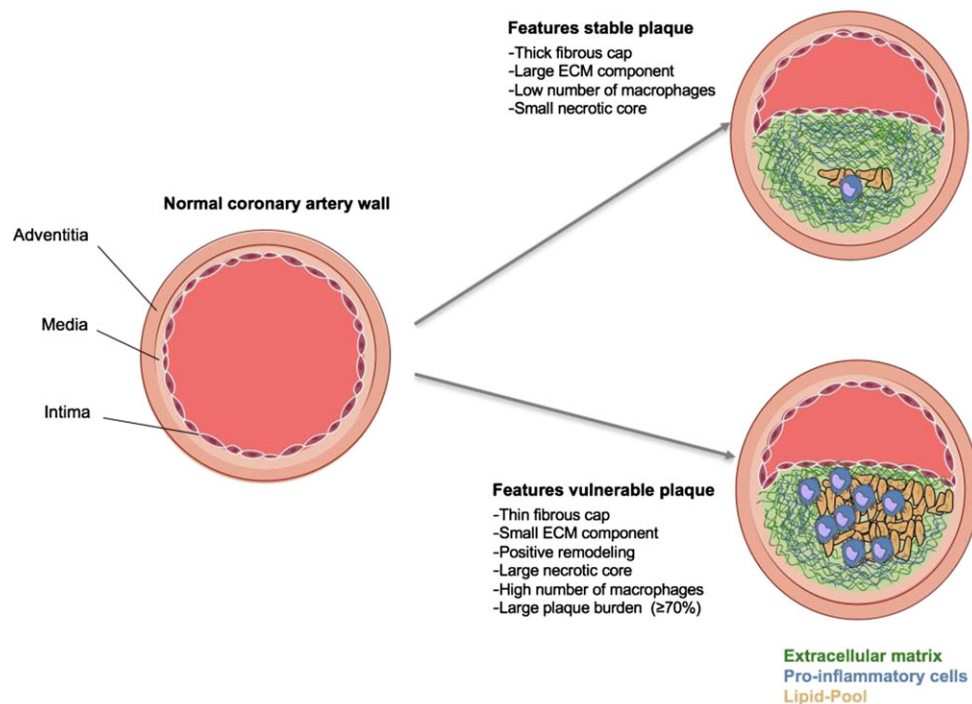
### Plaque assessment with non-contrast-enhanced and contrast-enhanced magnetic resonance imaging

With non-contrast-enhanced MRI, direct assessment of the coronary vessel wall, remodelling, and plaque instability have been demonstrated in patients with subclinical or stable CAD,

### Heart failure with reduced ejection fraction

Evaluation of cardiomyopathy with reduced ejection fraction by CMR is usually performed through a pharmacologic stress test, whereby information on wall motion, rest and stress myocardial perfusion, and delayed gadolinium enhancement are collected.<sup>38</sup> Apart from diagnosing ischaemia, CMR stress

**Figure 1** Schematic drawing of the features of stable and vulnerable plaques in the coronary arteries. The rupture of coronary plaques can result in the development of heart failure. Recognized features of the stable plaque include a thick fibrous cap, a relatively large extracellular matrix (ECM), a low number of macrophages, and a small necrotic core. The vulnerable plaque shows a thin fibrous cap, a small ECM component, positive remodelling, a high number of macrophages, and a large plaque burden. The ECM is marked by the colour green, pro-inflammatory cells are blue, and the lipid core is shown in yellow. Adapted from Makowski *et al.*<sup>44</sup>



test results have been demonstrated to provide accurate estimates of cardiovascular prognosis.<sup>39</sup> For example, Steel *et al.* showed the prognostic implication and usefulness of stress CMR myocardial perfusion and late gadolinium enhancement in a population of 254 patients, whereby patients with neither perfusion deficits nor late gadolinium enhancement had a 98.1% negative annual event rate for death and myocardial infarction.<sup>40</sup>

### Heart failure with preserved ejection fraction

Approximately half of HF patients have abnormalities in diastolic function with preserved LVEF.<sup>41</sup> Even though transthoracic echocardiography is currently the modality of choice for the diagnosis of diastolic dysfunction, this method is prone to relatively poor acoustic windows, a limited field of view, calculation errors relative to flow direction, and inferior spatial resolution.<sup>42</sup>

Another common cause of HFpEF is cardiac hypertrophy. By use of CMR, important information on wall thickness and location of asymmetric hypertrophy can be obtained, and it is also useful in distinguishing HF linked to hypertensive heart disease from hypertrophic cardiomyopathy. Based on CMR, Maron *et al.* identified mitral valve abnormalities such as elongation of mitral valve leaflets as a new biomarker for assessment of hypertrophic cardiomyopathy.<sup>43</sup>

### Challenges

CMR of coronary arteries has several advantages over CT, showing a superior soft-tissue contrast for the visualization of plaque morphology, not being affected by calcium blooming, and most importantly not involving ionizing radiation, which add to its attractiveness as a screening tool.<sup>15</sup> However, there are still technical challenges regarding cardiac motion

and spatial resolution, as the heart shows a rapid movement with the cardiac and breathing cycle. With its relatively long scanning and acquisition times, these requirements are especially challenging for CMR. The development and validation of new CMR techniques, for example, for quantification of fibrosis, plaque characterization, and CMR-targeted intervention, represent the leading research challenges for the future. From a clinical perspective, another important challenge is to increase the availability of the modality for patients.

### Outlook

CMR has made great advances in the past decade, with a significant reduction in imaging time, and holds the promise as a non-invasive and radiation-free multifaceted assessment of coronary atherosclerosis and HF with information on disease activity and prognosis. Especially with regard to the evaluation of HF patients, it is expected that the applications of CMR will expand rapidly. New techniques aiming at the identification and quantification of diffuse fibrosis will improve the *in vivo* assessment of pathology, novel contrast agents will enable to target specific tissue types for both diagnosis and treatment, and interventional CMR will open up guidance of therapeutic procedures.<sup>14</sup> CMR has the potential to enhance our understanding of coronary atherosclerosis and HF on functional and biological levels, to identify patients at risk for heart disease, and to enable individualized patient management and improved outcomes.

### Conflict of interest

None declared.

### References

- Lloyd-Jones DM, Larson MG, Leip EP, Beiser A, D'Agostino RB, Kannel WB, Murabito JM, Vasan RS, Benjamin EJ, Levy D, Framingham HS. Lifetime risk for developing congestive heart failure: the Framingham Heart Study. *Circulation* 2002; **106**: 3068–3072.
- Roth GA, Huffman MD, Moran AE, Feigin V, Mensah GA, Naghavi M, Murray CJ. Global and regional patterns in cardiovascular mortality from 1990 to 2013. *Circulation* 2015; **132**: 1667–1678.
- Mortality GBD, Causes of Death C. Global, regional, and national life expectancy, all-cause mortality, and cause-specific mortality for 249 causes of death, 1980–2015: a systematic analysis for the Global Burden of Disease Study 2015. *Lancet* 2016; **388**: 1459–1544.
- Yancy CW, Jessup M, Bozkurt B, Butler J, Casey DE Jr, Drazner MH, Fonarow GC, Geraci SA, Horwich T, Januzzi JL, Johnson MR, Kasper EK, Levy WC, Masoudi FA, McBride PE, McMurray JJ, Mitchell JE, Peterson PN, Riegel B, Sam F, Stevenson LW, Tang WH, Tsai EJ, Wilkoff BL, American College of Cardiology F, American Heart Association Task Force on Practice G. ACCF/AHA guideline for the management of heart failure: a report of the American College of Cardiology Foundation/American Heart Association Task Force on Practice Guidelines. *J Am Coll Cardiol* 2013; **62**: e147–e239.
- Libby P, Ridker PM, Hansson GK. Progress and challenges in translating the biology of atherosclerosis. *Nature* 2011; **473**: 317–325.
- Suzuki M, Saito M, Nagai T, Saeki H, Kazatani Y. Prevention of positive coronary artery remodeling with statin therapy in patients with coronary artery diseases. *Angiology* 2006; **57**: 259–265.
- Hunt SA. American College of C, American Heart Association Task Force on Practice G. ACC/AHA 2005 guideline update for the diagnosis and management of chronic heart failure in the adult: a report of the American College of

- Cardiology/American Heart Association Task Force on Practice Guidelines (Writing Committee to Update the 2001 Guidelines for the Evaluation and Management of Heart Failure). *J Am Coll Cardiol* 2005; **46**: e1–e82.
8. Ponikowski P, Voors AA, Anker SD, Bueno H, Cleland JG, Coats AJ, Falk V, Gonzalez-Juanatey JR, Harjola VP, Jankowska EA, Jessup M, Linde C, Nihoyannopoulos P, Parissis JT, Pieske B, Riley JP, Rosano GM, Ruilope LM, Ruschitzka F, Rutten FH, van der Meer P, Authors/Task Force M. ESC Guidelines for the diagnosis and treatment of acute and chronic heart failure: the Task Force for the diagnosis and treatment of acute and chronic heart failure of the European Society of Cardiology (ESC). Developed with the special contribution of the Heart Failure Association (HFA) of the ESC. *Eur Heart J* 2016; **37**: 2129–2200.
  9. Greenwood JP, Herzog BA, Brown JM, Everett CC, Plein S. Cardiovascular magnetic resonance and single-photon emission computed tomography in suspected coronary heart disease. *Ann Intern Med* 2016; **165**: 830–831.
  10. Lota AS, Gatehouse PD, Mohiaddin RH. T2 mapping and T2\* imaging in heart failure. *Heart Fail Rev* 2017; **22**: 431–440.
  11. Kempny A, Fernandez-Jimenez R, Orwat S, Schuler P, Bunck AC, Maintz D, Baumgartner H, Diller GP. Quantification of biventricular myocardial function using cardiac magnetic resonance feature tracking, endocardial border delineation and echocardiographic speckle tracking in patients with repaired tetralogy of Fallot and healthy controls. *J Cardiovasc Magn Reson* 2012; **14**: 32.
  12. Bernhardt P, Engels T, Levenson B, Haase K, Albrecht A, Strohm O. Prediction of necessity for coronary artery revascularization by adenosine contrast-enhanced magnetic resonance imaging. *Int J Cardiol* 2006; **112**: 184–190.
  13. Kim RJ, Wu E, Rafael A, Chen EL, Parker MA, Simonetti O, Klocke FJ, Bonow RO, Judd RM. The use of contrast-enhanced magnetic resonance imaging to identify reversible myocardial dysfunction. *N Engl J Med* 2000; **343**: 1445–1453.
  14. Karamitsos TD, Francis JM, Myerson S, Selvanayagam JB, Neubauer S. The role of cardiovascular magnetic resonance imaging in heart failure. *J Am Coll Cardiol* 2009; **54**: 1407–1424.
  15. Dweck MR, Williams MC, Moss AJ, Newby DE, Fayad ZA. Computed tomography and cardiac magnetic resonance in ischemic heart disease. *J Am Coll Cardiol* 2016; **68**: 2201–2216.
  16. Ehara S, Matsumoto K, Shimada K. The clinical value of high-intensity signals on the coronary atherosclerotic plaques: noncontrast T1-weighted magnetic resonance imaging. *Int J Mol Sci* 2016; **17**: 1187.
  17. Townsend N, Nichols M, Scarborough P, Rayner M. Cardiovascular disease in Europe—epidemiological update 2015. *Eur Heart J* 2015; **36**: 2696–2705.
  18. Writing Group M, Mozaffarian D, Benjamin EJ, Go AS, Arnett DK, Blaha MJ, Cushman M, Das SR, de Ferranti S, Despres JP, Fullerton HJ, Howard VJ, Huffman MD, Isasi CR, Jimenez MC, Judd SE, Kissela BM, Lichtman JH, Lisabeth LD, Liu S, Mackey RH, Magid DJ, McGuire DK, Mohler ER 3rd, Moy CS, Muntner P, Mussolino ME, Nasir K, Neumar RW, Nichol G, Palaniappan L, Pandey DK, Reeves MJ, Rodriguez CJ, Rosamond W, Sorlie PD, Stein J, Towfighi A, Turan TN, Virani SS, Woo D, Yeh RW, Turner MB, American Heart Association Statistics C, Stroke Statistics S. Heart disease and stroke statistics—2016 update: a report from the American Heart Association. *Circulation* 2016; **133**: e38–e360.
  19. Yonezawa M, Nagata M, Kitagawa K, Kato S, Yoon Y, Nakajima H, Nakamori S, Sakuma H, Hatakenaka M, Honda H. Quantitative analysis of 1.5-T whole-heart coronary MR angiograms obtained with 32-channel cardiac coils: a comparison with conventional quantitative coronary angiography. *Radiology* 2014; **271**: 356–364.
  20. Yang Q, Li K, Liu X, Bi X, Liu Z, An J, Zhang A, Jerecic R, Li D. Contrast-enhanced whole-heart coronary magnetic resonance angiography at 3.0-T: a comparative study with X-ray angiography in a single center. *J Am Coll Cardiol* 2009; **54**: 69–76.
  21. Hamdan A, Asbach P, Wellnhofer E, Klein C, Gebker R, Kelle S, Kilian H, Huppertz A, Fleck E. A prospective study for comparison of MR and CT imaging for detection of coronary artery stenosis. *JACC Cardiovasc Imaging* 2011; **4**: 50–61.
  22. Schuetz GM, Zacharopoulou NM, Schlattmann P, Dewey M. Meta-analysis: noninvasive coronary angiography using computed tomography versus magnetic resonance imaging. *Ann Intern Med* 2010; **152**: 167–177.
  23. Thavendiranathan P, Walls M, Giri S, Verhaert D, Rajagopalan S, Moore S, Simonetti OP, Raman SV. Improved detection of myocardial involvement in acute inflammatory cardiomyopathies using T2 mapping. *Circ Cardiovasc Imaging* 2012; **5**: 102–110.
  24. Bohnen S, Radunski UK, Lund GK, Kandolf R, Stehning C, Schnackenburg B, Adam G, Blankenberg S, Muellerleile K. Performance of T1 and T2 mapping cardiovascular magnetic resonance to detect active myocarditis in patients with recent-onset heart failure. *Circ Cardiovasc Imaging* 2015; **8**: e003073.
  25. Dusch MN, Thadani SR, Dhillion GS, Hope MD. Diastolic function assessed by cardiac MRI using longitudinal left ventricular fractional shortening. *Clin Imaging* 2014; **38**: 666–668.
  26. Rommel KP, von Roeder M, Latuscynski K, Oberueck C, Blazek S, Fengler K, Besler C, Sandri M, Lucke C, Gutberlet M, Linke A, Schuler G, Lurz P. Extracellular volume fraction for characterization of patients with heart failure and preserved ejection fraction. *J Am Coll Cardiol* 2016; **67**: 1815–1825.
  27. McCrohon JA, Moon JC, Prasad SK, McKenna WJ, Lorenz CH, Coats AJ, Pennell DJ. Differentiation of heart failure related to dilated cardiomyopathy and coronary artery disease using gadolinium-enhanced cardiovascular magnetic resonance. *Circulation* 2003; **108**: 54–59.
  28. Bellenger NG, Burgess MI, Ray SG, Lahiri A, Coats AJ, Cleland JG, Pennell DJ. Comparison of left ventricular ejection fraction and volumes in heart failure by echocardiography, radionuclide ventriculography and cardiovascular magnetic resonance; are they interchangeable? *Eur Heart J* 2000; **21**: 1387–1396.
  29. Asaumi Y, Noguchi T, Morita Y, Fujiwara R, Kanaya T, Matsuyama TA, Kawasaki T, Fujino M, Yamane T, Nagai T, Miyagi T, Ishibashi-Ueda H, Higashi M, Komori Y, Ishihara M, Ogawa H, Yasuda S. High-intensity plaques on noncontrast T1-weighted imaging as a predictor of periprocedural myocardial injury. *JACC Cardiovasc Imaging* 2015; **8**: 741–743.
  30. Abd-Elmoniem KZ, Ramos N, Yazdani SK, Ghanem AM, Holland SM, Freeman AF, Gharib AM. Coronary atherosclerosis and dilation in hyper IgE syndrome patients: depiction by magnetic resonance vessel wall imaging and pathological correlation. *Atherosclerosis* 2017; **258**: 20–25.
  31. Jahnke C, Manka R, Kozerke S, Schnackenburg B, Gebker R, Marx N, Paetsch I. Cardiovascular magnetic resonance profiling of coronary atherosclerosis: vessel wall remodelling and related myocardial blood flow alterations. *Eur Heart J Cardiovasc Imaging* 2014; **15**: 1400–1410.
  32. Miao C, Chen S, Macedo R, Lai S, Liu K, Li D, Wasserman BA, Vogel-Clausen J, Lima JA, Bluemke DA. Positive remodeling of the coronary arteries detected by magnetic resonance imaging in an asymptomatic population: MESA (Multi-Ethnic Study of Atherosclerosis). *J Am Coll Cardiol* 2009; **53**: 1708–1715.
  33. Kim WY, Astrup AS, Stuber M, Tarnow L, Falk E, Botnar RM, Simonsen C, Pietraszek L, Hansen PR, Manning WJ, Andersen NT, Parving H-H. Subclinical coronary and aortic atherosclerosis detected by magnetic resonance imaging in type 1 diabetes with and without diabetic nephropathy. *Circulation* 2007; **115**: 228–235.
  34. Ibrahim T, Makowski MR, Jankauskas A, Maintz D, Karch M, Schachoff S, Manning WJ, Schomig A, Schwaiger M, Botnar RM. Serial contrast-enhanced cardiac magnetic resonance imaging demonstrates regression of hyperenhancement within the coronary artery wall in patients after acute myocardial infarction.

- JACC Cardiovasc Imaging* 2009; **2**: 580–588.
35. Tavora F, Cresswell N, Li L, Ripple M, Burke A. Immunolocalisation of fibrin in coronary atherosclerosis: implications for necrotic core development. *Pathology* 2010; **42**: 15–22.
  36. Botnar RM, Perez AS, Witte S, Wiethoff AJ, Laredo J, Hamilton J, Quist W, Parsons EC Jr, Vaidya A, Kolodziej A, Barrett JA, Graham PB, Weisskoff RM, Manning WJ, Johnstone MT. In vivo molecular imaging of acute and subacute thrombosis using a fibrin-binding magnetic resonance imaging contrast agent. *Circulation* 2004; **109**: 2023–2029.
  37. Spuentrup E, Botnar RM, Wiethoff A, Ibrahim T, Sebastin K, Katho M, Oezgun M, Nagel E, Vymazal J, Graham P, Guenther R, Maintz D. MR imaging of thrombi using EP-2104R, a fibrin specific contrast agent: initial results in patients. *Eur Radiol* 2008; **18**: 1995–2005.
  38. Stacey RB, Hundley WG. The role of cardiovascular magnetic resonance (CMR) and computed tomography (CCT) in facilitating heart failure management. *Curr Treat Options Cardiovasc Med* 2013; **15**: 373–386.
  39. Hundley WG, Morgan TM, Neagle CM, Hamilton CA, Rerkpattanapipat P, Link KM. Magnetic resonance imaging determination of cardiac prognosis. *Circulation* 2002; **106**: 2328–2333.
  40. Steel K, Broderick R, Gandla V, Larose E, Resnic F, Jerosch-Herold M, Brown KA, Kwong RY. Complementary prognostic values of stress myocardial perfusion and late gadolinium enhancement imaging by cardiac magnetic resonance in patients with known or suspected coronary artery disease. *Circulation* 2009; **120**: 1390–1400.
  41. Wang J, Nagueh SF. Current perspectives on cardiac function in patients with diastolic heart failure. *Circulation* 2009; **119**: 1146–1157.
  42. Leong DP, De Pasquale CG, Selvanayagam JB. Heart failure with normal ejection fraction: the complementary roles of echocardiography and CMR imaging. *JACC Cardiovasc Imaging* 2010; **3**: 409–420.
  43. Maron MS, Olivetto I, Harrigan C, Appelbaum E, Gibson CM, Lesser JR, Haas TS, Udelson JE, Manning WJ, Maron BJ. Mitral valve abnormalities identified by cardiovascular magnetic resonance represent a primary phenotypic expression of hypertrophic cardiomyopathy. *Circulation* 2011; **124**: 40–47.
  44. Makowski MR, Henningsson M, Spuentrup E, Kim WY, Maintz D, Manning WJ, Botnar RM. Characterization of coronary atherosclerosis by magnetic resonance imaging. *Circulation* 2013; **128**: 1244–1255.