

Through-the-scope clip retention rates and performance in a porcine model



Authors

Jad AbiMansour¹, Shunsuke Kamba¹, Louis-Michel Wong Kee Song¹, Elizabeth Rajan¹

Institutions

1 Gastroenterology and Hepatology, Mayo Clinic, Rochester, United States

Key words

Endoscopic resection (ESD, EMRc, ...), Endoscopic resection (polypectomy, ESD, EMRc, ...), Non-variceal bleeding

received 16.9.2023

accepted after revision 17.11.2023

accepted manuscript online 04.12.2023

Bibliography

Endosc Int Open 2024; 12: E52–E56

DOI 10.1055/a-2221-7908

ISSN 2364-3722

© 2024. The Author(s).

This is an open access article published by Thieme under the terms of the Creative Commons Attribution-NonDerivative-NonCommercial License, permitting copying and reproduction so long as the original work is given appropriate credit. Contents may not be used for commercial purposes, or adapted, remixed, transformed or built upon. (<https://creativecommons.org/licenses/by-nc-nd/4.0/>)

Georg Thieme Verlag KG, Rüdigerstraße 14, 70469 Stuttgart, Germany

Corresponding author

Dr. Jad AbiMansour, Mayo Clinic, Gastroenterology and Hepatology, Rochester, United States
jadabiman@gmail.com

ABSTRACT

Background and study aims Limited comparative data exist to guide optimal through-the-scope (TTS) clip selection. The aim of this study was to compare the efficacy, retention, and safety of three industry-leading TTS clips on tissue that mimics common clinical scenarios.

Methods A survival study involving six domestic pigs was undertaken. Three commonly used clip models were selected: Assurance (STERIS, Mentor, Ohio, United States), Resolution (Boston Scientific, Boston, Massachusetts, United States), and SureClip (Micro-Tech, Ann Arbor, Michigan, United States). To mimic clinical practice, the following scenarios were assessed: (1) normal mucosa; (2) cold snare resection; and (3) hot mucosal resection simulating fibrotic ulcers. Deployment of clips was randomized to target sites. Repeat endoscopy was performed 2 weeks following placement. Endoscopists rated the ease of use of clip placement on a Likert scale of 1 to 5.

Results Fifty-four clips (18 Assurance, 18 Resolution, and 18 SureClip) were placed in six pigs. Mucosal healing was noted at all sites on follow up. Overall retention was nine of 18 (50.0%) SureClip, 10 of 18 (55.6%) Assurance, and 13 of 18 (72.2%) Resolution ($P=0.369$). There was no difference in clip retention on normal and cold snare resection sites; however, clip retention was significantly higher for Resolution clips on fibrotic ulcers (50.0% versus 0% for Assurance and 0% SureClip, $P=0.03$). No adverse events were reported. Ease of use was equivalent across all models.

Conclusions All clips were equivalent in efficacy and safety with successful clip deployment and mucosal healing. Overall retention rate was low for fibrotic tissue, with an improved retention rate observed with Resolution clips.

Introduction

The first clips for flexible endoscopy were developed more than 30 years ago for hemostasis [1]. Since then, through-the-scope (TTS) clips have evolved with increasing indications for use. Initial clip designs faced challenges regarding ease of use, positioning, deployment, and retention.

Several brands of TTS clips are currently available on the market [2]. Clip configuration is largely preserved across the

different clip models. However, technical variations exist, including the jaw span of an open clip, shape of distal prongs, length of clip arms, rotatability, ability to re-open and close the clip to facilitate repositioning, and handle-related deployment maneuvers. These design variables can impact clip functionality [3]. There are limited data to guide optimal clip selection and current practice is largely driven by operator preference and institutional supply chains.

The aim of this comparative study was to assess the efficacy, retention rate, and safety of three industry-leading TTS clips on tissue that mimics the most common scenarios faced in clinical practice.

Methods

Study design

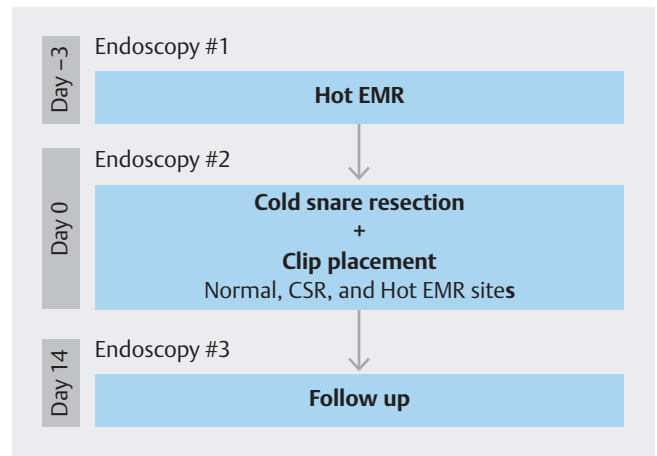
A preclinical study was performed using six domestic pigs (weight 35–40 kg). All experiments followed the American Association for Laboratory Animal Science guidelines [4], and the study protocol was approved by the Institutional Animal Care and Use Committee (IACUC # A00006854–22) of Mayo Clinic. The three TTS clip models used in the study were: Assurance (STERIS Endoscopy, Mentor, Ohio, United States), Resolution (Boston Scientific, Boston, Massachusetts, United States), and SureClip (Micro-Tech Endoscopy, Ann Arbor, Michigan, United States). These commercially available devices are approved for use in hemostasis, supplemental closure of luminal perforations, endoscopic marking and anchoring of jejunal feeding tubes.

Procedures

Each animal underwent three upper endoscopy procedures, including lesion creation (Day -3), clip deployment (Day 0) and follow up (Day 14) (► Fig. 1). Prior to each endoscopy, animals were maintained on a liquid diet for 48 hours, including a clear liquid diet 24 hours prior to the procedure. All procedures were performed under general anesthesia and orotracheal intubation.

Lesion creation

Hot endoscopic mucosal resection (EMR) was performed 72 hours prior to clip deployment to simulate fibrotic ulcers. Three lesions were created in a linear fashion using the band ligation EMR technique along the greater curvature of the gastric body in each animal. A mixture of 0.9% saline and dilute epinephrine (1:100,000) was injected into the submucosa. An upper endoscope (GIF-H180, Olympus, Tokyo, Japan) was fitted with a band ligator device (SmartBand, STERIS Endoscopy, Mentor,



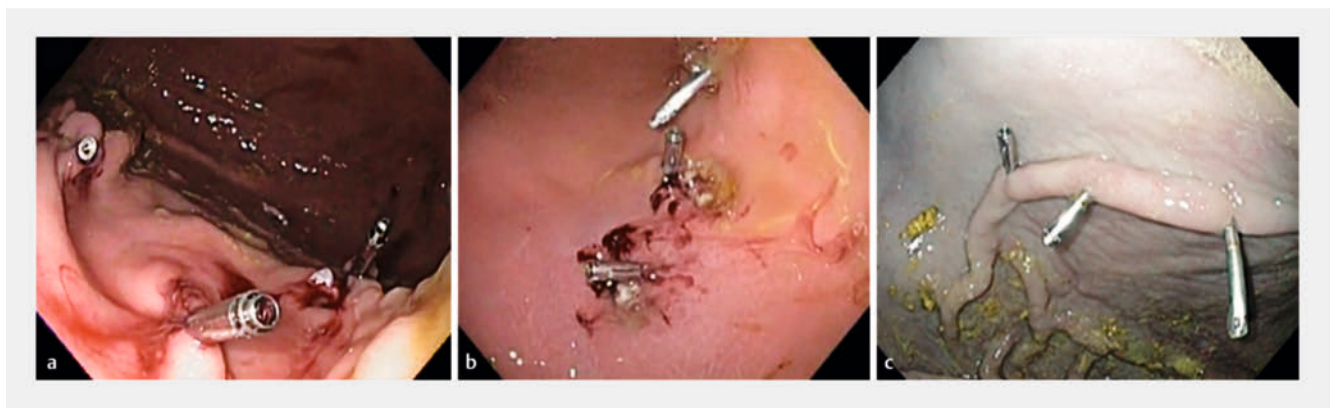► Fig. 1 Study design.

OH) and the target mucosa suctioned into the cap followed by deployment of a single band. The pseudopolyp was resected underneath the band using a 10-mm hot snare (Lariat Snare, STERIS Endoscopy, Mentor, Ohio, United States) using pulse cut current at 40 watts (Genii, STERIS Endoscopy, Mentor, Ohio, United States).

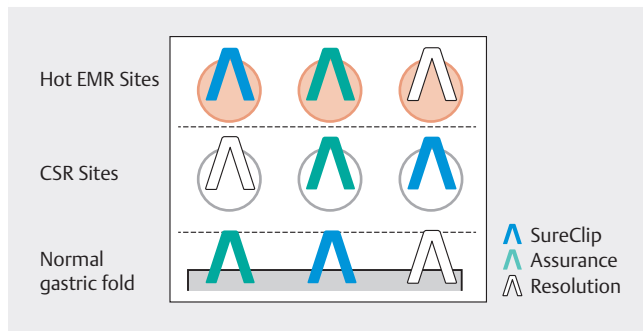
On the day of clip deployment, standard cold snare mucosal resection was performed in the gastric body of each animal using a 10-mm cold snare (Lariat Snare, STERIS Endoscopy, Mentor, Ohio, United States).

Clip placement

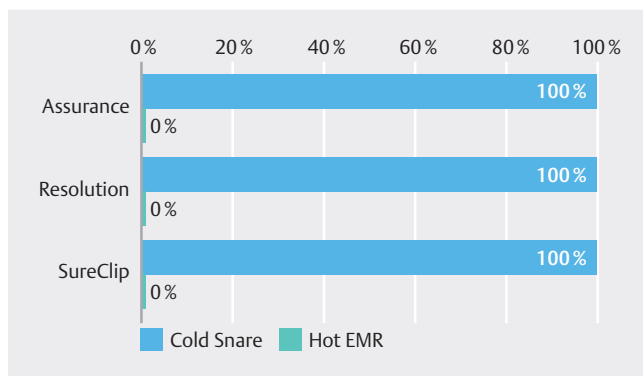
Deployment of each of the three clip models was randomized to a normal gastric fold, cold snare mucosal resection site, and simulated fibrotic ulcer (► Fig. 2). A total of nine clips (3 per model) were deployed in each animal (► Fig. 3). Endoscopists (n=2) were asked to evaluate each clip type by responding to the statement: overall, I am satisfied with the ease of clip deployment. Responses were rated on a 5-point Likert scale with: 1 = strongly disagree and 5 = strongly agree. Follow-up endoscopy was performed two weeks after clip placement to assess



► Fig. 2 Clip placement on a cold snare resection sites, b fibrotic ulcer sites, and c normal gastric fold.



► **Fig. 3** Schematic of a single pig stomach showing three different lesion types and deployed clips of each model.



► **Fig. 4** Complete tissue closure rate stratified by tissue and clip type.

mucosal healing, and the presence of retained clips for each model and defect type.

Outcomes and statistical analysis

The performance of each TTS clip model was assessed in terms of efficacy, clip retention and safety. Efficacy was measured by successful clip deployment across the target site. Tissue closure of cold snare resection sites and fibrotic ulcers was defined as complete, with no resection or ulcer base visible after clip deployment, or partial, with visible resection or ulcer base. Mucosal healing was defined as complete reepithelialization of fibrotic ulcers and cold mucosal resection sites, and clip retention rate was determined by the number and type of retained clips

observed on follow-up endoscopy. Adverse events (AEs) were documented during the procedure and follow up period. Overall retention rate and healing rates were calculated for each clip model in all animals, further stratified by mucosal/defect type. Data were reported as percentages and compared using Chi-squared analysis, with significance defined as $P < 0.05$.

Results

Band-assisted EMR was successfully performed in all animals prior to clip placement with resultant fibrotic ulcers. Cold snare mucosal resection was achieved in all animals. Clips were successfully deployed across all target sites (18 fibrotic ulcers, 18 cold snare resection sites and 18 normal mucosa) with a total of 54 clips (18 Assurance, 18 Resolution, and 18 SureClip) utilized in six pigs. Tissue defect closure was complete in all cold resection sites (18/18 sites, 100%) with full mucosal apposition achieved due to tissue pliability. However, closure was partial in all fibrotic ulcers with no sites achieving complete closure (0/18 sites, 0%) due to associated tissue firmness (► **Fig. 4**).

At week 2, mucosal healing was noted in all sites, regardless of clip model and independent of whether a clip was retained at the site. Overall clip retention rates were nine of 18 (50.0%) for SureClip, 10 of 18 (55.6%) for Assurance, and 13 of 18 (72.2%) for Resolution ($P = 0.369$) (► **Table 1**). On a per lesion basis, no differences were noted in SureClip, Assurance, and Resolution clip retention rates on normal tissue (83.3%, 100% and 83.3%, respectively, $P = 0.57$) or cold snare resection sites (66.7%, 66.7% and 83.3%, respectively, $P = 0.76$). However, retention rate was higher for Resolution clips on fibrotic ulcers (50.0% vs. 0% for other clips, $P = 0.03$). No AEs, specifically bleeding and perforations, were noted during clip placement, survival period and follow-up endoscopy. Ease of use was equal across all clip models, with a mean response of 5 (SD 0) for normal and cold snare resected tissue and mean response of 1 (SD 0) for fibrotic tissue.

Discussion

Through-the-scope clips are routinely used for hemostasis, repairing mucosal defects, securing prostheses, and closing fistulas [5, 6, 7]. More recently, there has been significant interest in developing and optimizing endoscopic clips for mucosal apposition after advanced tissue resection procedures, such as EMR,

► **Table 1** Retention rate stratified by tissue and clip type.

	Sureclip	Assurance	Resolution	P value
Overall	9/18 (50.0%)	10/18 (55.6%)	13/18 (72.2%)	0.37
Normal tissue	5/6 (83.3%)	6/6 (100.0%)	5/6 (83.3%)	0.57
Cold snare resection	4/6 (66.7%)	4/6 (66.7%)	5/6 (83.3%)	0.76
Fibrotic tissue (hot EMR)	0/6 (0%)	0/6 (0%)	3/6 (50%)	0.03*

* $P < 0.05$.
EMR, endoscopic mucosal resection.

endoscopic submucosal dissection and peroral endoscopic myotomy [8, 9, 10, 11].

The current literature assessing clip function is limited and consists largely of benchtop or biomechanical experimental studies [3, 8, 12]. The in-vivo comparative studies that have been performed are restricted to normal mucosa or a single lesion type [13, 14, 15]. This study adds to the literature by providing comparative outcomes related to clip deployment, retention rate, mucosal healing, and ease of use across multiple tissue types that would be encountered in clinical practice. The results suggest that overall clip function is preserved across different models. While all clips were deployed, ease of use was more impacted by the type of tissue rather than the specific type of device.

There was no significant difference in overall retention rates of the three clips studied. This is generally consistent with prior data that assessed clip retention rates at 2 weeks across multiple models [13, 14, 16]. When stratified by lesion type, differences were only seen in indurated/fibrotic tissue where Resolution clips were retained at a significantly higher rate than SureClip and Assurance. There are some data to support the relatively greater retention rates of Resolution clips. Shin et al. found higher retention of Resolution clips compared to TriClip (Cook Medical, Bloomington, Indiana, United States) and HX-5L clips (Olympus, Tokyo, Japan) at 5 weeks, as did Jensen and colleagues at 5 to 7 weeks [13, 14]. Swellengrebel et al. reported higher Resolution clip retention rates compared to QuickClips (Olympus, Tokyo, Japan) at week 12 [17]. However, a retained clip does not necessarily translate into greater clinical efficacy. One randomized study on chronic ulcers in canines similarly showed higher rates of Resolution clip retention in fibrotic ulcers, but found no difference in healing when compared to controls [15]. This is similar to the current study where more Resolution clips remained in-situ in the fibrotic subgroup, but there was no difference in rates of healing. In fact, all lesions in our study demonstrated complete reepithelialization by 2 weeks, including fibrotic ulcers which could only be partially closed.

Limitations of this study include the use of only three clip models and, as such, results may not be generalized to other TTS clip devices. However, the devices selected in our study are commonly used in clinical practice. Also, the study did not assess clip retention rates beyond 2 weeks; however, the 14-day survival period was adequate to facilitate healing in recently resected tissue as well as fibrotic ulcers. For TTS clips, there are not many indications that require extended retention rates, aside from fixation of a stent or feeding tube. In these cases, consideration of clip type or an alternative device, such as an over-the-scope clip (OTSC), may be more suitable. Similarly, fistula closure requires a more robust clip, such as the OTSC, or alternative closure methods. While attempts were made to replicate different tissue types that would be encountered in clinical practice, the study does not fully duplicate the diverse indications for which endoscopic clips are currently used. The lack of AEs and sample size also limits the ability to make definitive conclusions regarding safety.

Conclusions

Ultimately, the model used in clinical practice will be driven by several factors, including indication, anatomy, operator preference and institutional directives related to cost and supply chain. The data presented here indicate that minor variations in clip design do not have significant impact on mucosal healing, overall retention, and ease of use. Future studies are needed to evaluate cost-effectiveness, which may impact decision-making when selecting the optimal endoscopic clip.

Conflict of Interest

JA – intellectual property relation with Ruhof Corp. LW – consultant for Olympus Corp., Steris, Inc., and Boston Scientific, Inc. ER – intellectual property relation with Medtronic, Inc. and Ruhof Corp.; consultant for Olympus Corp. and Johnson & Johnson. SK – no disclosures

Funding

STERIS Endoscopy

References

- [1] Hayashi T. The study on stanch clips for the treatment by endoscopy. *Gastroenterolog Endosc* 1975; 17: 92–101
- [2] Parsi MA, Schulman AR, Aslanian HR et al. Devices for endoscopic hemostasis of nonvariceal GI bleeding (with videos). *VideoGIE* 2019; 4: 285–299
- [3] Wang TJ, Aihara H, Thompson AC et al. Choosing the right through-the-scope clip: a rigorous comparison of rotatability, whip, open/close precision, and closure strength (with videos). *Gastrointest Endosc* 2019; 89: 77–86.e1
- [4] National Research Council (US) Committee for the Update of the Guide for the Care and Use of Laboratory Animals. *Guide for the Care and Use of Laboratory Animals*. 8th Aufl. Washington (DC): National Academies Press (US); 2011
- [5] Qadeer MA, Dumot JA, Vargo JJ et al. Endoscopic clips for closing esophageal perforations: case report and pooled analysis. *Gastrointest Endosc* 2007; 66: 605–611 doi:10.1016/j.gie.2007.03.1028
- [6] Udorah MO, Fleischman MW, Bala V et al. Endoscopic clips prevent displacement of intestinal feeding tubes: a long-term follow-up study. *Dig Dis Sci* 2010; 55: 371–374 doi:10.1007/s10620-009-0726-3
- [7] Raymer GS, Sadana A, Campbell DB et al. Endoscopic clip application as an adjunct to closure of mature esophageal perforation with fistulae. *Clin Gastroenterol Hepatol* 2003; 1: 44–50
- [8] Voermans RP, Worm AM, van Berge Henegouwen MI et al. In vitro comparison and evaluation of seven gastric closure modalities for natural orifice transluminal endoscopic surgery (NOTES). *Endoscopy* 2008; 40: 595–601
- [9] Liaquat H, Rohn E, Rex DK. Prophylactic clip closure reduced the risk of delayed postpolypectomy hemorrhage: experience in 277 clipped large sessile or flat colorectal lesions and 247 control lesions. *Gastrointest Endosc* 2013; 77: 401–407 doi:10.1016/j.gie.2012.10.024
- [10] Kaltenbach T, Anderson JC, Burke CA et al. Endoscopic removal of colorectal lesions—recommendations by the US Multi-Society Task

- Force on Colorectal Cancer. *Gastrointest Endosc* 2020; 91: 486–519 doi:10.1053/j.gastro.2019.12.018
- [11] Aslanian HR, Sethi A, Bhutani MS et al. ASGE guideline for endoscopic full-thickness resection and submucosal tunnel endoscopic resection. *VideoGIE* 2019; 4: 343–350 doi:10.1016/j.vgie.2019.03.010
- [12] Daram SR, Tang S-J, Wu R et al. Benchtop testing and comparisons among three types of through-the-scope endoscopic clipping devices. *Surg Endosc* 2013; 27: 1521–1529
- [13] Jensen DM, Machicado GA, Hirabayashi K. Randomized controlled study of 3 different types of hemoclips for hemostasis of bleeding canine acute gastric ulcers. *Gastrointest Endosc* 2006; 64: 768–773 doi:10.1016/j.gie.2006.06.031
- [14] Shin EJ, Ko C-W, Magno P et al. Comparative study of endoscopic clips: duration of attachment at the site of clip application. *Gastrointest Endosc* 2007; 66: 757–761 doi:10.1016/j.gie.2007.03.1049
- [15] Jensen DM, Machicado GA. Hemoclippping of chronic canine ulcers: a randomized, prospective study of initial deployment success, clip retention rates, and ulcer healing. *Gastrointest Endosc* 2009; 70: 969–975 doi:10.1016/j.gie.2009.04.052
- [16] Khashab M, Saxena P, Valeshabad A et al. Which clip? A prospective comparative study of retention rates of endoscopic clips on normal mucosa and ulcers in a porcine model *Saudi J Gastroenterol* 2014; 20: 360
- [17] Swellengrebel HAM, Marijnen CAM, Vincent A et al. Evaluating long-term attachment of two different endoclips in the human gastrointestinal tract. *World J Gastrointest Endosc* 2010; 2: 344–348 doi:10.4253/wjge.v2.i10.344