

CASE REPORT

BEGINNER

CLINICAL CASE

An Unusual Cause of Stroke



A “Forgotten” Intracardiac Catheter Discovered After 48 Years



Giorgio Fiore, MD,^{a,b} Stefano Stella, MD,^b Andrea Conversano, MD,^b Eustachio Agricola, MD^{a,b}

ABSTRACT

A 48-year-old man with recurrent cerebral ischemic events underwent transesophageal echocardiography to investigate cardioembolic sources because transthoracic echocardiography had spotted a dubious filamentous mass on the mitral valve. A venous umbilical catheter, lost during the hospital stay after his birth, was surprisingly identified in his cardiac chambers. (**Level of Difficulty: Beginner.**) (J Am Coll Cardiol Case Rep 2023;6:101668)
© 2023 The Authors. Published by Elsevier on behalf of the American College of Cardiology Foundation. This is an open access article under the CC BY-NC-ND license (<http://creativecommons.org/licenses/by-nc-nd/4.0/>).

A 48-year-old man who had experienced a cerebellar stroke 1 month earlier and 2 episodes of transient amnesia in 2009 and 2015 that were not further investigated was referred by the neurologist to our laboratory to perform transesophageal echocardiography (TEE) to complete the diagnostic workup. Indeed, during the poststroke assessment of the cause, transthoracic echocardiography (TTE) was performed and revealed a filamentous

mass of dubious interpretation adhering to the mitral valve leaflets and the mitral subvalvular apparatus (Videos 1 and 2). The patient subsequently underwent cardiac magnetic resonance (CMR), which confirmed the above-mentioned structure and normal cardiac function; no further details were obtained because of the intrinsic limits of the diagnostic test. Doppler ultrasonography of the supra-aortic trunks did not reveal any abnormality, and magnetic resonance imaging (MRI) of the brain showed signs of a recent ischemic stroke in the territory of the right posterior inferior cerebellar artery and older diffuse small ischemic foci.

LEARNING OBJECTIVES

- To underline the role of multimodality imaging to reach a correct diagnosis.
- To strengthen the importance of a complete medical history as a fundamental aid in the diagnostic process.
- To highlight the importance of advanced 3D echocardiography to integrate and complete 2D findings.
- To discuss the management of unusual clinical scenarios that clinicians can face during their everyday practice.

MEDICAL HISTORY

The patient had a history of spastic hemiplegic cerebral palsy as an obstetric complication of a preterm twin pregnancy. He was hypertensive, and his long-term therapy included aspirin 100 mg daily (introduced after the latest acute event), irbesartan 300 mg daily, amitriptyline 50 mg daily, and botulinum toxin infiltrations every 3 months.

From the ^aVita-Salute San Raffaele University, IRCCS San Raffaele Scientific Institute, Milan, Italy; and the ^bUnit of Cardiovascular Imaging, IRCCS San Raffaele Scientific Institute, Milan, Italy.

The authors attest they are in compliance with human studies committees and animal welfare regulations of the authors' institutions and Food and Drug Administration guidelines, including patient consent where appropriate. For more information, visit the [Author Center](#).

Manuscript received May 15, 2022; revised manuscript received September 26, 2022, accepted October 6, 2022.

**ABBREVIATIONS
AND ACRONYMS****CMR** = cardiac magnetic resonance**MRI** = magnetic resonance imaging**TEE** = transesophageal echocardiography**TTE** = transthoracic echocardiography**DIFFERENTIAL DIAGNOSIS**

In a patient with stroke, the most common causes of posterior circulation artery ischemia are atherosclerosis, embolism, and dissection. In the setting of a young patient who experienced at least 3 episodes of brain ischemic events, the first of them at the age of 36, a cardioembolic origin should be suspected, specifically patent foramen ovale or silent undiagnosed atrial fibrillation. In this specific setting, the finding of a filamentous mass adhering to the valve apparatus leads to the suspicion of: 1) cardiac tumor (especially fibroelastomas); 2) valve endocarditis; or 3) thrombosis.

INVESTIGATIONS

With the patient conscious, TEE was performed at our laboratory and revealed an exceptional and unexpected finding: a railroad-shaped structure spreading from the right atrium to the left atrium and mitral subvalvular apparatus through the foramen ovale (**Figure 1, Videos 3 and 4**). Color Doppler evaluation of the interatrial septum and saline contrast study with an efficacious Valsalva maneuver were performed and excluded any intracardiac right-to-left shunt (**Figure 2, Video 5**).

A 3D TEE examination, integrating the 2D findings, allowed us to better define the structure as a vascular catheter (**Figure 3, Video 6**). The left-sided segment

fractured, with the distal fragment adhering to the anterior mitral valve leaflet and the mitral subvalvular apparatus with no distortion of the valve architecture and only mild central mitral regurgitation (**Video 7**). The proximal segment was tunneled (and probably epithelialized) in the atrial wall, with the distal tip freely moving in the left atrial cavity (**Video 8**). There was no evidence of vegetations, thrombosis, or calcification.

An urgent chest x-ray was performed and did not reveal any intracardiac radiopaque structure (**Figure 4**). After explication of the unusual finding to the patient, he mentioned the loss of an umbilical venous catheter during the hospital stay after his birth (for his spastic hemiplegic cerebral palsy) that was never further investigated. He did not report any other hospital stays or invasive procedures. After multidisciplinary discussion with a cardiologist, neurologist, and cardiac surgeon, initial conservative management was preferred. Therapy with aspirin 100 mg daily was confirmed and strict TTE follow-up and endocarditis prophylaxis were recommended.

DISCUSSION

We present a peculiar case with notable clinical implications and a challenging therapeutic approach. Venous catheter embolization is a rare but feared complication, mostly affecting the right cardiac chambers and pulmonary circulation. It is mostly asymptomatic and incidentally discovered.¹ However, serious consequences (pulmonary embolism, right ventricular rupture, ventricular arrhythmias, sudden cardiac death) have been reported.^{2,3} In the presence of a patent foramen ovale, paradoxical embolism is possible.⁴ The case of our patient is almost unique. Reconstructing his medical history, we reached the conclusion that the structure was an umbilical venous catheter lost during the prolonged postpartum hospitalization. The patient had no documentation of such an event, but he remembered that his parents had told him of the possible loss of a catheter in the umbilicus, near which he had a cutaneous scar. Umbilical catheters normally pass through the umbilicus, umbilical vein, left portal vein, ductus venosus, or middle or left hepatic vein, and the tip is placed in the inferior vena cava. In our patient, after being lost, the catheter reached the right atrium. There, owing to the incomplete anatomical closure of the foramen ovale, which normally occurs about 6 months after birth,⁵ it crossed to the left-heart chambers. The saline contrast study excluded any intracardiac shunt, confirming the subsequent complete anatomical closure of the foramen ovale after passage of the

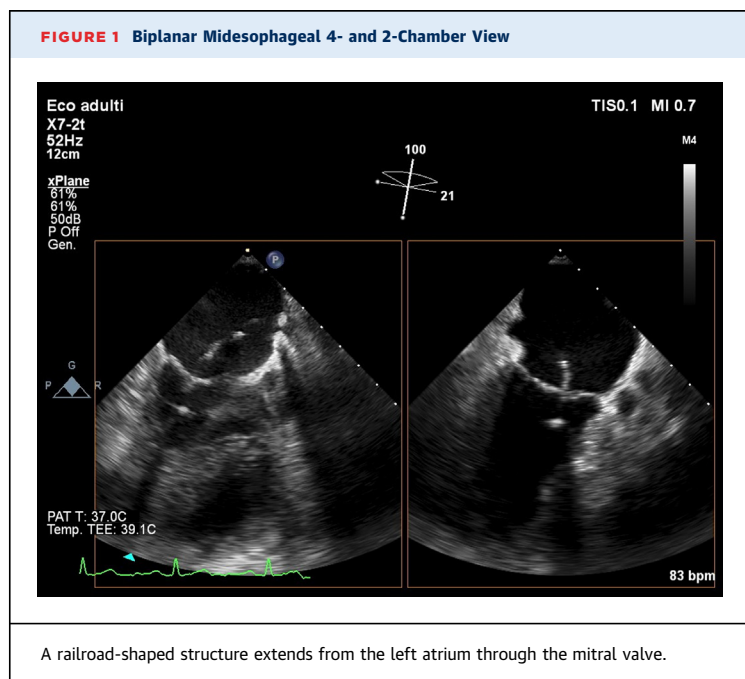
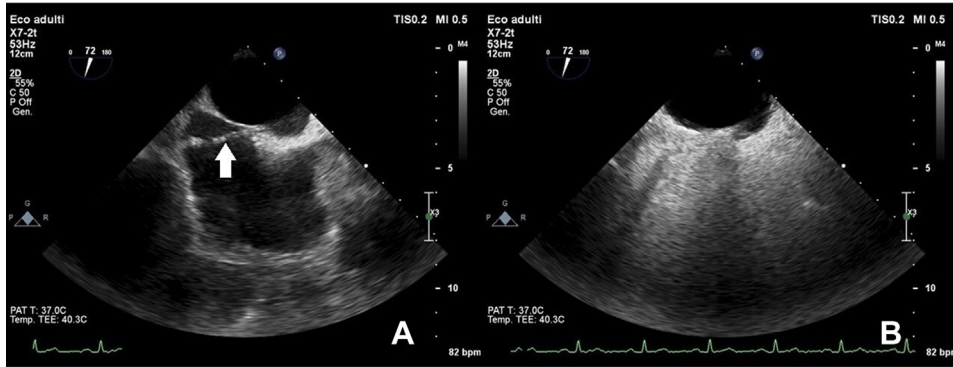


FIGURE 2 Midesophageal Bicaval View



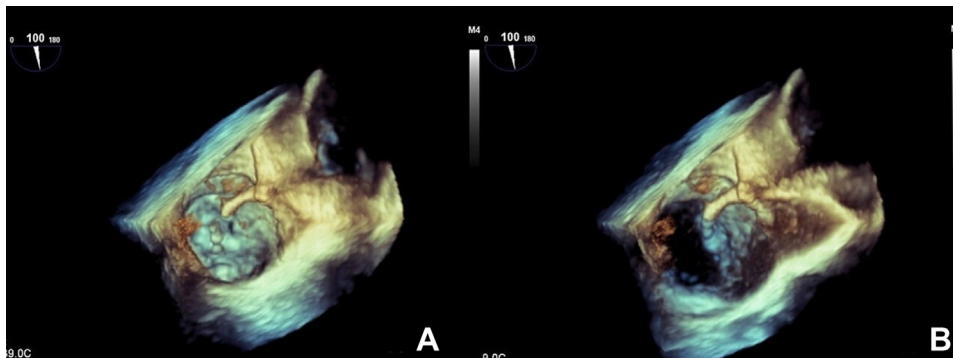
(A) The foreign structure (arrow) is passing through the interatrial septum. (B) The saline contrast study with Valsalva maneuver excluded right-to-left shunt.

catheter. Both the previous transitory amnesia episodes experienced by the patient and the more recent cerebellar ischemic stroke may have been related to thrombosis of the foreign body or even embolization of small fragments, given that the catheter appeared fractured at the TEE study. MRI of the brain demonstrated recent ischemic cerebellar lesions in the territory of the right posterior inferior cerebellar artery and signs of small ischemic foci. CMR did not add any further information because its role in the evaluation of mobile filamentous intracardiac masses may be debatable. In this context, cardiac CT could have

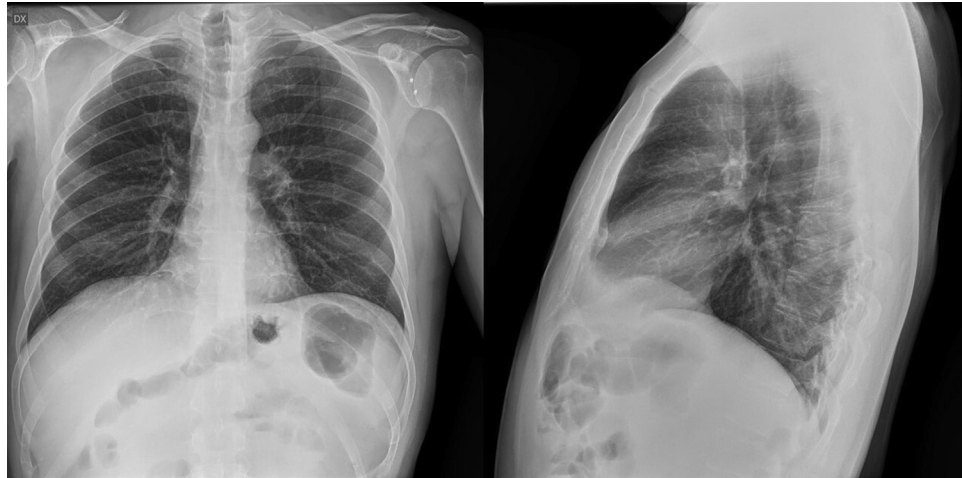
added further anatomical details, even avoiding the need for TEE.

The therapeutic choice should be strictly related to the clinical presentation. Because of the absence of catheter thrombosis, its partial endothelialization, and mostly its probable presence for 48 years, conservative management was chosen. Then, therapy with aspirin 100 mg daily, strict TTE follow-up, and endocarditis prophylaxis were recommended. Oral anticoagulation therapy with vitamin-K antagonists is a reasonable alternative, although no similar cases are present in the literature. In our patient, taking

FIGURE 3 3D Transesophageal Echocardiography



En-face view of the mitral valve in systole (A) and diastole (B) showing the proximal fragment of the vascular catheter emerging from the interatrial septum to the left atrium. The distal fragment, adhering to the anterior mitral valve leaflet, reaches the mitral subvalvular apparatus.

FIGURE 4 Chest X-Ray

No evidence of radiopaque structure.

also into consideration the absence of a right-to-left shunt and his history of arrhythmias, and the preference of avoiding continuous INR monitoring, our first strategy was to advise an antiplatelet drug. In case of new ischemic episodes or vascular complications, surgical extraction should be considered. Percutaneous retrieval of intravascular iatrogenic foreign bodies has been largely described⁶ but does not appear adequate to our patient because of the anatomical position and the strict adhesion to cardiac structures.

FOLLOW-UP

At the 6-month follow-up visit, the patient had not experienced any further neurological events. The result of Holter ECG monitoring was completely normal.

CONCLUSIONS

Physicians should always be aware of unusual clinical presentations, especially when the anamnesis is missing or unclear. A step-by-step approach and advanced, high-quality echocardiographic imaging allowed us to reach the diagnosis and retrospectively reconstruct the patient's medical history.

FUNDING SUPPORT AND AUTHOR DISCLOSURES

The authors have reported that they have no relationships relevant to the contents of this paper to disclose.

ADDRESS FOR CORRESPONDENCE: Dr. Giorgio Fiore, Department of Clinical Cardiology, Vita-Salute San Raffaele University, Via Olgettina 60, 20132 Milano, Italy. E-mail: gio.fio@hotmail.it.

REFERENCES

1. Nayeemuddin M, Pherwani AD, Asquith JR. Imaging and management of complications of central venous catheters. *Clin Radiol*. 2013;68:529-544.
2. Turner DD, Sommers SC. Accidental passage of a polyethylene catheter from cubital vein to right atrium: Report of a fatal case. *N Engl J Med*. 1954;251:744-745.
3. Suarez-Penaranda JM, Guitian B, Concheiro-Carro L. Longstanding intracardiac catheter embolism: An unusual autopsy finding. *Am J Forensic Med Pathol*. 1995;16:124-126.
4. Ching S, Chan RC, Yue CS. Recurrent stroke in a man with a pacemaker. *JAMA Cardiol*. 2019;4:1296-1297.
5. Christie A. Normal closing time of the foramen ovale and the ductus arteriosus: An anatomic and statistical study. *Am J Dis Child*. 1930;40:323-326.
6. Schechter MA, O'Brien PJ, Cox MW. Retrieval of iatrogenic intravascular foreign bodies. *J Vasc Surg*. 2013;57:276-281.

KEY WORDS 3D transesophageal echocardiography, cardiovascular imaging, umbilical catheter

APPENDIX For supplemental videos, please see the online version of this paper.