

Case Report

Polymorphous Adenocarcinoma: A Rare Case Report with Unique Radiographic Appearance on CBCT

Jagadish Chandra,¹ Junaid Ahmed ,² K. M. Veena,³ M. Vijayakumar,⁴ Nandita Shenoy ,² and Nanditha Sujir²

¹Dept. of Oral Surgery, Yenepoya Dental College, Yenepoya University, Deralakatte, India

²Dept. of Oral Medicine and Radiology, Manipal College of Dental Sciences, Mangalore, Manipal Academy of Higher Education (MAHE), Manipal, Karnataka 576104, India

³Dept. of Oral Medicine and Radiology, Yenepoya Dental College, Yenepoya University, Deralakatte, Karnataka, India

⁴Department of Surgical Oncology, Yenepoya Medical College, Yenepoya University, Deralakatte, Mangalore, India

Correspondence should be addressed to Junaid Ahmed; junaid.ahmed@manipal.edu

Received 29 May 2020; Revised 24 February 2021; Accepted 15 March 2021; Published 25 March 2021

Academic Editor: Sukumaran Anil

Copyright © 2021 Jagadish Chandra et al. This is an open access article distributed under the Creative Commons Attribution License, which permits unrestricted use, distribution, and reproduction in any medium, provided the original work is properly cited.

Background. Polymorphous low-grade adenocarcinoma (PLGA) is a slow growing malignant tumor of minor salivary glands and is generally of indolent nature. However, according to the most recent WHO Classification of Salivary Gland Tumors (2017), the cancer is classified as Polymorphous AdenoCarcinoma (PAC). PAC presents as a less aggressive tumor, though it could on rare occasions demonstrate distant metastasis. **Case Presentation.** A 47-year-old man who was referred by a private practitioner for a CBCT scan in reference to a proliferative soft-tissue growth in the hard palate. The growth was mild and tender and there was Grade III mobility in relation to all the maxillary teeth. Panoramic radiograph taken previously had revealed evidence of alveolar bone loss in relation to the maxillary teeth and was inconclusive of any other findings. The CBCT scan revealed evidence of moth-eaten appearance of maxilla with destruction of medial and lateral walls and floor of maxillary sinus. There was also evidence of involvement of right eustachian tube, ethmoidal wall, and nasopalatine canal. An intraosseous malignancy of the palate was suspected, and a total maxillectomy was performed. The tissue sample was sent for histopathological assessment wherein changes diagnostic for polymorphous low-grade adenocarcinoma of the palate were observed. **Conclusion.** PAC is a distinct, yet commonly occurring, minor salivary gland tumor with varied clinical and histologic appearance. This case report highlights the importance of CBCT in diagnosing the intraosseous involvement of such tumors which can help shed some light in enhancing our knowledge about the minor salivary gland malignancies like PAC.

1. Background

Polymorphous low-grade adenocarcinoma (PLGA) is a slow growing malignant tumor of minor salivary glands and is generally of indolent nature. However, according to the most recent WHO Classification of Salivary Gland Tumors (2017), the cancer is classified as Polymorphous AdenoCarcinoma (PAC) [1]. Among all the tumors of oral salivary glands, oral salivary gland carcinomas comprise only 20% of the malignant neoplasms [2]. Lobular carcinoma, terminal duct carcinoma, and low-grade papillary adenocarcinoma were the various names that were used for adenocarcinomas of the

minor salivary glands, before Evans and Batsakis [3] categorized them as a separate histologic entity in 1984. The World Health Organization later categorized PAC as a separate category of tumors of minor salivary glands in 1990 [4].

Due to its architecturally diverse structure, clinically indolent behavior, and cytological uniformity, PAC is thought to be a unique entity [5, 6]. Being asymptomatic with a low metastatic potential, it is commonly seen in elder women, with about 24% of primary tumors associated with major salivary glands (i.e., parotid, submandibular, or sublingual gland) and few in locations other than the head and neck, such as the breast and vagina [7, 8].

Although the third most commonly presenting malignant salivary gland tumor, our knowledge about PAC remains restricted to published case reports. Also, the architectural diversity associated with the name can be confusing for histopathological evaluation and can potentially be a diagnostic dilemma. Salivary gland neoplasms can be aggressive, and most of their clinical features often overlap; hence, a detailed examination and clinical investigation should be carried out in order to reach a definitive conclusion. Radiology is an important diagnostic tool for salivary gland pathology. It helps to determine the extent of involvement of bony structures, which can provide foresight into the treatment planning and provide a valuable tool in assessing the clinical picture. Cone Beam Computed Tomography (CBCT) is useful in the assessment of osseous structures and can help the clinician to determine the aggressive nature of the tumor as well as bony involvement due to a clear image of structures that are highly contrasted, and in comparison to most 2-D imaging methods, CBCT can provide a three-dimensional image of structures of the head and neck [9]. The following case report describes a unique case where a patient reported with the complaint of a soft-tissue growth in relation to the maxilla. This case report is aimed at highlighting the importance of CBCT in the detection of malignancies of salivary gland tissues, especially those cases with extensive bony involvement.

2. Case Presentation

A 47-year-old man was referred to the Department of Oral Medicine & Radiology with a history of soft tissue growth in the palate for the past two months. The growth was sudden in onset, growing rapidly in size over the next two months and localized to the palate. The patient reported no pain during the onset of growth. However, for the past one week, the patient reported mild pain. On clinical examination, there was a diffuse, proliferative soft tissue growth of the maxilla extending from the marginal gingiva in the palatal aspect of the anterior tooth and involving the entire surface of the hard palate up to the level of the hard and soft palate junction along with erythema of attached gingiva in relation to posterior teeth palatally and buccally as well as Grade III mobility of all the anterior and posterior maxillary teeth (Figures 1 and 2). The cervical group of lymph nodes were nonpalpable clinically.

The referring private practitioner had advised a panoramic radiograph earlier which revealed severe bone loss in relation to maxillary teeth suggestive of generalized periodontitis and was inconclusive for any other relevant findings except for a root stump in the lower right quadrant (Figure 3).

The patient was advised for a CBCT scan which revealed a moth-eaten appearance of the palate noticed bilaterally with involvement of nasopalatine canal anteriorly and external resorption of roots in relation to all the maxillary teeth present, with evidence of involvement of anterior and middle ethmoidal sinus, eustachian tube, and nasopharynx on the right side. Based on CBCT and clinical findings, a preliminary diagnosis of intraosseous malignancy involving the pal-

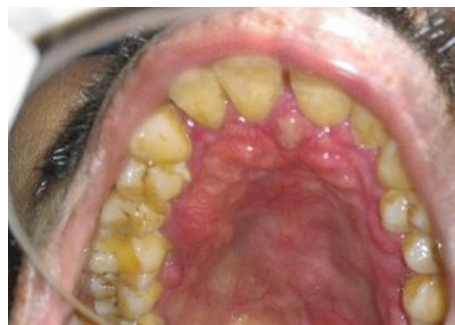

FIGURE 1: Evidence of diffuse, proliferative soft tissue swelling in the region of the hard palate.

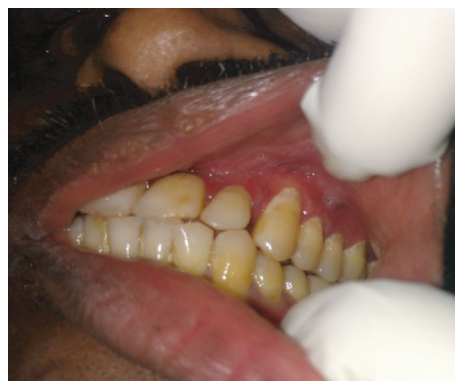

FIGURE 2: Evidence of erythema of the attached gingiva in relation to maxillary posterior teeth. The clinical features resembled a periodontal pathology.

ate was suspected (Figures 4–9). The patient was then scheduled for surgery with excision biopsy and total maxillectomy up to the floor of orbit.

The surgical procedure consisted of visualization of hard and soft palate and incision extending laterally around the maxillary tuberosity exposing the posterior border. Following exposure of the maxillary tuberosity, attachment to the soft palate and hard palate was divided. After soft tissue dissection up to the extension of the tumor, the extent of the bone which was tailored to the primary tumor including the lateral wall of the orbit and zygoma to be resected was marked. Following bone guttering, the bony resection was carried out using a chisel and mallet through the frontal process of the maxilla and lacrimal bone. Bleeding encountered during this procedure from the greater palatine artery and the branches of internal maxillary artery was controlled using pressure packing followed by ligation to achieve haemostasis. After mobilizing the segment, final osteotomy was done to separate the maxillary tuberosity from the pterygoid plates. Before removal, thorough clinical examination of the specimen was done to determine the adequacy of the tumor (Figures 10(a) and 10(b) and 11(a) and 11(b)).

The tissue sample was sent for histopathological examination which revealed an unencapsulated tumor within the underlying connective tissue approximating the surface epithelium, with a varied pattern of arrangement of tumor cells that included solid nests, strands, ducts, and tubular and

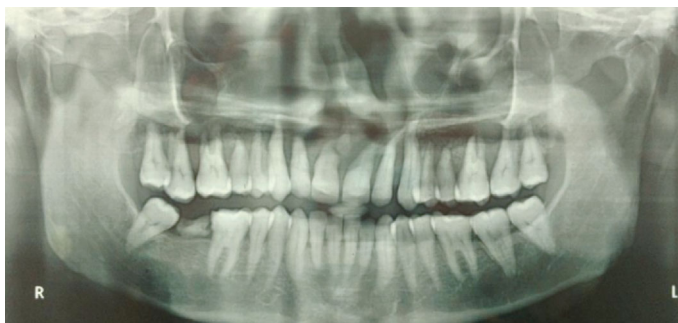

FIGURE 3: Panoramic radiograph of the patient revealing evidence of interdental bone loss in relation to all the maxillary teeth.

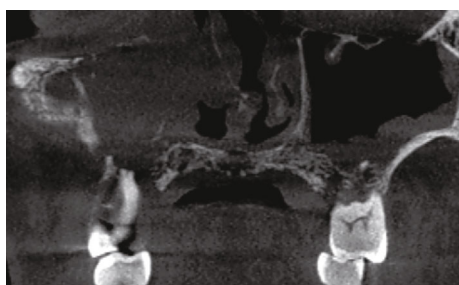

FIGURE 4: Coronal section of CBCT scan revealing destruction of walls of maxillary sinus along with involvement of nasopalatine canal.

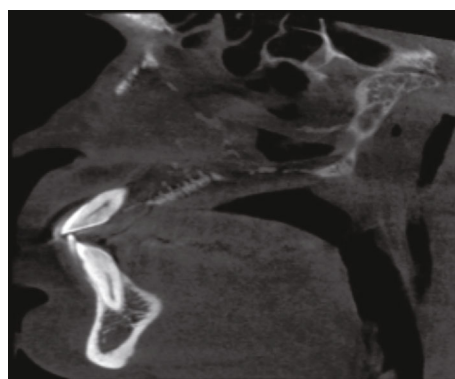


FIGURE 7: Sagittal section of CBCT revealing destruction of hard palate.

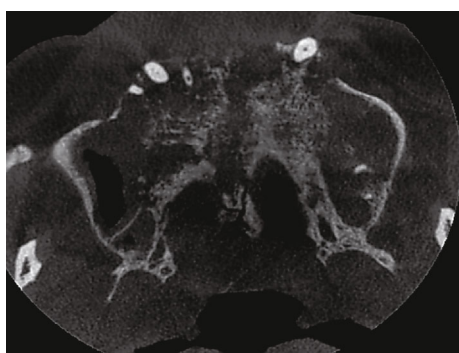


FIGURE 5: Axial view of CBCT scan revealing moth-eaten appearance of maxilla involving the hard palate and maxillary bone.

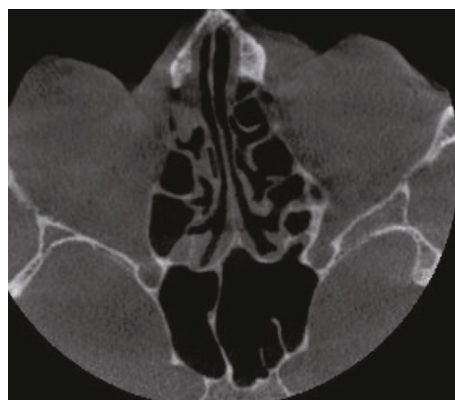

FIGURE 8: Axial view of CBCT scan revealing involvement of anterior and middle ethmoidal air sinus on the right side.

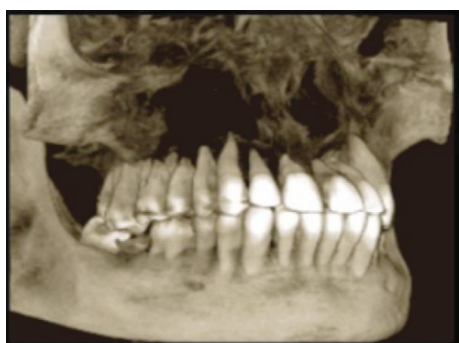

FIGURE 6: 3D reconstructed CBCT image revealing widespread destruction of maxilla and resorption of all maxillary teeth root apices.

papillary patterns and was lined by 1-2 layers of oval/cuboidal cells along with a peripheral layer of flat cells suggestive of polymorphous low-grade adenocarcinoma of the palate (Figures 12, 13, and 14). The patient is currently under follow-up for the past six months and is asymptomatic.

3. Discussion and Conclusion

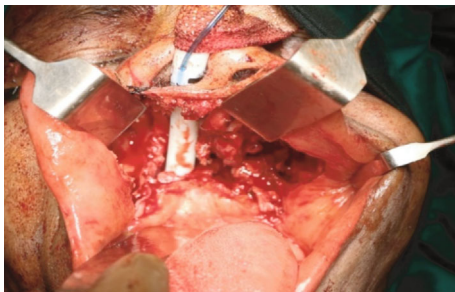
Clinically, PAC presents as a firm, well-circumscribed, painless, and slow growing mass mostly covered by nonulcerated mucosa resembling a benign neoplasm and could be fixed to underlying structures, eroding and infiltrating the underlying

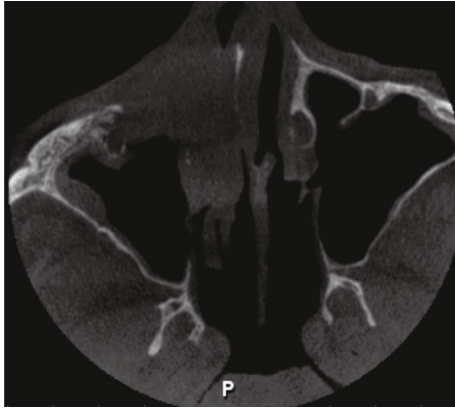
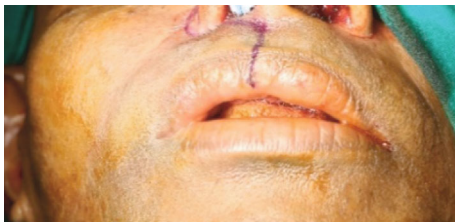
FIGURE 9: Axial view of CBCT scan revealing narrowing and involvement of eustachian tube on the right side.



(a)

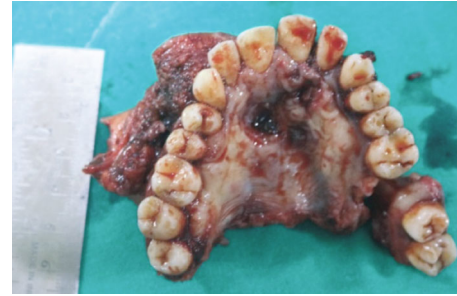

(b)

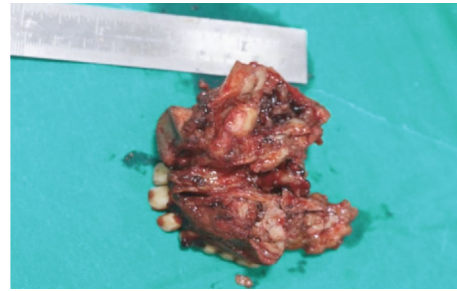
FIGURE 10: (a, b) Maxillectomy procedure done under local anesthesia.

bone, and is even present with perivascular and perineural invasion. Metastasis when reported is mostly confined to the regional nodes while spread to distant sites is a rarity and so is the transformation of this low-grade entity into a high-grade one [10].

Immunohistochemistry (IHC) has been utilized in a number of case series to distinguish between PAC and ACC, but there is a considerable overlap. Past studies conducted regarding the expression of ki-67 have consistently reported a very low labelling index (LI) in PAC which can assist in differentiating it from adenoid cystic carcinoma (ACC) [11–14]. In a few studies, p40 immunostaining has been demonstrated as a new tool for distinguishing salivary gland tumors with true myoepithelial differentiation from those showing nonspecific p63 expression. When these immunostains are performed in tandem, a discordant p63/p40-immunophenotype can reliably distinguish PAC from both adenoid cystic carcinoma and pleomorphic ade-



(a)



(b)

FIGURE 11: (a, b) Postsurgical maxillectomy specimen.

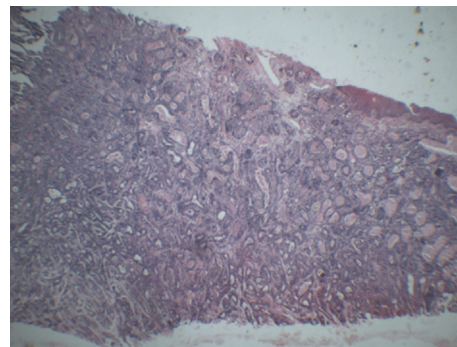


FIGURE 12: H and E section of tissue sample showing unencapsulated tumor close to surface epithelium with tumor cells arranged in solid nests.

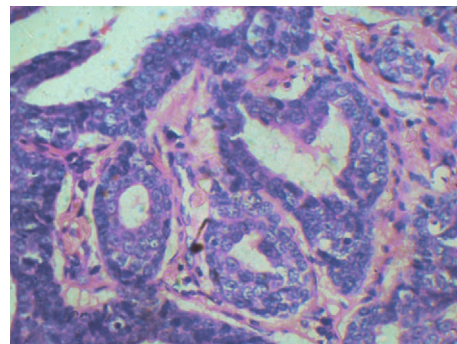


FIGURE 13: H and E sections showing ductal pattern of arrangement of tumor cells with evidence of vesicular nuclei.

noma, which generally show p63/p40 concordance [15]. Genetic abnormalities may be useful in differential diagnosis of PAC. PACs harbor PRKD1 mutations in >70% cases, and

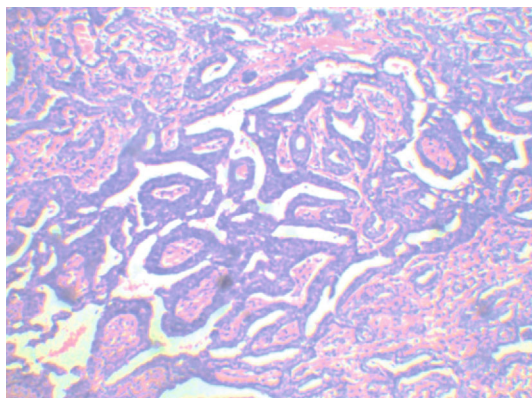


FIGURE 14: H and E sections showing arrangement of tumor cells in tubular pattern in the given tissue specimen.

PRKD1 mutations appear to be pathognomonic for this entity. In contrast, a vast majority of adenoid cystic carcinomas harbor MYB or MYBL1 gene rearrangements. While still not used widely in the clinic, use of these genetic markers may greatly facilitate the correct diagnosis [16].

The differential diagnosis for PAC includes pleomorphic adenoma and adenoid cystic carcinoma. PAC presents with a mucoid to the hyalinized matrix in comparison to pleomorphic adenoma which presents with a chondromyxoid matrix. Also, when compared to pleomorphic adenoma, PAC presents with perineural invasion. Another differentiating feature between the two is that PAC stains positive for S-100 and epithelial membrane antigen (EMA) whereas pleomorphic adenoma stains positive for glial fibrillary acidic protein (GFAP). When compared to adenoid cystic carcinoma, staining is positive for p-53, ki-67, bcl-2, and CD117. Perineural invasion is a feature of both PAC and adenoid cystic carcinoma, but the presence of the targetoid arrangement of perineural invasion is characteristic of PAC [17]. Also, in comparison to PAC, the cells of adenoid cystic carcinoma are smaller with hyperchromatic and angulated nuclei, less cytoplasm, and a coarser nuclear chromatin [18].

In the published literature, radiographic imaging of PAC has been mainly restricted to CT imaging since they provide a better soft-tissue contrast when compared to CBCT [19]. However, according to our knowledge, only a few case reports have highlighted the importance of CBCT in diagnosis of PGLA which describes it as presenting with no evidence of bone scalloping/erosion [20]. The radiographic appearance of PAC in our study resembled that of osteomyelitis and intraosseous malignancy. However, osteomyelitis of jaws is more common in the mandible when compared to the maxilla. Also, osteomyelitis of jaws is preceded most commonly with an identifiable cause of odontogenic infection such as a decayed tooth which was absent in our case. Intraosseous malignancies also present with a poorly defined, moth-eaten appearance. However, they occur more frequently in the mandibular posterior sections compared to the maxilla [21]. Also, these tumors reveal changes suggestive of carcinoma in the microscopic sections as defined by Sueti et al. for a definitive diagnosis of intraoral malignancy.

Adjuvant radiotherapy has been indicated in cases where there is metastasis of cervical lymph nodes. A wide excision has been shown to minimize the rate of recurrence in cases of PAC, and radical excision has been suggested for the recurrent cases [22].

3.1. Summary. Minor salivary gland malignancy is an uncommon occurrence in daily practice. However, being the third most common minor salivary gland malignancy, it is necessary for the diagnostician to be well-versed with the clinical, histopathological, and radiographic features of PGLA. Although the knowledge available on this entity is limited, it is necessary to be able to segregate it from the miscellaneous tumors of minor salivary glands in order to provide appropriate treatment for the patient. Due to its tendency for recurrence, it is important to regularly follow-up the patient posttreatment. The importance of radiography especially 3D imaging in the form of CBCT in dental practice is highlighted in this case report as we have noticed that even though salivary gland malignancies usually limit themselves to soft tissue involvement, there are cases wherein extensive involvement of bone with a varied radiological presentation can be observed.

PAC is a distinct, yet commonly occurring, minor salivary gland tumor with varied clinical and histologic appearance. This case report highlights the importance of CBCT in diagnosing the intraosseous involvement of such tumors which can help shed some light in enhancing our knowledge about the minor salivary gland malignancies like PAC.

Abbreviations

PAC:	Polymorphous low-grade adenocarcinoma
CT:	Computed tomography
CBCT:	Cone beam computed tomography
ACC:	Adenoid cystic carcinoma
PA:	Pleomorphic adenoma
IHC:	Immunohistochemistry
LI:	Labelling index
EMA:	Epithelial membrane antigen
GFAP:	Glial fibrillary acidic protein.

Data Availability

The datasets generated and/or analysed during the current study are not publicly available for the protection of privacy of the patient but are available from the corresponding author on request.

Ethical Approval

Ethics approval for the case report is not applicable as this is not a study but a report of a single case. The patient's confidentiality has been maintained in the manuscript. Our university rules do not mandate or require ethics approval for case reports.

Consent

A written consent was obtained from the patient prior to preparation of the case report. The patient's consent has been obtained prior to the submission of the manuscript. The patient has provided written consent to publish this case report.

Disclosure

The abstract was presented at the "9th International Conference on Clinical & Medical Case Reports".

Conflicts of Interest

The authors declare that there are no competing interests regarding the publication of this paper.

Authors' Contributions

JH assessed the patient clinically and referred the patient for a CBCT scan. JA assessed the CBCT scan and contributed in the radiographic interpretation of the lesion. The histopathologic assessment of the patient specimen was performed by VKM. MV along with JH performed total maxillectomy surgery for the patient under general anesthesia. NS helped with the review of this manuscript along with necessary inputs by JA. The CBCT scan for the patient was performed by MN who also majorly contributed to the writing of this manuscript. All authors have read and approved the manuscript.

References

- [1] R. R. Seethala, "Update from the 4th edition of the World Health Organization classification of head and neck tumours: preface," *Head and Neck Pathology*, vol. 11, no. 1, pp. 1-2, 2017.
- [2] K. Dhanuthai, M. Boonadulyarat, T. Jaengjongdee, and K. Jiruedee, "A clinico-pathologic study of 311 intraoral salivary gland tumors in Thais," *Journal of Oral Pathology & Medicine*, vol. 38, no. 6, pp. 495-500, 2009.
- [3] H. L. Evans and J. G. Batsakis, "Polymorphous low-grade adenocarcinoma of minor salivary glands a study of 14 cases of a distinctive neoplasm," *Cancer*, vol. 53, no. 4, pp. 935-942, 1984.
- [4] G. Seifert, C. Brocheriou, A. Cardesa, and J. W. Eveson, "WHO International Histological Classification of Tumours Tentative Histological Classification of Salivary Gland Tumours," *Pathology - Research and Practice*, vol. 186, no. 5, pp. 555-581, 1990.
- [5] B. A. Moore, B. B. Burkey, J. L. Netteville, R. B. Butcher II, and R. G. Amedee, "Surgical management of minor salivary gland neoplasms of the palate," *Ochsner Journal*, vol. 8, no. 4, pp. 172-180, 2008.
- [6] S. Asioli, G. Marucci, G. Ficarra et al., "Polymorphous adenocarcinoma of the breast. Report of three cases," *Virchows Arch*, vol. 448, no. 1, pp. 29-34, 2006.
- [7] P. Sukovic, "Cone beam computed tomography in craniofacial imaging," *Orthodontics & Craniofacial Research*, vol. 6, Supplement 1, pp. 31-36, 2003.
- [8] W.-Y. Yih, F. J. Kratochvil, and J. C. B. Stewart, "Intraoral minor salivary gland neoplasms: review of 213 cases," *Journal of Oral and Maxillofacial Surgery*, vol. 63, no. 6, pp. 805-810, 2005.
- [9] S. D. Vincent, H. L. Hammond, and M. W. Finkelstein, "Clinical and therapeutic features of polymorphous low-grade adenocarcinoma," *Oral Surgery, Oral Medicine, Oral Pathology*, vol. 77, no. 1, pp. 41-47, 1994.
- [10] D. Gibbons, M. H. Saboorian, F. Vuitch, S. T. Gokaslan, and R. Ashfaq, "Fine-needle aspiration findings in patients with polymorphous low grade adenocarcinoma of the salivary glands," *Cancer*, vol. 87, no. 1, pp. 31-36, 1999.
- [11] D. R. Gnepp, J. C. Chen, and C. Warren, "Polymorphous low-grade adenocarcinoma of minor salivary Gland," *The American Journal of Surgical Pathology*, vol. 12, no. 6, pp. 461-468, 1988.
- [12] R. H. W. Simpson, J. S. Reis-Filho, E. M. Pereira, A. C. Ribeiro, and A. Abdulkadir, "Polymorphous low-grade adenocarcinoma of the salivary glands with transformation to high-grade carcinoma," *Histopathology*, vol. 41, no. 3, pp. 250-259, 2002.
- [13] C. A. Waldron, S. K. El-Mofty, and D. R. Gnepp, "Tumors of the intraoral minor salivary glands: a demographic and histologic study of 426 cases," *Oral Surgery, Oral Medicine, and Oral Pathology*, vol. 66, no. 3, pp. 323-333, 1988.
- [14] D. Beltran, W. C. Faquin, G. Gallagher, and M. August, "Selective immunohistochemical comparison of polymorphous low-grade adenocarcinoma and adenoid cystic carcinoma," *Journal of Oral and Maxillofacial Surgery*, vol. 64, no. 3, pp. 415-423, 2006.
- [15] R. Sathyanarayanan, V. Suresh, and B. A. Thomas, "Polymorphous low-grade adenocarcinoma of the palate: a rare case report," *Iranian journal of cancer prevention*, vol. 9, no. 1, 2015.
- [16] I. Weinreb, L. Zhang, L. M. S. Tirunagari et al., "Novel PRKD gene rearrangements and variant fusions in cribriform adenocarcinoma of salivary gland origin," *Genes, Chromosomes and Cancer*, vol. 53, no. 10, pp. 845-856, 2014.
- [17] V. Surya, J. V. Tupkari, T. Joy, and P. Verma, "Histopathological spectrum of polymorphous low-grade adenocarcinoma," *Journal of oral and maxillofacial pathology*, vol. 19, no. 2, p. 266, 2015.
- [18] A. Potluri, J. Prasad, S. Levine, and J. Bastaki, "Polymorphous low-grade adenocarcinoma: a case report," *Dentomaxillofacial Radiology.*, vol. 42, no. 2, p. 14804843, 2013.
- [19] E. L. Adekeye and J. Cornah, "Osteomyelitis of the jaws: a review of 141 cases," *British Journal of Oral and Maxillofacial Surgery*, vol. 23, no. 1, 1985.
- [20] S. Gupta, C. A. Kumar, and N. Raghav, "Polymorphous low-grade adenocarcinoma of the palate: report of a case and review of literature," *International Journal of Head and Neck Surgery.*, vol. 2, no. 1, pp. 57-60, 2011.
- [21] P. Geetha, M. A. Tejasvi, B. B. Babu, H. Bhayya, and D. Pavani, "Primary intraosseous carcinoma of the mandible: a clinicoradiographic view," *Journal of cancer research and therapeutics*, vol. 11, no. 3, 2015.
- [22] I. A. El-Naaj, Y. Leiser, A. Wolff, and M. Peled, "Polymorphous low grade adenocarcinoma: case series and review of surgical management," *Journal of Oral and Maxillofacial Surgery*, vol. 69, no. 7, pp. 1967-1972, 2011.