

## SYSTEMATIC REVIEW ARTICLE

BENTHAM  
SCIENCEAlpha<sub>1</sub>-Antitrypsin Deficiency: Transition of Care for the Child With AAT Deficiency into AdulthoodHenry C. Lin<sup>1</sup>, Nagraj Kasi<sup>2</sup> and J. Antonio Quiros<sup>2,\*</sup><sup>1</sup>Division of Pediatric Gastroenterology, Hepatology, and Nutrition, The Children's Hospital of Philadelphia, USA;<sup>2</sup>Division of Pediatric Gastroenterology, Hepatology and Nutrition MUSC Children's Hospital, South Carolina, SC, USA

**Abstract: Importance:** Alpha<sub>1</sub>-antitrypsin (AAT) deficiency is a common, but an underdiagnosed genetic condition, affecting 1 in 1500 individuals. It can present insidiously with liver disease in children. Although clinical practice guidelines exist for the management of AAT deficiency, especially with regards to pulmonary involvement, there are no published recommendations that specifically relate to the management of the liver disease and monitoring for lung disease associated with this condition, particularly in children.

**Objective:** To review the literature on the management of AAT deficiency-associated liver disease in adults and children.

**Evidence Review:** A systematic search for articles indexed in PubMed and published was undertaken. Some earlier selected landmark references were included in the review. Search terms included: "alpha<sub>1</sub>-antitrypsin deficiency"; "liver disease"; "end-stage liver disease"; "liver transplantation" and "preventative management". Recommendations for the management of children with suspected or confirmed AAT deficiency were made according to the Strength of Recommendation Taxonomy scale.

**Findings:** Liver complications arising from AAT deficiency result from the accumulation of mutated AAT protein within hepatocytes. Liver disease occurs in 10% of children, manifested by cholestasis, pruritus, poor feeding, hepatomegaly, and splenomegaly, but the presentation is highly variable. A diagnostic test for AAT deficiency is recommended for these children. Baseline liver function tests should be obtained to assess for liver involvement; however, the only curative treatment for AAT deficiency-associated liver disease is organ transplantation.

**Conclusion and Relevance:** There should be a greater vigilance for AAT deficiency testing among pediatricians. Diagnosis should prompt assessment of liver involvement. Children with AAT-deficiency-associated liver disease should be referred to a liver specialist and monitored throughout their lifetimes for the symptoms of AAT-deficiency-related pulmonary involvement.

**Keywords:** Alpha<sub>1</sub>-antitrypsin deficiency, systematic review, pediatric liver disease, diagnosis, emphysema, pulmonary function tests.

## 1. INTRODUCTION

Fifty years ago Laurell and Eriksson first described the relationship between low levels of the protein alpha<sub>1</sub>-antitrypsin (AAT) and early-onset emphysema and recognized that the condition was inherited [1]. AAT deficiency, which is estimated to affect 1 in 1500 individuals [2], is the only known genetic risk factor for Chronic Obstructive Pulmonary Disease (COPD) and is responsible for up to 3% of all cases of COPD [3]. It is estimated that less than 10% of AAT-deficient individuals have been diagnosed [3-5].

Lung disease due to AAT deficiency may become apparent at any age in adulthood. In addition to pulmonary disease, there is an association between a low level of AAT and liver disease leading to cirrhosis in children [6, 7]. AAT deficiency is the most frequent genetic cause of liver disease in children [2]. The spectrum of the liver disease phenotype ranges from protracted jaundice and liver enzyme elevation to cirrhosis and chronic liver disease [8]. Of children with AAT deficiency-associated liver disease, progressive liver dysfunction occurs in a small proportion [8]. In addition, AAT deficiency predisposes adults to chronic liver disease and hepatocellular carcinoma (HCC) [9]. Other extrapulmonary manifestations of AAT deficiency include the

\*Address correspondence to this author at the Pediatric Gastroenterology and Nutrition, Pediatric Hepatology, and Liver Transplant Program, MUSC Children's Hospital, 135 Rutledge Ave MSC 558, Charleston SC 29425, USA; Tel: 843-792-5021; Fax: 843-792-7332; E-mail: [quirosj@musc.edu](mailto:quirosj@musc.edu)

## ARTICLE HISTORY

Received: April 27, 2018  
Revised: October 02, 2018  
Accepted: November 06, 2018

DOI:  
10.2174/1573396314666181113094517



skin disease necrotizing panniculitis, vasculitis (Wegener's granulomatosis), and rheumatoid arthritis [10, 11].

AAT deficiency is a single-gene disorder that results from mutations in the *SERPINA* gene located on chromosome 14. The *SERPINA* gene encodes for AAT, also known as alpha<sub>1</sub>-proteinase inhibitor (alpha<sub>1</sub>-PI). Alpha<sub>1</sub>-PI is a 52-kDa protein that plays a protective role in the lung through inhibition of proteolytic enzymes, especially neutrophil elastase (NE), which is released in response to inflammation. In the absence of sufficient levels of alpha<sub>1</sub>-PI, the protease-antiprotease balance is altered and the uninhibited NE may lead to progressive emphysema [9, 11].

The *SERPINA* gene is highly susceptible to mutations; individuals who produce normal levels of alpha<sub>1</sub>-PI are homozygous (PI\*MM) for the (normal) M allele. The majority of those with severe AAT deficiency are homozygous for the Z allele (PI\*ZZ) and have insufficient alpha<sub>1</sub>-PI levels, while the mutation leading to the S allele is also common and results in lower levels of alpha<sub>1</sub>-PI [11, 12]. More than 100 alleles have been identified, but not all are associated with the disease. Individuals may be heterozygous and carry the S, Z, or MZ genotypes with reduced levels of alpha<sub>1</sub>-PI that confer a lower, but increased risk for the disorder, particularly in smokers [13]. In PI\*ZZ individuals, the abnormal alpha<sub>1</sub>-PI protein that is formed accumulates in the hepatocytes and is retained in the liver rather than being secreted into the bloodstream; this may cause liver injury, cirrhosis, and HCC that are associated with AAT deficiency [11, 14-16]. Individuals with "Null" mutations produce no alpha<sub>1</sub>-PI [12]. The occurrence of the Null allele does not cause liver disease, but can result in the development of lung disease [9].

The purpose of this review is to summarize the current scientific knowledge surrounding AAT deficiency liver disease, with a particular focus on children. While liver complications due to AAT deficiency, such as protracted hyperbilirubinemia or elevated liver enzymes, present early in neonates and children, they are not routinely diagnosed. In addition, when these complications normalize, there is a lack of follow-up of children as they transition into adulthood, for monitoring of pulmonary manifestations. We will explore the reasons for under-recognition and propose recommendations to improve the rate of diagnosis and management of AAT deficiency in children, who may also go on to develop extra-hepatic manifestations.

## 2. METHODS

Evidence for the content and information provided in this paper was obtained from the peer-reviewed literature on AAT deficiency by carrying out a systematic review according to the standards of Preferred Reporting Items for Systematic Reviews and Meta-Analyses (PRISMA) guidelines [17]. The term "AAT deficiency" was combined with the following search terms to identify relevant articles from the PubMed database: "liver disease" (to include "adolescent management" or "pulmonary screening" or "health screening"); "end-stage liver disease"; "liver transplantation"; "liver disease management"; "lung screening algorithm" and "preventive management". Recent papers (from the past 5 years) authored by leaders in the field of AAT deficiency

were included in the search. Selected landmark references were also included.

Recommendations for management of patients diagnosed with liver disease as a consequence of their AAT deficiency were evaluated based on their quality of evidence according to the Strength of Recommendations Taxonomy (SORT) [18], with levels of evidence assigned grades from A to C.

## 3. PATHOPHYSIOLOGY OF LIVER DISEASE IN AAT DEFICIENCY

The Z mutation in the alpha<sub>1</sub>-PI molecule results in misfolded AAT protein and subsequent abnormal spontaneous polymerization within the Endoplasmic Reticulum (ER), preventing the secretion of approximately 85% of the protein from the liver. The accumulation of alpha<sub>1</sub>-PI polymers within the hepatocyte Endoplasmic Reticulum (ER) causes liver injury. Two pathways are believed to be involved to counter the accumulation of Z protein in the ER: (a) binding of the non-polymerized Z protein to the transmembrane ER chaperone calnexin, followed by binding to ubiquitin, and subsequent degradation of the complex; (b) autophagic degradation, apoptosis, and cell death in the minority of hepatocytes with the heaviest accumulation of mutant protein polymer (reviewed by Teckman [15]). The hepatocytes that have a lower level of Z protein polymer accumulation proliferate to maintain functional liver mass, but over time the chronic processes of cell injury, cell death, and compensatory proliferation result in end organ fibrosis, cirrhosis, and HCC.

The efficiency of the degradation mechanism involving calnexin is believed to be a factor in determining the susceptibility to liver injury of an individual with the PI\*ZZ genotype [10, 15]. Overt liver disease may occur more consistently in newborn infants than in young adults due to liver cells in the former being less capable of degrading mutant Z protein [9]. Whereas PI\*ZZ is the primary genotype associated with liver disease, the S allele is not associated with liver disease, except when coinherited with the Z allele [10].

## 4. CLINICAL COURSE OF LIVER DISEASE IN AAT DEFICIENCY

Among PI\*ZZ children, the presentation of liver disease can be highly variable. During the neonatal period, liver disease is typically cholestatic in nature and includes symptoms of prolonged cholestatic jaundice, pruritus, poor feeding and weight gain, hepatomegaly, and splenomegaly. Cholestasis (indicated when the direct reacting serum bilirubin level is >1.0 mg/dL if the total bilirubin is <5 mg/dL, or when the direct bilirubin represents >20% of the total bilirubin if the total bilirubin is >5 mg/dL) [19] usually resolves within the first 6 to 12 months of life, except when children also have paucity of intrahepatic ducts. The majority of AAT-deficient children recover clinically; however, children who have splenomegaly may develop cirrhosis [7] and 5% of children with liver disease will ultimately require Liver Transplantation (LT) within the first 4 years of life [20]. Some children with liver disease due to AAT deficiency are also at risk for developing HCC, or rarely, fulminant hepatic failure [8, 15, 21]. Factors that indicate potentially more severe prognosis in PI\*ZZ childhood liver disease are shown in Table 1.

**Table 1. Clinical features and risk factors for AAT deficiency in childhood [8].**

<b>Clinical Features Suggesting PI*ZZ AAT Deficiency in Childhood</b>
Infant with increased level of transaminase and/or bilirubin
Infant with neonatal hepatitis syndrome
Child or adolescent with hepatomegaly and/or hepatosplenomegaly
Infant with failure to thrive
Infant with vitamin K-deficient coagulopathy
Child or adolescent with symptoms of chronic liver disease
First degree relative of PI*ZZ individual
<b>Factors Indicating Potentially More Severe Prognosis in PI*ZZ Childhood Liver Disease</b>
PI*ZZ relative with liver disease
Neonatal cholestasis
Male gender
Persistent hyperbilirubinemia
Hard hepatomegaly
Early splenomegaly
Prolonged prothrombin time
Persistently elevated gamma glutamyltransferase level

A population based study that screened 200,000 newborns in Sweden in the 1970s [2] identified 122 infants with the PI\*Z genotype (120 homozygotes and 2 heterozygotes); clinical signs of liver disease were found in 22 (17%) of the PI\*ZZ infants (11% neonatal cholestasis and 6% who had other clinical symptoms of liver disease without jaundice) [2]. The children with the PI\*ZZ genotype have been followed prospectively from birth through to 18 years of age; none of those who were identified as having neonatal liver disease had any clinical signs of liver disease at age 12 or 18 [2, 22].

In older children, AAT deficiency may present as asymptomatic chronic hepatitis. The majority of children with AAT deficiency have no evidence of active liver injury and remain healthy [15]. Progressive liver disease in previously well, young or middle-aged adults appears to be infrequent but risk does increase with age [15]. A study by Dawwas *et al.* [23] has shown that 17.5% of 57 PI\*ZZ individuals (median age 56 years) with lung disease also had severe fibrosis or cirrhosis. In a study of 647 AAT-deficient adults (mean age 54.7 years), the prevalence of liver disease was 7.9% [24].

While cirrhosis may become clinically apparent at any age, the peak incidence occurs in elderly PI\*ZZ never-smokers who have not developed severe emphysema, and in cases where emphysema has been treated [8, 15]. When the causes of death were examined in a study of PI\*ZZ never-smokers, cirrhosis was observed to be a principal cause of mortality, accounting for 28% of deaths compared with 45% from emphysema [11]. Approximately 50% of PI\*ZZ adults die of severe lung disease at a mean age of 52 years and have mild or no signs of liver disease, whereas among those dying around 10 years later, there are signs of chronic progressive liver disease [9].

Cirrhosis resulting from AAT deficiency is an established risk factor for HCC; survival following diagnosis of cirrhosis

is lowered and 30% of patients have primary liver cancer at autopsy [10]. AAT-deficient individuals should be screened for HCC using biomarkers or imaging. Hepatocytes with high accumulation of mutant alpha<sub>1</sub>-PI may survive with damage and are believed to stimulate “in trans” adjacent hepatocytes with low accumulation to proliferate, generating a cancer-prone state [25].

Genetic and environmental factors may play a role in the clinical course and severity of AAT deficiency associated liver disease. Specifically, a childhood history of liver disease, male gender, and obesity has been implicated as risk factors for developing liver disease during adulthood [8, 9, 24]. Consequently, physicians should consider counseling AAT-deficient patients for obesity.

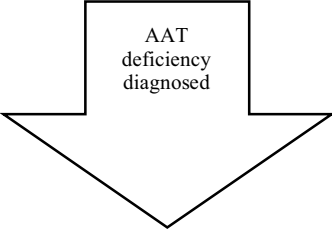
## 5. HETEROZYGOTES AND LIVER DISEASE

Liver disease should be a consideration even in heterozygotes. Although transiently elevated serum transaminases have been described in a small minority of PI\*MZ newborns, clinically significant health problems do not appear to develop in childhood; however, studies in adults have shown an odds ratio for the risk of developing chronic liver disease in PI\*Z heterozygotes of 1.8 to 3.1 [8]. Rakela *et al.*, [26] showed that liver disease became symptomatic later in life at the age of 58 years in PI\*ZZ, 66 years in PI\*SZ, and 73 years in PI\*MZ individuals, whereas neither the PI\*MS nor PI\*SS phenotypes have any direct correlation with liver disease [10].

## 6. DIAGNOSIS OF AAT DEFICIENCY IN INDIVIDUALS WITH LIVER DISEASE

The clinical features that suggest PI\*ZZ AAT deficiency in childhood are shown in Table 1 [8]. As liver disease due to AAT deficiency presents early in neonates and children,

**Table 2. Summary of recommendations for the management of children with suspected and confirmed AAT deficiency according to the strength of recommendations taxonomy (SORT) [18]**

Clinical Management	Level of Evidence <sup>a</sup>	Comments
<i>Children with unexplained liver disease or suspected AAT deficiency</i>		
Genetic testing for AAT deficiency	A	Consensus guidelines recommend diagnostic testing for all patients who have unexplained liver disease <sup>8</sup>
Liver biopsy to evaluate tissue for the presence of intra-hepatocystic globules	C	Based on clinical opinion [15, 27]
		
<i>Children with liver disease as a result of confirmed AAT deficiency</i>		
In children >6 months old with jaundice or recurrent elevated bilirubin, evaluate for LT	C	Based clinical opinion following a study of the study of 18 patients who received LT [28]
Annual physical exam to assess for splenomegaly and portal hypertension	C	Based on the clinical experience of the authors
Evaluate for LT if portal hypertension		
Annual liver function tests (alpha-fetoprotein and enzymes)		
Annual ultrasound to assess the liver, spleen, and portal vasculature		
Screen for HCC		

Abbreviations: HCC, Hepatocellular Carcinoma, LT, Liver Transplant.

<sup>a</sup>Level of evidence for recommendations: A, based on consistent and good quality patient-oriented evidence; B, based on inconsistent or limited quality patient-oriented evidence; C, based on consensus, usual practice, opinion, disease-oriented evidence and case series.

but can follow a relatively benign course, testing for the disorder should be part of the differential diagnosis in children with liver abnormalities. We summarize the current scientific opinion surrounding the diagnosis and management of children with suspected and confirmed AAT deficiency in Table 2.

In general, the diagnosis of AAT deficiency does not require liver biopsy, although it may be helpful for excluding other causes of liver disease and can be used to establish the degree of fibrosis and liver parenchymal disruption and thus “stage” liver disease [8]. Findings on liver biopsy are highly variable and may include globular, eosinophilic inclusions of polymerized alpha<sub>1</sub>-PI protein [15], as well as fibrosis, and nodular transformation (Fig. 1A). The presence of periodic acid–Schiff-positive diastase-resistant globules on liver biopsy (Fig. 1B) should prompt suspicion of AAT deficiency [15, 27].

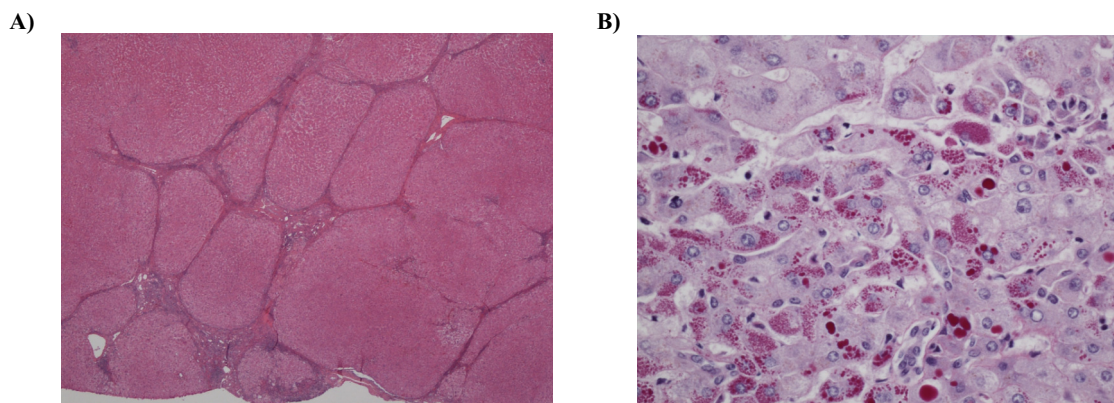
Apart from low alpha<sub>1</sub>-PI levels, laboratory tests and clinical features of liver disease in adults with AAT deficiency are indistinguishable from those of cirrhosis of any etiology; for example, the biochemical and histopathological

findings in PI\*ZZ adults may be similar to those of alcoholic liver disease. In cases of unexplained liver disease, therefore, a specific laboratory diagnosis of AAT deficiency is required [8, 15]. The American Thoracic Society/European Respiratory Society (ATS/ERS) Task Force recommendations include testing for AAT deficiency in all individuals with unexplained liver disease, including neonates, children, adults, and especially the elderly [8]. Additionally, unexplained liver disease should be confirmed by the testing for elevated liver enzymes (alanine aminotransferase [ALT], aspartate aminotransferase [AST], and bilirubin).

## 7. MANAGEMENT OF LIVER DISEASE IN AAT DEFICIENCY AND THERAPEUTIC APPROACHES

In children with AAT deficiency, protracted jaundice or recurrence of bilirubin elevations after 6 months of age should prompt evaluation for progressive liver disease and signs of portal hypertension. In addition, evaluation for LT should be considered [28].

The standard management of liver disease in children is supportive care as it cannot be predicted which children



**Fig. (1).** Biopsy findings from patients with AAT deficiency-related liver disease. **A)** Hematoxylin and eosin stain (2 ×) demonstrating fibrosis with nodular transformation. AAT. **B)** PAS-diastase staining (40 ×) demonstrating PAS-positive, diastase-resistant globules that are characteristic in AAT deficiency.

will develop progressive liver disease. This includes routine assessment by hepatologists comprising a physical exam to assess for splenomegaly and other signs of portal hypertension. Laboratory tests should include liver function tests, assessment of synthetic liver function (INR, albumin) and fat soluble vitamin levels. No standard recommendation exists on the frequency of these assessments, but they should be checked at minimum on an annual basis. Patients should also have a baseline and annual ultrasound to assess the liver, spleen, and portal vasculature. In addition, ultrasound can be used as a screening tool, as patients with AAT deficiency are at an increased risk of liver cancers, and should also undergo annual alpha-fetoprotein (a plasma protein notably elevated in HCC) testing. If liver disease progresses, management should focus on supportive care for complications of portal hypertension. Children and young adults with portal hypertension should be referred to a liver specialist and evaluated for liver transplant. When liver disease is progressive, monitoring of clotting function, fat-soluble vitamins, and albumin levels is necessary. Vaccination against viral hepatitis and checking vaccine-induced immunity status is recommended in AAT-deficient children with overt liver disease [8].

In the case of AAT-deficient adults, current recommendations are to assess patients by tests of liver function, including asymptomatic individuals [8, 24]. A recent study suggests that effective screening of liver disease in patients with PI\*ZZ-related lung disease should include a combination of conventional tests of liver function, platelet count, and liver ultrasound [23]; however, Clark *et al.* [24] report that an increased level of ALT does not consistently identify liver disease in adults with AAT deficiency. The standard liver supportive care in adults is the same as for many liver diseases (*i.e.*, hepatitis A and B vaccination, physical examination, ultrasound, limitation of alcohol consumption) [8, 15].

The only corrective therapy at present for AAT-deficient patients with severe liver disease is liver transplantation [9, 15], although several potential therapies are under investigation. Novel treatments could include small molecules that inhibit polymerization, compounds that accelerate proteolysis pathways, and gene therapy for inhibiting transcription or translation of mutant Z RNA [9]. An alternative approach has involved the use of dermal fibroblasts isolated from in-

dividuals with AAT deficiency to generate human induced pluripotent stem cell lines, which have been differentiated into hepatocyte-like cells [29]. The ultimate aim of this research is to provide cells suitable for autologous cell-based treatment of AAT deficiency [14].

## 8. LIVER TRANSPLANTATION

AAT deficiency is the most common metabolic disease leading to LT in children, whereas it is a rarer indication for LT among adults [10, 20, 30]. Analysis of subjects from the United Network for Organ Sharing database who underwent LT has shown that AAT deficiency accounted for 1.06% of all adult LTs and 3.51% of pediatric LTs [30].

Indications for considering LT include persistent and recurrent cholestasis, worsening coagulation profile; very high liver enzyme levels, severe AAT deficiency-related glomerulonephritis [7], and ascites as a result of portal hypertension. In a study of 97 PI\*ZZ children, Francavilla *et al.* [20] found that duration of jaundice, severity of bile duct reduplication, severe fibrosis, established cirrhosis, and biochemical abnormalities all predicted outcome and requirement for LT at an early stage of liver disease. Bakula *et al.* [31] concluded from a study in 59 children with cholestasis or chronic hepatitis that LT should not be delayed in PI\*ZZ patients with portal hypertension, esophageal varices, or deterioration of hepatic function. The main outcomes from several studies that describe LT in AAT-deficient patients are summarized in Table 3 [20, 30, 32-34].

Post-transplant outcomes in children with AAT deficiency are no different than for other children undergoing LT. In addition, alpha<sub>1</sub>-PI levels are normalized after LT suggesting that this is a “curative” intervention in selected patients. By observing the changes in patient pulmonary function, LT was shown to stabilize the progression of pulmonary disease [34, 35].

## 9. REASONS FOR THE UNDER-RECOGNITION OF AAT DEFICIENCY AND THE LACK OF ROUTINE DIAGNOSIS OF LIVER COMPLICATIONS

Although accessible, inexpensive, and straightforward testing procedures are available, both liver and lung disease due to AAT deficiency are underdiagnosed. Even for those

**Table 3. Outcomes in patients with AAT deficiency who undergo liver transplantation.**

Reference	Patient Cohort	Outcome
Hughes <i>et al.</i> , 2011 [32]	35 Children	1-year and 10-year survival rates of 82.7% and 76.5%, respectively
Kemmer <i>et al.</i> , 2008 [30]	570 Adults and children	1-, 3-, and 5-year survival was 89%, 85%, and 83%, respectively, for adults vs. 92%, 90%, and 90% for children
Francavilla <i>et al.</i> , 2000 [20]	97 Children with AAT deficiency, 24 of whom received liver transplant	10-year total survival rate of 98%
Prachalias <i>et al.</i> , 2000 [33]	21 Children	40-month survival rate of 100%
Vennarecci, <i>et al.</i> , 1996 [34]	22 Adults and 13 children	1-year survival rate of 73% for adults and 87.5% for children
Filipponi <i>et al.</i> , 1994 [28]	16 Children	22-month survival rate of 94%

who are diagnosed, there is often a long delay, while the vast majority are never diagnosed at all [3, 21, 36, 37]. There is still a lack of awareness of AAT deficiency-related liver and lung disease among the medical community [38-40]. In the case of lung disease, the similarity of the symptoms with those of usual (non-hereditary) COPD, as well as with those of asthma, and the observation that many AAT-deficient individuals may not have clinically significant lung function impairment, adds to the challenge of diagnosing the disorder [8, 11, 38, 48]. A key feature of the diagnosis of AAT deficiency in both liver disease and lung disease is that unequivocal evidence can only be provided by the results of a specific genetic test [41].

#### 10. THE RATIONALE FOR INCREASED VIGILANCE FOR AAT DEFICIENCY-RELATED LIVER DISEASE

It is of crucial importance that both early detection of AAT deficiency and an increased rate of testing susceptible individuals be carried out, so that (i) AAT-deficient individuals can then take measures to preserve pulmonary function (*e.g.*, smoking abstinence or cessation, and preventing infection); (ii) Family members who are at increased risk can be screened and heterozygous carriers detected; and (iii) Effective management for AAT deficiency can be instituted [42-44]. It is of interest in this connection that the screening program of newborn children in Sweden that led to the early detection of AAT deficiency has been shown to prevent adolescent children from starting to smoke [45].

The ATS/ERS have published guidelines for the clinical recognition of AAT deficiency, and recommendations for testing for the disorder (Table 4). Genotyping provides a definitive diagnosis and may also be necessary for detecting heterozygotes [37, 40]. Physicians should be aware of the family history and the need to test family members [38]. Information about the implications of having the test for AAT deficiency should be provided to both adults and older children [40, 46-49].

#### 11. TARGETED TESTING AND POPULATION-BASED SCREENING

The rationale for both targeted testing of individuals with liver disease or COPD (as recommended by official guidelines), versus population-based screening of newborns or adults, have been reviewed previously [37, 44, 50]. At present, population-based screening of neonates, adolescents, or adults is not recommended. Targeted detection programs in combination with awareness programs in different countries have identified a large number of individuals with AAT deficiency [43, 50, 51], as has a population screening study in Italy [52]. Campos *et al.* [41] reported a detection rate for AAT deficiency of 2.8% by US referral laboratories that also included screening of individuals with liver disease, which is higher than the rate observed by testing COPD patients alone. The detection of AAT deficiency by early screening of infants with liver disease has been suggested as being beneficial by Topic *et al.* [53].

#### 12. GENERAL MANAGEMENT OF THE AAT-DEFICIENT PATIENT

When AAT deficiency has been diagnosed, general management should include yearly liver function tests (more frequently if patients have progressive liver disease). If liver enzymes are elevated, liver function tests should be repeated after one month; the patient should be referred to a hepatologist if elevated liver enzyme levels persist.

If liver disease is due to AAT deficiency, follow-up appointments should involve baseline assessment of lung function. If there are concerns about lung function upon examination patients should have a pulmonary consultation and attend yearly pulmonary function testing. There is limited evidence from the literature that screening for pulmonary symptoms is routinely carried out in children with liver disease, but given the natural history of AAT deficiency, children should have routine pulmonary function test screening at least once when they are teenagers and then routinely when they are adults. Other annual exams should consist of a basic metabolic panel, complete blood count, and inflammatory



**Table 4. The ATS/ERS task force's recommendations for genetic testing for AAT deficiency [8]<sup>a</sup>.**

Adults with symptomatic emphysema or COPD	Genetic testing is recommended
Symptomatic adults with asthma with airflow obstruction that is incompletely reversible after aggressive treatment with bronchodilators	
Individuals with unexplained liver disease, including neonates, children, and adults	
Asymptomatic individuals with persistent obstruction on pulmonary function tests with identifiable risk factors (e.g., smoking, occupational exposure)	
Adults with necrotizing panniculitis	
Siblings of an individual with AAT deficiency	Genetic testing should be discussed
Individuals with a family history of COPD or liver disease not known to be attributed to AAT deficiency	

<sup>a</sup>The recommendation type was determined by the Task Force's subjective weighing of all the issues that either supported or opposed genetic testing.

markers to look for signs of other associations with AAT deficiency such as diabetes, inflammatory bowel disease, and renal disease.

When patients develop symptomatic lung disease, they should receive the range of conventional treatments for COPD, as well as vaccinations and prompt treatment of respiratory illness. Augmentation therapy with intravenous purified alpha<sub>1</sub>-PI, a specific treatment for AAT deficiency, is recommended for individuals with obstructive pulmonary disease due to the disorder [8]. Studies of augmentation therapy have shown increased levels of alpha<sub>1</sub>-PI in the lung [54], a slower rate of lung function decline [55-57], a reduced loss of lung tissue [58, 59] and could also lead to a reduced mortality [8].

Planned care follow-up and medical monitoring programs, which can be coordinated by the primary care physician [38], are important, as a lack of adequate follow-up of patients with lung or liver disease will lead to deterioration.

## CONCLUSION

The variability in the presenting symptoms affecting either the liver or the lung across age groups leads to the potential for the AAT-deficient patient to be seen by a wide range of healthcare professionals, both primary care and specialist. Since there are many reasons for the presentation of liver disease in young children, physicians do not routinely include AAT deficiency in the differential diagnosis. A correct diagnosis is important for effective clinical follow-up and for genetic counseling [27]. Detecting liver disease due to AAT deficiency in children could help to prevent them developing lung disease in adulthood.

Primary care physicians have a key role in increasing the awareness and testing of AAT deficiency leading to earlier diagnosis and more time effective management of this disorder; physicians still regard AAT deficiency as primarily a lung disease, and this contributes to the lack of a routine diagnosis of liver disease due to the disorder. The development of guidelines for the recognition of the extra-pulmonary manifestations of AAT deficiency would be of particular benefit to pediatricians and family physicians who might be

unaware of the hepatic implications of for this condition among children.

## CONSENT FOR PUBLICATION

Not applicable.

## CONFLICT OF INTEREST

The authors declare no conflict of interest, financial or otherwise.

## ACKNOWLEDGEMENTS

Declared none.

## REFERENCES

- Laurell CB, Eriksson S. The electrophoretic a-1-globulin pattern of serum in a-1-antitrypsin deficiency. *Scand J Clin Lab Invest* 1963; 15(2): 132-40.
- Sveger T. Liver disease in alpha-1-antitrypsin deficiency detected by screening of 200,000 infants. *N Engl J Med* 1976; 294(24): 1316-21.
- Campos MA, Wanner A, Zhang G, Sandhaus RA. Trends in the diagnosis of symptomatic patients with alpha-1-antitrypsin deficiency between 1968 and 2003. *Chest* 2005; 128(3): 1179-86.
- Lara B. COPD and alpha-1-antitrypsin deficiency. *Arch Bronconeumol* 2010; 46 (Suppl 4): 2-8.
- Rahaghi FF, Sandhaus RA, Strange C, *et al.* The prevalence of alpha-1 antitrypsin deficiency among patients found to have airflow obstruction. *COPD* 2012; 9(4): 352-58.
- Sharp HL, Bridges RA, Krivit W, Freier EF. Cirrhosis associated with alpha-1-antitrypsin deficiency: A previously unrecognized inherited disorder. *J Lab Clin Med* 1969; 73(6): 934-9.
- Sharp HL. History of the first description of childhood liver disease in AATD. *COPD* 2013; 10 (Suppl 1):13-6.
- American Thoracic Society/European Respiratory Society statement: standards for the diagnosis and management of individuals with alpha-1 antitrypsin deficiency. *Am J Respir Crit Care Med* 2003; 168(7): 818-900.
- McLean C, Greene CM, McElvaney NG. Gene targeted therapeutics for liver disease in alpha-1 antitrypsin deficiency. *Biologics* 2009; 3: 63-75.
- Fairbanks KD, Tavill AS. Liver disease in alpha 1-antitrypsin deficiency: A review. *Am J Gastroenterol* 2008; 103(8): 2136-41.
- Stoller JK, Aboussouan LS. A review of alpha-1-antitrypsin deficiency. *Am J Respir Crit Care Med* 2012; 185(3): 246-59.

- [12] Fregonese L, Stolk J, Frants RR, Veldhuisen B. Alpha-1 antitrypsin Null mutations and severity of emphysema. *Respir Med* 2008; 102(6): 876-84.
- [13] Molloy K, Hersh CP, Morris VB, *et al.* Clarification of the risk of chronic obstructive pulmonary disease in alpha-1-antitrypsin deficiency PiMZ heterozygotes. *Am J Respir Crit Care Med* 2014; 189(4): 419-27.
- [14] Lomas DA. Twenty years of polymers: A personal perspective on alpha-1 antitrypsin deficiency. *COPD* 2013; 10 (Suppl 1): 17-25.
- [15] Teckman JH. Liver disease in alpha-1 antitrypsin deficiency: Current understanding and future therapy. *COPD* 2013; 10 (Suppl 1): 35-43.
- [16] Lomas DA, Evans DL, Finch JT, Carrell RW. The mechanism of Z alpha 1-antitrypsin accumulation in the liver. *Nature* 1992; 357(6379): 605-7.
- [17] Moher D, Liberati A, Tetzlaff J, Altman DG. Preferred reporting items for systematic reviews and meta-analyses: The PRISMA statement. *PLoS Med* 2009; 6(7): e1000097.
- [18] Ebell MH, Siwek J, Weiss BD, *et al.* Strength Of Recommendation taxonomy (SORT): A patient-centered approach to grading evidence in the medical literature. *J Am Board Fam Pract* 2004; 17(1): 59-67.
- [19] Moyer V, Freese DK, Whittington PF, *et al.* Guideline for the evaluation of cholestatic jaundice in infants: Recommendations of the North American Society for Pediatric Gastroenterology, Hepatology and Nutrition. *J Pediatr Gastroenterol Nutr* 2004; 39(2): 115-28.
- [20] Francavilla R, Castellaneta SP, Hadzic N, *et al.* Prognosis of alpha-1-antitrypsin deficiency-related liver disease in the era of paediatric liver transplantation. *J Hepatol* 2000; 32(6): 986-92.
- [21] Kalsheker NA. alpha-1-Antitrypsin deficiency: Best clinical practice. *J Clin Pathol* 2009; 62(10): 865-9.
- [22] Sveger T, Eriksson S. The liver in adolescents with alpha 1-antitrypsin deficiency. *Hepatology* 1995; 22(2): 514-7.
- [23] Dawwas MF, Davies SE, Griffiths WJ, Lomas DA, Alexander GJ. Prevalence and risk factors for liver involvement in individuals with PiZZ-related lung disease. *Am J Respir Crit Care Med* 2013; 187(5): 502-8.
- [24] Clark VC, Dhanasekaran R, Brantly M, Rouhani F, Schreck P, Nelson DR. Liver test results do not identify liver disease in adults with alpha(1)-antitrypsin deficiency. *Clin Gastroenterol Hepatol* 2012; 10(11): 1278-83.
- [25] Rudnick DA, Perlmutter DH. Alpha-1-antitrypsin deficiency: A new paradigm for hepatocellular carcinoma in genetic liver disease. *Hepatology* 2005; 42(3): 514-21.
- [26] Rakela J, Goldschmidt M, Ludwig J. Late manifestation of chronic liver disease in adults with alpha-1-antitrypsin deficiency. *Dig Dis Sci* 1987; 32(12):1358-62.
- [27] De Tommaso AM, Rossi CL, Escanhoela CA, *et al.* Diagnosis of alpha-1-antitrypsin deficiency by DNA analysis of children with liver disease. *Arq Gastroenterol* 2001; 38(1): 63-8.
- [28] Filipponi F, Soubrane O, Labrousse F, *et al.* Liver transplantation for end-stage liver disease associated with alpha-1-antitrypsin deficiency in children: Pretransplant natural history, timing and results of transplantation. *J Hepatol* 1994; 20(1): 72-8.
- [29] Rashid ST, Corbineau S, Hannan N, *et al.* Modeling inherited metabolic disorders of the liver using human induced pluripotent stem cells. *J Clin Invest* 2010; 120(9): 3127-36.
- [30] Kemmer N, Kaiser T, Zacharias V, Neff GW. Alpha-1-antitrypsin deficiency: Outcomes after liver transplantation. *Transplant Proc* 2008; 40(5): 1492-4.
- [31] Bakula A, Socha P, Pawlowska J, Teisseyre M, Jankowska I, Kalicinski P. Good and bad prognosis of alpha-1-antitrypsin deficiency in children: When to list for liver transplantation. *Transplant Proc* 2007; 39(10): 3186-88.
- [32] Hughes MG, Jr., Khan KM, Gruessner AC, *et al.* Long-term outcome in 42 pediatric liver transplant patients with alpha 1-antitrypsin deficiency: A single-center experience. *Clin Transplant* 2011; 25(5): 731-6.
- [33] Prachalias AA, Kalife M, Francavilla R, *et al.* Liver transplantation for alpha-1-antitrypsin deficiency in children. *Transpl Int* 2000; 13(3): 207-10.
- [34] Vennarecci G, Gunson BK, Ismail T, *et al.* Transplantation for end stage liver disease related to alpha 1 antitrypsin. *Transplantation* 1996; 61(10): 1488-95.
- [35] Jain AB, Patil V, Sheikh B, *et al.* Effect of liver transplant on pulmonary functions in adult patients with alpha 1 antitrypsin deficiency: 7 cases. *Exp Clin Transplant* 2010; 8(1): 4-8.
- [36] Koczulla R, Bittkowski N, Andress J, *et al.* The German registry of individuals with alpha-1-antitrypsin deficiency--a source for research on patient care. *Pneumologie* 2008; 62(11): 655-8.
- [37] Stoller JK, Brantly M. The challenge of detecting alpha-1 antitrypsin deficiency. *COPD* 2013; 10 (Suppl 1): 26-34.
- [38] Fromer L. Improving diagnosis and management of alpha-1 antitrypsin deficiency in primary care: Translating knowledge into action. *COPD* 2010; 7(3): 192-198.
- [39] Taliercio RM, Chatburn RL, Stoller JK. Knowledge of alpha-1 antitrypsin deficiency among internal medicine house officers and respiratory therapists: Results of a survey. *Respir Care* 2010; 55(3): 322-7.
- [40] Silverman EK, Sandhaus RA. Clinical practice. Alpha-1-antitrypsin deficiency. *N Engl J Med* 2009; 360(26): 2749-57.
- [41] Campos M, Shmuels D, Walsh J. Detection of alpha-1 antitrypsin deficiency in the US. *Am J Med* 2012; 125(7): 623-4.
- [42] Bals R, Koczulla R, Kotke V, Andress J, Blackert K, Vogelmeier C. Identification of individuals with alpha-1-antitrypsin deficiency by a targeted screening program. *Respir Med* 2007; 101(8): 1708-14.
- [43] Aboussouan LS, Stoller JK. Detection of alpha-1 antitrypsin deficiency: A review. *Respir Med* 2009; 103(3): 335-41.
- [44] Hogarth DK, Rachelefsky G. Screening and familial testing of patients for alpha 1-antitrypsin deficiency. *Chest* 2008; 133(4): 981-8.
- [45] Thelin T, Sveger T, McNeil TF. Primary prevention in a high-risk group: smoking habits in adolescents with homozygous alpha-1-antitrypsin deficiency (ATD). *Acta Paediatr* 1996; 85(10): 1207-12.
- [46] Coors ME, Moseley R, McGorray S. Informed consent process in Alpha-1 testing of at-risk children: views of parents and adults tested as children. *COPD* 2011; 8(1): 30-8.
- [47] Klitzman R. The impact of social contexts in testing for alpha-1 antitrypsin deficiency: The roles of physicians and others. *Genet Test Mol Biomarkers* 2009; 13(2): 269-76.
- [48] Sveger T, Thelin T, McNeil TF. Young adults with alpha 1-antitrypsin deficiency identified neonatally: Their health, knowledge about and adaptation to the high-risk condition. *Acta Paediatr* 1997; 86(1): 37-40.
- [49] Sveger T, Thelin T, McNeil TF. Neonatal alpha-1-antitrypsin screening: Parents' views and reactions 20 years after the identification of the deficiency state. *Acta Paediatr* 1999; 88(3): 315-8.
- [50] Sveger T, Thelin T. A future for neonatal alpha-1-antitrypsin screening? *Acta Paediatr* 2000; 89(6): 628-31.
- [51] Carroll TP, O'Connor CA, Floyd O, *et al.* The prevalence of alpha-1 antitrypsin deficiency in Ireland. *Respir Res* 2011; 12: 91.
- [52] Corda L, Medicina D, La Piana GE, *et al.* Population genetic screening for alpha-1-antitrypsin deficiency in a high-prevalence area. *Respiration* 2011; 82(5): 418-25.
- [53] Topic A, Prokic D, Stankovic I. Alpha-1-antitrypsin deficiency in early childhood. *Fetal Pediatr Pathol* 2011; 30(5): 312-9.
- [54] Wewers MD, Casolaro MA, Crystal RG. Comparison of alpha-1-antitrypsin levels and antineutrophil elastase capacity of blood and lung in a patient with the alpha-1-antitrypsin phenotype null-null before and during alpha-1-antitrypsin augmentation therapy. *Am Rev Respir Dis* 1987; 135(3): 539-43.
- [55] Seersholm N, Wencker M, Banik N, *et al.* Does alpha-1-antitrypsin augmentation therapy slow the annual decline in FEV1 in patients with severe hereditary alpha-1-antitrypsin deficiency? *Wissenschaftliche Arbeitsgemeinschaft zur Therapie von Lungenerkrankungen (WATL) alpha-1-AT study group. Eur Respir J* 1997; 10(10): 2260-63.
- [56] Wencker M, Banik N, Buhl R, Seidel R, Konietzko N. Long-term treatment of alpha-1-antitrypsin deficiency-related pulmonary emphysema with human alpha-1-antitrypsin. *Wissenschaftliche*



- Arbeitsgemeinschaft zur Therapie von Lungenerkrankungen (WATL)-alpha1-AT-study group. *Eur Respir J* 1998; 11(2): 428-33.
- [57] Survival and FEV1 decline in individuals with severe deficiency of alpha1-antitrypsin. The Alpha-1-Antitrypsin Deficiency Registry Study Group. *Am J Respir Crit Care Med* 1998; 158(1): 49-59.
- [58] Dirksen A, Dijkman JH, Madsen F, *et al.* A randomized clinical trial of alpha(1)-antitrypsin augmentation therapy. *Am J Respir Crit Care Med* 1999; 160(5 Pt 1): 1468-72.
- [59] Dirksen A, Piitulainen E, Parr DG, *et al.* Exploring the role of CT densitometry: A randomised study of augmentation therapy in alpha1-antitrypsin deficiency. *Eur Respir J* 2009; 33(6): 1345-53.