

# Antiadhesive effect and safety of sodium hyaluronate-carboxymethyl cellulose membrane in thyroid surgery

Dong Sik Bae\*, Jung-Woo Woo<sup>1,\*</sup>, Se Hyun Paek<sup>1</sup>, Hyungju Kwon<sup>2</sup>, Young Jun Chai<sup>1</sup>, Su-jin Kim<sup>1</sup>, June Young Choi<sup>2</sup>, Kyu Eun Lee<sup>1</sup>, Yeo-Kyu Youn<sup>1</sup>

Department of Surgery, Inje University Haeundae Paik Hospital, Inje University College of Medicine, Busan, <sup>1</sup>Department of Surgery, Seoul National University Hospital, Seoul, <sup>2</sup>Department of Surgery, Seoul National University Bundang Hospital, Seongnam, Korea

**Purpose:** A number of researchers have suggested the use of sodium hyaluronate carboxymethyl cellulose (HA-CMC) membrane for preventing postoperative adhesion. This study evaluated the antiadhesive effect and safety of HA-CMC membrane in thyroidectomy for papillary thyroid cancer.

**Methods:** One hundred sixty-two patients who underwent thyroidectomy were prospectively randomized. In the study group of 80 patients, the 7.5 cm × 13 cm HA-CMC membrane was applied to the operative field after thyroidectomy. The subjects were asked about complications including adhesive symptoms using an 8-item questionnaire at 2 weeks, 3 months, and 6 months after surgery. In addition, items on the appearance of neck wrinkles and scars were evaluated by a physician who had no information about the patient's allocation.

**Results:** There were no significant differences in complications such as swallowing difficulty, and wrinkles between study and control groups. Both groups presented significantly decreased scores over time in swallowing difficulty, and wrinkles. There were no complications regarding the HA-CMC membrane.

**Conclusion:** The antiadhesive effect of HA-CMC membrane in thyroid surgery is still uncertain, although it is biologically safe. Further investigation is needed to confirm the antiadhesive effect of HA-CMC membrane in thyroid surgery.

## INTRODUCTION

Thyroid cancer is the most common cancer in Korea [1]. Papillary thyroid cancer (PTC) is the most common but least aggressive histologic subtype of thyroid cancer. Most patients with PTC have an excellent prognosis. These excellent prognoses accentuate the lower complication rate of thyroid surgery and the improved postoperative quality of life. Many studies have evaluated the major complications of thyroidectomy, such as hypoparathyroidism and recurrent laryngeal nerve injury, but postoperative adhesive symptoms have been overlooked in those previous studies. Many patients complain of adhesive symptoms including swallowing difficulty or a pulling sensation during neck extension [2]. Moreover, internal adhesion scars after neck surgery are often externally visible (Fig. 1).

Numerous antiadhesive agents such as nadroparine calcium and aprotinin have been introduced. Barrier agents such as a sodium hyaluronatecarboxymethyl cellulose (HA-CMC) membrane (Seprafilm, Genzyme Co., Cambridge, MA, USA), HA-CMC solution (Guardix, Hanmi Medicare, Seoul, Korea), and an oxidized regenerated cellulose barrier (Interceed, Ethicon Inc., Somerville, NJ, USA) have also been used. The efficacy of these agents has been evaluated exclusively in the peritoneal and

### Corresponding Author

Kyu Eun Lee  
Department of Surgery, Seoul National University Hospital, 101 Daehak-ro, Jongno-gu, Seoul 110-744, Korea  
Tel: +82-2-2072-2081  
Fax: +82-2-766-3975  
E-mail: kyu.eun.lee.md@gmail.com

\*These authors contributed equally to this study and should be considered co-first authors.

### Key Words

Sodium hyaluronate carboxymethyl cellulose, HA-CMC, Seprafilm, Adhesion, Thyroid

Received May 22, 2013  
Revised August 2, 2013  
Accepted August 22, 2013

J Korean Surg Soc 2013;85:199-204  
<http://dx.doi.org/10.4174/jkss.2013.85.5.199>

Copyright © 2013, the Korean Surgical Society

© Journal of the Korean Surgical Society is an Open Access Journal. All articles are distributed under the terms of the Creative Commons Attribution Non-Commercial License (<http://creativecommons.org/licenses/by-nc/3.0/>) which permits unrestricted non-commercial use, distribution, and reproduction in any medium, provided the original work is properly cited.

pelvic cavities. Studies on these agents have primarily focused on evaluating abdominal or pelvic pain, as well as intestinal obstructions and infertility [3-8].

An HA-CMC membrane (Sefrafilm) was developed to reduce the formation of postoperative adhesions. Each chemical constituent in the solution has been shown to prevent the development of adhesion [9].

As far as we know, this is the first randomized double-blinded prospective study to evaluate the antiadhesive effect and safety of HA-CMC membranes in thyroidectomy.

## METHODS

### Patients

Between February and November 2011, 192 patients who

underwent total thyroidectomy due to micro-PTC smaller than 1 cm, which was confined to thyroid tissue, were initially enrolled in this study. Age of patients ranges from 20 to 70. All operations were done by a specialized endocrine surgery team (Y.Y.K., L.K.E., C.J.Y.). The number of patients enrolled was calculated based on a previous study that had used a HA-CMC solution [2].

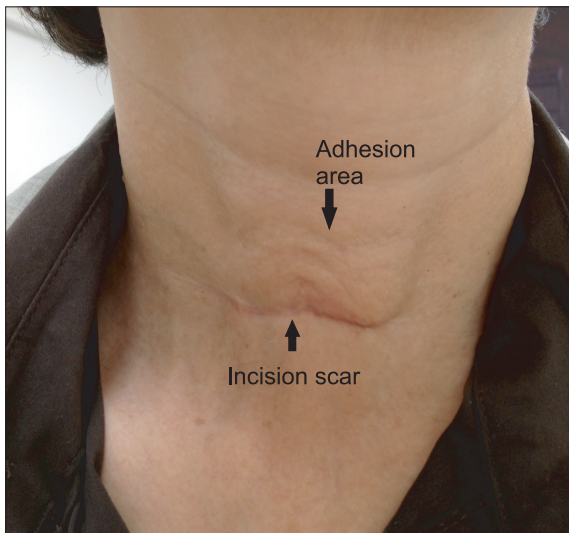
Patients were excluded if they had a history of previous neck surgery, radiation exposure, an uncontrolled medical illness causing swallowing difficulty like stroke or drug abuse. Following approval by the Institutional Review Board (IRB No. H-1011-009-338), all patients gave their written informed consent to participate in the study. The patients were randomized with 96 patients in both the study and control groups using a web-based randomized allocation protocol.

Twenty patients were dropped because of lateral lymph node dissection during the operation; 6 were dropped because of loss of follow-up in the outpatient department; 3 were dropped because their final pathologic reports were benign follicular neoplasm, and one patient was dropped as the patient's operation was cancelled due to the development of anaphylactic shock before the operation. Thus, finally, the study group and control group consisted of 80 and 82 patients, respectively. All patients and the examiner were blinded to the group allocation.

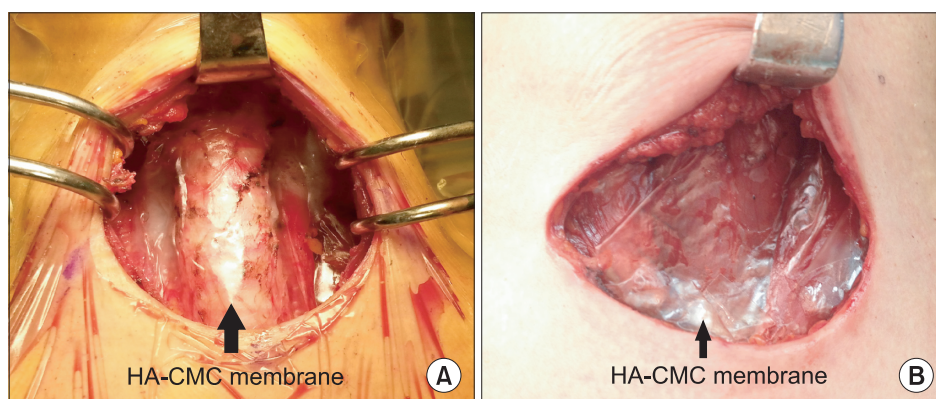
This system used a 4 × 6 random permuted block operated by the Medical Research Collaborating Center (MRCC), Seoul, Korea. Randomization was done after the completion of hemostasis and before closing the strap muscle with a double blinded method.

### Antiadhesion

HA-CMC membranes (Sefrafilm) are nontoxically denatured polysaccharides composed of hyaluronic acid and carboxymethyl cellulose. This material transforms to a



**Fig. 1.** Postthyroidectomy adhesion. A noticeable scar and marked sunken wrinkles above the scar are evident (pictured at postoperative month 3).



**Fig. 2.** Application of hyaluronate carboxymethyl cellulose (HA-CMC) membrane after total thyroidectomy. (A) HA-CMC membrane is rapping trachea in operative bed. (B) Subflap application of the HA-CMC membrane. HA-CMC membrane is rapping strap muscles in neck.

hydrophilic gel in a wet environment within 48 hours and then functions as a protective coat for 7 to 30 days. HA-CMC membranes degrade within 1 month *in vivo*.

Each patient in the initial study group had a 7.5 cm × 13 cm HA-CMC membrane applied to the operative field: the thyroid bed, around the trachea, and the flapped area beneath the platysma (Fig. 2). Patients in the initial control group did not have the HA-CMC membrane applied. At 2 weeks, 3 months and 6 months postoperatively, complications including swallowing difficulty, wrinkles, and inflammation were assessed using 8 items (Table 1). Among these items, swallowing difficulty and wrinkles are items concerning the antiadhesive effect of the HA-CMC membrane, and inflammation is an item regarding the safety of the HA-CMC membrane. At each assessment, a physician who did not know the allocation of the patients examined the patients and described their scores on neck wrinkles.

**Table 1.** Items used to assess postoperative complications after thyroidectomy

Question	Score
1. Swallowing difficulty	
1-1. Difficulties in swallowing saliva	1-2-3-4-5
1-2. Difficulties in swallowing water	1-2-3-4-5
1-3. Difficulties in swallowing food	1-2-3-4-5
2. Wrinkle	
2-1. Severity of wrinkle (patient's finding)	1-2-3-4-5
2-2. Severity of wrinkle at resting (physician's finding)	1-2-3-4-5
2-3. Severity of wrinkle at extension (physician's finding)	1-2-3-4-5
2-4. Severity of wrinkle at swallowing (physician's finding)	1-2-3-4-5
3. Inflammation	
3-1. Inflammatory change on the neck (physician's finding)	1-2-3-4-5

**Table 2.** Clinical characteristics of patients in the control and study group

Characteristic	Study group (n = 80)	Control group (n = 82)	P-value
Sex			0.920
Male	18	19	
Female	62	63	
Age (yr)	52.29 ± 10.46 (23-70)	49.48 ± 10.32 (24-69)	0.087
Duration of operation (min)	86.99 ± 21.47 (45-170)	87.73 ± 23.54 (38-175)	0.834

Values are presented as mean ± standard deviation (range).

## Statistical analysis

Statistical analysis was performed using IBM SPSS ver. 18.0 (IBM Co., Armonk, NY, USA). A repeated measures analysis of variance (ANOVA) test was used to analyze the changes in complications between the different postoperative periods and to compare complications between the study and control groups at each postoperative time point. Continuous variables were expressed as the mean ± standard deviation, and statistical significance was defined as  $P < 0.05$ . MRCC provided advice on statistical analyses and illustration of graphs.

## RESULTS

The clinical characteristics of the final 162 patients included in this study are presented in Table 2. The two groups were comparable with regard to sex, age, and operation time. There were no major complications such as bleeding, inflammation, aspiration, or dyspnea.

Table 3 presents minor complications such as swallowing difficulty and wrinkles. There were no significant differences between the study group and control group. The distribution pattern was not a normal variation; therefore, the repeated measures ANOVA test was used to analyze the changes in complications between different postoperative periods and to compare the complications between the study and control groups at each postoperative time point.

Table 4 presents the results of the repeated measures ANOVA test for swallowing difficulty and wrinkles, respec-

**Table 3.** Complications after total thyroidectomy

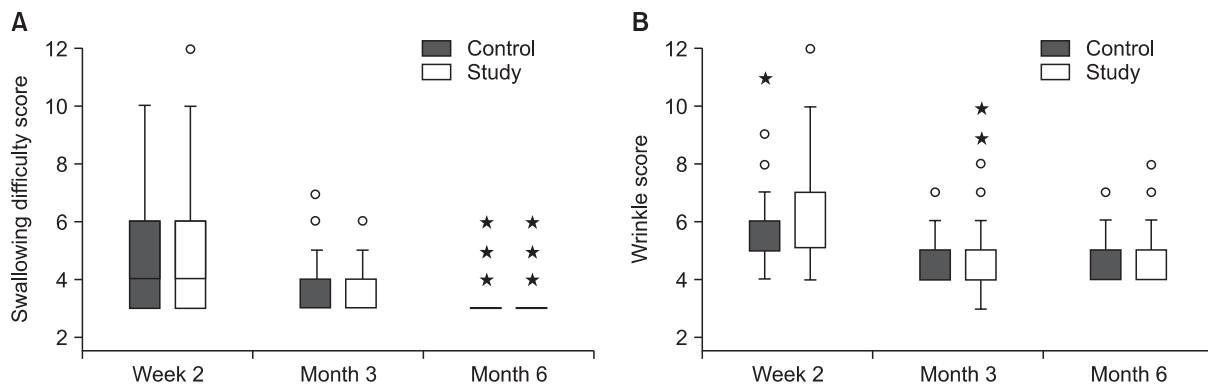
	Study group (n = 80)	Control group (n = 82)	P-value
2 Weeks after surgery			
Swallowing difficulty	4.88 ± 1.912 (3-12)	4.67 ± 1.678 (3-10)	0.471
Wrinkle	5.88 ± 1.649 (4-12)	5.72 ± 1.289 (4-11)	0.504
3 Months after surgery			
Swallowing difficulty	3.58 ± 0.991 (3-6)	3.52 ± 0.919 (3-7)	0.736
Wrinkle	5.06 ± 1.408 (3-10)	4.89 ± 0.956 (4-7)	0.363
6 Months after surgery			
Swallowing difficulty	3.35 ± 0.813 (3-6)	3.24 ± 0.579 (3-6)	0.339
Wrinkle	4.60 ± 0.989 (4-8)	4.43 ± 0.786 (4-7)	0.218

Values are presented as mean ± standard deviation (range).

**Table 4. A repeated measures ANOVA test for swallowing difficulty and wrinkle**

	Swallowing difficulty			Wrinkle		
	T	Degree of freedom	P-value	T	Degree of freedom	P-value
Group	0.177	1	0.6744	0.226	1	0.6347
Time	157.14	1.63347	<0.0001	229.487	1.92526	<0.0001
Group × time	0.066	1.63347	0.9354	1.523	1.92526	0.4490

ANOVA, analysis of variance.



**Fig. 3.** Swallowing difficulty score (A) and wrinkle score (B) at each postoperative time point. The scores significantly decreased over time ( $P < 0.0001$ ). A repeated measures analysis of variance test was used to analyze the changes in complications between different postoperative periods. Each box shows the range from the 25th percentile to the 75th percentile. Mild outliers are any score more than  $1.5 \times IQR$  from the rest of the scores and are indicated by open dots. IQR stands for “interquartile range”, and is the middle 50% of the scores. Extreme outliers are any score more than  $3 \times IQR$  from the rest of the scores and are indicated by stars.

tively. Both swallowing difficulty and wrinkles decreased over time ( $P < 0.0001$ ), but use of the HA-CMC membrane was associated with neither swallowing difficulty nor wrinkles. There were no significant differences between the study and control groups. Fig. 3 shows these results for swallowing difficulty, and wrinkles.

## DISCUSSION

The aim of this study was to evaluate the antiadhesive effect and safety of HA-CMC membranes in thyroidectomy. We showed that there was no significant difference in the total adhesion score between patients to whom the HA-CMC membrane was applied during surgery and the control group. This is believed to be the first prospective double-blinded randomized controlled study to evaluate the effects of HA-CMC membranes in thyroid surgery.

An ideal adhesion barrier should be degradable and not cause a foreign body reaction, impair wound healing, or promote infection [10]. To prevent contact between the injured areas, a barrier agent should remain effective for an adequate amount of time to allow reestablishment of the mesothelium [8].

Postoperative adhesion formation causes significant surgical

morbidities such as intestinal obstruction, infertility, and complicated reoperations and continues to be an economic burden on the healthcare system [11,12]. Many factors, including trauma, ischemia, foreign material, and deposition of blood contribute significantly to the risk of postoperative adhesion formation [13,14]. Adhesion barrier devices that are used to separate tissue surfaces and prevent adhesions are an increasingly accepted adjunct to abdominopelvic surgery. Many studies have shown the antiadhesive effect of HA-CMC in animal models, human abdominal surgery, human facial surgery, human esophageal surgery, human breast surgery and human craniotomy [15-22]. Among them, there were interesting studies on a novel antiadhesive film based on cross-linked carboxymethylcellulose and atorvastatin, with that of sodium hyaluronate-carboxymethylcellulose [23,24]. They reported an equivocal or more improved antiadhesive effect of the novel material.

We speculated that the HA-CMC membrane did not have an antiadhesive effect in thyroid surgery because the membrane type antiadhesive material did not have a lubricating effect between the neck muscles. There is no natural barrier in the neck space in contrast to the abdominal cavity where the peritoneum functions as a natural barrier. In the abdominal cavity, membrane type antiadhesive materials may be enough

to prevent adhesion between the peritoneum and bowel since the peritoneum may separate organs during healing. However in the neck space, both separation and lubrication could be necessary to prevent adhesion since there is no natural barrier like the peritoneum. Thus, the HA-CMC membrane may not be an ideal antiadhesive material in thyroid surgery compared to the HA-CMC solution. The HA-CMC solution showed a little antiadhesive effect although there was no significant effect [2].

There were no complications related to the application of the HA-CMC membranes in the study group. The HA-CMC membrane has been shown to be safe for use in abdominal or pelvic surgery, with respect to abscess formation, pulmonary embolism, and foreign body reactions. The HA-CMC membrane also did not have adverse effects on the oncological outcome of adjuvant therapy [7]. However, wrapping the sutures or staple line of a fresh bowel anastomosis should be avoided due to the increased risk of sequelae associated with anastomotic leakages [13]. Considering our results and the absence of such anastomosis in the operative field, it appears that the HA-CMC membrane is safe for application in thyroidectomies.

Most patients in the present study showed signs and symptoms of postoperative adhesion to some degree. Primarily as a result of the loss of normal tissue planes caused by postoperative adhesion, a second thyroid operation is associated with a high rate of complications, such as hypoparathyroidism and recurrent laryngeal nerve injury [25].

At present, there is no reliable method for measuring the adhesion grade, and we could not do anything other than use a questionnaire with a visual analogue scale, which is the limitation of this study.

Age may be an important factor to adhesion, so subgroup analysis was done with the cutoff value of age 50. However, there was no significant difference in subgroup analysis. The P-value of swallowing difficulty were 0.164 in age  $\leq$ 50 group, and 0.963 in age  $>$ 50 group. And the P-value of wrinkle were 0.872 in age  $\leq$ 50 group, and 0.437 in age  $>$ 50 group.

In conclusion, the present study shows that the signs and symptoms of postoperative adhesion after thyroidectomy are common but decrease over time. The application of an HA-CMC membrane in thyroidectomy is safe but the antiadhesive effect of HA-CMC membrane in thyroid surgery is still uncertain. Further investigation is needed to confirm the antiadhesive effect of HA-CMC membrane in thyroid surgery.

## CONFLICTS OF INTEREST

No potential conflict of interest relevant to this article was reported.

## ACKNOWLEDGEMENTS

This work was sponsored by unrestricted study grant from Genzyme. We are indebted to MRCC for their statistical assistance. And we want to express our special gratitude to Dr. Woo's wife Min Hye Kim for her infinite understanding and dedication.

## REFERENCES

1. Jung KW, Park S, Kong HJ, Won YJ, Lee JY, Seo HG, et al. Cancer statistics in Korea: incidence, mortality, survival, and prevalence in 2009. *Cancer Res Treat* 2012;44:11-24.
2. Park WS, Chung YS, Lee KE, Kim HY, Choe JH, Koh SH, et al. Anti-adhesive effect and safety of sodium hyaluronate and sodium carboxymethyl cellulose solution in thyroid surgery. *Asian J Surg* 2010;33:25-30.
3. Becker JM, Dayton MT, Fazio VW, Beck DE, Stryker SJ, Wexner SD, et al. Prevention of postoperative abdominal adhesions by a sodium hyaluronate-based bioresorbable membrane: a prospective, randomized, double-blind multicenter study. *J Am Coll Surg* 1996;183:297-306.
4. Fazio VW, Cohen Z, Fleshman JW, van Goor H, Bauer JJ, Wolff BG, et al. Reduction in adhesive small-bowel obstruction by Sefrafilin adhesion barrier after intestinal resection. *Dis Colon Rectum* 2006;49:1-11.
5. Kutlay J, Ozer Y, Isik B, Kargici H. Comparative effectiveness of several agents for preventing postoperative adhesions. *World J Surg* 2004;28:662-5.
6. Metwally M, Cheong Y, Li TC. A review of techniques for adhesion prevention after gynaecological surgery. *Curr Opin Obstet Gynecol* 2008;20:345-52.
7. Kusunoki M, Ikeuchi H, Yanagi H, Noda M, Tonouchi H, Mohri Y, et al. Bioresorbable hyaluronate-carboxymethylcellulose membrane (Sefrafilin) in surgery for rectal carcinoma: a prospective randomized clinical trial. *Surg Today* 2005;35:940-5.
8. Zeng Q, Yu Z, You J, Zhang Q. Efficacy and safety of Sefrafilin for preventing postoperative abdominal adhesion: systematic review and meta-analysis. *World J Surg* 2007;31:2125-31.
9. Yigit O, Uslu Coskun B, Coskun H, Yilmaz B, Alkan S, Cinar U, et al. Efficacy of anti-adhesive barriers in secondary thyroidectomy: an experimental study. *Laryngoscope* 2004;114:1668-73.
10. Osada H, Minai M, Tsunoda I, Fujii TK, Tsubata K, Satoh K. The effect of hyaluronic acid-carboxymethylcellulose in reducing adhesion reformation in rabbits. *J Int Med Res* 1999;27:292-6.
11. Baakdah H, Tulandi T. Adhesion in gynecology complication, cost, and prevention: a review. *Surg Technol Int* 2005;14:185-90.
12. Parker MC, Wilson MS, Menzies D, Sunderland G, Thompson JN, Clark DN, et al. Colorectal surgery: the risk and burden of adhesion-related complications. *Colorectal Dis* 2004;6:506-11.

13. Menzies D. Peritoneal adhesions. Incidence, cause, and prevention. *Surg Annu* 1992;24 Pt 1:27-45.
14. Divilio LT. Surgical adhesion development and prevention. *Int Surg* 2005;90(3 Suppl):S6-9.
15. Greenawalt KE, Corazzini RL, Colt MJ, Holmdahl L. Adhesion formation to hemostatic agents and its reduction with a sodium hyaluronate/carboxymethylcellulose adhesion barrier. *J Biomed Mater Res A* 2012;100:1777-82.
16. Yang EJ, Kang E, Jang JY, Kim D, Yom CK, Lim JY, et al. Effect of a mixed solution of sodium hyaluronate and carboxymethyl cellulose on upper limb dysfunction after total mastectomy: a double-blind, randomized clinical trial. *Breast Cancer Res Treat* 2012;136:187-94.
17. Bristow RE, Montz FJ. Prevention of adhesion formation after radical oophorectomy using a sodium hyaluronate-carboxymethylcellulose (HA-CMC) barrier. *Gynecol Oncol* 2005;99:301-8.
18. Mumert ML, Altay T, Couldwell WT. Technique for decompressive craniectomy using Seprafilm as a dural substitute and anti-adhesion barrier. *J Clin Neurosci* 2012;19:455-7.
19. Ahn JH, Lim HW, Hong HR. The clinical application and efficacy of sodium hyaluronate-carboxymethylcellulose during tympanomastoid surgery. *Laryngoscope* 2012;122:912-5.
20. Hashimoto D, Hirota M, Yagi Y, Baba H. Hyaluronate carboxymethylcellulose-based bioresorbable membrane (Seprafilm) reduces adhesion under the incision to make unplanned re-laparotomy safer. *Surg Today* 2012;42:863-7.
21. Sheldon HK, Gainsbury ML, Cassidy MR, Chu DI, Stucchi AF, Becker JM. A sprayable hyaluronate/carboxymethylcellulose adhesion barrier exhibits regional adhesion reduction efficacy and does not impair intestinal healing. *J Gastrointest Surg* 2012;16:325-33.
22. Krill LS, Ueda SM, Gerardi M, Bristow RE. Analysis of postoperative complications associated with the use of anti-adhesion sodium hyaluronate-carboxymethylcellulose (HA-CMC) barrier after cytoreductive surgery for ovarian, fallopian tube and peritoneal cancers. *Gynecol Oncol* 2011;120:220-3.
23. Lalountas M, Ballas KD, Michalakis A, Psarras K, Asteriou C, Giakoustidis DE, et al. Postoperative adhesion prevention using a statin-containing cellulose film in an experimental model. *Br J Surg* 2012;99:423-9.
24. Lalountas MA, Ballas KD, Skouras C, Asteriou C, Kontoulis T, Pissas D, et al. Preventing intraperitoneal adhesions with atorvastatin and sodium hyaluronate/carboxymethylcellulose: a comparative study in rats. *Am J Surg* 2010;200:118-23.
25. Chao TC, Jeng LB, Lin JD, Chen MF. Reoperative thyroid surgery. *World J Surg* 1997;21:644-7.