

## REVIEW

# Chronic rhinosinusitis in patients with cystic fibrosis—Current management and new treatments

Brian Jake Johnson MD  | Garret W. Choby MD  | Erin K. O'Brien MD 

Department of Otorhinolaryngology, Mayo Clinic, Rochester, Minnesota

**Correspondence**Erin K. O'Brien MD, Department of Otorhinolaryngology, Mayo Clinic, 200 First Street SW, Rochester, MN 55905.  
Email: obrien.erin@mayo.edu**Abstract**

**Objectives:** The purpose of this article is to provide a state-of-the-art review of the literature and summarize the latest publications on medical and surgical treatment of cystic fibrosis (CF) chronic rhinosinusitis (CRS), with an emphasis on describing recent advancements in cystic fibrosis transmembrane conductance regulator (CFTR) modulator therapies.

**Methods:** A comprehensive literature review was conducted utilizing the PubMed database with search phrases detailed within the body of the article. Abstracts were reviewed to include publications detailing medical, surgical, and CFTR modulating therapies for CF CRS. Findings from studies not previously reviewed and publications regarding CFTR modulators were emphasized.

**Results:** No clear guidelines for treatment of CF CRS are available. Nasal saline rinses, topical steroids, topical antibiotics, and topical dornase alfa are reported medical therapies. Ivacaftor has some sinonasal symptomatic benefit. A new triple therapy CFTR modulator, elexacaftor/tezacaftor/ivacaftor, is capable of treating 90% of patients with CF and has shown the greatest FEV1 improvement of any CFTR modulator yet. There is no clear consensus on surgical indications or technique, though aggressive surgery in recalcitrant disease has shown some symptomatic benefit. Endoscopic sinus surgery after lung transplantation may benefit some patients in whom the sinuses serve as a reservoir for recurrent pulmonary infections by decreasing rates of bronchiolitis obliterans syndrome and improving 5 year survival.

**Conclusion:** As lifespan increases for patients with CF, further investigation into medical therapy, CFTR modulator sinonasal outcomes, and surgical technique and outcomes for CF CRS is needed.

**Level of Evidence:** 5.

**KEYWORDS**

CF, CFTR modulator, chronic rhinosinusitis, cystic fibrosis, endoscopic sinus surgery, sinus disease

This is an open access article under the terms of the Creative Commons Attribution-NonCommercial-NoDerivs License, which permits use and distribution in any medium, provided the original work is properly cited, the use is non-commercial and no modifications or adaptations are made.

© 2020 The Authors. *Laryngoscope Investigative Otolaryngology* published by Wiley Periodicals, Inc. on behalf of The Triological Society.

## 1 | INTRODUCTION

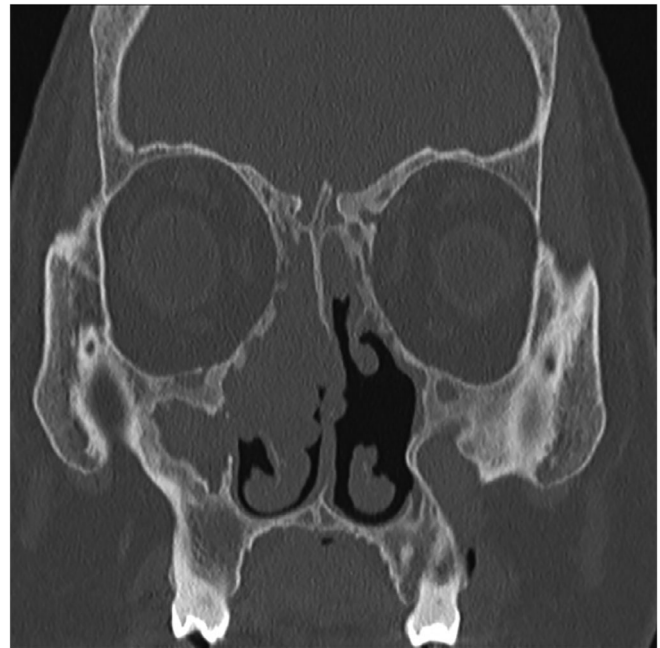Cystic fibrosis (CF) is an autosomal recessive disease caused by defective CF transmembrane conductance regulator (CFTR) protein. Mutations in the CFTR gene result in impaired chloride transport to the luminal surface of mucosal epithelium, aberrations in sodium and water resorption, and ultimately, viscous secretions in multiple organs. CF affects 30 000 Americans with nearly 1000 new cases diagnosed yearly. The thickened and tenacious mucus causes disease in the upper and lower airways, gastrointestinal tract, and genitourinary system.<sup>1,2</sup> Research focus and treatment development has been heavily centered on the lungs, as pulmonary disease is the main driver of mortality in CF.<sup>1</sup> However, sinonasal disease is important in patients with CF, both as a source of symptomatic quality of life burden and as a reservoir for pulmonary disease.<sup>3</sup>

## 2 | METHODS

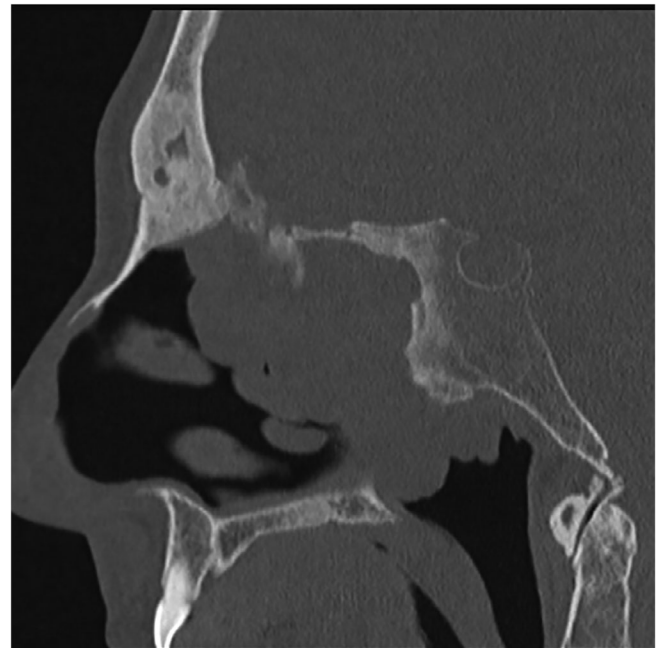
The PubMed database was utilized to review current published literature regarding CF chronic rhinosinusitis (CRS). The following search phrases were used: "cystic fibrosis chronic rhinosinusitis," "cystic fibrosis chronic rhinosinusitis medical," "cystic fibrosis chronic rhinosinusitis surgical," "cystic fibrosis ivacaftor," "cystic fibrosis lumacaftor," "cystic fibrosis tezacaftor," and "cystic fibrosis elexacaftor." This article aims to review current CF CRS medical and surgical therapies, and present evidence on new CFTR modulators.

### 2.1 | Sinonasal manifestations of CF

In the nasal cavity and paranasal sinuses, CF induces chronic disease due to compromise of mucociliary clearance (MCC). The viscous epithelial secretions and inspissated mucus can lead to CRS via impaired MCC, recurrent and/or persistent infection, intramucosal microabscesses, and TH1 mediated and neutrophil predominant inflammation.<sup>1</sup> This is in contrast to the TH2 mediated inflammation of more common forms of nasal polyposis.<sup>1</sup> Though less than 20% of CF patients self-report CRS symptoms, 2/3 have polyposis and up to 100% of CF patients have radiographic or endoscopic evidence of sinonasal inflammation.<sup>1,2,4</sup> Radiographic imaging of the paranasal sinuses in patients with CF tends to demonstrate bony demineralization, medialization of the lateral nasal wall, sinus opacification, paranasal sinus bone sclerosis, and sinus hypoplasia/under pneumatization (Figures 1 and 2).<sup>4</sup> Furthermore, among patients with CF, those with more severe genotypes have worse disease on sinus computed tomography (CT) scan and more often have sinus hypoplasia/aplasia compared to those with less severe genotypes.<sup>5</sup> Adults with CF CRS have significantly worse Lund-Kennedy (LK) scores compared to those without CF, but endoscopic findings are similar in CF patients regardless of the presence of CRS symptoms.<sup>6</sup> The discordance of objective findings and symptoms creates difficulty in diagnosing and treating patients with CF CRS. However, a recent prospective study



**FIGURE 1** Computed tomography (CT) scan CT findings of a patient with CF CRS. Note the poor pneumatization of the frontal, maxillary, and sphenoid sinuses, as well as the sclerotic/osteitic bony remodeling. CF, cystic fibrosis; CRS, chronic rhinosinusitis



**FIGURE 2** Sagittal CT computed tomography (CT) scan findings of a patient with CF CRS. Note the poor pneumatization of the frontal, maxillary, and sphenoid sinuses, as well as the sclerotic/osteitic bony remodeling. CF, cystic fibrosis; CRS, chronic rhinosinusitis

of 33 post-endoscopic sinus surgery (ESS) patients with CF CRS and diverse lung function found that CRS exacerbation was associated with an odds ratio of 2.07 for having a pulmonary exacerbation recorded at the next visit.<sup>7</sup> Given the common findings of significant

objective disease on imaging and endoscopy, acute change in sinonasal symptomatology may alert the clinician to impending pulmonary exacerbation.

As understanding of the disease and subsequent therapies, including lung transplantation, continue to improve, the life expectancy of CF patients has increased. For people with CF born between 2012 and 2017, median projected survival age is 43.6 years, compared to 32.7 for those born from 2002 to 2007.<sup>2</sup> As a direct result of this increased life span, more patients with CF are requiring long-term management of their CRS and nasal polyposis.

## 2.2 | Genetics

Mutations in the CFTR gene cause abnormal transcription or translation and affect functional chloride transport at the cell membrane.<sup>8</sup> Nearly 2000 genetic variants have been identified, with the most common mutation being F508del.<sup>8</sup> Eighty-six percent of patients with CF carry at least one copy of this mutation, and no other allelic variant is found in more than 5% of patients.<sup>2,8</sup> Mutations are grouped into one of five classes, based on the type of defect caused: synthetic, trafficking, channel gating, channel conductance, and transcription levels.<sup>9</sup> Classes I to III are considered minimal function CFTR mutations and cause more severe phenotypes, while those in IV to V have residual function in CFTR and cause less severe phenotypes.<sup>9</sup> The definitions of minimal and residual function have been based on the disease severity generally associated with these genotypes, as well as their responsiveness to CFTR modulating therapies.<sup>10,11</sup> Patients with residual function CFTR exhibit the typical spectrum of CF disease, yet disease that progresses much more slowly than those with minimal function CFTR.<sup>10,11</sup> Though this classification system provides a framework for understanding loss of function of CFTR based on the mutation, it has become clear that individual CFTR mutations alone do not completely predict the disease phenotype.<sup>8</sup> For example, F508del leads to misfolding and degradation of the protein product, aberrant chloride channel function, and reduced quantity of protein translated.<sup>8</sup> It has also been found that variants of other genes, distinct from CFTR, can modify CF phenotype and influence onset of CF-related sequelae.<sup>8</sup> Though all of this information highlights the complexity of the disease, it also has allowed for a paradigm shift in treatment—from treating the sequelae of CF to correcting and potentiating the genetic cause of disease.

## 2.3 | CFTR heterozygotes

Heterozygosity of CFTR alleles does not cause the full spectrum of CF disease if there is one normal CFTR allele, but one CFTR mutation can lead to CF-like disease in at least one of the classically affected organ systems.<sup>12</sup> Interestingly, it is not only the loss of a copy of wild-type CFTR that is problematic for carriers of CFTR mutations. F508del, the most common CFTR mutant, has a dominant negative effect that impairs processing of the wild-type protein and limits its expression

and function.<sup>12</sup> Compared to the general population, CFTR carriers more commonly report CRS symptoms (36% vs 14%,  $P < .05$ ) and were found more commonly in a population of patients with CRS (7% vs 2%,  $P < .04$ ).<sup>13,14</sup> Though patients with a single CFTR mutation are five times more likely to have CRS, most have normal sweat chloride levels (SCLs) and nasal potential difference (NPD) similar to patients without CF.<sup>13</sup> Normal values on routine testing and the absence of the classic constellation of CF symptoms may limit recognition of these patients. Suspicion of a CRS patient harboring a CFTR mutation should be increased if the patient has: juvenile nasal polyposis, purulent chronic pansinusitis, chronic superinfection of nasal polyposis, hypoplastic frontal and maxillary sinuses, chronic pulmonary symptoms, or infertility.<sup>15,16</sup> As new CF therapies arise, identification of CFTR heterozygotes may allow for better management of this subset of patients with CRS.

## 2.4 | Medical therapies

For 75 years, treatment for CF has centered around targeting end-organ manifestations.<sup>9</sup> In CF CRS, this is no different, as the mainstay of medical treatment includes nasal saline rinses with steroids and/or antibiotics.<sup>1,4</sup> Though nasal rinses with normal (0.9%) saline alone have no clear evidence for benefit in CF, they are used to topically deliver beneficial steroids and antibiotics.<sup>4</sup> Topical steroids improve polyposis and sinonasal endoscopic appearance in patients with CF CRS, but studies on their effect on symptoms have mixed results.<sup>4</sup> Though their symptomatic effect is unclear, topical steroids can be used safely with minimal systemic effects.<sup>8</sup> Topical and oral antibiotics are often used during pulmonary exacerbations but have also been investigated for daily use. Topical colistin and tobramycin have been shown to reduce bacterial load, and tobramycin decreased rate of reoperation 1 year postoperatively.<sup>17,18</sup> In a study of nine patients, six patients used aerosolized tobramycin and experienced improved SNOT-20 scores compared to 0.9% saline.<sup>17</sup> Two larger trials are currently examining the daily use of antibiotics. Oral aztreonam alone is being compared to oral and nasally inhaled aztreonam, with SNOT-20 scores as a secondary outcome being investigated in 30 patients.<sup>19</sup> Nebulized, nasally inhaled tobramycin vs nebulized 0.9% saline is being examined with secondary outcomes including SNOT-20 score and several other sinus specific symptoms in 86 patients.<sup>20</sup> Topical dornase alfa (DA), a recombinant DNase, improves CRS symptoms and lung function by cleaving extracellular neutrophil DNA.<sup>21</sup> It has been shown to improve sinonasal symptoms (compared to saline rinses), post-ESS outcomes, lung function, and prevent pulmonary exacerbations.<sup>1,3,4,21</sup> The main drawback to widespread utilization of both daily topical antibiotics and DA in CF CRS is the cost, with approximate yearly cost of \$13 972 to \$27 944 for DA and \$12 315 to \$26 366 for colistin, aztreonam, and tobramycin.<sup>22</sup>

CFTR modulators work at the molecular level to increase transmission of CFTR to the epithelial cell membrane (corrector) or improve function of CFTR (potentiator). Functionally, they augment the defect caused by CFTR mutations. In the context of the currently available

modulators, CFTR mutations can be thought of as those that cause misprocessing and prevent trafficking (minimal function) and those that lower activity of CFTR at the epithelial surface (residual function).<sup>23</sup>

The first modulator shown to be effective was ivacaftor (Vertex Pharmaceuticals). It functions as a “potentiator” by increasing the time that activated CFTR channels at the cell surface remain open, and was first proven to benefit patients with the second most common CFTR mutation, G551D (representing 5% of patients).<sup>4,23</sup> G551D is a class III mutation that allows for transport of CFTR to the epithelial membrane, but causes CFTR gating dysfunction and thus is a residual function mutation.<sup>10,23</sup> When initially studied in patients 12 years and older, ivacaftor showed improvements in FEV1, improved pulmonary symptoms, decreased pulmonary exacerbations, decreased SCL, and improved weight gain.<sup>23</sup> This was followed up with a study in patients aged 6 to 11 that showed improvement in FEV1, SCL, and weight gain.<sup>24</sup> Despite a pretreatment mean FEV1 of 84.7% in these young patients, treatment with ivacaftor led to a 12.6% mean increase in FEV1, indicating benefit of intervention in patients with minimal loss of pulmonary function.<sup>24</sup>

In addition to pulmonary outcomes, ivacaftor is the only modulator with published data regarding rhinologic outcomes. In 2014 and 2015, three case reports of one patient each and a case series of 12 patients' response to ivacaftor were published. The case series patients all had at least one copy of G551D, and the case reports covered three different mutations—F508del/G551D, G551D/P205S (P205S is type I, mild phenotype mutation), and F508del/S1215N (S1215N is a type III mutation).<sup>25-29</sup> All three individual case reports detailed improvement or resolution of sinus symptoms, improvement of sinus CT, and increased FEV1, while the case series of 12 reported only improved CT appearance.<sup>25-28</sup>

A prospective study by McCormick et al showed improvements in the subcategories of rhinology (rhinorrhea, postnasal drip, thick nasal discharge), sleep function (difficulty falling asleep, waking up at night, and lack of a good night's sleep), and psychological function (fatigue, reduced concentration, sadness) on SNOT-20 scores for CF patients initiating ivacaftor.<sup>30</sup> While statistically significant, the improvements did not meet the minimal clinically important difference, which was attributed to the low self-reporting of symptoms in CF CRS patients.<sup>30</sup> Recently, Cho et al published two studies showing benefits of ivacaftor in vitro. The first found synergistic effects of resveratrol (a potentiator) and ivacaftor on chloride transport in G551D human sinonasal epithelium.<sup>31</sup> The second reported reduction of *Pseudomonas* biofilms utilizing a ciprofloxacin-ivacaftor coated biodegradable nasal stent.<sup>32</sup> The authors of this study plan to next conduct a study of the coated stents to assess effect on biofilms in vivo.<sup>32</sup>

Another class of CFTR modulator, lumacaftor (a “corrector”), was found to correct misprocessing of F508del CFTR and increase trafficking of the protein to the cell surface.<sup>33</sup> In patients homozygous for F508del, lumacaftor-ivacaftor improved FEV1, decreased pulmonary exacerbations, improved BMI, and improved quality of life on the Cystic Fibrosis Questionnaire-Revised (CFQ-R).<sup>33</sup> Though sinus outcomes were not explicitly analyzed, examination of the supplementary appendix revealed significantly less nasal congestion in the treatment

arm of the TRAFFIC trial (one of the two randomized control trials in the study).<sup>33</sup> This decrease in nasal congestion was not found in the other trial, TRANSPORT, so further study of this modulator combination therapy on sinonasal outcomes is warranted. Lumacaftor-ivacaftor has also been shown to improve NPD in patients homozygous for F508del, but none of the studies examined or reported sinonasal outcomes.<sup>34-36</sup>

For patients heterozygous for F508del and a residual function allele, tezacaftor (a corrector) plus ivacaftor was found to improve FEV1 and CFQ-R when compared to placebo and ivacaftor alone.<sup>10</sup> In this trial, nasal congestion was not significantly different between placebo and treatment groups.<sup>10</sup> Searching for studies examining rhinologic outcomes of tezacaftor-ivacaftor within the PubMed database yielded no results.

Recently, a major breakthrough in CFTR modulator therapy was made by adding the next generation corrector elexacaftor (Vertex Pharmaceuticals) to tezacaftor-ivacaftor.<sup>11</sup> Elexacaftor-tezacaftor-ivacaftor displayed significant improvement in FEV1, CFQ-R, decreased pulmonary exacerbations, and normalized SCLs in patients heterozygous for F508del and a minimal function allele.<sup>11</sup> To this point, ivacaftor for patients with G551D has set the benchmark for CFTR modulator therapy, with an increase of 10.6% in FEV1.<sup>11</sup> Elexacaftor-tezacaftor-ivacaftor improved upon this standard, by showing a 13.8% increase in FEV1.<sup>11</sup> By improving these measures in patients with F508del/minimal function alleles, elexacaftor-tezacaftor-ivacaftor showed that it could modulate disease for patients with F508del, regardless of their second allele.<sup>11</sup> This new medication has raised the bar for CFTR modulator therapy efficacy (with regard to FEV1 improvement) and extends CFTR modulator therapy to nearly 90% of people with CF.<sup>11</sup> In this study and its supplemental appendix, the only reported outcome related to the sinonasal cavity was a nonsignificant difference between therapy and placebo in “nasopharyngitis.”<sup>11</sup> A currently ongoing clinical trial aims to examine the effect of the new medication on sinus disease in 70 patients with CF.<sup>37</sup> With such strong early data, further research into this therapy is needed, and its effects on all aspects of CF disease should be explored. One area of potential high impact is the lung transplant CF patient. With such great FEV1 improvement, triple therapy could potentially improve postlung transplant outcomes, survival, or even change the trajectory of patients who previously would have received lung transplant.

Sinonasal outcomes have only been directly studied for ivacaftor.<sup>25-28,30</sup> Given the efficacy of CFTR modulators on pulmonary disease, increasing lifespan, and prevalence of sinus disease in patients with CF, further investigation of CFTR modulators and other therapies effects on sinus outcomes is warranted. However, one potential barrier to the study and use of CFTR modulators is cost. All of the aforementioned therapies cost roughly \$300 000 per year.<sup>22,38</sup>

## 2.5 | Surgical therapy

Sinus surgery for patients with CF has been established to be a safe procedure for both children and adults, and pediatric facial growth is

not affected by sinus surgery.<sup>39-42</sup> Patients may undergo multiple sinus procedures and have altered anatomy, but the coupling of CT scan with intraoperative navigation has been important advancement in the surgical management of these patients.<sup>4,43</sup> There is currently no clear consensus on indications for ESS in patients with CF CRS, although 20% to 60% undergo ESS.<sup>1</sup> Two recent studies examined patient characteristics predictive of ESS. Brook et al found that patients with severe CFTR mutations and previous ESS were more likely to undergo ESS compared to those with mild CFTR mutations and no history of ESS.<sup>44</sup> Ayoub et al found early ESS (vs ESS later or medical therapy) was predicted by Lund Mackay CT score, SNOT-22, previous ESS, nasal polyposis, and lower FEV1 at presentation.<sup>45</sup> With their findings, they offer a SNOT-22 score of >39 and an FEV1 of <68.7% at presentation to predict the need for ESS at any time point.<sup>45</sup>

Surgical technique for ESS in patients with CF CRS is also without clear evidence of a best practice, though some sinus specific protocols have been published. For the maxillary sinus, several variations of a wide maxillary antrostomy have been promoted as safe and with improved mucus clearance.<sup>46</sup> Recently, modified endoscopic medial maxillectomy has been recommended with significant improvements in symptom score, endoscopic appearance, and decreased pulmonary exacerbations.<sup>46</sup> Though FEV1 was unchanged, the authors state that the procedure also allows for better access to the maxillary sinus, including in-office debridement, improved clearance of mucus with rinses, and increased penetrance of topical therapies.<sup>46</sup> Utilizing endoscopic maxillary mega-antrostomy, 74% of patients reported complete resolution of symptoms while 26% reported partial symptomatic improvement.<sup>47,48</sup> Patients with CF made up nearly 25% of this cohort, and this has become the authors' standard protocol for management of the maxillary sinus in patients with CF CRS.<sup>47,48</sup> Regardless of technique, poor pneumatization of the maxillary sinus and under-mineralized/hypoplastic uncinate processes in patients with CF are important surgical considerations when addressing the maxillary sinus.<sup>4</sup>

Evidence on specific surgical technique for the ethmoid, sphenoid, and frontal sinuses is lacking. Anatomically, concha bullosa and Haller cells were less common in patients with CF, while Onodi cells were more common.<sup>49</sup> In children, a low ethmoid roof compared to patients without CF was noted, though this was not true for adults.<sup>49</sup> Regarding the frontal sinus, two patients with CF CRS and persistent symptoms after multiple ESS had good symptomatic improvement after modified endoscopic Lothrop (Draf III) frontal sinus surgery.<sup>50</sup> Overall, very little data are available on surgical approaches for CF CRS.

In three systematic reviews of ESS for CF CRS, adults and children consistently experienced symptomatic benefit, but no clear improvement in FEV1 was demonstrated.<sup>40,51,52</sup> Data on endoscopy score, CT appearance, hospitalization, and antibiotic use were mixed.<sup>40,51,52</sup> Necessity of ESS prior to or after lung transplant (LuTx) is a subject of debate. There is growing evidence to support the sinonasal cavity and the lungs as a unified airway with translocation of bacteria from the sinuses as a source of colonization or infection of the lungs.<sup>53-56</sup> Regarding ESS prior to LuTx, one paper reported 87% of patients' lungs were recolonized (mean 19 days after ESS) with

*Pseudomonas aeruginosa* post-transplant and no survival benefit when compared to centers where patients did not undergo ESS before transplantation.<sup>57</sup> There was no standardized surgical procedure in this cohort and postsurgical sinus care was unclear.<sup>57</sup> Four papers reported outcomes of ESS shortly after LuTx, three of which came from University of Zurich and followed essentially the same protocol. This initially consisted of maxillary antrostomy, ethmoidectomy, sphenoidotomy, and Draf I frontal sinusotomy (with daily postoperative isotonic saline rinses) after recovery from LuTx and 2 weeks of culture-directed antibiotic therapy.<sup>58</sup> Later, the authors generally describe more aggressive surgery to remove all septations in sinuses, including removal of the floor of the sphenoid sinus and the middle turbinate.<sup>59</sup> The authors advocate that this allows for better drainage of the sinuses and improved penetrance of nasal rinses, with no adverse effects.<sup>59</sup> After ESS, these three studies reported a correlation between negative sinus culture and negative lung culture, though there was a 59% to 68% rate of persistent nasal colonization.<sup>58-60</sup> The earliest paper from this group reported rates of bronchiolitis obliterans syndrome (BOS) comparable to patients without CF who undergo LuTx and lower rates of tracheobronchitis and pneumonia in cases of successful sinus surgery (defined by obtaining three or less sinus aspirates with bacterial counts greater than 10<sup>4</sup>).<sup>58</sup> Their 2013 paper reported that patients with negative bronchoalveolar lavage and nasal aspirates had improved survival at 5 years after LuTx (86% vs 57%) with fewer patients having BOS stages 1 and 2 (as defined by FEV1 66%-80% and 51%-65% of baseline, respectively).<sup>60,61</sup> Overall, these studies indicate that ESS after LuTx may have some benefit, especially to patients in whom bacterial eradication can be achieved.

A 2019 paper evaluated nine patients who underwent various forms of ESS (with daily postoperative saline rinses) after LuTx and 1 week of preoperative IV antibiotics.<sup>62</sup> Compared to 14 patients who had LuTx without ESS, those who had ESS had improved nasal obstruction, rhinorrhea, SNOT-22 score, and LK score.<sup>62</sup> Another 2019 paper investigated 20 patients who underwent 36 ESS at least a year after LuTx.<sup>63</sup> In that cohort, antibiotic use was decreased in the 6 months after ESS compared to 6 months preoperatively, but no difference was found in length of hospitalizations or FEV1.<sup>63</sup> Similarly, a 2020 paper evaluated complete ESS (bilateral maxillary antrostomy of any size, bilateral total ethmoidectomy, bilateral sphenoidotomy, and bilateral Draf IIa or IIb frontal sinusotomy) vs limited ESS (any procedure less than above) in patients with CF CRS. In their retrospective review, they found that use of oral antibiotics was reduced in the complete ESS group, but found no difference in IV antibiotic use, hospital admission frequency or length, or rate of change in FEV1.<sup>64</sup>

### 3 | CONCLUSION

The lifespan of patients with CF has greatly increased over the past 20 years due to improvement in treatment of end-organ disease. Management of CF CRS, however, remains challenging. At this time, there are no consensus guidelines regarding treatment of CF CRS.



However, the CF Foundation is currently developing guidelines for Otorhinolaryngology care, which will be an excellent resource to standardize the care of patients with CF CRS.

Currently, common medical therapies for CF CRS include saline rinses, topical steroids, DA, topical antibiotics during exacerbation, and CFTR modulators in appropriate patients. Beginning in 2012, targeted therapies such as ivacaftor (a potentiator) sparked a new wave of treatment for CF, directly modulating the dysfunctional protein that defines the disease. Correctors (increase trafficking to cell membrane) have been added since then, now with a triple combination therapy expansion that can be applied to treat nearly 90% of CF patients. There is no definitive agreement on surgical indications or technique, though aggressive surgery in recalcitrant disease has shown some symptomatic benefit. ESS after lung transplant appears to benefit patients in whom sinus bacteria are eradicated by decreasing pulmonary infections, decreasing rates of BOS, and improving 5 year survival. As treatment for CF expands and patients with CF live longer, further investigation is required to examine the effects of these medications on sinus disease. As CFTR modulators are increasingly utilized, the treatment paradigm of CF CRS may change. However, the otolaryngologist will remain critical to the multidisciplinary care team by providing longitudinal care for the rhinologic, otologic, and upper airway needs of patients with CF.

## CONFLICT OF INTEREST

The authors declare no potential conflict of interest.

## ORCID

Brian Jake Johnson  <https://orcid.org/0000-0003-4092-8164>

Garret W. Choby  <https://orcid.org/0000-0002-3745-2727>

Erin K. O'Brien  <https://orcid.org/0000-0002-4891-9548>

## REFERENCES

- Tipirneni KE, Woodworth BA. Medical and surgical advancements in the management of cystic fibrosis chronic rhinosinusitis. *Curr Otorhinolaryngol Rep*. 2017;5(1):24-34.
- CF Foundation. 2017 Annual Data Report. Bethesda, MD: Cystic Fibrosis Foundation Patient Registry; 2018.
- Zheng Z, Safi C, Gudis DA. Surgical management of chronic rhinosinusitis in cystic fibrosis. *Med Sci*. 2019;7(4):57.
- Safi C, Zheng Z, Dimango E, Keating C, Gudis DA. Chronic rhinosinusitis in cystic fibrosis: diagnosis and medical management. *Med Sci*. 2019;7(2):32.
- Halderman AA, Lee S, London NR, et al. Impact of high- versus low-risk genotype on sinonasal radiographic disease in cystic fibrosis. *Laryngoscope*. 2019;129(4):788-793.
- Casserly P, Harrison M, O'Connell O, O'Donovan N, Plant BJ, O'Sullivan P. Nasal endoscopy and paranasal sinus computerised tomography (CT) findings in an Irish cystic fibrosis adult patient group. *Eur Arch Otorhinolaryngol*. 2015;272(11):3353-3359.
- Zemke AC, Nourai SM, Moore J, et al. Clinical predictors of cystic fibrosis chronic rhinosinusitis severity. *Int Forum Allergy Rhinol*. 2019;9(7):759-765.
- Cutting GR. Cystic fibrosis genetics: from molecular understanding to clinical application. *Nat Rev Genet*. 2015;16(1):45-56.
- Clancy JP, Jain M. Personalized medicine in cystic fibrosis: dawning of a new era. *Am J Respir Crit Care Med*. 2012;186(7):593-597.
- Rowe SM, Daines C, Ringshausen FC, et al. Tezacaftor-ivacaftor in residual-function heterozygotes with cystic fibrosis. *N Engl J Med*. 2017;377(21):2024-2035.
- Middleton PG, Mall MA, Drevinek P, et al. Elexacaftor-tezacaftor-ivacaftor for cystic fibrosis with a single Phe508del allele. *N Engl J Med*. 2019;381(19):1809-1819.
- Tucker TA, Fortenberry JA, Zsembery A, Schwiebert LM, Schwiebert EM. The DeltaF508-CFTR mutation inhibits wild-type CFTR processing and function when co-expressed in human airway epithelia and in mouse nasal mucosa. *BMC Physiol*. 2012;12:12.
- Wang X, Moylan B, Leopold DA, et al. Mutation in the gene responsible for cystic fibrosis and predisposition to chronic rhinosinusitis in the general population. *JAMA*. 2000;284(14):1814-1819.
- Wang X, Kim J, McWilliams R, Cutting GR. Increased prevalence of chronic rhinosinusitis in carriers of a cystic fibrosis mutation. *Arch Otolaryngol Head Neck Surg*. 2005;131(3):237-240.
- Coste A, Girodon E, Louis S, et al. Atypical sinusitis in adults must lead to looking for cystic fibrosis and primary ciliary dyskinesia. *Laryngoscope*. 2004;114(5):839-843.
- Calton JB, Koripella PC, Willis AL, Le CH, Chiu AG, Chang EH. Paranasal sinus size is decreased in CFTR heterozygotes with chronic rhinosinusitis. *Int Forum Allergy Rhinol*. 2017;7(3):256-260.
- Mainz JG, Schadlich K, Schien C, et al. Sinonasal inhalation of tobramycin vibrating aerosol in cystic fibrosis patients with upper airway *Pseudomonas aeruginosa* colonization: results of a randomized, double-blind, placebo-controlled pilot study. *Drug Des Devel Ther*. 2014;8:209-217.
- Moss RB, King VV. Management of sinusitis in cystic fibrosis by endoscopic surgery and serial antimicrobial lavage. Reduction in recurrence requiring surgery. *Arch Otolaryngol Head Neck Surg*. 1995;121(5):566-572.
- Aztreonam Aerosol to Treat Cystic Fibrosis Nasal Disease. <https://ClinicalTrials.gov/show/NCT02730793>. Accessed December 5, 2019.
- Tobramycin Delivered by Nebulized Sonic Aerosol for Chronic Rhinosinusitis Treatment of Cystic Fibrosis Patients. <https://ClinicalTrials.gov/show/NCT02888730>. Accessed December 5, 2019.
- Mainz JG, Schien C, Schiller I, et al. Sinonasal inhalation of dornase alfa administered by vibrating aerosol to cystic fibrosis patients: a double-blind placebo-controlled cross-over trial. *J Cyst Fibros*. 2014;13(4):461-470.
- Health CAFDaTi. Table 11 Cost Comparison Table for Drugs Used for Cystic Fibrosis. *Common Drug Review*. Ottawa, Canada: Canadian Agency for Drugs and Technologies in Health; 2015.
- Ramsey BW, Davies J, McElvaney NG, et al. A CFTR potentiator in patients with cystic fibrosis and the G551D mutation. *N Engl J Med*. 2011;365(18):1663-1672.
- Davies JC, Wainwright CE, Canny GJ, et al. Efficacy and safety of ivacaftor in patients aged 6 to 11 years with cystic fibrosis with a G551D mutation. *Am J Respir Crit Care Med*. 2013;187(11):1219-1225.
- Chang EH, Tang XX, Shah VS, et al. Medical reversal of chronic sinusitis in a cystic fibrosis patient with ivacaftor. *Int Forum Allergy Rhinol*. 2015;5(2):178-181.
- Sheikh SI, Long FR, McCoy KS, Johnson T, Ryan-Wenger NA, Hayes D Jr. Ivacaftor improves appearance of sinus disease on computerised tomography in cystic fibrosis patients with G551D mutation. *Clin Otolaryngol*. 2015;40(1):16-21.
- Vreede CL, Berkhout MC, Sprij AJ, Fokkens WJ, Heijerman HG. Ivacaftor and sinonasal pathology in a cystic fibrosis patient with genotype deltaF508/S1215N. *J Cyst Fibros*. 2015;14(3):412-413.
- Hayes D Jr, McCoy KS, Sheikh SI. Improvement of sinus disease in cystic fibrosis with ivacaftor therapy. *Am J Respir Crit Care Med*. 2014;190(4):468.
- Chillon M, Casals T, Nunes V, Gimenez J, Perez Ruiz E, Estivill X. Identification of a new missense mutation (P205S) in the first transmembrane domain of the CFTR gene associated with a mild cystic fibrosis phenotype. *Hum Mol Genet*. 1993;2(10):1741-1742.

30. McCormick J, Cho DY, Lampkin B, et al. Ivacaftor improves rhinologic, psychologic, and sleep-related quality of life in G551D cystic fibrosis patients. *Int Forum Allergy Rhinol.* 2019;9(3):292-297.
31. Zhang S, Cho D, Lazrak A, et al. Resveratrol and ivacaftor are additive CFTR potentiators: therapeutic implications for CF sinus disease. *Pediatr Pulm.* 2018;53:161-161.
32. Cho DY, Lim DJ, Mackey C, et al. In-vitro evaluation of a ciprofloxacin- and ivacaftor-coated sinus stent against *Pseudomonas aeruginosa* biofilms. *Int Forum Allergy Rhinol.* 2019;9(5):486-492.
33. Wainwright CE, Elborn JS, Ramsey BW, et al. Lumacaftor-ivacaftor in patients with cystic fibrosis homozygous for Phe508del CFTR. *N Engl J Med.* 2015;373(3):220-231.
34. Masson A, Schneider-Futschik EK, Baatallah N, et al. Predictive factors for lumacaftor/ivacaftor clinical response. *J Cyst Fibros.* 2019;18(3):368-374.
35. Graeber SY, Dopfer C, Naehrlich L, et al. Effects of lumacaftor-ivacaftor therapy on cystic fibrosis transmembrane conductance regulator function in Phe508del homozygous patients with cystic fibrosis. *Am J Respir Crit Care Med.* 2018;197(11):1433-1442.
36. Pranke IM, Hatton A, Simonin J, et al. Correction of CFTR function in nasal epithelial cells from cystic fibrosis patients predicts improvement of respiratory function by CFTR modulators. *Sci Rep.* 2017;7(1):7375.
37. Impact of Triple Combination CFTR Therapy on Sinus Disease. <https://ClinicalTrials.gov/show/NCT04056702>. Accessed December 5, 2019.
38. Mahase E. Cystic fibrosis: triple therapy shows promising results. *BMJ.* 2019;367:l6347.
39. Tumin D, Hayes D Jr, Kirkby SE, Tobias JD, McKee C. Safety of endoscopic sinus surgery in children with cystic fibrosis. *Int J Pediatr Otorhinolaryngol.* 2017;98:25-28.
40. Macdonald KI, Gipsman A, Magit A, et al. Endoscopic sinus surgery in patients with cystic fibrosis: a systematic review and meta-analysis of pulmonary function. *Rhinology.* 2012;50(4):360-369.
41. Schulte DL, Kasperbauer JL. Safety of paranasal sinus surgery in patients with cystic fibrosis. *Laryngoscope.* 1998;108(12):1813-1815.
42. Van Peteghem A, Clement PA. Influence of extensive functional endoscopic sinus surgery (FESS) on facial growth in children with cystic fibrosis. Comparison of 10 cephalometric parameters of the midface for three study groups. *Int J Pediatr Otorhinolaryngol.* 2006;70(8):1407-1413.
43. Fuchsmann C, Ayari S, Reix P, et al. Contribution of CT-assisted navigation and microdebriders to endoscopic sinus surgery in cystic fibrosis. *Int J Pediatr Otorhinolaryngol.* 2008;72(3):343-349.
44. Brook CD, Maxfield AZ, Ahmed H, Sedaghat AR, Holbrook EH, Gray ST. Factors influencing the need for endoscopic sinus surgery in adult patients with cystic fibrosis. *Am J Rhinol Allergy.* 2017;31(1):44-47.
45. Ayoub N, Thamboo A, Habib AR, Nayak JV, Hwang PH. Determinants and outcomes of upfront surgery versus medical therapy for chronic rhinosinusitis in cystic fibrosis. *Int Forum Allergy Rhinol.* 2017;7(5):450-458.
46. Virgin FW, Rowe SM, Wade MB, et al. Extensive surgical and comprehensive postoperative medical management for cystic fibrosis chronic rhinosinusitis. *Am J Rhinol Allergy.* 2012;26(1):70-75.
47. Costa ML, Psaltis AJ, Nayak JV, Hwang PH. Long-term outcomes of endoscopic maxillary mega-antrostomy for refractory chronic maxillary sinusitis. *Int Forum Allergy Rhinol.* 2015;5(1):60-65.
48. Cho DY, Hwang PH. Results of endoscopic maxillary mega-antrostomy in recalcitrant maxillary sinusitis. *Am J Rhinol.* 2008;22(6):658-662.
49. Eggesbo HB, Sovik S, Dolvik S, Eiklid K, Kolmannskog F. CT characterization of developmental variations of the paranasal sinuses in cystic fibrosis. *Acta Radiol.* 2001;42(5):482-493.
50. Jaberloo MC, Pulido MA, Saleh HA. Modified Lothrop procedure in cystic fibrosis patients: does it have a role? *J Laryngol Otol.* 2013;127(7):666-669.
51. Liang J, Higgins TS, Ishman SL, Boss EF, Benke JR, Lin SY. Surgical management of chronic rhinosinusitis in cystic fibrosis: a systematic review. *Int Forum Allergy Rhinol.* 2013;3(10):814-822.
52. Vlastarakos PV, Fetta M, Segas JV, Maragoudakis P, Nikolopoulos TP. Functional endoscopic sinus surgery improves sinus-related symptoms and quality of life in children with chronic rhinosinusitis: a systematic analysis and meta-analysis of published interventional studies. *Clin Pediatr.* 2013;52(12):1091-1097.
53. Mainz JG, Hentschel J, Schien C, et al. Sinonasal persistence of *Pseudomonas aeruginosa* after lung transplantation. *J Cyst Fibros.* 2012;11(2):158-161.
54. Morlacchi LC, Greer M, Tudorache I, et al. The burden of sinus disease in cystic fibrosis lung transplant recipients. *Transpl Infect Dis.* 2018;20(5):e12924.
55. Choi KJ, Cheng TZ, Honeybrook AL, et al. Correlation between sinus and lung cultures in lung transplant patients with cystic fibrosis. *Int Forum Allergy Rhinol.* 2018;8(3):389-393.
56. Pletcher SD, Goldberg AN, Cope EK. Loss of microbial niche specificity between the upper and lower airways in patients with cystic fibrosis. *Laryngoscope.* 2019;129(3):544-550.
57. Leung MK, Rachakonda L, Weill D, Hwang PH. Effects of sinus surgery on lung transplantation outcomes in cystic fibrosis. *Am J Rhinol.* 2008;22(2):192-196.
58. Holzmann D, Speich R, Kaufmann T, et al. Effects of sinus surgery in patients with cystic fibrosis after lung transplantation: a 10-year experience. *Transplantation.* 2004;77(1):134-136.
59. Vital D, Hofer M, Boehler A, Holzmann D. Posttransplant sinus surgery in lung transplant recipients with cystic fibrosis: a single institutional experience. *Eur Arch Otorhinolaryngol.* 2013;270(1):135-139.
60. Vital D, Hofer M, Benden C, Holzmann D, Boehler A. Impact of sinus surgery on pseudomonas airway colonization, bronchiolitis obliterans syndrome and survival in cystic fibrosis lung transplant recipients. *Respiration.* 2013;86(1):25-31.
61. Estenne M, Maurer JR, Boehler A, et al. Bronchiolitis obliterans syndrome 2001: an update of the diagnostic criteria. *J Heart Lung Transplant.* 2002;21(3):297-310.
62. Luparello P, Lazio MS, Voltolini L, Borch B, Taccetti G, Maggiore G. Outcomes of endoscopic sinus surgery in adult lung transplant patients with cystic fibrosis. *Eur Arch Otorhinolaryngol.* 2019;276(5):1341-1347.
63. Cheng TZ, Choi KJ, Honeybrook AL, et al. Decreased antibiotic utilization after sinus surgery in cystic fibrosis patients with lung transplantation. *Am J Rhinol Allergy.* 2019;33(4):354-358.
64. Lee DJ, Yao C, Sykes J, Rizvi L, Tullis E, Lee JM. Complete versus limited endoscopic sinus surgery for chronic rhinosinusitis in adults with cystic fibrosis. *Otolaryngol Head Neck Surg.* 2020;162(4):572-580.

**How to cite this article:** Johnson BJ, Choby GW, O'Brien EK. Chronic rhinosinusitis in patients with cystic fibrosis—Current management and new treatments. *Laryngoscope Investigative Otolaryngology.* 2020;5:368–374. <https://doi.org/10.1002/lio2.401>