

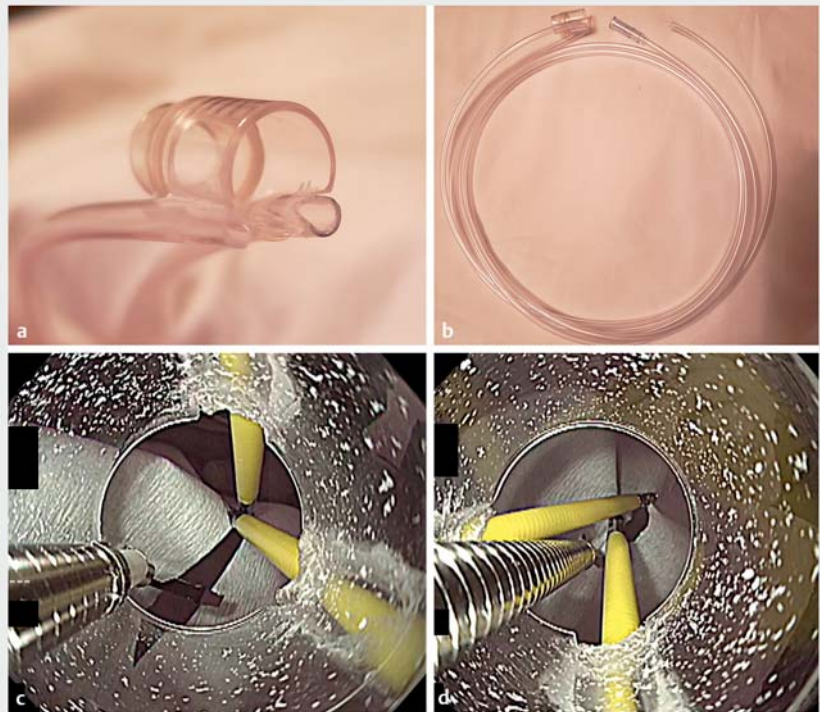


## Mucosal suturing method after gastric endoscopic submucosal dissection using self-made transparent "cross-hood" attachment

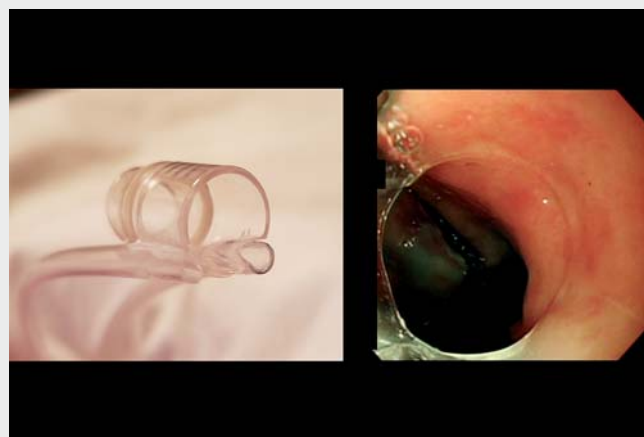
The ulcer floor after endoscopic submucosal dissection (ESD) sometimes becomes so large that several defect closure techniques have been reported [1–4] to prevent delayed bleeding or perforation. We developed a new device named the "cross-hood" that makes it easier to close a large mucosal defect after ESD.

This cross-hood was constructed with a long hood (MH-462; Olympus, Tokyo, Japan) and two Impact Shooters (TOP Corp, Tokyo, Japan). We shaved the tip of the hood, and then completed this device by attaching severed outer tubes of the Impact Shooters to the hood (► **Fig. 1 a, b**; ► **Video 1**). It is important to attach each tube to the hood so that the long axis of each tube is crossed (► **Fig. 1 c, d**). We report a case of successful closure of the large mucosal defect after gastric ESD using the cross-hood (► **Video 1**). The lesion was 10 mm in diameter and was located at the lesser curvature of the antrum (► **Fig. 2 a**). The lesion was completely resected en bloc (► **Fig. 2 b**). The size of the mucosal defect after ESD was approximately 35 mm (► **Fig. 2 c**). First we held the left side edge of the mucosal defect with grasping forceps from the right side of the outer channel; consequently we held the right side edge of the mucosal defect with grasping forceps from the left side of the outer channel. Thus, the two grasping forceps crossed and grasped the opposite side edges of the mucosal defect (► **Fig. 3 a, b**). By pulling both grasping forceps, both side edges of the mucosal defect were drawn together and closed using a conventional clip (► **Fig. 3 c**). Finally, we completed the closure (► **Fig. 3 d**). The ulcer floor was completely closed (► **Fig. 2 d**).

The cross-hood requires making a special device, but it does make closing large mucosal defects easy without a special technique. Closure of a large post-ESD defect with the cross-hood is feasible and useful.



► **Fig. 1** The self-made "cross-hood" device. **a** Shaved tip of the hood. **b** Severed outer tubes for attachment. **c** Attachment direction with the two outer channels on the same side as the inner channel. **d** Attachment direction with the two outer channels on the opposite side of the inner channel.



► **Video 1** Mucosal suturing method after gastric endoscopic submucosal dissection using self-made transparent "cross-hood" attachment.

Endoscopy\_UCTN\_Code\_TTT\_1AO\_2AI

### Competing interests

The authors declare that they have no conflict of interest.

### The authors

Rindo Ishii<sup>1</sup>, Ken Ohata<sup>1</sup>, Bo Liu<sup>1</sup>, Ryoju Negishi<sup>1</sup>, Yohei Minato<sup>1</sup>, Takashi Muramoto<sup>1</sup>, Makoto Kobayashi<sup>2</sup>

1 Department of Gastrointestinal Endoscopy, NTT Medical Center Tokyo, Tokyo, Japan

2 Department of Gastroenterology, Yokkaichi Municipal Hospital, Mie, Japan

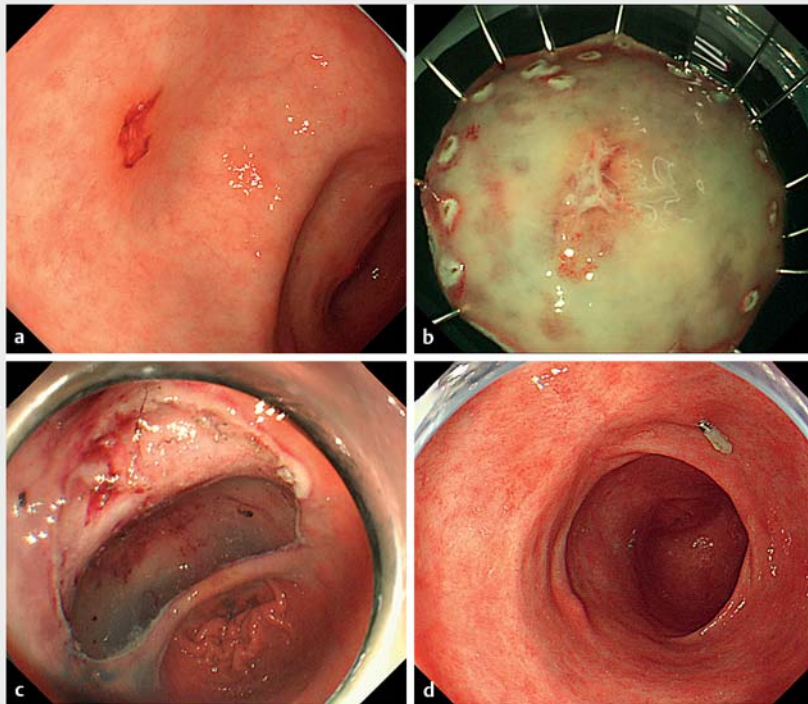
### Corresponding author

**Ken Ohata, MD**

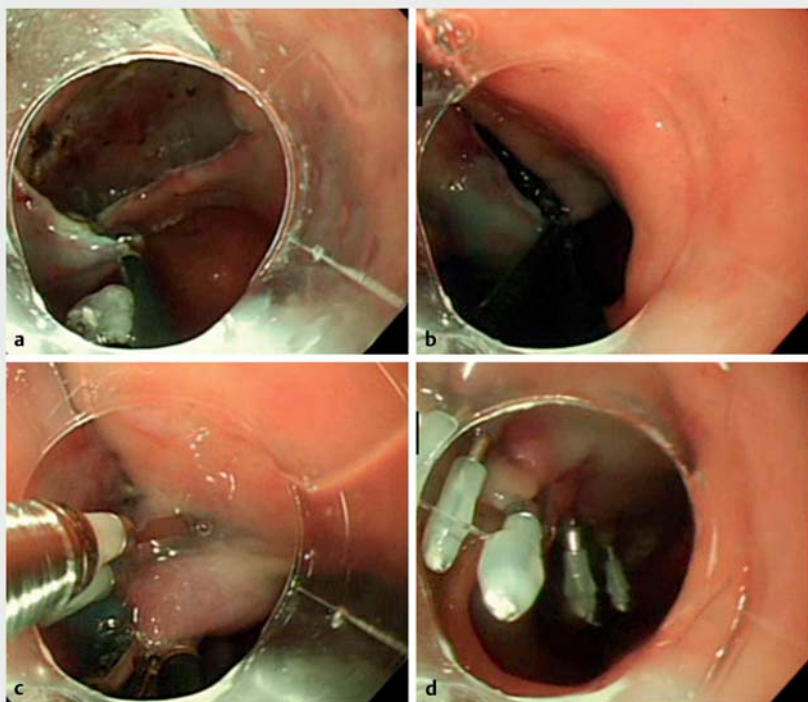
Department of Gastrointestinal Endoscopy, NTT Medical Center Tokyo, 5-9-22 Higashi-Gotanda, Shinagawa-Ku, Tokyo, 141-8625, Japan

Fax: +81-3-3448-6541

ken.ohata1974@gmail.com



► **Fig. 2** **a** The lesion was 10 mm in diameter and located at the lesser curvature of the antrum. **b** The lesion was completely resected en bloc. **c** The size of the mucosal defect after endoscopic submucosal resection was approximately 35 mm. **d** The ulcer floor was completely closed.



► **Fig. 3** **a, b** Two grasping forceps were crossed and grasped the opposite side of the edges of the mucosal defect. **c** By pulling both grasping forceps to the endoscope, both side edges of the mucosal defect were drawn together and closed using a conventional clip. **d** Finally, we completed the closure of the remnant gaps using only conventional clips.

## References

- [1] Matsuda T, Fujii T, Emura F et al. Complete closure of a large defect after EMR of a lateral spreading colorectal tumor when using a two-channel colonoscope. *Gastrointest Endosc* 2004; 60: 836–838
- [2] Sakamoto N, Beppu K, Matsumoto T et al. “Loop Clip”, a new closure device for large mucosal defects after EMR and ESD. *Endoscopy* 2008; 40: E97–E98
- [3] Fujii T, Ono A, Fu KI et al. A novel endoscopic suturing technique using a specially designed so-called “8-ring” in combination with resolution clips (with videos). *Gastrointest Endosc* 2007; 66: 1215–1220
- [4] Goto O, Sasaki M, Akimoto T et al. Endoscopic hand-suturing for defect closure after gastric endoscopic submucosal dissection: a pilot study in animals and in humans. *Endoscopy* 2017; 49: 792–797

## Bibliography

*Endoscopy* 2022; 54: E773–E775  
DOI 10.1055/a-1806-1742  
ISSN 0013-726X  
published online 8.4.2022  
© 2022. The Author(s).

This is an open access article published by Thieme under the terms of the Creative Commons Attribution-NonDerivative-NonCommercial License, permitting copying and reproduction so long as the original work is given appropriate credit. Contents may not be used for commercial purposes, or adapted, remixed, transformed or built upon. (<https://creativecommons.org/licenses/by-nc-nd/4.0/>)

Georg Thieme Verlag KG, Rüdigerstraße 14,  
70469 Stuttgart, Germany



## ENDOSCOPY E-VIDEOS

<https://eref.thieme.de/e-videos>



*Endoscopy E-Videos* is an open access online section, reporting on interesting cases and new techniques in gastroenterological endoscopy. All papers include a high quality video and all contributions are freely accessible online. Processing charges apply (currently EUR 375), discounts and waivers acc. to HINARI are available.

This section has its own submission website at

<https://mc.manuscriptcentral.com/e-videos>