

# Single Ring-Enhancing Lesion with the Lipid Peak on MR Spectroscopy

Vinay Goel, Leve Joseph, Deepa Dash<sup>1</sup>, Sushant Agarwal, Ajay Garg

Department of Neuroimaging and Interventional Neuroradiology, All India Institute of Medical Sciences, New Delhi, India, <sup>1</sup>Division of Neurology, Department of Medicine, University of Ottawa, Canada

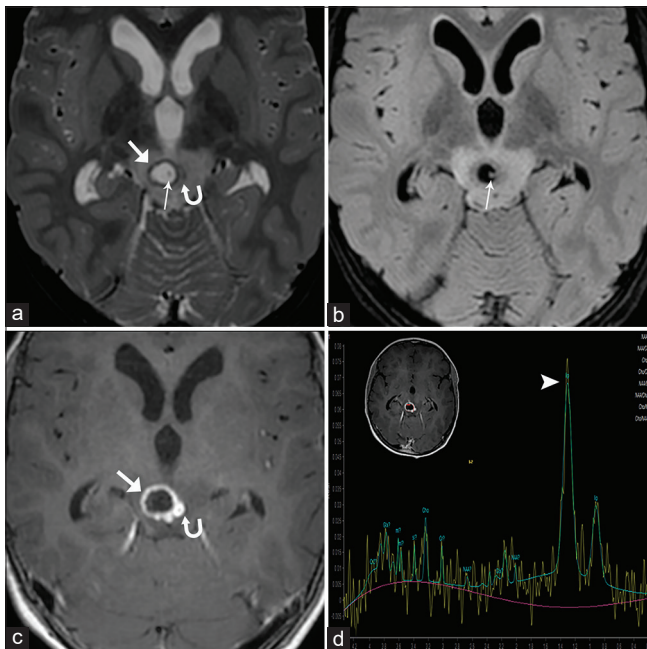
## CLINICAL DESCRIPTION

A 12-year-old boy presented in our emergency department with chief complaints of two episodes of seizures, headache, vomiting, and bilateral ptosis for the past 7 days. On neurological examination, bilateral third cranial nerve palsies were seen. Contrast-enhanced MRI of the brain revealed a conglomerate peripherally enhancing cystic lesion of size 9 mm in the tegmentum of the midbrain with perilesional edema [Figure 1]. The core of the cystic lesion was hyperintense on T2-WI and hypointense on FLAIR images suggesting signal suppression and CSF-like fluid contents. Eccentric scolex was seen on T2 W and FLAIR images. MR spectroscopy [Figure 1d] performed at short TE of 35 ms shows a lipid peak within the core of the lesion. A contrast-enhanced CT scan [Figure 2a] showed a peripherally enhancing lesion with eccentric scolex in the

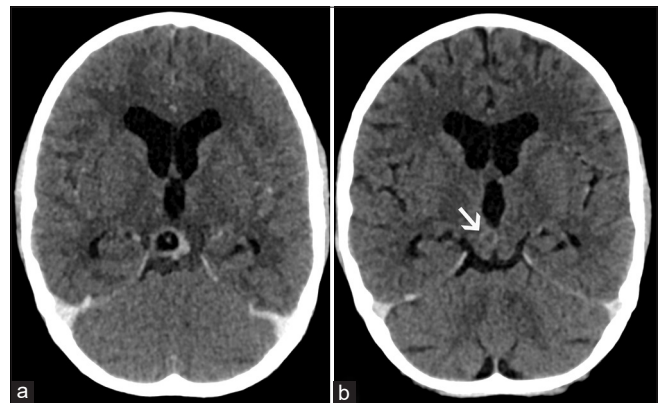
right tegmentum of the midbrain, suggesting the possibility of neurocysticercosis (NCC). A provisional diagnosis of NCC was made, and the patient was put on a tapering dose of steroids. Follow-up NCCT done after one month showed a decrease in the size of the lesion and perilesional edema [Figure 2b]. His ptosis improved after three months of clinical follow-up.

## DISCUSSION

The presence of scolex within a cystic lesion on CT/MRI is one of the definitive criteria of the diagnosis of NCC<sup>[1]</sup>; however, sometimes neurotuberculoma has been reported to have central calcification, which may be mistaken for scolex. MR spectroscopy (MRS) has been used to characterize various neurological lesions like brain abscess, tumors, cystic lesions, and granulomatous lesions like tuberculoma in the last few years. A classification of the various pathologic metabolic spectra has been developed by Chernov *et al.*<sup>[2]</sup> classifying MRS spectra into types I, II, and III according to the predominant metabolite peak (NAA, choline, lipid) with further subtypes A, B, and C depending upon the presence of lactate and lipid peaks. The lipid peak is seen as a singlet at 1.33 ppm, is broad, and has a shoulder on the left. The lipid peak does not invert at intermediate echo time; this feature helps differentiate lipid from lactate. The lipid peak is usually best seen at short TE due to short T2 of lipids and is not detectable in normal brain tissue.<sup>[3]</sup> Sometimes adjacent subcutaneous



**Figure 1:** MRI brain. Axial T2 WI (a) shows a single conglomerate lesion of 2 cysts (thick arrow and hairpin-arrow) with extensive perilesional edema on the right side of the tegmentum of the midbrain. The core of the larger cyst is hyperintense on T2 WI (a) and hypointense on FLAIR (b) images suggesting signal suppression. Scolex is seen as eccentric dot-like hypointensity (thin arrow in a) on T2 WI (a) and as hyperintensity (thin arrow in b) on FLAIR (b) images. Axial post gadolinium T1 WI (c) shows peripheral enhancement of the lesion, MR spectroscopy (d) shows lipid peak at short TE (arrowhead)



**Figure 2:** Contrast-enhanced CT scan of the brain at the level of the third ventricle shows a well-defined peripherally enhancing lesion with eccentric scolex (a) in the right side of the tegmentum of the midbrain. A follow-up non-contrast CT scan done after one month (b) shows a significant reduction in the lesion size (arrow)

fat or fatty calvarial bone marrow may contaminate the voxel and erroneously show an abnormal lipid peak; thus, one should be careful in voxel placement. Tuberculoma shows a prominent lipid peak due to the presence of lipid in the cell wall of mycobacteria.<sup>[4]</sup> Solid tumors like lymphoma<sup>[5]</sup> and papillary craniopharyngioma<sup>[2]</sup> may show lipid peak on MRS. Cystic lesions like adamantinomatous craniopharyngioma can also show lipid peak.<sup>[2]</sup> Proton spectroscopy of cysticercal fluid may show increased choline, lipid, succinate, alanine, and acetate and reduced levels of NAA and creatine; best seen at intermediate TE.<sup>[6]</sup> As the scolex degenerates, there is a proliferation of membranes resulting in increased lipids.<sup>[7]</sup>

The presence of lipid peak in a ring-enhancing lesion is not pathognomonic of neurotuberculoma, and lipid peak alone on MRS should not be used to differentiate between tuberculoma and neurocysticercosis. Other morphological characteristics of NCC like size, presence of scolex, suppression of core signal on FLAIR images, and different stages of evolution should be used in diagnosing NCC.

### Declaration of patient consent

The authors certify that they have obtained all appropriate patient consent forms. In the form, the patient(s) has/have given his/her/their consent for his/her/their images and other clinical information to be reported in the journal. The patients understand that their names and initials will not be published and due efforts will be made to conceal their identity, but anonymity cannot be guaranteed.

### Financial support and sponsorship

Nil.

### Conflicts of interest

There are no conflicts of interest.

## REFERENCES

1. Del Brutto OH, Rajshekhar V, White AC Jr, Tsang VC, Nash TE, Takayanagui OM, *et al.* Proposed diagnostic criteria for neurocysticercosis. *Neurology* 2001;57:177-83.
2. Chernov MF, Ono Y, Muragaki Y, Kubo O, Nakamura R, Iseki H, *et al.* Differentiation of high-grade and low-grade gliomas using pattern analysis of long-echo single-voxel proton magnetic resonance spectroscopy ((1) H-MRS). *Neuroradiol J* 2008;21:338-49.
3. Cianfoni A, Law M, Re TJ, Dubowitz DJ, Rumboldt Z, Imbesi SG. Clinical pitfalls related to short and long echo times in cerebral MR spectroscopy. *J Neuroradiol* 2011;38:69-75.
4. Santy K, Nan P, Chantana Y, Laurent D, Nadal D, Richner B. The diagnosis of brain tuberculoma by (1) H-magnetic resonance spectroscopy. *Eur J Pediatr* 2011;170:379-87.
5. Yamasaki F, Takayasu T, Nosaka R, Amatya VJ, Doskaliyev A, Akiyama Y, *et al.* Magnetic resonance spectroscopy detection of high lipid levels in intraaxial tumors without central necrosis: A characteristic of malignant lymphoma. *J Neurosurg* 2015;122:1370-9.
6. Zhao JL, Lerner A, Shu Z, Gao XJ, Zee CS. Imaging spectrum of neurocysticercosis. *Radiol Infect Dis* 2015;1:94-102.
7. Valkounova J, Zdarska Z, Slais J. Histochemistry of the racemose form of *Cysticercus cellulosae*. *Folia Parasitol (Praha)* 1992;39:207-26.

**Address for correspondence:** Prof. Ajay Garg,

Department of Neuroimaging and Interventional Neuroradiology, Room No 14, Cathlab Complex, Neurosciences Centre, All India Institute of Medical Sciences, New Delhi - 110 029, India.  
E-mail: drajaygarg@gmail.com

**Submitted:** 30-Jun-2021 **Revised:** 31-Aug-2021 **Accepted:** 29-Sep-2021

**Published:** 10-Mar-2022

This is an open access journal, and articles are distributed under the terms of the Creative Commons Attribution-NonCommercial-ShareAlike 4.0 License, which allows others to remix, tweak, and build upon the work non-commercially, as long as appropriate credit is given and the new creations are licensed under the identical terms.

**For reprints contact:** WKHLRPMedknow\_reprints@wolterskluwer.com

**DOI:** 10.4103/aian.aian\_604\_21