


Contents lists available at [ScienceDirect](https://www.sciencedirect.com)

International Journal for Parasitology: Parasites and Wildlife

journal homepage: [www.elsevier.com/locate/ijppaw](http://www.elsevier.com/locate/ijppaw)

## *Sarcocystis calchasi* and other Sarcocystidae detected in predatory birds in California, USA

Krysta H. Rogers<sup>a,\*</sup>, David Arranz-Solís<sup>b,1</sup>, Jeroen P.J. Saeij<sup>b</sup>, Stephany Lewis<sup>c,2</sup>, Aslı Mete<sup>d</sup>

<sup>a</sup> Wildlife Health Laboratory, California Department of Fish and Wildlife, 1701 Nimbus Road Suite D, Rancho Cordova, CA, 95670, USA

<sup>b</sup> Department of Pathology, Microbiology and Immunology, School of Veterinary Medicine, University of California, Davis, One Shields Avenue, Davis, CA, 95616, USA

<sup>c</sup> California Wildlife Center, 26026 Puma Road, Calabasas, CA, 91302, USA

<sup>d</sup> California Animal Health and Food Safety Laboratory, University of California, Davis, 620 West Health Sciences Dr., Davis, CA, 95616, USA

### ARTICLE INFO

#### Keywords:

Accipitridae  
Apicomplexa  
Definitive host  
Protozoa  
Raptor  
*Sarcocystis calchasi*

### ABSTRACT

Outbreaks of neurological disease associated with *Sarcocystis calchasi* have been observed in captive and free-ranging rock pigeons (*Columba livia*) in Europe and the United States as well as in wild Brandt's cormorants (*Phalacrocorax penicillatus*) and captive psittacines in California, USA. Experimental and field studies have identified northern goshawks (*Accipiter gentilis*) and European sparrowhawks (*A. nisus*) as definitive hosts in Europe while the definitive hosts elsewhere remain unknown. In this study, we aimed to identify the potential definitive host(s) of *S. calchasi* through molecular analysis of intestinal samples from seven predatory (n = 85) and one omnivorous (n = 11) bird species in California. In total, apicomplexan-generic 28S rRNA PCR products were obtained and sequenced for 42 raptors. Three of 16 (18.8%) Cooper's hawks (*A. cooperii*) and two of 26 (5.6%) red-tailed hawks (*Buteo jamaicensis*) also tested positive for the *S. calchasi*-specific ITS1 PCR and sequencing of the 28S rRNA PCR product was 100% homologous to *S. calchasi*. In addition to *S. calchasi* (5.9%; 5/85), other *Sarcocystis* spp. detected in raptors included: *S. jamaicensis* (21.2%; 18/85), *S. columbae* (8.2%; 7/85), *S. turdusi* (7.1%; 6/85), and *S. halioti* (4.7; 4/85%). Infections with closely related *S. jamaicensis* and *S. (Frenkelia) microti* (9.4%; 8/85) could not be distinguished for eight raptors. *Eumonospora henryae* (1.2%; 1/85) was detected in one raptor. Our results indicate for the first time that *S. calchasi* may have a definitive host range in North America that includes at least two raptors, Cooper's hawks and red-tailed hawks, within the family Accipitridae.

### 1. Introduction

*Sarcocystis* spp., which belong to the family Sarcocystidae, are parasites with an obligate two-host life cycle involving a definitive host and an intermediate host. Disease may occur in the intermediate host following the ingestion of sporocysts shed in the feces of the definitive host, typically a predator that consumes the tissue cysts (sarcocysts) present in the muscle of the intermediate host (Dubey et al., 2016). For many *Sarcocystis* spp., the complete life cycle with the known definitive and intermediate hosts remains undetermined. Historically, *Sarcocystis* spp. have been identified by the morphology of the sarcocysts found in the muscle or other tissues of the intermediate host while the morphology of the oocysts and sporocysts had little taxonomic value,

making it challenging to link these different life stages to a single parasite (Dubey et al., 2016). Laboratory studies involving dosing either a potential intermediate or definitive host with parasites was commonly utilized to demonstrate the complete life cycle (Box and Smith, 1982; Luznar et al., 2001; Olias et al., 2010b). Recently, advances in molecular techniques have enabled more expansive research on potential hosts using PCR to genetically identify *Sarcocystis* spp. found in the tissues of the intermediate host or in the intestines and feces of the definitive host (Gjerde et al., 2018; Olias et al., 2010c, 2011; Parmentier et al., 2018; Prakas et al., 2011). This methodology continues to expand the host range of many *Sarcocystis* spp., and consequently, it has been observed that bird-infecting species typically have multiple hosts (Olias et al., 2014).

\* Corresponding author.

E-mail addresses: [krysta.rogers@wildlife.ca.gov](mailto:krysta.rogers@wildlife.ca.gov) (K.H. Rogers), [darranz@ucdavis.edu](mailto:darranz@ucdavis.edu) (D. Arranz-Solís), [jsaeij@ucdavis.edu](mailto:jsaeij@ucdavis.edu) (J.P.J. Saeij), [stephany@ojairaptorcenter.org](mailto:stephany@ojairaptorcenter.org) (S. Lewis), [amete@ucdavis.edu](mailto:amete@ucdavis.edu) (A. Mete).

<sup>1</sup> These authors contributed equally to this paper.

<sup>2</sup> Present address: Ojai Raptor Center, P.O. Box 182, Oak View, CA 93022, USA.

<https://doi.org/10.1016/j.ijppaw.2021.12.008>

Received 19 November 2021; Received in revised form 23 December 2021; Accepted 23 December 2021

Available online 27 December 2021

2213-2244/© 2021 The Authors. Published by Elsevier Ltd on behalf of Australian Society for Parasitology. This is an open access article under the CC BY-NC-ND

license (<http://creativecommons.org/licenses/by-nc-nd/4.0/>).

While raptors can act as intermediate hosts for some *Sarcocystis* spp., such as *S. falcatula* and *S. neurona* (Olson et al., 2007; Wunshmann et al., 2009, 2010), raptors are the recognized definitive host for many *Sarcocystis* spp. (Dubey et al., 2016). Sporocysts have been recovered from the intestines and/or feces of raptors in the United States and elsewhere. A survey of *Sarcocystis* spp. from four species of hawks in Georgia, USA between 2001 and 2004 reported infections in 67% of raptors including Cooper's hawks (*Accipiter cooperii*), sharp-shinned hawks (*A. striatus*), red-tailed hawks (*Buteo jamaicensis*), and red-shouldered hawks (*B. lineatus*) (Yabsley et al., 2009). However, genetic analysis of the 18S rRNA gene segment in this study failed to separate the closely related parasites. More recently, analysis of the 28S rRNA gene segment and the internal transcribed spacer 1 (ITS1) region has been used to differentiate closely related bird-infecting *Sarcocystis* spp. (Olias et al., 2010c, 2014; Prakas et al., 2018). Although several *Sarcocystis* spp. are nearly identical at the partial 28S rRNA gene, these species may be differentiated using the ITS1 region.

*Sarcocystis calchasi* was identified in 2008 as the causative agent of pigeon protozoal encephalitis following an outbreak of neurological disease in racing pigeons (*Columba livia* f. *domestica*) in Germany (Olias et al., 2009). Sarcocysts were observed on histology in the skeletal muscles and rare parasites were detected in the severe brain lesions of infected pigeons (Maier et al., 2015; Olias et al., 2010a). Molecular evaluation of brain and muscle tissues from infected pigeons identified *S. calchasi* (Olias et al., 2009). The northern goshawk (*Accipiter gentilis*), a common avian predator that frequently preys on rock pigeons, was confirmed as a definitive host of *S. calchasi* in a laboratory study in Germany (Olias et al., 2010b). Subsequent molecular research in Germany has identified *S. calchasi* in intestinal samples from European sparrowhawks (*A. nisus*), another likely definitive host for this parasite in Europe (Olias et al., 2011). Since its initial discovery, *S. calchasi* has been identified in the United States in captive and free-ranging pigeons (*C. livia*) (Mete et al., 2019; Olias et al., 2014; Trupkiewicz et al., 2016; Wunshmann et al., 2011), a free-ranging Eurasian collared dove (*Streptopelia decaocto*) (Hodo et al., 2016), captive psittacines (Rimoldi et al., 2013), and wild Brandt's cormorants (*Phalacrocorax penicillatus*) (Bamac et al., 2020), and in Japan in a free-ranging rock pigeon (Ushio et al., 2015). The definitive hosts for *S. calchasi* remain unknown outside of Europe, although raptor species within the genus *Accipiter* have been suggested.

In the United States, *S. calchasi* was first detected in captive and free-ranging rock pigeons in Minnesota and Missouri in 2011 and 2012 (Olias et al., 2014; Wunshmann et al., 2011). An outbreak in California during late winter and spring 2017 marked the first widespread mortality event involving free-ranging rock pigeons (Mete et al., 2019). Infection was identified in 21 rock pigeons exhibiting neurologic disease from 10 different counties (Mete et al., 2019). Between March and May 2019, an outbreak along the southern California coast was identified in a seabird, the Brandt's cormorant (*Phalacrocorax penicillatus*) (Bamac et al., 2020). Wildlife rehabilitation centers had reported increased admissions of cormorants with neurological signs. *Sarcocystis calchasi* was confirmed in brain and muscle tissues from 7 of 8 cormorants examined, with one cormorant positive for *S. falcatula* (Bamac et al., 2020). This outbreak of *S. calchasi*-encephalitis marked the first time this parasite was detected in a seabird with no regular avian predators. The authors hypothesized that sporocysts shed in the feces of terrestrial definitive hosts were washed into the ocean following increased rainfall in late winter where they were ingested, either directly or indirectly, by near-shore Brandt's cormorants (Bamac et al., 2020). The land to sea transmission of other apicomplexan parasites such as *S. neurona* and *Toxoplasma gondii* have been documented in marine mammal infections (Miller et al., 2002, 2010). However, unlike *S. neurona* and *T. gondii* whose definitive hosts include the Virginia opossum (*Didelphis virginiana*) and domestic cat (*Felis catus*), respectively, the definitive hosts of *S. calchasi* contributing to the fecal contamination of land and sea environments remain unknown.

In the present study, we surveyed eight different species of potential avian predators and scavengers of rock pigeons for *Sarcocystis* spp. to identify the likely definitive host(s) of *S. calchasi*. Additionally, we provide a summary of all the *Sarcocystis* spp. found in the intestines of the evaluated raptor species, expanding the putative definitive host range for some of the parasites we identified through molecular analysis.

## 2. Materials and methods

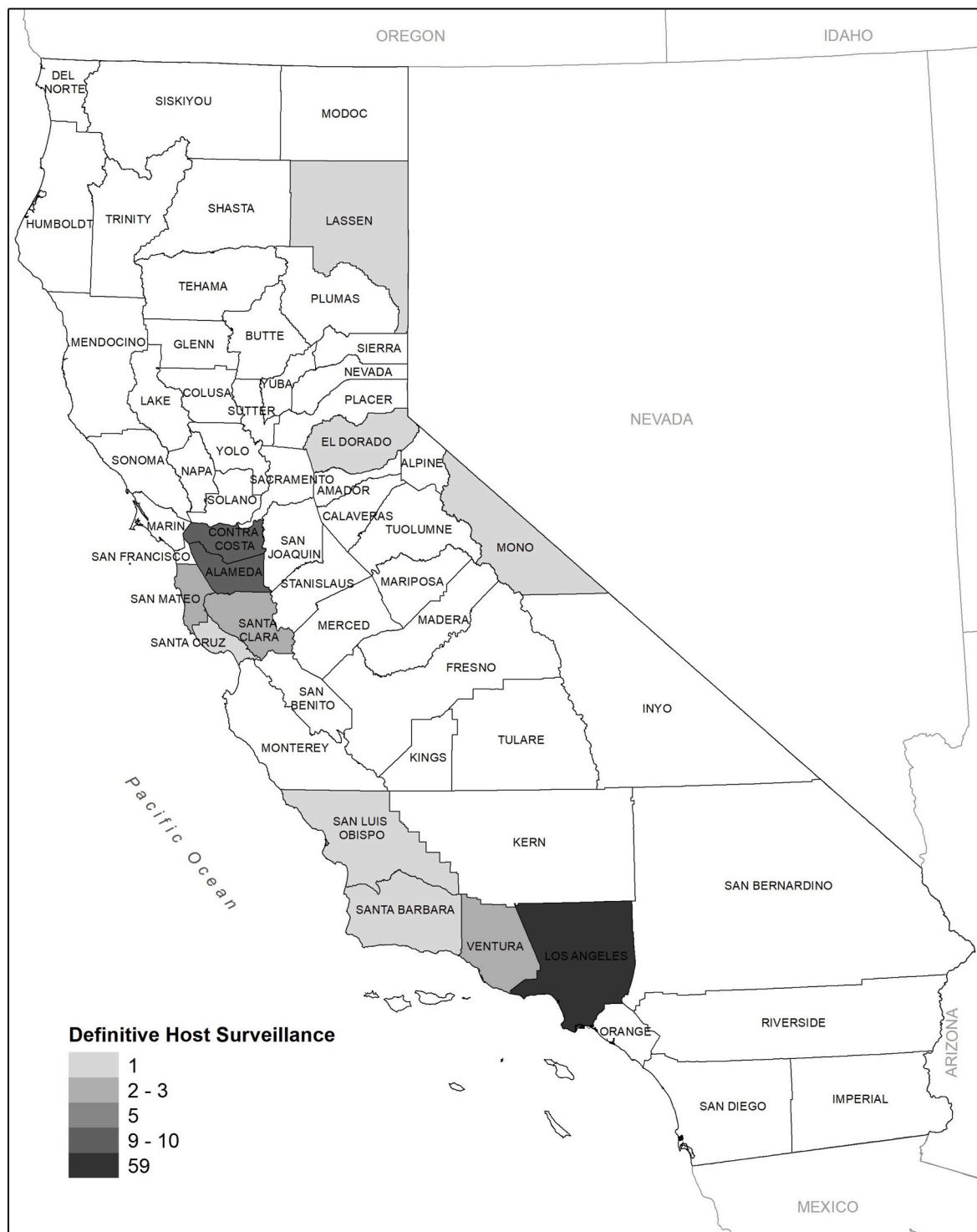
### 2.1. Postmortem examination

Ninety-six birds were evaluated for this study including 85 raptors and 11 American crows (*Corvus brachyrhynchos*). These carcasses were submitted to the California Department of Fish and Wildlife's (CDFW) Wildlife Health Laboratory (WHL; Rancho Cordova, CA, USA) between 2016 and 2020 by members of the public, wildlife rehabilitation centers, CDFW staff, or other government agencies for postmortem examination and cause of death determination. Carcasses were received at WHL and stored in a freezer (−20 °C) until postmortem examination. Prior to examination, the carcasses were thawed at 4 °C for 3–5 days. A gross necropsy was performed at WHL, and findings were recorded including age, sex, adipose deposition, appearance/condition of organs, and abnormalities (e.g., injuries). Tissue samples of pectoral muscle, lung, heart, liver, spleen, kidneys, pancreas, intestines, and brain were collected into individual whirl-pak® bags (Nasco Sampling, LLC, Fort Atkinson, WI) and stored at −80 °C.

Individuals evaluated for *Sarcocystis* spp. were preferentially selected based on a collection location and date corresponding with previous *S. calchasi* outbreaks in rock pigeons (Mete et al., 2019) and Brandt's cormorants (Bamac et al., 2020) and included species that are known to prey or scavenge on rock pigeons (Fig. 1). The species evaluated included American crow (n = 11), Cooper's hawk (n = 16), great horned owl (*Bubo virginianus*) (n = 12), northern goshawk (n = 2), peregrine falcon (*Falco peregrinus*) (n = 3), red-shouldered hawk (n = 12), red-tailed hawk (n = 36), and sharp-shinned hawk (n = 4).

### 2.2. Molecular characterization

For the *Sarcocystis* spp. analysis, the intestines were thawed, and immediately a section of the small intestine was excised, macerated with a sterile blade, collected into a cryovial, and stored at −80 °C until molecular analysis. Archived intestinal tissue was limited for some birds, in which case a section was collected from the available portion. Frozen intestinal samples from all 96 birds included in the study were tested for *Sarcocystis* spp. by polymerase chain reaction (PCR). Approximately 50–100 mg of tissue from each bird was used to isolate DNA, and 100–250 ng of DNA was subsequently used for PCR as previously described (Bamac et al., 2020). Briefly, the amplification of a ~350 bp fragment from the 28S rRNA region was achieved by using the *Sarcocystis* spp. (and other apicomplexan parasites) conserved primers SAD2F and SAD2R. Samples that tested positive were further analyzed by the *S. calchasi*-specific PCR (ITS1) with the primer pair SCa1 and SCa2, with a predicted amplicon size of 225 bp (Bamac et al., 2020). For sequence analysis, PCR products from 28S rRNA-positive samples were purified and analyzed by Sanger sequencing using the SAD2R primer. *Sarcocystis calchasi* and *S. neurona* positive DNA samples were used as positive controls, while nuclease-free water used as a template served as a negative control to ensure no cross-contamination occurred (Bamac et al., 2020). Sequences were analyzed as previously described (Bamac et al., 2020) using BioEdit sequence alignment editor v7.0.5.3 (Hall 1999), comparing sequences available from the National Center for Biotechnology Information (NCBI) GenBank (<https://www.ncbi.nlm.nih.gov/genbank/>) by BLASTn (Altschul et al., 1990). Generated sequences were deposited in GenBank under the accession numbers OK576416 - OK576465.



**Fig. 1.** Number of avian carcasses evaluated for *Sarcocystis* spp. by county in California, USA between 2016 and 2020. Species include American crow (*Corvus brachyrhynchos*; n = 11), Cooper’s hawk (*Accipiter cooperii*; n = 16), great horned owl (*Bubo virginianus*; n = 12), northern goshawk (*A. gentilis*; n = 2), peregrine falcon (*Falco peregrinus*; n = 3), red-shouldered hawk (*Buteo lineatus*; n = 12), red-tailed hawk (*B. jamaicensis*; n = 36), and sharp-shinned hawk (*A. striatus*; n = 4).

2.3. Phylogenetic analysis

Phylogenetic comparisons were made between the apicomplexan parasites found in the intestinal samples from the raptors and the respective closest reference sequence in GenBank. Briefly, a Maximum Likelihood phylogeny test was performed using MEGA-X version 10.2.6 (Kumar et al., 2018) applying the Neighbor-Join and BioNJ algorithms to a matrix of pairwise distances estimated using the Tamura-Nei model

(Tamura and Nei, 1993).

2.4. Histopathological examination

Histopathology was performed on intestinal tissue of selected birds to confirm the presence of sporocysts. The remaining archived intestinal tissue was thawed, and sections were immersed in 10% neutral buffered formalin, paraffin-embedded, sectioned at 4 μm, and stained with

hematoxylin and eosin for histologic examination by light microscopy at the California Animal Health and Food Safety Laboratory System (CAHFS; Davis, CA, USA).

2.5. Statistical analysis

We analyzed differences in infection prevalence using the chi-square ( $\chi^2$ ) test of independence. Values reported are mean  $\pm$  SE. Statistical analyses were performed using NCSS (Hintze, 2007) and  $P < 0.05$  were considered statistically significant. Maps were prepared using ArcMap (ESRI, Inc., Redlands, CA, USA).

3. Results

3.1. Postmortem examination

The 85 raptor carcasses were collected from 12 counties (Fig. 1) including Alameda (n = 8), Contra Costa (n = 10), El Dorado (n = 1), Lassen (n = 1), Los Angeles (n = 51), Mono (n = 1), San Francisco (n = 5), San Luis Obispo (n = 1), San Mateo (n = 2), Santa Clara (n = 3), Santa Cruz (n = 1), and Ventura (n = 1). The raptors were collected in 2016 (n = 6), 2017 (n = 14), 2018 (n = 22), 2019 (n = 19), and 2020 (n = 24). Of the 85 raptors, 51 were female and 34 were male while 44 were juveniles and 41 were adults. Trauma was the most common cause of death for the raptors followed by anticoagulant rodenticide toxicosis, starvation, and diseases (e.g., West Nile virus, avian trichomonosis, etc.).

The 11 American crow carcasses were collected from four counties (Fig. 1) including Alameda (n = 1), Los Angeles (n = 8), Santa Barbara (n = 1), and Ventura (n = 1) in 2018 (n = 1), 2019 (n = 1), and 2020 (n = 9). Seven of the 11 crows were female and four were male while six were juveniles and five were adults. Starvation and diseases (e.g., West Nile virus) were the most common causes of death for the crows followed by trauma.

3.2. Molecular characterization

In total, the intestinal samples of 46 of 85 (54.1%) raptors tested positive for the apicomplexan-generic 28S rRNA PCR (Table 1). Twenty-eight (44.7%) raptors and 10 American crows tested negative. Samples from the remaining 11 raptors and one crow yielded poor quality DNA (i.e., either too low concentration, 1–10 ng/ul, or an A260/A280 < 1) in repeated extractions and tested negative for the 28S rRNA PCR. These samples were excluded from the analysis because it could not be ruled

out that the negative results were due to the poor-quality DNA rather than an actual absence of parasite DNA. Additionally, the PCR products from four of the 46 positive raptors were deemed unreadable despite several sequencing attempts, as the chromatogram showed high background noise and mixed peaks that rendered it impossible to discern between nucleotides. The 28S rRNA PCR products were sequenced for the remaining 42 raptors.

Five of the 42 raptors also tested positive for the *S. calchasi*-specific ITS1 PCR (Table 1) and all five were further confirmed to be 100% identical to *S. calchasi* by sequencing of the 28S rRNA PCR product (Table 2). Infected raptors included 3 of 16 (18.8%) Cooper’s hawks and 2 of 26 (5.6%) red-tailed hawks (Table 1), all collected from Los Angeles County. The *S. calchasi*-positive Cooper’s hawks were collected in November 2016, May 2017, and June 2017 while the red-tailed hawks were collected in March and June 2020. One positive Cooper’s hawk was an adult female and two were juvenile males. Both positive red-tailed hawks were males, one was a juvenile and one was an adult.

Screening the sequences of the remaining 28S rRNA-positive raptors through BLASTn, a high percentage of homology (96–100%) to a number of different *Sarcocystis* spp. and other apicomplexan parasites were found (Tables 1 and 2). Of note, when the chromatograms of the positive raptors were analyzed, nine showed nucleotides with double, overlapping peaks in an otherwise clean sequence with no, or minimal, noise (see examples in Fig. 2). Because these were detected in only a few nucleotides (1–11) in each sequence, and there was always one predominant nucleotide over the other in each double peak, two different sequences were analyzed separately by combining only the high and low peak nucleotides. After BLASTn analysis, the closest match from each sequence was considered as the primary and secondary infection for each raptor, respectively. In addition to *S. calchasi* (5.9%; 5/85), the following parasites also were detected in raptors: *S. jamaicensis* (21.2%; 18/85), *S. columbae* (8.2%; 7/85), *S. turdusi* (7.1%; 6/85), *S. halieta* (4.7; 4/85%), and *Eumonospora henryae* (1.2%; 1/85) (Table 2). Further, eight raptors (9.4%; 8/85) had sequences with the same homology percentage (~99%) to two different sequences by BLASTn, namely *S. jamaicensis* and *S. (Frenkelia) microti*. Therefore, either of these parasites could be considered as the cause of infection (Table 2). Detailed information for each bird and sequence is presented in Supplementary Table 1.

Overall, significantly more red-tailed hawks were infected compared with the other six raptor species ( $X^2 = 5.9, P = 0.0151$ ). Red-tailed hawks also had the highest diversity of parasites with seven, followed by Cooper’s hawks with four and red-shouldered hawks with three. Significantly more juvenile, red-shouldered hawks ( $X^2 = 1.3, P = 0.038$ )

Table 1

Number and prevalence (%) of *Sarcocystis* spp. and other Sarcocystidae identified by BLASTn analysis of 28S PCR-positive intestinal samples from dead predatory and omnivorous birds collected in California, USA between 2016 and 2020. The parasite species was matched by BLASTn to the closest reference sequence available in GenBank. Bird species include American crow (*Corvus brachyrhynchos*), Cooper’s hawk (*Accipiter cooperii*), great horned owl (*Bubo virginianus*), northern goshawk (*A. gentilis*), peregrine falcon (*Falco peregrinus*), red-shouldered hawk (*Buteo lineatus*), red-tailed hawk (*B. jamaicensis*), and sharp-shinned hawk (*A. striatus*).

Predatory species	n	Number positive (Prevalence %)							
		<i>Sarcocystis</i> spp. (28S PCR)	<i>S. calchasi</i>	<i>S. columbae</i>	<i>S. halieta</i>	<i>S. turdusi</i>	<i>S. jamaicensis</i>	<i>S. jamaicensis/S. (Frenkelia) microti</i>	<i>Eumonospora henryae</i>
Cooper’s hawk	16	8 (50.0)	3 (18.8)	4 (25.0)	1 (6.3)	2 (12.5)	–	–	–
Great horned owl	12	1 (8.3)	–	–	–	–	–	–	–
Northern goshawk	2	2 (100)	–	2 (100)	–	1 (50.0)	–	–	–
Peregrine falcon	3	–	–	–	–	–	–	–	–
Red-shouldered hawk	12	8 (66.7)	–	–	1 (8.3)	–	6 (50.0)	1 (8.3)	–
Red-tailed hawk	36	25 (69.4)	2 (5.6)	1 (2.8)	2 (5.6)	1 (50.0)	12 (33.3)	7 (19.4)	1 (2.8)
Sharp-shinned hawk	4	2 (50.0)	–	–	–	2 (5.6)	–	–	–
Total	85	46 (54.1)	5 (5.9)	7 (8.2)	4 (4.7)	6 (7.1)	18 (21.2)	8 (9.4)	1 (1.2)
Omnivorous species	n	<i>Sarcocystis</i> spp. (28S PCR)	<i>S. calchasi</i>	<i>S. columbae</i>	<i>S. halieta</i>	<i>S. turdusi</i>	<i>S. jamaicensis</i>	<i>S. jamaicensis/S. (Frenkelia) microti</i>	<i>Eumonospora henryae</i>
American crow	11	–	–	–	–	–	–	–	–



**Table 2**

*Sarcocystis* spp. and other Sarcocystidae identified by BLASTn analysis of 28S PCR-positive intestinal samples from dead raptors (n = 85) collected in California, USA between 2016 and 2020. The parasite species was matched by BLASTn to the closest reference sequence available in GenBank. Raptor species include Cooper's hawk (*Accipiter cooperii*), great horned owl (*Bubo virginianus*), northern goshawk (*A. gentilis*), peregrine falcon (*Falco peregrinus*), red-shouldered hawk (*Buteo lineatus*), red-tailed hawk (*B. jamaicensis*), and sharp-shinned hawk (*A. striatus*).

Primary infection <sup>a</sup>	% homology to GenBank	Secondary infection <sup>a</sup>	% homology to GenBank	n (%)
<i>S. jamaicensis</i>	97.0–99.7			13 (15.8)
<i>S. jamaicensis</i>	97.1	<i>S. jamaicensis</i>	96.7	1 (1.2)
<i>S. jamaicensis</i>	97.7	<i>S. jamaicensis</i> or <i>S. (Frenkelia) microti</i> <sup>b</sup>	98.7	1 (1.2)
<i>S. jamaicensis</i> or <i>S. (Frenkelia) microti</i> <sup>b</sup>	99.7	<i>S. jamaicensis</i> or <i>S. (Frenkelia) microti</i> <sup>b</sup>	99.3	1 (1.2)
<i>S. jamaicensis</i> or <i>S. (Frenkelia) microti</i> <sup>b</sup>	99.3			4 (4.7)
<i>S. jamaicensis</i> or <i>S. (Frenkelia) microti</i> <sup>b</sup>	99.3–99.7	<i>S. jamaicensis</i>	97.7	2 (2.4)
<i>S. calchasi</i>	100			5 (5.9)
<i>S. turdusi</i>	98.7–99.7			4 (4.7)
<i>S. turdusi</i>	98.4	<i>S. columbae</i>	99.0	1 (1.2)
<i>S. columbae</i>	99.7			3 (3.5)
<i>S. columbae</i>	99.7	<i>S. turdusi</i>	98.7	1 (1.2)
<i>S. columbae</i>	99.7	<i>S. halietai</i>	100.0	1 (1.2)
<i>S. columbae</i>	99.7	<i>S. jamaicensis</i>	99.0	1 (1.2)
<i>S. halietai</i>	100			3 (3.5)
<i>Eumonospora henryae</i>	95.7			1 (1.2)
Negative				28 (32.9)
Bad quality DNA				11 (12.9)
Unreadable sequences <sup>c</sup>				4 (4.7)

<sup>a</sup> Nine of 85 raptors presented mixed infections, i.e., chromatograms showed clear double peaks in only a few nucleotides. In these cases, two sequences were analyzed separately by combining only the high and low peak nucleotides. The closest BLASTn match for each sequence was considered the primary and secondary infection, respectively.

<sup>b</sup> Eight of 85 raptors had sequences with identical homology percentage to two different sequences by BLASTn for *S. jamaicensis* and *S. (Frenkelia) microti*. In these cases, either of these parasites could be considered as the cause of infection.

<sup>c</sup> Sequence considered unreadable when its respective chromatograph presented high background noise or mixed peaks that rendered it impossible to discern between nucleotides.

and great horned owls ( $X^2 = 5.5$ ,  $P = 0.020$ ) were infected compared to adults. No other age or sex differences were observed.

### 3.3. Phylogenetic analysis

All 28S rRNA sequences from the raptor intestinal samples grouped within the same branch or sub-branch as their respective reference sequence in the phylogenetic tree (Fig. 3). However, for the *S. jamaicensis* and *S. (Frenkelia) microti* sequences, two distinct branches were observed (Fig. 3). The first branch included the *S. jamaicensis* sequences with two separate sub-branches comprised of sequences obtained from red-tailed hawks and red-shouldered hawks, respectively. The second branch included the *S. jamaicensis*/*S. (Frenkelia) microti* sequences that had the same homology percentage, including the GenBank reference sequences. All but one of these sequences were obtained from red-tailed hawks, with one sequence from a red-shouldered hawk. The remaining *Sarcocystis* spp. found in our study formed the lower main

branch of the tree, being distributed in sub-branches, one for each *Sarcocystis* spp. (*S. turdusi*, *S. calchasi*, *S. columbae*, and *S. halietai*) together with their respective reference sequence (Fig. 3). Finally, the *E. henryae* sequence from one red-tailed hawk formed a distant branch in the tree (not shown), accounting for the higher number of dissimilar nucleotides compared to the other sequences.

### 3.4. Histopathological examination

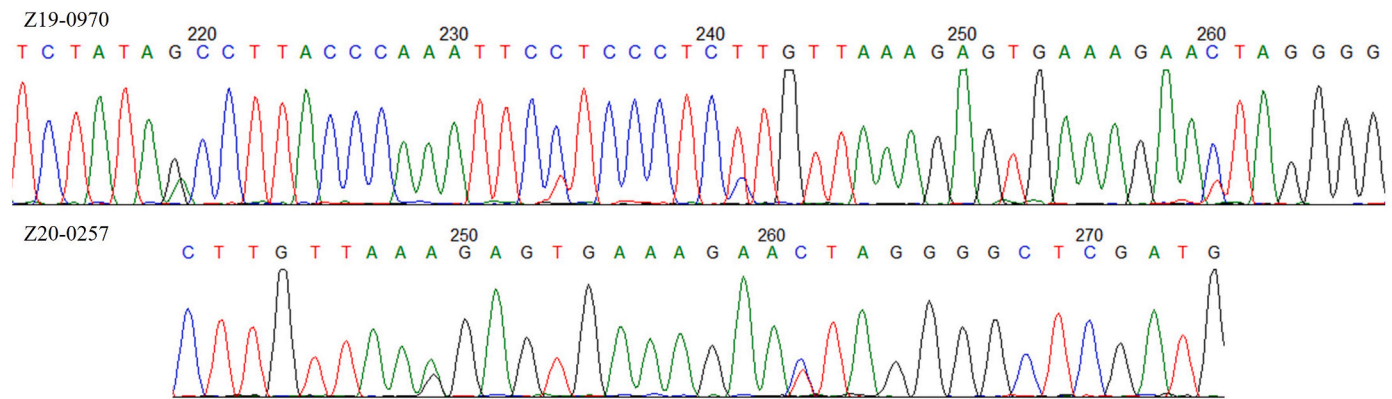
Histopathological evaluation of the intestine was performed on the three Cooper's hawk's and two red-tailed hawk's positive for *S. calchasi*. Structures consistent with sporocysts/oocysts were observed in the mucosa of the intestine in 2 of 3 Cooper's hawks and both red-tailed hawks (Fig. 4); the intestine of one Cooper's hawk was too autolyzed, limiting evaluation.

## 4. Discussion

In this study, Cooper's hawks and red-tailed hawks were identified for the first time as likely definitive hosts for *S. calchasi* in California, the causative agent of protozoal encephalitis in free-ranging rock pigeons and wild Brandt's cormorants. Populations of Cooper's hawks and red-tailed hawks are wide-ranging and may be the definitive hosts of *S. calchasi* elsewhere in North America. Both species are relatively adaptable to living in urban environments where their density is often higher than in more rural and undisturbed areas (Stout and Rosenfield, 2010; Stout et al., 2006). Similarly, large numbers of non-native rock pigeons, Eurasian collared doves, and psittacines, all competent intermediate hosts for *S. calchasi*, also reside in urban environments including that of the San Francisco Bay and Los Angeles Metropolitan Areas (Garrett 1998). This combination of factors may help explain the epizootic nature of *S. calchasi* in these locations with multiple intermediate hosts becoming infected during an overlapping timeframe, which is unique among *Sarcocystis* spp. with a bird-to-bird life cycle. Higher densities of definitive hosts in urban areas, could then contribute to the land-to-sea transmission of *S. calchasi* to a near-shore seabird, the Brandt's cormorant, along the southern California coast during periods of high precipitation.

Northern goshawks were identified as a definitive host of *S. calchasi* following a laboratory study in Germany in which two goshawks were fed pectoral muscle from an infected rock pigeon and began shedding sporocysts on day 6 post-infection (Olias et al., 2010b). Oocysts, each containing two sporocysts, were observed in the mucosa of the small intestine of the goshawk by microscopy. Later, field studies examining the intestinal samples and/or feces of northern goshawks and European sparrowhawks, identified infection with *S. calchasi* through molecular analysis of the ITS1 and 28S rRNA gene segments (Olias et al., 2011; Parmentier et al., 2018), and oocysts were observed in the lamina propria of some birds (Olias et al., 2011). This expanded the definitive host range for *S. calchasi* in Germany, and presumably elsewhere in Europe, to northern goshawks and European sparrowhawks, which both belong to the genus *Accipiter*. In the present study, intestinal samples of seven raptor species and American crows, considered to be possible predators and/or scavengers of rock pigeons, were examined. Three Cooper's hawks and two red-tailed hawks tested positive for *S. calchasi* with a 100% homology to the GenBank reference sequence. Further, histopathology confirmed the presence of sporocysts in the mucosa of the intestine in four of the five raptors indicating sporogony was occurring, rather than the parasite simply passing through the raptor's digestive tract following a meal.

In the United States, the range of northern goshawks is more restricted, and overlaps only rarely with rock pigeons (Squires et al., 1997). However, the range of a related *Accipiter*, the Cooper's hawk, is widespread and commonly overlaps with rock pigeons in diverse habitats including urban areas (Rosenfield et al., 2019). Cooper's hawks are primarily an avian predator that will readily consume pigeons. A



**Fig. 2.** Examples of two 28S rRNA chromatograms showing double, overlapping peaks. The chromatogram for northern goshawk (*Accipiter gentilis*) Z19-0970 (top) from Lassen County, California, USA shows the predominate nucleotide for *Sarcocystis columbae* (99.7% homology) and secondary nucleotide for *S. turdusi* (98.7% homology); clear double peaks are patent at positions 219, 234, 241 and 260. The chromatogram for Cooper's hawk (*A. cooperii*) Z20-0257 (bottom) from Los Angeles County, California, USA shows the predominate nucleotide for *S. columbae* (99.7% homology) and the secondary nucleotide for *S. haliyeti* (100% homology); clear double peaks are patent at positions 249 and 261. Note the marginal presence of noise in the remainder of the sequences.

previous study in Georgia identified a *Sarcocystis* spp. in a Cooper's hawk compatible with *S. calchasi* (Yabsley et al., 2009). However, only the 18S rRNA gene segment was evaluated, and therefore, the parasite could not be conclusively identified as *S. calchasi*. Interestingly in the present study, *S. calchasi* also was detected in red-tailed hawks. Red-tailed hawks belong to the genus *Buteo* but are wide-ranging and have a diverse diet feeding on mammals as well as birds, reptiles, and amphibians (Preston and Beane, 2009). While Cooper's hawks and red-tailed hawks belong to different genera, they are within the family Accipitridae, suggesting other Buteos may be definitive hosts for *S. calchasi*. The study in Georgia also identified closely related *Sarcocystis* spp. based on the 18S rRNA gene segment in red-tailed and red-shouldered hawks (Yabsley et al., 2009). Additional molecular analysis is needed to evaluate the possibility of other definitive hosts for *S. calchasi*.

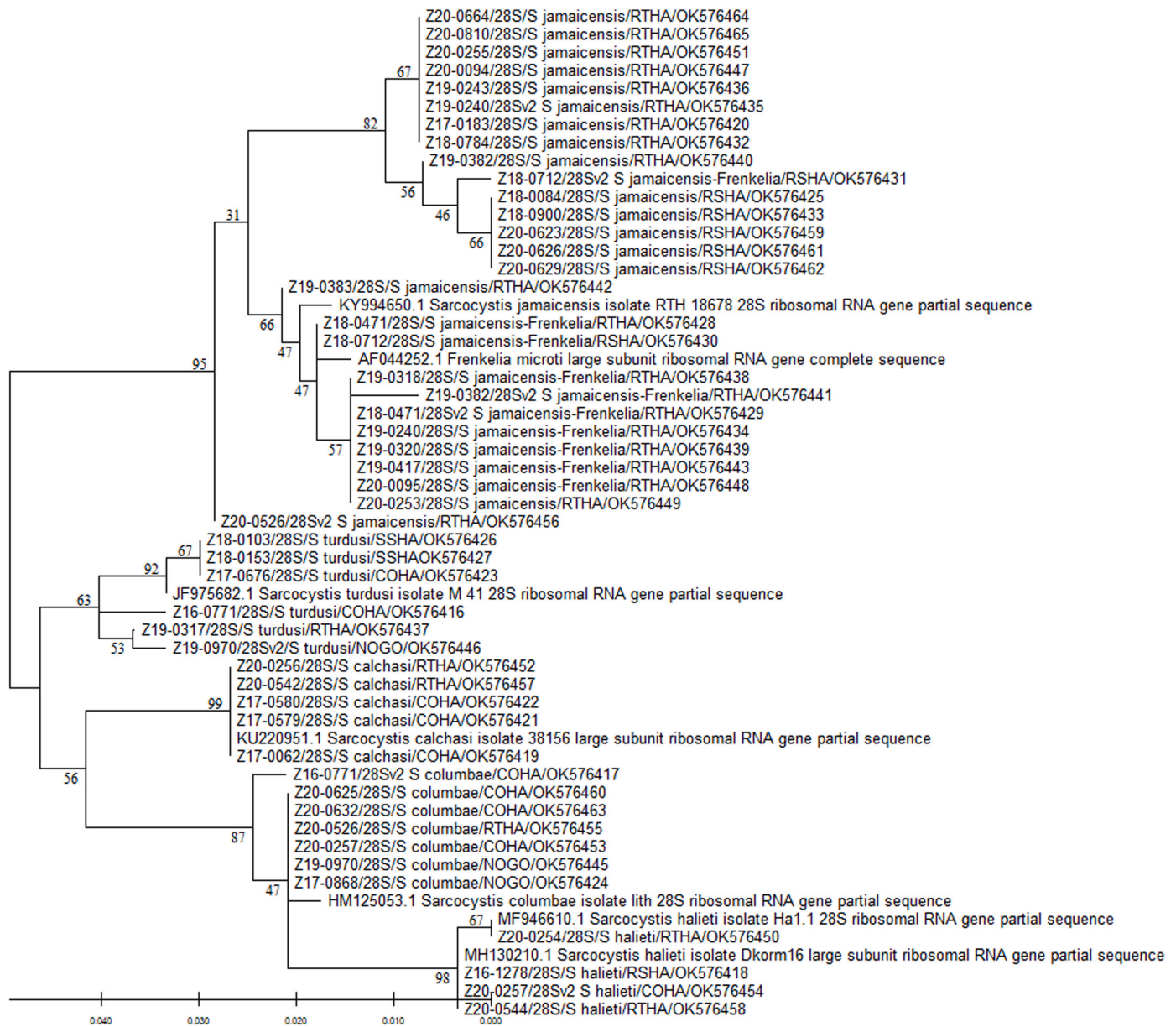
In addition to *S. calchasi*, multiple closely related *Sarcocystis* spp. and other apicomplexan protozoa were detected in the intestinal samples from the raptors evaluated in the present study, including *S. columbae*, *S. haliyeti*, *S. turdusi*, *S. jamaicensis*, *S. jamaicensis/S. (Frenkelia) microti*, and *E. henryae*. Co-infection with multiple *Sarcocystis* spp. were found in nine raptors. While the 28S and ITS1 PCRs successfully identified the DNA of apicomplexans in the intestine of 54% (46/85) of the raptors in our study, this methodology may overlook the presence of other protozoa that are not detectable with these primers (Gjerde et al., 2018). Furthermore, some sequences had only 96–99% homology to reference sequences in GenBank; thus, comparing sequences from other conserved regions (e.g., ITS1) and employing additional techniques that allow screening for multiple genera and/or species, such as restriction fragment length polymorphism, are needed to confirm the identity of these parasites.

In the present study, new potential definitive hosts were identified for several previously recognized *Sarcocystis* spp. Northern goshawks and European sparrowhawks had been identified as definitive hosts for *S. columbae* in Europe (Olias et al., 2011) whereas in the United States, a species related to *S. columbae* had been detected in the intestinal tract of a single Cooper's hawk from North Carolina (Lindsay et al., 2017). Northern goshawks and red-tailed hawks also were identified as possible definitive hosts for *S. columbae* in the present study. Muscle cysts of *S. columbae* were previously observed in native wood pigeons (*Columba palumbus*) from Germany and Lithuania (Olias et al., 2010c; Prakas et al., 2011). A comparable intermediate host for *S. columbae* in the western United States is the native band-tailed pigeon (*Patagioenas fasciata*) which inhabit conifer and deciduous forests (Keppie and Braun, 2000). However, since band-tailed pigeons do not occur in the eastern United States, other intermediate hosts are likely. Sarcocysts of *S. columbae* also

were found in one herring gull (*Larus argentatus*) in Lithuania with sequences 99.9–100% identical to those from wood pigeons (Prakas et al., 2020), which supports an expansive host range.

Definitive hosts of *S. turdusi* had not been previously established although muscle cysts of *S. turdusi* were found in common blackbirds (*Turdus merula*) in Lithuania (Kutkiene et al., 2012). In the present study, three *Accipiter* spp. and red-tailed hawks were identified as possible definitive hosts of *S. turdusi* suggesting that North American blackbirds also may harbor this parasite. For *S. haliyeti*, the white-tailed sea eagle (*Haliaeetus albicilla*) and the much smaller European sparrowhawk have been recognized as definitive hosts in Europe (Gjerde et al., 2018; Mayr et al., 2016). This suggests that in addition to great cormorants (*Phalacrocorax carbo*) and herring gulls (Prakas et al., 2018, 2020), other intermediate hosts such as songbirds are likely for *S. haliyeti*, which is supported by the diversity of potential definitive hosts identified in the present study. Interestingly, two raptor species were recently identified as intermediate hosts of *S. haliyeti* although the morphology of the sarcocysts in the muscle varied from those described in non-raptorial intermediate hosts (Prakas et al., 2021). Encephalitis in a little owl (*Athene noctua*) also was associated with *S. haliyeti* infection (Maier-Sam et al., 2021). Studies evaluating the transmission of *Sarcocystis* spp., including *S. haliyeti*, are needed to clarify the life cycles of these parasites.

The taxonomy of some parasites remains unclear and requires further study, for example, *S. jamaicensis* and *S. (Frenkelia) microti*. Red-tailed hawks have been identified as a definitive host for both parasites with various rodents being the likely intermediate host for *S. jamaicensis* and known intermediate host for *S. (Frenkelia) microti* (Upton and McKown, 1992; Verma et al., 2017). Our analysis has identified red-shouldered hawks as another possible definitive host for these parasites. Early researchers established *Frenkelia* as a separate genus from *Sarcocystis* based on the sarcocysts identified in the brain of rodents infected with *Frenkelia* spp.; however, later it became clear that some *Sarcocystis* spp. also may form cysts in the brain in addition to the muscle tissue (Dubey et al., 2016; Votykpa et al., 1998). Recent molecular analyses indicate that *Frenkelia* is closely related to *Sarcocystis*, and that *Frenkelia* should be a junior synonym to *Sarcocystis* (Verma et al., 2017). Our analysis supports this finding and suggests that *S. jamaicensis* and *S. microti* are different species as they have two single nucleotide polymorphisms (SNP), although these SNPs occur at different locations. The *S. jamaicensis* and *S. microti* sequences also comprised two separate branches in the phylogenetic tree. Interestingly, within the *S. jamaicensis* branch, there were two distinct sub-branches for sequences from red-tailed hawks and red-shouldered hawks, respectively. This suggests these *S. jamaicensis*-like parasites could be new variants or subspecies of *S. jamaicensis* and that a particular variant may be more common in



**Fig. 3.** Phylogenetic tree based on 28S rRNA sequences of *Sarcocystis* spp. obtained from raptor intestinal samples and reference sequences available in GenBank. The phylogenetic relationships were determined by the Maximum Likelihood method using MEGA-X version 10.2.6 (Kumar et al., 2018). Numbers above or below nodes represent bootstrap confidence values from 500 replicates. The distances were computed using the Tamura-Nei model (Tamura and Nei, 1993). Branch lengths are proportional to sequence divergence and relate to the scale bar (bottom left). GenBank reference sequences are labeled by their accession number and associated information. Raptor sequences are labeled by animal identification number, region amplified (28S), *Sarcocystis* spp. with the highest homology found by BLASTn, 4-letter alpha-code for the raptor species common name, and NCBI accession number. COHA: Cooper’s hawk (*Accipiter cooperii*), NOGO: northern goshawk (*A. gentilis*), RSHA: red-shouldered hawk (*Buteo lineatus*), RTHA: red-tailed hawk (*B. jamaicensis*), SSHA: sharp-shinned hawk (*A. striatus*). Note the *Eumonospora henryae*-like sequence was not included in the analysis. Detailed information for each bird and sequence is presented in [Supplementary Table 1](#).

different raptor species. Given the small number of SNPs and less than 100% homology to the GenBank reference sequence, further studies are needed to evaluate these variants.

Another genus with unclear taxonomy is *Eumonospora*. The *Eumonospora*-like parasite identified in the present study was distantly related to the *Sarcocystis* spp. found in the raptor intestinal samples. Recently, Chou et al. (2020) suggested *Eumonospora* should be synonymized with *Caryospora* and *Avispora*. In Japan, *E. henryae* was identified in fecal samples from five captive owls, including four different species (Chou et al., 2020), and a captive merlin (*F. columbarius*) (Chou et al., 2021). The merlin was exhibiting severe watery diarrhea, and infections with *Caryospora* spp. reportedly have been associated with diarrhea in captive-bred raptors in Europe and the Middle East (Forbes et al., 1997;

Mateuta and Samour, 2017). The *E. henryae*-like sequence detected in the single red-tailed hawk in the present study was only 95.7% homologous to the sequence from the merlin (Chou et al., 2021), which may indicate a different, yet-to-be defined but closely related, parasite. The red-tailed hawk was admitted to a wildlife rehabilitation center after it was found grounded and presented with emaciation and copious green diarrhea; coccidia oocysts were noted on fecal floatation. Additional research is needed to determine if red-tailed hawks are a true definitive host for *E. henryae*.

## 5. Conclusions

In this study, we identify for the first time Cooper’s hawks and red-



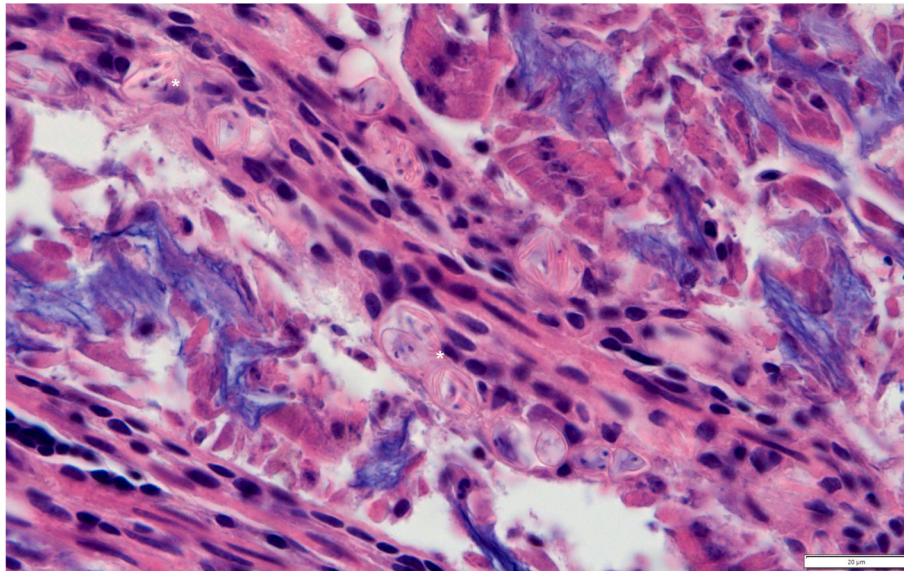


Fig. 4. Photomicrograph of intestine from *Sarcocystis calchasi*-positive Cooper's hawk (*Accipiter cooperii*) Z17-0062 collected from Los Angeles County, California, USA, showing sporocysts/oocysts (\*) in the mucosa. Hematoxylin and eosin stain; scale bar 20  $\mu$ m.

tailed hawks as likely definitive hosts for *S. calchasi* in California, as well as identify new possible definitive hosts for other related *Sarcocystis* spp. by using ITS1 and 28S sequence analysis. Further research is needed to determine the competency of *S. calchasi*-definitive hosts for producing and shedding sporocysts into the environment to better understand infection dynamics. Specifically for *S. calchasi*, the management of non-native populations of columbids and psittacines in urban areas may be warranted to help protect the health of sensitive marine species susceptible to infection following periods of high precipitation. Additionally, further molecular surveillance for *Sarcocystis* spp. in both definitive and intermediate hosts is needed to elucidate the complete life cycle for closely related bird-infecting *Sarcocystis* spp. Experimental infection studies also are necessary to confirm the definitive and intermediate hosts for these parasites.

#### Declaration of competing interest

The authors declare no conflict of interest.

#### Acknowledgements

We thank the staff and volunteers at the California Wildlife Center (Calabasas, CA), Defiance Canyon Raptor Rescue (Bieber, CA), East Bay Regional Park District (Oakland, CA), Golden Gate Raptor Observatory (San Rafael, CA), Greater Los Angeles County Vector Control District (Sylmar, CA), Lindsay Wildlife Experience (Walnut Creek, CA), Mid-peninsula Regional Open Space District (Los Altos, CA), Ohlone Humane Society Wildlife Rehabilitation Center (Fremont, CA), Pasadena Humane (Pasadena, CA), Peninsula Humane Society and SPCA (Burlingame, CA), Presidio Trust (San Francisco, CA), Santa Barbara Wildlife Care Network (Goleta, CA), Wildcare Eastern Sierra (Bishop, CA), Wildlife Center of Silicon Valley (San Jose, CA) for submitting carcasses. We thank T. Giudici, T. Kasteen, S. McMillin, B. Munk, K. Rush, N. Shirkey, and T. Tognazzini with CDFW for assisting with the mortality investigations. This research did not receive any specific grant from funding agencies in the public, commercial, or not-for-profit sectors. The authors declare no conflict of interest.

#### Appendix A. Supplementary data

Supplementary data to this article can be found online at <https://doi.org/10.1016/j.ijppaw.2021.12.008>.

[org/10.1016/j.ijppaw.2021.12.008](https://doi.org/10.1016/j.ijppaw.2021.12.008).

#### References

- Altschul, S.F., Gish, W., Miller, W., Myers, E.W., Lipman, D.J., 1990. Basic local alignment search tool. *J. Mol. Biol.* 215, 403–410.
- Bamac, O.E., Rogers, K.H., Arranz-Solis, D., Saeij, J.P., Lewis, S., Duerr, R., Skoglund, J., Peronne, L., Mete, A., 2020. Protozoal encephalitis associated with *Sarcocystis calchasi* and *S. falcatula* during an epizootic involving Brandt's cormorants (*Phalacrocorax penicillatus*) in coastal Southern California, USA. *Int. J. Parasitol. Parasites Wildl.* 12, 185–191.
- Box, E.D., Smith, J.H., 1982. The intermediate host spectrum in a *Sarcocystis* species of birds. *J. Parasitol.* 68, 668–673.
- Chou, S., Izawa, N., Ike, K., Tokiwa, T., 2021. Detection of *Eumonospora henryae* (Apicomplexa: Sarcocystidae) from *Falco columbarius* (Falconiformes: Aves): comparison of host–parasite phylogram and comments on the family Sarcocystidae. *Poche, 1913. Int. J. Parasitol. Parasites Wildl.* 14, 75–83.
- Chou, S., Tokiwa, T., Hadano, S., Izawa, N., Ueda, M., Kojima, A., Ike, K., 2020. Resurrection of the genus *Eumonospora* (Apicomplexa: Sarcocystidae) for *Caryospora* species without stieda body. *Parasitol. Int.* 77, 102101.
- Dubey, J.P., Calero-Bernal, R., Rosenthal, B.M., Speer, C.A., Fayer, R., 2016. *Sarcocystosis of Animals and Humans*, second ed. CEC Press, Taylor and Francis Group, Boca Raton, Florida.
- Forbes, N.A., Simpson, G.N., 1997. *Caryospora neofalconis*: an emerging threat to captive-bred raptors in the United Kingdom. *J. Avian Med. Surg.* 11, 110–114.
- Garrett, K.L., 1998. Population trends and ecological attributes of introduced parrots, doves, and finches in California. In: Baker, R.O., Crabb, A.C. (Eds.), *Proc. 18<sup>th</sup> Verteb. Pest Conf.*, Univ. of California, Davis, pp. 46–54.
- Gjerde, B., Vikøren, T., Hammes, I.S., 2018. Molecular identification of *Sarcocystis halietae* n. sp., *Sarcocystis lari* and *Sarcocystis truncata* in the intestine of a white-tailed sea eagle (*Haliaeetus albicilla*) in Norway. *Int. J. Parasitol. Parasites Wildl.* 7, 1–11.
- Hall, T.A., 1999. BioEdit: a user-friendly biological sequence alignment editor and analysis program for Windows 95/98/NT. *Nucleic Acids Symp. Ser.* 41, 95–98.
- Hintze, J., 2007. NCSS. Statistical Software. Version 07.1.21. NCSS, LLC, Kaysville, Utah.
- Hodo, C.L., Whitley, D.B., Hamer, S.A., Corapi, W.V., Snowden, K., Heatley, J.J., Hoffmann, A.R., 2016. Histopathologic and molecular characterization of *Sarcocystis calchasi* encephalitis in white-winged doves (*Zenaida asiatica*) and Eurasian collared doves (*Streptopelia decaocto*), East-central Texas, USA, 2010–13. *J. Wildl. Dis.* 52, 395–399.
- Keppie, D.M., Braun, C.E., 2000. Band-tailed pigeon (*Patagioenas fasciata*), version 1.0. In: Poole, A.F., Gill, F.B. (Eds.), *Birds of the World*. Cornell Lab of Ornithology, Ithaca, New York, USA. <https://doi.org/10.2173/bow.batpig1.01>. Available online: (Accessed 12 September 2021).
- Kumar, S., Stecher, G., Li, M., Nknyaz, C., Tamura, K., 2018. MEGA X: molecular evolutionary genetics analysis across computing platforms. *Mol. Biol. Evol.* 35, 1547–1549.
- Kutkienė, L., Prakas, P., Butkauskas, D., Sruoga, A., 2012. Description of *Sarcocystis turdusi* sp. nov. from the common blackbird (*Turdus merula*). *Parasitology* 139, 1438–1443.
- Lindsay, D.S., Verma, S.K., Scott, D., Dubey, J.P., von Dohlen, A.R., 2017. Isolation, molecular characterization, and in vitro schizogonic development of *Sarcocystis* sp. ex *Accipiter cooperii* from a naturally infected Cooper's hawk (*Accipiter cooperii*). *Parasitol. Int.* 66, 106–111.



- Luznar, S.L., Avery, M.L., Dame, J.B., MacKay, R.J., Greiner, E.C., 2001. Development of *Sarcocystis falcatula* in its intermediate host, the brown-headed cowbird (*Molothrus ater*). *Vet. Parasitol.* 95, 327–334.
- Maier, K., Olias, P., Enderlein, D., Klopffleisch, R., Mayr, S.L., Gruber, A.D., Lierz, M., 2015. Parasite distribution and early-stage encephalitis in *Sarcocystis calchasi* infections in domestic pigeons (*Columba livia f. domestica*). *Avian Pathol.* 44, 5–12.
- Maier-Sam, K., Kaiponen, T., Schmitz, A., Schulze, C., Bock, S., Hlinak, A., Olias, P., 2021. Encephalitis associated with *Sarcocystis halieti* infection in a free-ranging little owl (*Athene noctua*). *J. Wildl. Dis.* 57, 712–714.
- Mateuta, V.D., Samour, J.H., 2017. Prevalence of *Caryospora* species (Apicomplexa: Eimeriidae) in falcons in the United Arab Emirates. *J. Avian Med. Surg.* 31, 327–334.
- Mayr, S.L., Maier, K., Müller, J., Enderlein, D., Gruber, A.D., Lierz, M., 2016. *Accipiter* hawks (Accipitridae) confirmed as definitive hosts of *Sarcocystis turdusi*, *Sarcocystis cornixi* and *Sarcocystis* sp. ex *Phalacrocorax carbo*. *Parasitol. Res.* 115, 3041–3047.
- Mete, A., Rogers, K.H., Wolking, R., Bradway, D.S., Kelly, T., Piazza, M., Crossley, B., 2019. *Sarcocystis calchasi* outbreak in feral rock pigeons (*Columba livia*) in California. *Vet. Pathol.* 56, 317–321.
- Miller, M.A., Conrad, P.A., Harris, M., Hatfield, B., Langlois, G., Jessup, D.A., Magargal, S.L., Packham, A.E., Toy-Choutka, S., Melli, A.C., 2010. A protozoal-associated epizootic impacting marine wildlife: mass-mortality of southern sea otters (*Enhydra lutris nereis*) due to *Sarcocystis neurona* infection. *Vet. Parasitol.* 172, 183–194.
- Miller, M.A., Gardner, I.A., Kreuder, C., Paradies, D.M., Worcester, K.R., Jessup, D.A., Dodd, E., Harris, M., Ames, J.A., Packham, A.E., Conrad, P.A., 2002. Coastal freshwater runoff is a risk factor for *Toxoplasma gondii* infection of southern sea otters (*Enhydra lutris nereis*). *Int. J. Parasitol.* 32, 997–1006.
- Olias, P., Olias, L., Krücken, J., Lierz, M., Gruber, A.D., 2011. High prevalence of *Sarcocystis calchasi* sporocysts in European *Accipiter* hawks. *Vet. Parasitol.* 175, 230–236.
- Olias, P., Gruber, A.D., Heydorn, A.O., Kohls, A., Hafez, H.M., Lierz, M., 2010a. Unusual biphasic disease in domestic pigeons (*Columba livia f. domestica*) following experimental infection with *Sarcocystis calchasi*. *Avian Dis.* 54, 1032–1037.
- Olias, P., Gruber, A.D., Heydorn, A.O., Kohls, A., Mehlhorn, H., Hafez, H.M., Lierz, M., 2009. A novel *Sarcocystis*-associated encephalitis and myositis in racing pigeons. *Avian Pathol.* 38, 121–128.
- Olias, P., Gruber, A.D., Kohls, A., Hafez, H.M., Heydorn, A.O., Mehlhorn, H., Lierz, M., 2010b. *Sarcocystis* species lethal for domestic pigeons. *Emerg. Infect. Dis.* 16, 497.
- Olias, P., Maier, K., Wuenschmann, A., Reed, L., Armien, A.G., Shaw, D.P., Gruber, A.D., Lierz, M., 2014. *Sarcocystis calchasi* has an expanded host range and induces neurological disease in cockatiels (*Nymphicus hollandicus*) and North American rock pigeons (*Columbia livia f. dom.*). *Vet. Parasitol.* 200, 59–65.
- Olias, P., Olias, L., Lierz, M., Mehlhorn, H., Gruber, A.D., 2010c. *Sarcocystis calchasi* is distinct to *Sarcocystis columbae* sp. nov. from the wood pigeon (*Columba palumbus*) and *Sarcocystis* sp. from the sparrowhawk (*Accipiter nisus*). *Vet. Parasitol.* 171, 7–14.
- Olson, E.J., Wünschmann, A., Dubey, J.P., 2007. *Sarcocystis* sp.-associated meningoencephalitis in a bald eagle (*Haliaeetus leucocephalus*). *J. Vet. Diagn. Invest.* 19, 564–568.
- Parmentier, S.L., Maier-Sam, K., Failing, K., Enderlein, D., Gruber, A.D., Lierz, M., 2018. Prevalence of *Sarcocystis calchasi* in free-ranging host species: *Accipiter* hawks and common wood pigeon in Germany. *Sci. Rep.* 8, 1–8.
- Prakas, P., Bea, A., Juozaitytė-Ngugu, E., Olano, I., Villanúa, D., Švažas, S., Butkauskas, D., 2021. Molecular identification of *Sarcocystis halieti* in the muscles of two species of birds of prey from Spain. *Parasites Vectors* 14, 1–7.
- Prakas, P., Butkauskas, D., Juozaitytė-Ngugu, E., 2020. Molecular identification of four *Sarcocystis* species in the herring gull, *Larus argentatus*, from Lithuania. *Parasites Vectors* 13, 1–6.
- Prakas, P., Butkauskas, D., Sruoga, A., Švažas, S., Kutkienė, L., 2011. Identification of *Sarcocystis columbae* in wood pigeons (*Columba palumbus*) in Lithuania. *Vet. Med. Zoot* 55, 33–39.
- Prakas, P., Butkauskas, D., Švažas, S., Stanevičius, V., 2018. Morphological and genetic characterization of *Sarcocystis halieti* from the great cormorant (*Phalacrocorax carbo*). *Parasitol. Res.* 117, 3663–3667.
- Preston, C.R., Beane, R.D., 2009. Red-tailed hawk (*Buteo jamaicensis*), version 1.0. In: Poole, A.F. (Ed.), *Birds of the World*. Cornell Lab of Ornithology, Ithaca, New York, USA. <https://doi.org/10.2173/bow.rethaw.01>. Available online: (Accessed 12 September 2021).
- Rimoldi, G., Speer, B., Wellehan Jr., J.F., Bradway, D.S., Wright, L., Reavill, D., Barr, B. C., Childress, A., Shivaprasad, H.L., Chin, R.P., 2013. An outbreak of *Sarcocystis calchasi* encephalitis in multiple psittacine species within an enclosed zoological aviary. *J. Vet. Diagn. Invest.* 25, 775–781.
- Rosenfield, R.N., Madden, K.K., Bielefeldt, J., Curtis, O.E., 2019. Cooper's hawk (*Accipiter cooperii*), version 1.0. In: Rodewald, P.G. (Ed.), *Birds of the World*. Cornell Lab of Ornithology, Ithaca, NY, USA. <https://doi.org/10.2173/bow.coohaw.01>. Available online: (Accessed 12 September 2021).
- Squires, J.R., Reynolds, R.T., Orta, J., Marks, J.S., 1997. Northern goshawk (*Accipiter gentilis*), version 1.0. In: Billerman, S.M. (Ed.), *Birds of the World*. Cornell Lab of Ornithology, Ithaca, NY, USA. <https://doi.org/10.2173/bow.norgos.01>. Available online: (Accessed 12 September 2021).
- Stout, W.E., Rosenfield, R.N., 2010. Colonization, growth, and density of a pioneer Cooper's hawk population in a large metropolitan environment. *J. Raptor Res.* 44, 255–267.
- Stout, W.E., Temple, S.A., Cary, J.R., 2006. Landscape features of red-tailed hawk nesting habitat in an urban/suburban environment. *J. Raptor Res.* 40, 181–192.
- Tamura, K., Nei, M., 1993. Estimation of the number of nucleotide substitutions in the control region of mitochondrial DNA in humans and chimpanzees. *Mol. Biol. Evol.* 10, 512–526.
- Trupkiewicz, J.G., Calero-Bernal, R., Verma, S.K., Mowery, J., Davison, S., Habecker, P., Georoff, T.A., Ialeggio, D.M., Dubey, J.P., 2016. Acute, fatal *Sarcocystis calchasi*-associated hepatitis in Roller pigeons (*Columba livia f. dom.*) at Philadelphia Zoo. *Vet. Parasitol.* 216, 52–58.
- Upton, S.J., McKown, R.D., 1992. The red-tailed hawk, *Buteo jamaicensis*, a native definitive host of *Frenkelia microti* (Apicomplexa) in North America. *J. Wildl. Dis.* 28, 85–90.
- Ushio, N., Watanabe, K.I., Chambers, J.K., Shibato, T., Nakayama, H., Uchida, K., 2015. *Sarcocystis calchasi* encephalitis in a rock pigeon. *J. Vet. Med. Sci.* 77, 1523–1526.
- Verma, S.K., Von Dohlen, A.R., Mowery, J.D., Scott, D., Rosenthal, B.M., Dubey, J.P., Lindsay, D.S., 2017. *Sarcocystis jamaicensis* n. sp., from red-tailed hawks (*Buteo jamaicensis*) definitive host and IFN- $\gamma$  gene knockout mice as experimental intermediate host. *J. Parasitol.* 103, 555–564.
- Votypka, J., Hypša, V., Jirku, M., Flegr, J., Vavra, J., Lukes, J., 1998. Molecular phylogenetic relatedness of *Frenkelia* spp. (Protozoa, Apicomplexa) to *Sarcocystis falcatula* Stiles 1893: is the genus *Sarcocystis* paraphyletic? *J. Eukaryot. Microbiol.* 45, 137–141.
- Wünschmann, A., Armien, A.G., Reed, L., Gruber, A.D., Olias, P., 2011. *Sarcocystis calchasi*-associated neurologic disease in a domestic pigeon in North America. *Transbound. Emerg. Dis.* 58, 526–530.
- Wünschmann, A., Rejmanek, D., Conrad, P.A., Hall, N., Cruz-Martinez, L., Vaughn, S.B., Barr, B.C., 2010. Natural fatal *Sarcocystis falcatula* infections in free-ranging eagles in North America. *J. Vet. Diagn. Invest.* 22, 282–289.
- Wünschmann, A., Rejmanek, D., Cruz-Martinez, L., Barr, B.C., 2009. *Sarcocystis falcatula*-associated encephalitis in a free-ranging great horned owl (*Bubo virginianus*). *J. Vet. Diagn. Invest.* 21, 283–287.
- Yabsley, M.J., Ellis, A.E., Stallknecht, D.E., Howarth, E.W., 2009. Characterization of *Sarcocystis* from four species of hawks from Georgia, USA. *J. Parasitol.* 95, 256–259.