

Locking Plate Use with or without Strut Support for Varus Displaced Proximal Humeral Fractures in Elderly Patients

Hongshu Wang, MD, Biyu Rui, PhD, Shengdi Lu, MD, Congfeng Luo, PhD, Yunfeng Chen, PhD, and Yimin Chai, PhD

Investigation performed at the Department of Orthopaedics, Shanghai Jiao Tong University Affiliated Sixth People's Hospital, Shanghai, People's Republic of China

Background: Varus displaced fractures of the proximal part of the humerus, particularly in osteoporotic bone, commonly require open reduction and internal fixation. However, surgical treatment methods remain controversial and have shown inconsistent results. A fibular allograft for indirect medial reduction and strut support has been used in an effort to prevent secondary postoperative varus displacement. However, the long-term outcomes of this method require confirmation. We hypothesized that placing a fibular strut parallel to the calcar screw could increase the biomechanical stability of the medial hinge, thus preventing secondary varus deformity. In the present study, we compared the clinical outcomes of locking plate use with and without medial strut support with use of a fibular allograft for the treatment of varus humeral fractures in patients ≥ 65 years old.

Methods: We compared 2 different graft techniques involving the use of fibular allografts in elderly patients with varus displaced proximal humeral fractures who underwent open reduction and internal fixation. The patients were divided into 3 groups: (1) the intramedullary graft group (Group A), (2) the medial hinge support group (Group B), and (3) the locking plate alone group (Group C). Clinical outcomes included the final varus angulation of the humeral head, the occurrence of major complications (screw cut-out or cut-through or osteonecrosis), and the American Shoulder and Elbow Surgeons (ASES) score at 1 year after treatment.

Results: A total of 128 patients were included in our study. The final varus angles were 14.7° , 13.1° , and 18.6° , for the intramedullary graft group, the medial hinge support group, and locking plate alone group, respectively. The mean ASES scores were 87.2, 88.6, and 82.2, respectively. There were differences in ASES scores between Group A and Group C as well as also between Group B and Group C. Fewer major complications were found in patients managed with locking plates in combination with intramedullary graft or medial hinge support (Group A and Group B) than in patients managed with locking plates alone (Group C).

Conclusions: The use of a locking plate in combination with medial strut support with use of a fibular allograft reduced complications when used for the treatment of varus displaced proximal humeral fractures in elderly patients in comparison with the use of a locking plate alone.

Level of Evidence: Therapeutic Level III. See Instructions for Authors for a complete description of levels of evidence.

Fractures of the proximal part of the humerus are the third most common type of fracture, accounting for 4% to 10% of all fractures¹. The incidence of proximal humeral fractures increases steadily with age². Nonoperative treatment of displaced fractures avoids implant-related complications that are widely recognized following surgical intervention. However,

consistently satisfactory results cannot always be expected with conservative treatment³⁻⁵.

Recent reports have shown that these fractures are amenable to reduction with operative stabilization and early rehabilitation⁶. Locking plates with angular-stable screws provide more stability to osteoporotic bone; however, the complication

Disclosure: The authors indicated that no external funding was received for any aspect of this work. The **Disclosure of Potential Conflicts of Interest** forms are provided with the online version of the article (<http://links.lww.com/JBJSOA/A106>).

Copyright © 2019 The Authors. Published by The Journal of Bone and Joint Surgery, Incorporated. All rights reserved. This is an open-access article distributed under the terms of the [Creative Commons Attribution-Non Commercial-No Derivatives License 4.0](https://creativecommons.org/licenses/by-nc-nd/4.0/) (CCBY-NC-ND), where it is permissible to download and share the work provided it is properly cited. The work cannot be changed in any way or used commercially without permission from the journal.

rate remains high⁷. One of the major complications of surgical treatment for proximal humeral fractures in the elderly is fixation failure-related secondary varus displacement due to screw cut-out or cut-through⁸. Walch et al. first described the use of intramedullary grafts to treat nonunion of the humeral surgical neck⁹. The use of a fibular allograft for indirect medial reduction and strut support was then proposed by Gardner et al. in an attempt to solve the problem of secondary postoperative varus displacement of proximal humeral fractures¹⁰. Although widely accepted and applied, the long-term outcomes of this method require confirmation in clinical trials.

In addition to the method of using the fibular allograft for indirect medial reduction and strut support as described by Gardner et al., we also applied another method using fibular allograft in which the fibular strut is placed parallel to the calcar screw, mainly to support the medial hinge and also to serve as a humeral head buttress.

In the present study, we compared the clinical outcomes of 3 techniques for the treatment of varus humeral fractures in patients ≥ 65 years old using a locking plate (including 2 techniques also involving fibular allografting and 1 technique involving a locking plate alone).

Materials and Methods

Ethical Considerations

The study was approved by the Ethics Committee of Shanghai Jiao Tong University Affiliated Sixth People's Hospital.

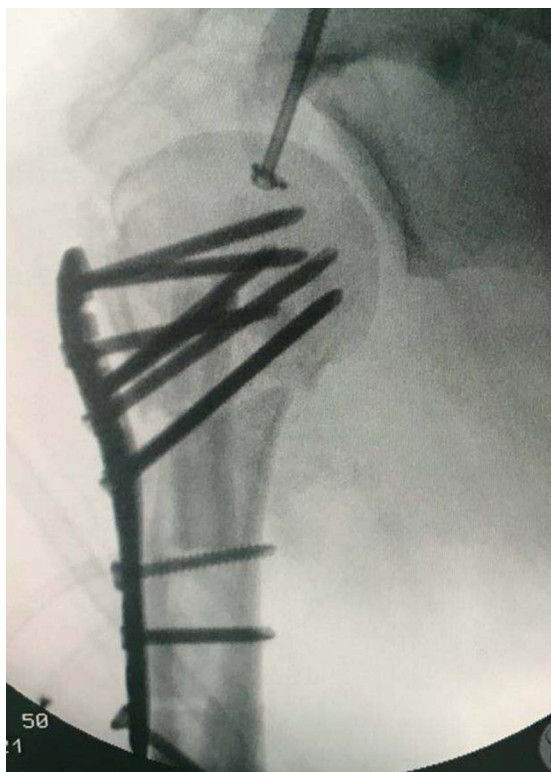


Fig. 1
Radiograph showing the intramedullary graft pattern of fibular allografting.

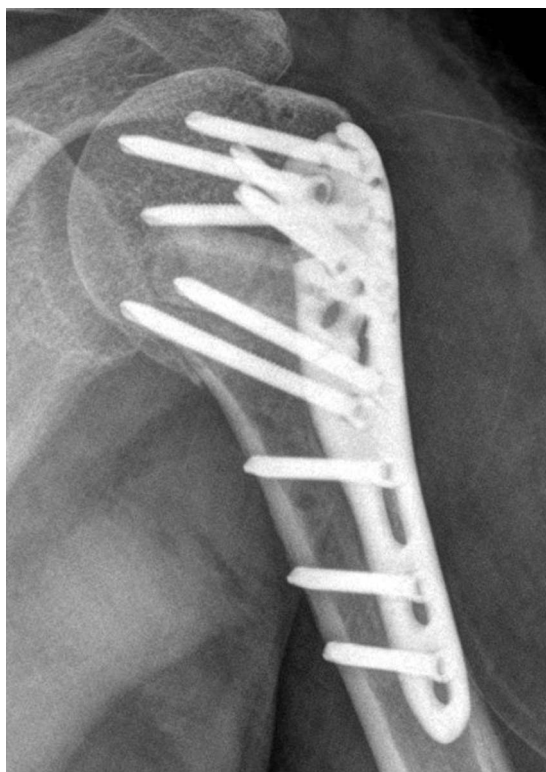


Fig. 2
Radiograph showing the medial hinge support pattern of fibular allografting.

Informed consent was obtained from all donors. All study methods were in accordance with the Declaration of Helsinki.

Patient Selection Criteria

Acute AO/OTA type-11C proximal humeral fractures (4-part fractures according to the Neer classification system⁷) with humeral head varus displacement that had occurred ≤ 3 days before treatment with open reduction and locking plate fixation alone or with medial strut support in the form of a fibular allograft were included in our analysis. All fractures occurred between January 2012 and January 2015. The inclusion criteria were the completion of at least 1 year of follow-up and a patient age of ≥ 65 years at the time of the fracture. The exclusion criteria included any injuries to upper-limb tendons, ligaments, vessels, or nerves; open fractures; and additional fractures involving the ipsilateral elbow, wrist, or hand. The patients were divided into 3 groups on the basis of the treatment method: Group A (intramedullary grafting), Group B (medial hinge support), and Group C (locking plate alone).

Surgical Procedures

All procedures were performed at a single trauma center (Department of Orthopaedic Surgery, Shanghai Jiao Tong University Affiliated Sixth People's Hospital). Patients were placed in the beach-chair position with the injured shoulder resting on a radiolucent part of the operating table. After exposure through a deltopectoral approach, there were 2 patterns

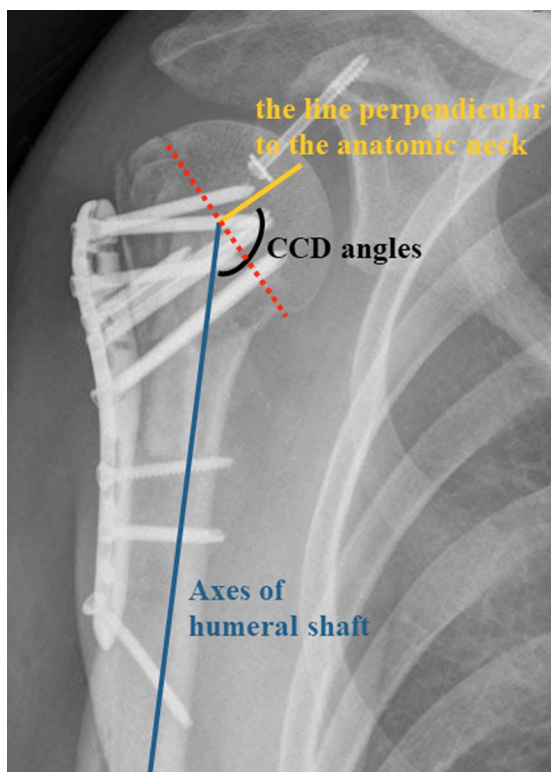


Fig. 3
The CCD angle was calculated on a 20° external rotation anteroposterior radiograph by comparing the angle of intersection between the axis of the proximal part of the humerus and the line perpendicular to the anatomical neck. The red dotted line indicates the anatomical neck, the yellow line is perpendicular to the anatomical neck, and the blue line indicates the axis of the humeral shaft.

of fibular insertion: (1) intramedullary grafting and (2) medial hinge support.

Intramedullary grafting: A fibular segment with a length of approximately 6 to 8 cm was cut with a sagittal oscillating saw on the back table. The fibular segment was manipulated with a 1.5-mm Kirschner wire and then was inserted into the medullary canal through the fracture line between the greater and lesser tuberosities. The fibular segment was then placed along the longitudinal axis of the humeral shaft. Appropriate allograft length was confirmed fluoroscopically to ensure that the graft was positioned 2 to 3 cm proximal to the level of the surgical neck of the humerus (Fig. 1).

Medial hinge support: A fibular segment with a length of approximately 4 cm was cut with a sagittal oscillating saw on the back table. The fragment of the greater tuberosity was elevated, and the fibular segment was placed through the cavity, with the distal end of the fibular graft contacting and supporting the lower part of humeral head. The excess part of the fibular segment was cut accordingly. After secondary trimming of the fibular graft, the graft was placed parallel to the calcar screws of the locking plate (AO PHILOS, titanium 6-aluminum 7-niobium, ISO 5832-11), and approximately 1.5 cm above the medial cortex of the hinge to allow for the insertion of the calcar screws. The appropriate length of the fibular segment was determined so that the proximal end of fibular segment was in direct contact with the fracture surface of the humeral head (Fig. 2).

The decision to insert the fibular segment was based on surgeon preference. The procedures were conducted by 6 trauma surgery specialists. After surgical stabilization, all shoulders underwent passive range-of-motion and pendulum exercises within 6 weeks. Active range-of-motion exercise was

TABLE I Demographics Characteristics and Clinical Outcomes at 1 Year				
	Group A: Intramedullary Graft (N = 39)	Group B: Medial Hinge Support (N = 43)	Group C: Locking Plate Alone (N = 46)	P Value
Sex (no. of patients)				
Male	16	14	13	0.46
Female	23	29	33	
Age* (yr)	72.2 ± 5.9	72.7 ± 5.6	72.5 ± 5.0	0.70 (Group A vs. Group B) 0.79 (Group A vs. Group C) 0.89 (Group B vs. Group C)
CCD varus angulation*	14.7° ± 3.1°	13.1° ± 3.8°	18.6° ± 5.7°	0.11 (Group A vs. Group B) 0.01 (Group A vs. Group C) 0.01 (Group B vs. Group C)
ASES score*	87.2 ± 3.6	88.6 ± 3.8	82.2 ± 4.5	0.11 (Group A vs. Group B) 0.01 (Group A vs. Group C) 0.01 (Group B vs. Group C)
Complications	7.7% (3 cases)	2.3% (1 case)	10.9% (5 cases)	−0.34 (Group A vs. Group B) 0.72 (Group A vs. Group C) 0.20 (Group B vs. Group C)

*The values are given as the mean and the standard deviation at the time of the latest follow-up for patients without major complications.

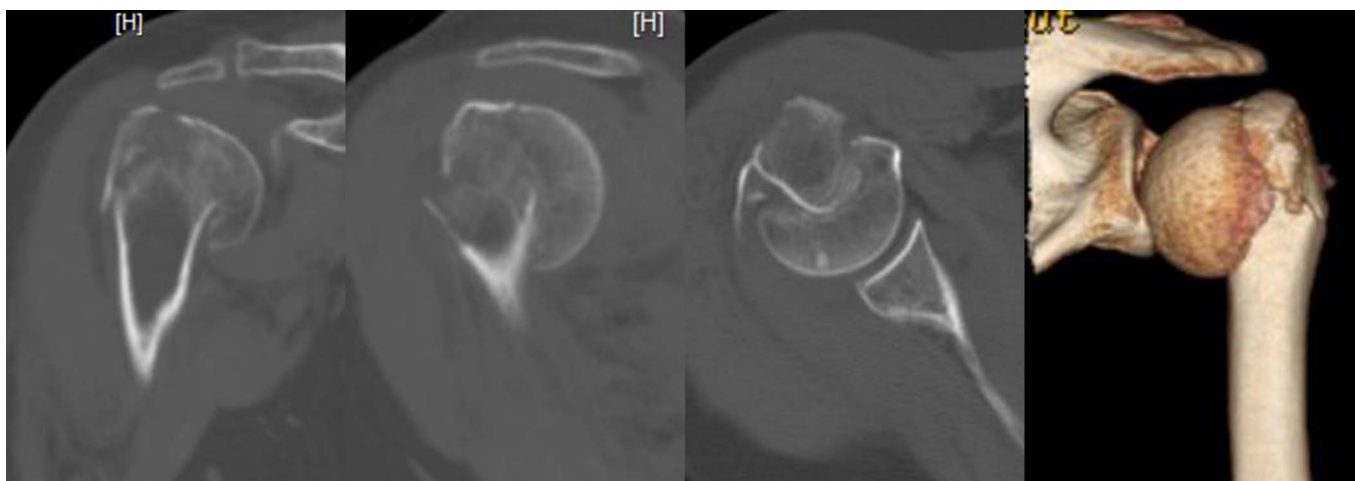


Fig. 4-A

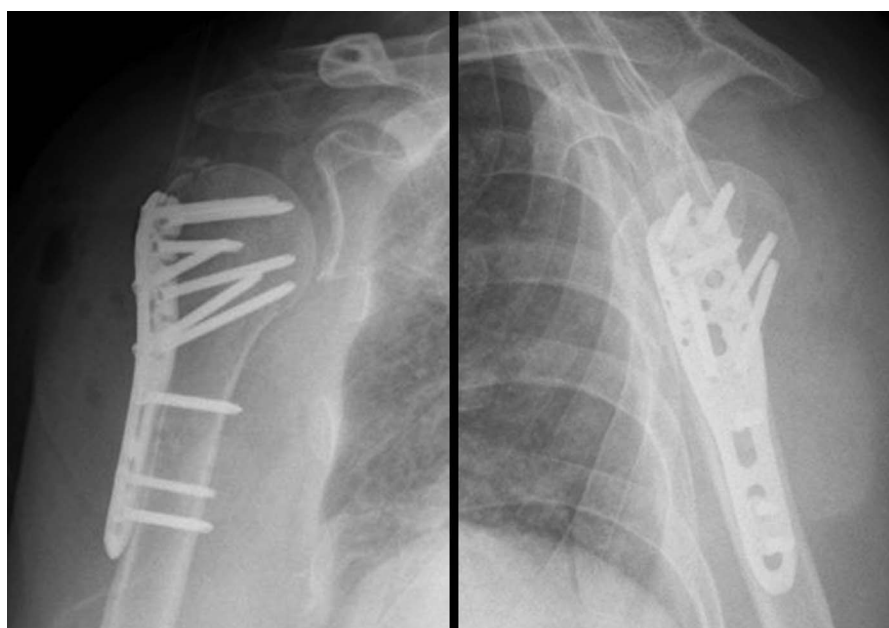


Fig. 4-B

Figs. 4-A and 4-B Case 1 (Group C). **Fig. 4-A** Preoperative computed tomographic (CT) scans and 3-dimensional (3D) CT reconstruction. **Fig. 4-B** Postoperative anteroposterior and lateral radiographs.

allowed in 6 weeks. Partial functional use, active, non-assisted motion and isometric strength were added into daily exercise according to clinical and radiological evidence of healing 6 to 12 weeks postoperatively. Manual passive motion therapy performed by a physiotherapist and isotonic strength, concentric, and eccentric exercises were added at 10 weeks postoperatively¹¹. Patients underwent regular follow-up after discharge. Arthroplasty was performed for patients who had the complications of avascular osteonecrosis of the humeral head and fixation failure.

Data Collection

Demographic data including age and sex were recorded for the 3 groups. Major complications (screw cut-out and cut-through

and osteonecrosis of the humeral head) were recorded during follow-up. Assessments were conducted at 1 year postoperatively by a trained physical therapist who was blinded to the details of the patients' treatment. The clinical parameters included the final central column diaphyseal (CCD) varus angle and the American Shoulder and Elbow Surgeons (ASES) standardized score^{12,13}. The ASES score has a patient self-evaluation section and a physician assessment section. The patient self-evaluation section contains visual analog scales for pain and instability and a questionnaire on activities of daily living. The questionnaire is marked on a 4-point ordinal scale that can be converted to a cumulative activities of daily living index. The physician assessment section includes an area to collect demographic information and assess range of motion,

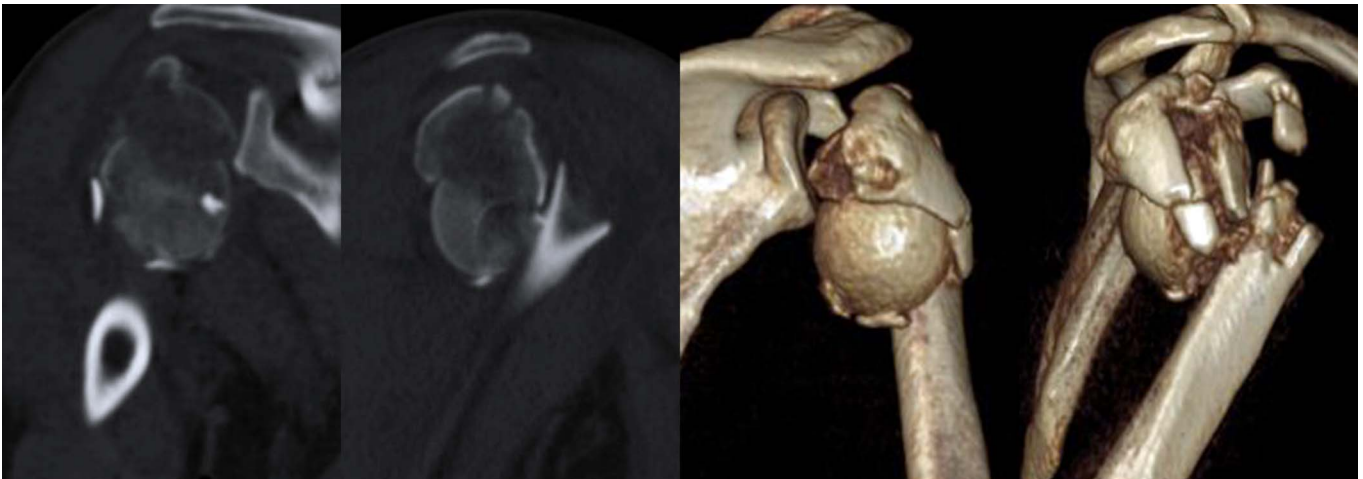


Fig. 5-A

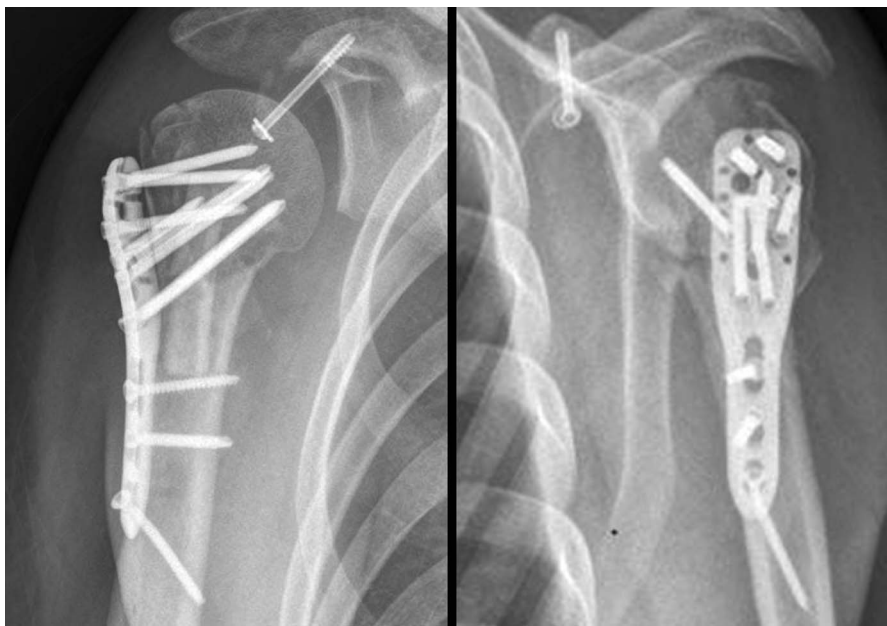


Fig. 5-B

Figs. 5-A and 5-B Case 2 (Group A). **Fig. 5-A** Preoperative CT scans and 3D CT reconstruction. **Fig. 5-B** Postoperative anteroposterior and lateral radiographs.

specific physical signs, strength, and stability. A shoulder score can be derived from the visual analog scale score for pain (50%) and the cumulative activities of daily living score (50%).

The CCD angles were measured by 2 technicians from the department of radiology with use of a picture archiving and communication system (PACS) (Kingstar Winning TWebView 2012, v6.0.0; Kingstar Winning Software). The CCD angles were calculated on the 20° external rotation anteroposterior radiograph by comparing the intersection angle of the axis of the proximal part of the humerus and the line perpendicular to the anatomical neck as described by Hertel et al.¹⁴ (Fig. 3). CCD angles were recorded immediately after surgery and 1 year after treatment, and the differences were calculated to represent the extent of final CCD varus angulation.

Statistical Analysis

Statistical analysis was performed with use of Excel 2017 Professional Plus software (Microsoft). A p value of <0.05 was considered to be significant. Data are presented as the mean and the standard deviation. The Student t test and the F test were used to compare numeric and nonnumeric variables, respectively.

Results

A total of 128 patients (85 female, 43 male) had complete follow-up (average, 19 months; range, 12 to 34 months) and functional assessment in our study. The average age was 70.5 years (range, 65 to 85 years). The right shoulder was involved in 76 patients (73 of whom were right-hand dominant).

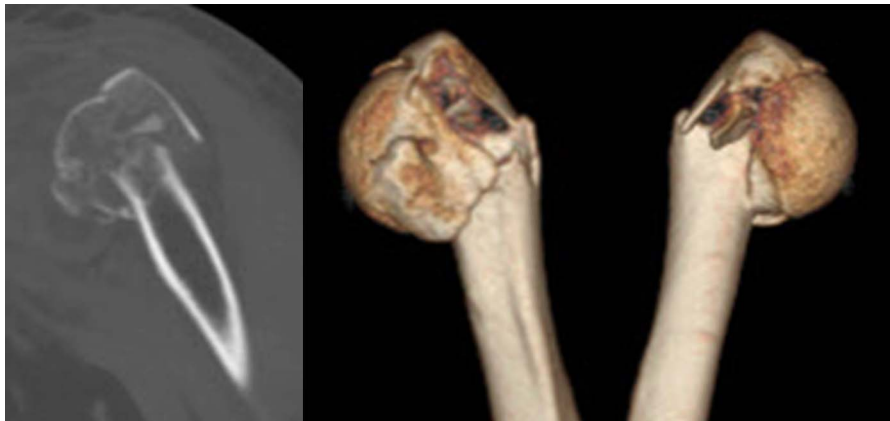


Fig. 6-A

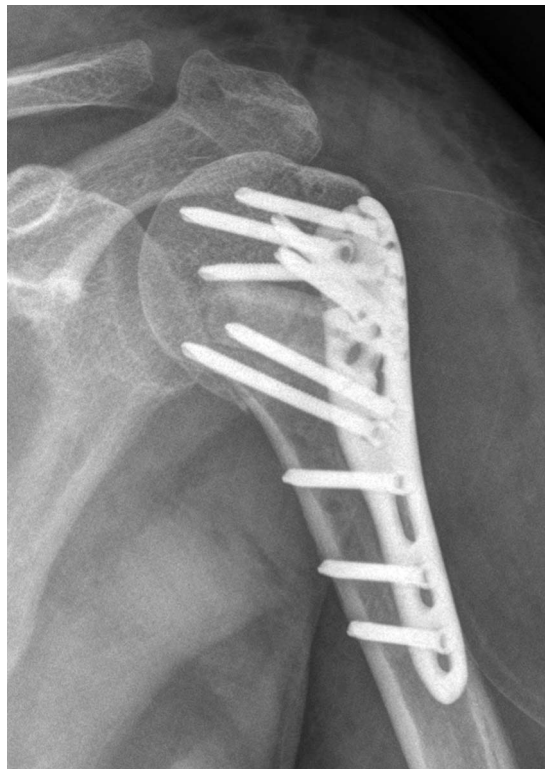

Fig. 6-B

Figs. 6-A and 6-B Case 3 (Group B). **Fig. 6-A** Preoperative CT scans and 3D CT reconstruction. **Fig. 6-B** Postoperative anteroposterior radiograph.

There were no significant differences among the 3 groups in terms of demographic characteristics.

Clinical Results

The clinical outcomes 1 year after treatment are shown in Table I. The ASES scores were evaluated for patients without major complications and showed that patients in both Group A and Group B had superior functional outcomes than patients in Group C (mean and standard deviation, 87.2 ± 3.6 in Group A, 88.6 ± 3.8 in Group B, and 82.2 ± 4.5 in Group C). The ASES scores showed significant differences between Groups A and C ($p = 0.01$) as well as between Groups B and C ($p = 0.01$) but not between Groups A and B ($p = 0.11$).

Radiographic Results

The average final CCD angle was $14.7^\circ \pm 3.1^\circ$ in Group A, $13.1^\circ \pm 3.8^\circ$ in Group B, and $18.6^\circ \pm 5.7^\circ$ in Group C. The CCD angle was significantly different between Groups A and C ($p = 0.01$) as well as between Groups B and C ($p = 0.01$) but not between Groups A and B ($p = 0.11$).

Complications

The rates of major complications in Groups A, B, and C were 7.7%, 2.3%, and 10.9%, respectively. The complications included 2 cases of osteonecrosis of the humeral head (1 in Groups A and 1 in Group C) and 7 cases of screw cut-out or cut-through (2 in Group A, 1 in Group B, and 4 in Group C). All patients who had

major complications were managed with arthroplasty. There were no cases of infection, allograft rejection, nonunion, or nerve injury during the study period.

Representative Cases

The informed consent of publishing the following radiology data and medical history was acquired from each patient.

Case 1 (Group C). A 71-year-old woman sustained a varus displaced 4-part proximal humeral fracture in a low-energy fall and was managed with open reduction and internal fixation without fibular allograft (Figs. 4-A and 4-B).

Case 2 (Group A). A 66-year-old man sustained a varus displaced 4-part proximal humeral fracture as the result of low-energy fall. The medial cortex could not be reduced intraoperatively with use of an indirect reduction push tool to reduce the medial column, and the fibular allograft was locked into place (Figs. 5-A and 5-B).

Case 3 (Group B). A 69-year-old woman sustained a varus displaced 4-part proximal humeral fracture as the result of low-energy fall. The fibular allograft was placed in the medial hinge support pattern to support the humeral head from secondary varus angulation (Figs. 6-A and 6-B).

Discussion

Most proximal humeral fractures affect elderly patients and can be treated nonoperatively with good functional outcomes¹⁵. Unstable fractures can be treated surgically¹⁶. It has been reported that unstable proximal humeral fractures account for approximately 12.6% of all proximal humeral fractures¹⁷. Locking plates, intramedullary nails, hemiarthroplasty, and reverse total shoulder replacement are common surgical options for the treatment of proximal humeral fractures^{15,18,19}.

In 2013, Gomberawalla et al. performed a meta-analysis comparing joint preservation and arthroplasty for the treatment of displaced 3 and 4-part fractures of the proximal part of the humerus²⁰. The results showed that patients in the joint-preservation groups had a significantly higher Constant score because, compared with hemiarthroplasty, joint-preservation allows tuberosity healing in an anatomical position, resulting in the restoration of rotator cuff function. Varus displaced proximal humeral fractures are the most common type of unstable proximal humeral fracture as the integrity of the medial hinge is likely to be destroyed by medial comminution²¹, which is reported to be strongly associated with loss of reduction after fixation of proximal humeral fractures²¹. In order to enhance the biomechanical stability of the medial hinge, Gardner et al. proposed the technique of applying an intramedullary fibular strut graft in combination with a locking plate¹⁰. In the present study, we showed that the use of a locking plate with fibular strut-grafting in a head-butress pattern (Group B) was associated with relatively fewer complications when compared with the use of a locking plate with fibular strut-grafting in a medial support pattern (Group A) or a locking plate alone (Group C). Although the medial cortical buttress is widely accepted to be a standard technique for open reduction and internal fixation^{22,23}, we are not aware of any biomechanical studies or high-level

clinical trials indicating that intramedullary fibular strut-grafting increases the medial buttress strength. The present study might partially support this theory as the patients who were managed with a locking plate combined with intramedullary fibular strut-grafting (Group A) had a lower rate of fixation failure and a decreased final CCD varus angle in comparison with patients who were managed with a locking plate alone (Group C). Furthermore, the present study demonstrated that the use of a locking plate combined with medial hinge support using fibular strut-grafting (Group B) had increased medial hinge biomechanical stability when compared with other methods.

In general, the functional outcomes for all patients were satisfactory, and the average ASES score in the medial hinge support group (Group B) was better than that in the locking plate alone group (Group C), indicating the functional results after proximal humeral fracture may correlate with the final CCD angle.

According to Gardner et al., the allograft will eventually remodel and incorporate into the patient's skeletal system, obviating the need for transplant removal¹⁰. The major concerns regarding the use of allograft are the limited supply, the high cost, and the risk of infection and rejection. However, we found no transplant-related complications and, given the high reoperation rates resulting from the lack of a medial buttress, the cost of allografting may be offset if the technique can reduce the rates of fixation failure and revision procedures.

The major limitation of the present study was its observational nature. The selection of treatment method was based on surgeon preference instead of being randomized. All procedures were performed by trauma specialists, and the reduction and fixation qualities were confirmed with radiographs immediately postoperatively. In addition, the baseline data of the groups were well-matched; however, further randomized controlled studies with longer follow-up are still necessary.

Conclusions

In the present retrospective study, the use of a locking plate in combination with medial strut support with use of a fibular allograft was a more stable and reliable method for the surgical correction of varus displaced proximal humeral fractures in elderly patients in comparison with the use of a locking plate alone. ■

Hongshu Wang, MD¹

Biyu Rui, PhD¹

Shengdi Lu, MD¹

Congfeng Luo, PhD¹

Yunfeng Chen, PhD¹

Yimin Chai, PhD¹

¹Department of Orthopaedics, Shanghai Jiao Tong University Affiliated Sixth People's Hospital, Shanghai, People's Republic of China

E-mail address for Y. Chai: ymchai@sjtu.edu.cn

ORCID iD for H. Wang: [0000-0002-9137-5419](https://orcid.org/0000-0002-9137-5419)

ORCID iD for B. Rui: [0000-0001-9796-1948](https://orcid.org/0000-0001-9796-1948)

ORCID iD for S. Lu: [0000-0001-5313-2902](https://orcid.org/0000-0001-5313-2902)

ORCID iD for C. Luo: [0000-0001-5876-5266](https://orcid.org/0000-0001-5876-5266)

ORCID iD for Y. Chen: [0000-0002-1612-5794](https://orcid.org/0000-0002-1612-5794)

ORCID iD for Y. Chai: [0000-0002-1972-5971](https://orcid.org/0000-0002-1972-5971)

References

1. Court-Brown CM, Garg A, McQueen MM. The epidemiology of proximal humeral fractures. *Acta Orthop Scand*. 2001 Aug;72(4):365-71.
2. Launonen AP, Lepola V, Saranko A, Flinkkilä T, Laitinen M, Mattila VM. Epidemiology of proximal humerus fractures. *Arch Osteoporos*. 2015;10:209. Epub 2015 Feb 13.
3. Hauschild O, Konrad G, Audige L, de Boer P, Lambert SM, Hertel R, Südkamp NP. Operative versus non-operative treatment for two-part surgical neck fractures of the proximal humerus. *Arch Orthop Trauma Surg*. 2013 Oct;133(10):1385-93. Epub 2013 Jul 3.
4. Olerud P, Ahrengart L, Ponzer S, Saving J, Tidermark J. Internal fixation versus nonoperative treatment of displaced 3-part proximal humeral fractures in elderly patients: a randomized controlled trial. *J Shoulder Elbow Surg*. 2011 Jul;20(5):747-55. Epub 2011 Mar 24.
5. Sanders RJ, Thissen LG, Teepen JC, van Kampen A, Jaarsma RL. Locking plate versus nonsurgical treatment for proximal humeral fractures: better midterm outcome with nonsurgical treatment. *J Shoulder Elbow Surg*. 2011 Oct;20(7):1118-24. Epub 2011 Apr 9.
6. Shulman BS, Egol KA. Open reduction internal fixation for proximal humerus fractures indications, techniques, and pitfalls. *Bull Hosp Jt Dis* (2013). 2013; 71(Suppl 2):54-9.
7. Neer CS 2nd. Displaced proximal humeral fractures. I. Classification and evaluation. *J Bone Joint Surg Am*. 1970 Sep;52(6):1077-89.
8. Wang G, Mao Z, Zhang L, Zhang L, Zhao Y, Yin P, Gao L, Tang P, Kang H. Meta-analysis of locking plate versus intramedullary nail for treatment of proximal humeral fractures. *J Orthop Surg Res*. 2015 Sep 15;10:122.
9. Walch G, Badet R, Nové-Josserand L, Levigne C. Nonunions of the surgical neck of the humerus: surgical treatment with an intramedullary bone peg, internal fixation, and cancellous bone grafting. *J Shoulder Elbow Surg*. 1996 May-Jun;5(3):161-8.
10. Gardner MJ, Boraiah S, Helfet DL, Lorich DG. Indirect medial reduction and strut support of proximal humerus fractures using an endosteal implant. *J Orthop Trauma*. 2008 Mar;22(3):195-200.
11. Buckley RE, Moran CG, Apivatthakakul T, editors. *AO principles of fracture management*. 3rd ed. Georg Thieme; 2017. p 604.
12. Richards RR, An KN, LU Bigliani, Friedman RJ, Gartsman GM, Gristina AG, Iannotti JP, Mow VC, Sidles JA, Zuckerman JD. A standardized method for the assessment of shoulder function. *J Shoulder Elbow Surg*. 1994 Nov;3(6):347-52. Epub 2009 Feb 13.
13. Piitulainen K, Paloneva J, Ylinen J, Kautiainen H, Häkkinen A. Reliability and validity of the Finnish version of the American Shoulder and Elbow Surgeons Standardized Shoulder Assessment Form, patient self-report section. *BMC Musculoskelet Disord*. 2014 Aug 11;15:272.
14. Hertel R, Knothe U, Ballmer FT. Geometry of the proximal humerus and implications for prosthetic design. *J Shoulder Elbow Surg*. 2002 Jul-Aug;11(4):331-8.
15. Maier D, Jaeger M, Izadpanah K, Strohm PC, Suedkamp NP. Proximal humeral fracture treatment in adults. *J Bone Joint Surg Am*. 2014 Feb 5;96(3):251-61.
16. Murray IR, Amin AK, White TO, Robinson CM. Proximal humeral fractures: current concepts in classification, treatment and outcomes. *J Bone Joint Surg Br*. 2011 Jan;93(1):1-11.
17. Court-Brown CM, Garg A, McQueen MM. The epidemiology of proximal humeral fractures. *Acta Orthop Scand*. 2001 Aug;72(4):365-71.
18. Zhu Y, Lu Y, Shen J, Zhang J, Jiang C. Locking intramedullary nails and locking plates in the treatment of two-part proximal humeral surgical neck fractures: a prospective randomized trial with a minimum of three years of follow-up. *J Bone Joint Surg Am*. 2011 Jan 19;93(2):159-68.
19. Mao Z, Zhang L, Zhang L, Zeng X, Chen S, Liu D, Zhou Z, Tang P. Operative versus nonoperative treatment in complex proximal humeral fractures. *Orthopedics*. 2014 May;37(5):e410-9.
20. Gomberawalla MM, Miller BS, Coale RM, Bedi A, Gagnier JJ. Meta-analysis of joint preservation versus arthroplasty for the treatment of displaced 3- and 4-part fractures of the proximal humerus. *Injury*. 2013 Nov;44(11):1532-9. Epub 2013 May 9.
21. Gardner MJ, Weil Y, Barker JU, Kelly BT, Helfet DL, Lorich DG. The importance of medial support in locked plating of proximal humerus fractures. *J Orthop Trauma*. 2007 Mar;21(3):185-91.
22. Sproul RC, Iyengar JJ, Devic Z, Feeley BT. A systematic review of locking plate fixation of proximal humerus fractures. *Injury*. 2011 Apr;42(4):408-13. Epub 2010 Dec 19.
23. Jost B, Spross C, Grehn H, Gerber C. Locking plate fixation of fractures of the proximal humerus: analysis of complications, revision strategies and outcome. *J Shoulder Elbow Surg*. 2013 Apr;22(4):542-9. Epub 2012 Sep 6.