



# Children treated for developmental dysplasia of the hip at birth and with normal acetabular index at 1 year: How many had residual dysplasia at 5 years?

Øyvind Håberg<sup>1,2</sup>, Thomas Bremnes<sup>3</sup>, Olav A Foss<sup>2,4</sup>, Oskar Angenete<sup>3,5</sup>, Øystein B Lian<sup>1,2</sup>, and Ketil J Holen<sup>2,4</sup>

## Abstract

**Purpose:** The purpose of the study was to assess the effect of further follow-up for children treated for developmental dysplasia of the hip, with normal clinical and radiological findings at 1-year time point. The effect was quantified by the number of hips with a pathologic deterioration up to 5 years.

**Methods:** Among 47,289 children born in Sør-Trøndelag county in Norway between 2003 and 2015, 265 children had developmental dysplasia of the hip. Of these, 164 children (239 hips) treated for developmental dysplasia of the hip with normal clinical findings and normal acetabular index at the 1-year time point were included in the study. The number of hips with pathologic acetabular index at the 5-year time point were reported. The diagnostic uncertainty related to radiological measurements was quantified together with the effect of introducing a second radiographic measurement, the center edge angle.

**Results:** A total of 239 treated hips were normal at the 1-year time point. At 5-year time point, 10 (4.2%) hips had a pathologic acetabular index measurement and none classified to have developmental dysplasia of the hip caused by measurement inaccuracy. Eight (3.3%) hips had pathologic center edge angle measurement. Four hips had both pathologic acetabular index and center edge angle measurements, with three later treated with surgery. The intra- and interobserver repeatability coefficients were within 3.1°–6.6°.

**Conclusion:** The repeatability coefficient of the acetabular index measurements was high and no hips could be classified to have developmental dysplasia of the hip at the 5-year time point when taking this repeatability into account. Hips classified as pathologic combining acetabular index and center edge angle measurements were likely to be treated with surgery for residual dysplasia. We recommend further follow-up for these children.

**Level of evidence:** level II.

**Keywords:** DDH, Frejka splint, long-term follow-up, acetabular index, center edge angle

## Introduction

Developmental dysplasia of the hip (DDH) represents a continuum of hip pathologies, ranging from minor dysplasia of the acetabulum to frankly dislocated hips. The majority of children with minor hip instability at birth are spontaneously normalized within the first 8 weeks.<sup>1–3</sup> Persistent dysplasia alters the hip biomechanics, leading to an overburden of the articular cartilage, which may result in early osteoarthritis. Therefore, individuals with persistent dysplasia of hips need to be identified for treatment.

In 1995, after the introduction of the selective ultrasound (US) hip screening program at our hospital, a final examination at 5 years was intended as a standard endpoint of the follow-up protocol, based on findings from a randomized

<sup>1</sup>Department of Orthopedic Surgery, Kristiansund Hospital, Kristiansund, Norway

<sup>2</sup>Institute of Neuromedicine and Movement Science, Faculty of Medicine and Health Services, NTNU, Trondheim, Norway

<sup>3</sup>Department of Radiology and Nuclear Medicine, St. Olav's Hospital, Trondheim University Hospital, Trondheim, Norway

<sup>4</sup>Department of Orthopedic Surgery, Trondheim University Hospital, Trondheim, Norway

<sup>5</sup>Institute of Circulation and Medical Imaging, Faculty of Medicine and Health Services, NTNU, Trondheim, Norway

Date Received: 13 December 2021; accepted: 28 March 2022

### Corresponding author:

Øyvind Håberg, Department of Orthopedic Surgery, Kristiansund Hospital, Herman Døhlens vei 1, N-6508 Kristiansund, Norway.  
Email: Oyvind.Haberg@helse-mr.no

controlled trial.<sup>4</sup> However, a 5-year follow-up would have been unnecessary if follow-up could be safely ended after 1 year. This change would save time, prevent parents from worrying, and prevent unnecessary exposure to radiography.

Screening children for DDH and selecting those in need of treatment can be difficult. Radiographical measurements on a continuous scale are routinely used for screening DDH. Using a threshold measurement, hips are classified as normal or having DDH. Three-dimensional objects are transformed into two-dimensional images in conventional radiography. This transformation results in loss of information along one axis, loss of depth, resulting in image distortion of the object's size and shape.<sup>5</sup> In standard pelvic radiographs, anatomical structures closer to the radiographic tube, such as the pubic symphysis, are projected with a higher magnification than structures further away, such as the sacroiliac joints. In addition, pelvic orientation affects image formation and thereby radiographic measurements. Consequently, uncertainty arises over the categorization of hips as normal or with DDH, especially when radiographic measurements are close to the threshold value. Several studies highlight the difficulties and uncertainties related to radiological measurements in detecting DDH in children younger than the age of 5 years.<sup>6–9</sup>

In this study, the main method to classify DDH was a radiographic measurement, the acetabular index (AI). AI could be measured at both 1- and 5-year time points during follow-up. In addition, a second radiographic measurement, the center edge angle (CEA), was included at the 5-year time point to explore whether a combination of AI and CEA would improve classification. Further investigations on intra- and interobserver repeatability of our measurement results were completed.

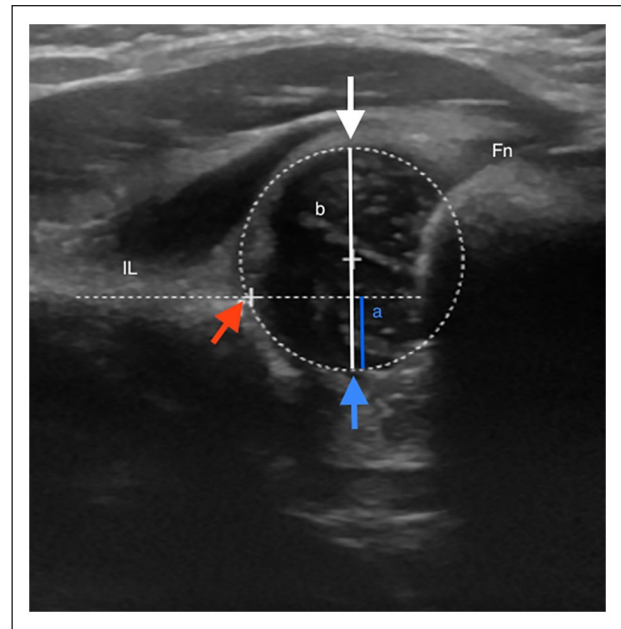
The primary aim of the study was to examine the number of hips treated for DDH at birth, with normal findings at 1 year, that had a pathologic deterioration up to 5 years. In addition, the study assessed the effect of combining AI and CEA measurements on DDH classification and the incidence of avascular necrosis (AVN).

## Materials and methods

Children treated for DDH, using a Frejka pillow, and with normal radiographic and clinical findings at the 1-year time point were included in the study, whereas children with  $AI \geq 30^\circ$  and syndromes known to have increased risk for DDH, such as arthrogyrosis, DiGeorge syndrome, Down's syndrome, Meckel–Gruber syndrome, and Klippel–Feil syndrome, were excluded.

Since 1995, data from all children who underwent US examination of the hips at our hospital have been registered in a local registry.

US findings, demographic data, sex, birth weight and length, birth presentation, gestational age, birth number, family history of DDH, foot deformity, and Ortolani and Barlow test findings were recorded in the registry. In this



**Figure 1.** Pathologic hip (classified as subluxated) examined with ultrasound the first week after birth. The dotted circle indicates the femoral head and the dotted horizontal line indicates the level of the lateral acetabular margin. Distance *a* is measured central in the femoral head from the level of the lateral acetabular margin to the acetabular floor (blue line). Distance *b* represents the diameter of the femoral head and is measured from the lateral joint capsule which equalizes the lateral part of the femoral head to the acetabular floor (white line). The femoral head coverage (FHC) is presented in %:  $(FHC = a/b \times 100 = 33\%)$ . Red arrow points at the lateral acetabular margin, blue arrow points at the acetabular floor, whereas the white arrow points at the lateral joint capsule. Fn: femoral neck; IL: os ilium.

study, data on children examined for DDH in the period 2003–2015 were extracted from this registry.

### The examinations and DDH classification at three time points

At birth (within the first 4 weeks), a child was classified to have DDH if a hip had a positive Ortolani or Barlow test and an US finding of femoral head coverage (FHC) below 50% (Figure 1). All these children underwent treatment. In addition, 65 hips with an FHC below 50% were clinically stable. A total of 58 were treated, whereas the last 7 hips were found to be normal at a later follow-up.

At 1-year time point, the child was examined for asymmetry of the skin folds, grades of abduction and rotation of the hip, and limb length. Hips with normal clinical findings and  $AI < 30^\circ$  were classified as normal.

At 5-year time point, the child was examined for limping gait, side differences in hip abduction, rotation, and limb length. Hips with normal clinical findings and  $AI < 24^\circ$  were classified as normal.

### The US examination

The primary US examination was performed within the first 3 days after birth. For the examinations, Siemens Antares (Siemens AG, Munich, Germany) with an 8–16 MHz linear probe was used. Since 2007, GE Logic 7 (GE Healthcare, Milwaukee, WI, USA) has been used with the same type of probe. Measurement of the FHC is demonstrated in Figures 1 and 2. The US method is described in detail in a previous paper.<sup>10</sup> FHC is an expression of hip containment. All treated children were monitored with US. We classified the hips as normal (FHC > 50%), sublaxatable (FHC 40%–49%), sublaxated (FHC 30%–39%), and luxated (FHC < 30%).

### Radiological examination

A standard anterior–posterior pelvic radiography was obtained at 1- and 5-year time points. To ensure that radiographs were comparable, children with no radiographs from the 1-year time point when aged 9–18 months and those with radiographs from the 5-year time point before turning the age of 4 years were excluded. To identify radiographs obtained with the child in a non-optimal positioning, the obturator index (OI) was defined. An OI between 0.56 and 1.80 was considered best suited for further examination.<sup>11</sup> However, to replicate clinical practice, no hips were excluded based on OI; instead, the OI was described after the results were presented.

To calculate intra- and interobserver repeatability, 35 children were randomly selected after 1- and 5-year time points each for re-examination of the radiographs. The radiographs were re-examined for AI after 1 year and for AI and CEA after 5 years, first by the same radiologist, to calculate intraobserver repeatability, and second by another senior consultant in radiology, blinded to previous descriptions, to calculate interobserver repeatability.<sup>12,13</sup>

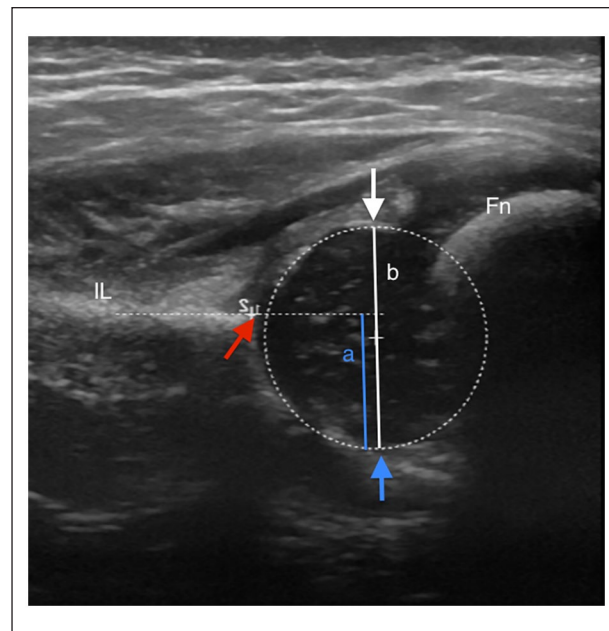
The primary radiological measurement at 1- and 5-year time points was AI. The AI is the angle between the junction of the Hilgenreiner line and a line to the lateral bony corner of the acetabulum (Figures 3 and 4). The CEA, first described by Wiberg, is a measure of the bony coverage of the femoral head by the acetabulum (Figure 5).<sup>14</sup> The lateral bony corner of the acetabulum was used during the measurement of this angle.

To investigate the additional effect of the combined use of CEA and AI, a CEA < 15° was considered pathologic.

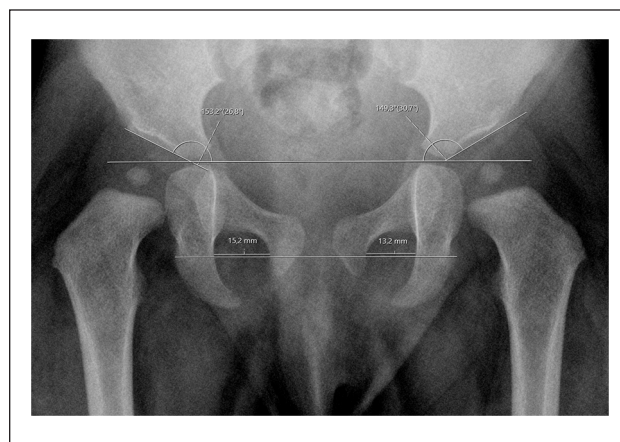
To evaluate the development of AVN at 1- and 5-year time points, we used the Bucholz classification.<sup>15</sup>

### Statistical analysis

Statistical analyses were performed using IBM SPSS Statistics for Windows, version 27 (IBM Corp., Armonk, NY, USA). Descriptive statistics were used; continuous

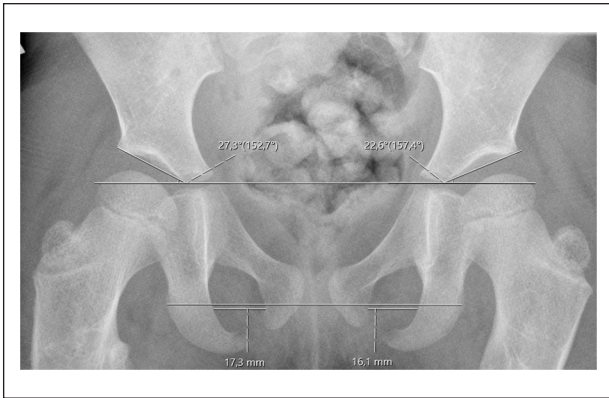


**Figure 2.** Normal hip examined with ultrasound the first week after birth. The dotted circle indicates the femoral head and the dotted horizontal line indicates the level of the lateral acetabular margin. The landmarks and measurements are as described in Figure 1. The femoral head coverage (FHC) is presented in %: (FHC =  $a/b \times 100 = 61\%$ ). Fn: femoral neck; IL: os ilium.

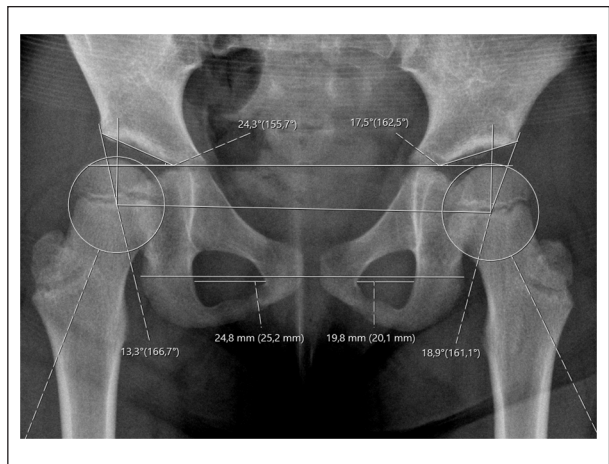


**Figure 3.** Pelvis at 1 year. There is a normal acetabular index of 26.8° in the right hip and a pathologic acetabular index of 30.7° in the left hip. The obturator index of 0.87 (13.2/15.2).

data are presented as means, standard deviation (SD), and ranges (min–max); and categorical data are presented as frequencies and percentages (%). Intra- and interobserver repeatability were calculated using the method described by Bland and Altman.<sup>12</sup> The repeatability coefficient was defined as 2 SDs of the mean difference between two corresponding measurements and the 95% limits of agreement (LoA) between the mean  $\pm$  2 SD.



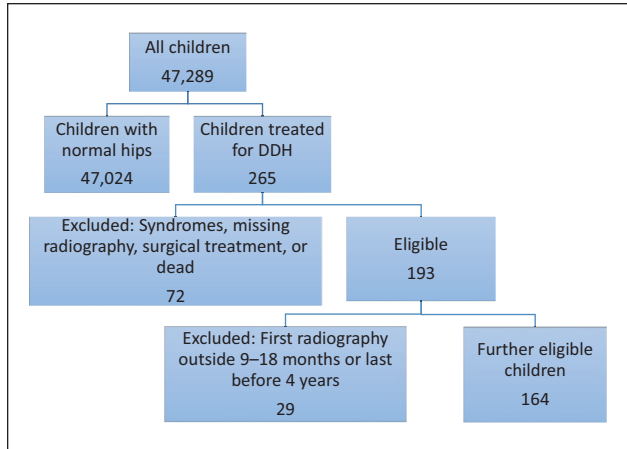
**Figure 4.** Pelvis at 5 years. There is a pathologic acetabular index of 27.3° in the right hip and a normal acetabular index of 22.6° in the left hip. The obturator index of 0.93 (16.1/17.3).



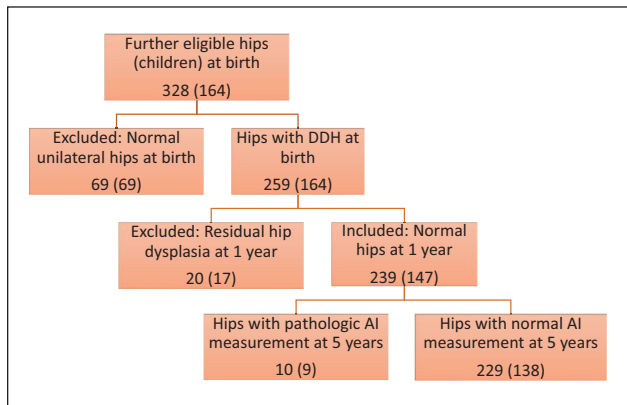
**Figure 5.** Pelvis at 5 years. There is a pathologic center edge angle of 13.3° in the right hip and a normal center edge angle of 18.9° in the left hip. Acetabular index of 24.3° in the right hip and 17.5° in the left hip. The obturator index of 1.3 (24.8/19.8).

**Results**

Between 2003 and 2015, 47,289 children were born at our hospital (Figure 6). At birth, 265 (0.6%) children were diagnosed and treated for DDH. Of these, 72 children were considered not eligible for inclusion in this study, due to syndromes known to have increased risk for DDH, missing radiographs, or prolonged treatment or death. Of 193 children considered eligible, 29 children were excluded because radiography was performed outside the predetermined time interval. Of the remaining 164 children, 95 children had bilateral DDH and 69 had unilateral DDH. The healthy hips of these 69 children were excluded, leaving 259 hips with DDH (Figure 7). Eighteen of these hips had FHC > 50% and were treated due to a positive Ortolani and Barlow test. Twenty of the children had residual dysplasia after 1 year and were excluded. When calculating



**Figure 6.** Flowchart of children.



**Figure 7.** Flowchart of hips (children).

the incidence of AVN, both hips of the 69 children with unilateral DDH were included.

**Included hips (children)**

At 1-year time point, 239 hips (147 children) were classified as normal and included in the study. Twenty-nine (12%) and 210 (88%) of the hips were present in boys and girls, respectively. The mean treatment time with the Frejka pillow was 3.8 (0.5; 2–4) months. Seven hips had radiographs with an OI outside the best reference interval. The mean AI measurement was 24.1° (3.3; 13.9°–30.0°). The mean age was 13.0 (1.3; 9.5–17.5) months.

At the 5-year time point, the mean age was 62 (4.8; 49.0–85.5) months. All radiographs had an OI within the best reference interval.

**Repeatability coefficient**

The intraobserver repeatability coefficient was 3.1° for AI at the 1-year time point, 4.4° for AI at the 5-year time point, and 3.9° for CEA at the 5-year time point.

**Table 1.** Hips (children) with pathologic AI at 5-year time point.

Child	1	2	3 right	3 left	4	5	6	7	8	9
Femoral head coverage, %	46	28	35	34	39	35	35	41	47	35
AI at 1 year (95% LoA)	27 (23.9–30.1)	29 (25.9–32.1)	25 (21.9–28.1)	26 (22.9–29.1)	23 (19.9–26.1)	30 (26.9–33.1)	22 (18.9–25.1)	27 (23.9–30.1)	28 (24.9–31.1)	27 (23.9–30.1)
AI at 5 years (95% LoA)	26 (21.6–30.4)	26 (21.6–30.4)	24 (19.6–28.4)	26 (21.6–30.4)	25 (20.6–29.4)	26 (21.6–30.4)	26 (21.6–30.4)	24 (19.6–28.4)	26 (21.6–30.4)	25 (20.6–29.4)
Center edge angle at 5 years (95% LoA)	20 (16.1–23.9)	20 (16.1–23.9)	10 (6.1–13.9)	11 (7.1–14.9)	21 (17.1–24.9)	16 (12.1–19.9)	16 (12.1–19.9)	21 (17.1–24.9)	15 (11.1–18.9)	15 (11.1–18.9)
Surgery (age, years)	–	–	+ (10)	+ (10)	–	–	–	–	+ (8)	–

Hips with AI  $\geq 24^\circ$  were considered as pathologic. In addition, hips with CEA  $< 15^\circ$  were considered pathologic. AI: acetabular index; CEA: center edge angle; LoA: limits of agreement.

The interobserver repeatability coefficient was  $4.1^\circ$  for AI at the 1-year time point,  $6.6^\circ$  for AI at the 5-year time point, and  $5.6^\circ$  for CEA at the 5-year time point.

### AI results at 5-year time point

The mean AI measurement was  $17.5^\circ$  (3.6;  $8.3^\circ$ – $26.3^\circ$ ) and classified as normal in 229 hips.

The AI was pathologic in 10 hips (9 children). No AI measurements were outside the LoA (Table 1). When examining the medical records of these 10 hips, 6 hips (6 children) had no additional treatment for DDH and follow-up was later ended. Of the 10 hips, 1 is still under follow-up. In one hip, a proximal derotating and varus femoral osteotomy was performed at the age of 8 years. The last child underwent further follow-up and was operated at the age of 10 years with a bilateral proximal femur and Dega osteotomy of the pelvis.

### CEA results at 5-year time point

The mean CEA was  $23.8^\circ$  (4.8;  $9.1^\circ$ – $38.1^\circ$ ). The CEA was classified as pathologic in eight hips (six children). Three of the eight hips had CEA measurements outside LoA. Four of these hips are presented in Table 1.

The remaining four had the following CEA:  $9^\circ$ ,  $12^\circ$ ,  $13^\circ$ , and  $15^\circ$ . These four hips were followed up and were later normalized.

### The combination of AI and CEA results at 5-year time point

Of the 10 hips with pathologic AI measurement, four hips (three children) had pathologic CEA measurement. Of these four hips, three hips were later operated due to DDH and one hip is still under follow-up. The three children were all girls with no further apparent similarities.

In contrast, none of the hips with pathologic CEA and a normal AI measurement are operated. The hips found to be normal at follow-ups.

### Avascular necrosis

No children had signs of AVN on radiography at the 1-year time point. At 5 years, 4 of the 328 hips (Figure 7) had stage 1 AVN. None of these children had any symptoms of AVN and follow-up was ended because no symptoms and progression were identified on radiography.

### Discussion

The primary aim of the study was to examine the number of hips treated for DDH at birth, with normal findings at 1 year, that had a pathologic deterioration up to 5 years. At 5 years, 10 hips had a pathological AI measurement. However, none could be classified to have DDH caused by measurement inaccuracy.

In our region, a steady number of children ( $< 1\%$ ) are treated for DDH. The treatment rate in this study after selective US screening was 0.6% of all children, which is consistent with findings from other studies that conducted selective or universal screening programs.<sup>16,17</sup>

Nevertheless, a continuous need exists to focus on diagnosis and follow-up of DDH because no specific guidelines on the length of follow-up of children with DDH have been established.

Timing of the US examination has changed significantly during the last 10–15 years. To minimize the number of false-positive cases after US screening, the US examinations are now recommended at around 4 weeks after birth, even if this might be more demanding logistically.<sup>18</sup> In this study, with the initial US examination performed within 1–3 days after birth, we found 65 clinically stable hips with an FHC below 50% and 58 of these hips were treated. The remaining seven hips were untreated and were later found to be normal at further follow-up. Probably most of these 65 hips would have developed into normality without treatment.<sup>2,3</sup> As a consequence, we have now postponed the first US examination from 1–3 days after birth to 4–6 weeks.

Several US classifications exist for DDH. Often used is the Graf method, measuring angles, in contrast to the

FHC method measuring distances. However, the landmarks for the measurements are quite similar. At our hospital, we have measured the FHC for many years and are confident with this method. Graf has developed a classification and stratification system, which might be the cause for the widespread use of the Graf method. The FHC classification is simpler, but not so consistent concerning the stratification. Unfortunately, we have no possibility to change the US measurements into the Graf method in this study.<sup>19</sup>

Broadhurst et al.<sup>20</sup> found no reduction in the incidence of lately detected DDH in England over the last 35 years. Wright et al.<sup>21</sup> found that 70% of respondents in a UK survey reported a yearly follow-up of children with DDH until skeletal maturity. Conversely, Allington<sup>22</sup> found that follow-up could be ended if radiologic findings at the age of 2 years were normal in a selected group of otherwise normal children. Cashman et al.<sup>23</sup> found that successfully treated hips developed normal AI values after the age of at least 18 months. In addition, they found that, for dysplastic hips with successful reduction using the Pavlik harness, 2.4% had persistent dysplasia and 0.2% had persistent severe late dysplasia. They all had a CEA  $<20^\circ$  at the 5-year time point. Most treated children will develop normally during the first 12–18 months, but some children will deteriorate until the age of 5 years. These results are similar to our findings.

Modaressi et al.<sup>24</sup> presented results after long-term follow-up (until skeletal maturity) of 150 children treated for DDH with normal clinical and radiological findings at the age when they began to walk. A final examination was performed at the mean age of 11.8 (10–16) years. At the end of follow-up, four children had residual hip dysplasia or acetabular retroversion. Two children each underwent surgery when they were fully mature skeletally. This study had similar characteristics as our study; both had similar number of participants and similar clinical and radiological findings on children at the age of 1 year. However, Modaressi et al.<sup>24</sup> described pathological development in puberty, whereas our study found radiologic–pathological development within the first 5 years of life. None of our study's participants underwent surgery at the 5-year time point, but two children (three hips) underwent surgery at the ages of 8 and 10 years, after further follow-up showed deterioration into residual dysplasia. One child is still being followed up.

Some decades ago, Wynne-Davies and later Haasbeek suggested that late development of hip dysplasia could be a different entity from early DDH, probably due to genetic predispositions.<sup>25,26</sup> Recently, new data on genetic predisposition to DDH have been reported and sequencing techniques for genetic analysis may improve our understanding of DDH genetics in the future.<sup>27</sup>

Based on evidence from other studies, AI was used as the main measurement tool at the 1- and 5-year time points.<sup>28,29</sup> Shin et al.<sup>28</sup> compared the use of the lateral sourcil and lateral osseous margin in measuring the AI and CEA in children with DDH and found the lateral osseous margin to have a better reliability than the acetabular sourcil. Li et al.<sup>29</sup> found the AI to be the best predictor of late residual dysplasia. Several other studies have reported use of AI as the primary measurement tool during follow-up.<sup>30</sup> Kothari et al.<sup>31</sup> described the use of the AI and compared the use of the lateral bony margin with the use of the lateral sourcil in calculating the AI; they concluded that these two methods of measuring the AI could not be used interchangeably. Tönnis and Brunken<sup>11</sup> reported the normal AI values at the 1- and 5-year time points. In addition, Tönnis<sup>32</sup> described the upper SD as the borderline between normal and pathologic hips and values above 2 SDs as indicative of severe hip dysplasia. Based on these reports,  $30^\circ$  and  $24^\circ$  were used as cut-off AI values at the ages of 1 and 5 years, respectively. Hips with larger values were defined as pathologic. In this study, we used the lateral bony margin as the landmark, following Tönnis and Brunken.<sup>11</sup>

Hip joints were classified as normal or pathologic based on a threshold value of a continuous angle measurement on radiographs. The uncertainty associated with the measurements was quantified, which affected the threshold value. Of the 239 hips with normal clinical and radiological findings at the 1-year time point, 10 (4.2%) were considered pathologic based on AI measured at the 5-year time point. However, the highest AI measured was only  $26^\circ$ . Concurrently, the corresponding intraobserver repeatability coefficient was  $4.4^\circ$ . Combined with the corresponding repeatability coefficient, none of the hips could be categorized as pathologic with 95% confidence.

The repeatability coefficient of the measurements of AI and CEA was high, leading to uncertainty in measuring borderline cases. However, the results are consistent with those reported by other studies.<sup>6–9</sup> Broughton et al.<sup>6</sup> reported the 95% confidence interval of AI to be  $\pm 6^\circ$  and Kay et al.<sup>7</sup> reported it to be  $>8.35^\circ$ . Both research groups highlighted the need to take several readings when measuring the AI because single measurements can be unreliable. Ömeroglu et al.<sup>13</sup> observed intra- and interobserver variability in the CEA at the same level as observed in our study; therefore, our results may be comparable. Upasani et al.<sup>33</sup> studied the intra- and interobserver reliability in measuring AI and CEA and focused on the difficulties in measuring a three-dimensional pelvis on a radiographic frontal plane. They questioned the reliability and reproducibility of these measurements in children younger than the age of

3 years. Based on our findings, using AI alone could cause uncertainty in the classification of DDH due to the high repeatability coefficient.

CEA was measured at the 5-year time point. As ossification of the femoral head increases at the age of 5 years, we find this angle to be important when examining for residual dysplasia. Therefore, repeatable diagnostic results and differences were examined using AI or CEA. Overall, eight hips had a  $CEA \leq 15^\circ$ . With the corresponding intra-observer repeatability coefficient at  $3.9^\circ$ , three of the eight hips could be categorized as pathologic with 95% confidence (outside LoA).

Four hips in three children had a pathologic AI and CEA at the 5-year time point and three of those needed surgery for residual dysplasia, and the fourth hip is still under follow-up. When combining the AI and CEA, hips with both measurements categorized as pathologic are likely to be treated with surgery. This highlights the complexity of DDH.

No hips had AVN at 1-year time point and four hips at 5-year time point after treatment with Frejka pillow. This finding was comparable with the other studies.<sup>34</sup>

This study was retrospective with prospective recorded data. This could lead to some limitations due to potential missing data and variations in follow-up procedures. For the untreated children, we do not know the number of late development of hip dysplasia. However, the 1- and 5-year time points were standardized with few missing data. All children requiring surgery for DDH in the region were treated at our hospital.

In conclusion, of 239 hips classified as normal at 1-year time point, three were later treated with surgery after the 5-year time point. At our hospital, we will continue follow-up of these children after 1 year.

At the 5-year time point, no hips could be classified to have residual dysplasia using AI measurement alone. However, hips classified as pathologic based on both AI and CEA measurements were those likely to be later treated with surgery. We therefore recommend further follow-up for these children.

### Acknowledgments

A special thanks to the late Dr. Ole Jacob Johansen, the pediatrician who performed most of the clinical examinations. Thanks to Dr. Helge Rønningen, Dr. Torarin Lamvik, and Dr. Lars Fosse for conducting some ultrasound examinations. We also thank Myrhle Slettvåg Hoel for her work with the Local Registry for Children with DDH.

### Author contributions

Ø. Håberg: Collecting of data, writing of the manuscript.  
T. Bremnes: Radiologic measurements, writing of the manuscript.  
O.A. Foss: Supervision, statistical analysis, writing of the manuscript.  
O. Angenete: Radiologic measurements, writing of the manuscript.  
Ø.B. Lian: Supervision, writing of the manuscript.

K.J. Holen: Supervision, statistical analysis, writing of the manuscript.

### Declaration of conflicting interests

The author(s) declared no potential conflicts of interest with respect to the research, authorship, and/or publication of this article.

### Funding

The author(s) disclosed receipt of the following financial support for the research, authorship, and/or publication of this article: The corresponding author has a PhD scholarship from Helse Møre og Romsdal Hospital trust, Norway.

### Ethical approval

The Regional Committee for Medical Health Research Ethics in Norway has approved the study 2016/1159.

### Informed consent

The children and parents provided written informed consent. They were at liberty to refrain from participating in the study.

### References

1. Barlow T. Early diagnosis and treatment of congenital dislocation of the hip. *Bone Joint J* 1962; 44(2): 292–301.
2. Holen K, Tegnander A, Eik-Nes S, et al. The use of ultrasound in determining the initiation of treatment in instability of the hip in neonates. *J Bone Joint Surg Br* 1999; 81(5): 846–851.
3. Lussier EC, Sun YT, Chen HW, et al. Ultrasound screening for developmental dysplasia of the hip after 4 weeks increases exam accuracy and decreases follow-up visits. *Pediatr Neonatol* 2019; 60(3): 270–277.
4. Holen KJ, Tegnander A, Bredland T, et al. Universal or selective screening of the neonatal hip using ultrasound? A prospective, randomised trial of 15,529 newborn infants. *J Bone Joint Surg Br* 2002; 84(6): 886–890.
5. Carlton RR and Adler AM. *Principles of radiographic imaging*. Clifton Park, NY: Cengage Learning, 2012.
6. Broughton NS, Brougham DI, Cole WG, et al. Reliability of radiological measurements in the assessment of the child's hip. *J Bone Joint Surg Br* 1989; 71(1): 6–8.
7. Kay RM, Watts HG and Dorey FJ. Variability in the assessment of acetabular index. *J Pediatr Orthop* 1997; 17(2): 170–173.
8. Portinaro NM, Murray DW, Bhullar TP, et al. Errors in measurement of acetabular index. *J Pediatr Orthop* 1995; 15(6): 780–784.
9. Spatz DK, Reiger M, Klaumann M, et al. Measurement of acetabular index intraobserver and interobserver variation. *J Pediatr Orthop* 1997; 17(2): 174–175.
10. Holen KJ, Terjesen T, Tegnander A, et al. Ultrasound screening for hip dysplasia in newborns. *J Pediatr Orthop* 1994; 14(5): 667–673.
11. Tönnis D and Brunken D. Eine Abgrenzung normaler und pathologischer Hüftpfannendachwinkel zur Diagnose der Hüftdysplasie. *Archiv Für Orthopädische Und Unfall-chirurgie, Mit Besonderer Berücksichtigung Der*

- Frakturenlehre Und Der Orthopädisch-chirurgischen Technik* 1968; 64(3): 197–228.
12. Bland JM and Altman D. Statistical methods for assessing agreement between two methods of clinical measurement. *Lancet* 1986; 327(8476): 307–310.
  13. Ömeroglu H, Biçimoglu A, Ağuş H, et al. Measurement of center-edge angle in developmental dysplasia of the hip: a comparison of two methods in patients under 20 years of age. *Skeletal Radiol* 2002; 31(1): 25–29.
  14. Wiberg G. Studies on dysplastic acetabula and congenital subluxation of the hip joint. *Acta Chir Scand* 1939; 83(58): 1.
  15. Buchholz RW and Ogden J (ed.). Patterns of ischemic necrosis of the proximal femur in nonoperatively treated congenital hip disease. In: *The hip proceedings of the sixth open scientific meeting of the hip society*, CV Mosby, St. Louis, MO, 1978.
  16. Biedermann R, Riccabona J, Giesinger JM, et al. Results of universal ultrasound screening for developmental dysplasia of the hip: a prospective follow-up of 28 092 consecutive infants. *Bone Joint J* 2018; 100-B(10): 1399–1404.
  17. Pollet V, Percy V and Prior HJ. Relative risk and incidence for developmental dysplasia of the hip. *J Pediatr* 2017; 181: 202–207.
  18. Tan SHS, Wong KL, Lim AKS, et al. The earliest timing of ultrasound in screening for developmental dysplasia of the hips. *Ultrasonography* 2019; 38(4): 321–326.
  19. Graf R. Ultrasound examination of the hip. An update. *Der Orthopade* 2002; 31(2): 181–189.
  20. Broadhurst C, Rhodes AML, Harper P, et al. What is the incidence of late detection of developmental dysplasia of the hip in England? A 26-year national study of children diagnosed after the age of one. *Bone Joint J* 2019; 101-B(3): 281–287.
  21. Wright J, Tudor F, Luff T, et al. Surveillance after treatment of children with developmental dysplasia of the hip: current UK practice and the proposed Stanmore protocol. *J Pediatr Orthop B* 2013; 22(6): 509–515.
  22. Allington NJ. Successful Pavlik harness treatment for developmental dysplasia of the hip and normal X-Ray at the age of 2 years: is a longer follow-up necessary? *J Pediatr Orthop* 2017; 37: 328–331.
  23. Cashman JP, Round J, Taylor G, et al. The natural history of developmental dysplasia of the hip after early supervised treatment in the Pavlik harness. *J Bone Joint Surg Br* 2002; 84(3): 418–425.
  24. Modaresi K, Erschbamer M and Exner GU. Dysplasia of the hip in adolescent patients successfully treated for developmental dysplasia of the hip. *J Child Orthop* 2011; 5(4): 261–266.
  25. Wynne-Davies R. Acetabular dysplasia and familial joint laxity: two etiological factors in congenital dislocation of the hip: a review of 589 patients and their families. *J Bone Joint Surg Br* 1970; 52(4): 704–716.
  26. Haasbeek JF, Wright JG and Hedden DM. Is there a difference between the epidemiologic characteristics of hip dislocation diagnosed early and late. *Can J Surg* 1995; 38(5): 437–438.
  27. Harsanyi S, Zamborsky R, Krajciová L, et al. Association analysis of GDF5 and contributing factors in developmental dysplasia of the hip in infants. *Ortop Traumatol Rehabil* 2021; 23(5): 335–339.
  28. Shin CH, Yang E, Lim C, et al. Which acetabular landmarks are the most useful for measuring the acetabular index and center-edge angle in developmental dysplasia of the hip? A comparison of two methods. *Clin Orthop Relat Res* 2020; 478(9): 2120–2131.
  29. Li Y, Guo Y, Li M, et al. Acetabular index is the best predictor of late residual acetabular dysplasia after closed reduction in developmental dysplasia of the hip. *Int Orthop* 2018; 42(3): 631–640.
  30. Osarumwense D, Popple D, Kershaw IF, et al. What follow-up is required for children with a family history of developmental dysplasia of the hip. *J Pediatr Orthop B* 2007; 16(6): 399–402.
  31. Kothari A, Noor S, Maddock CL, et al. The lateral edge and sourcil acetabular indices for surgical decision-making in developmental dysplasia of the hip. *J Child Orthop* 2020; 14(6): 513–520.
  32. Tönnis D. Normal values of the hip joint for the evaluation of X-rays in children and adults. *Clin Orthop Relat Res* 1976(119): 39–47.
  33. Upasani VV, Bomar JD, Parikh G, et al. Reliability of plain radiographic parameters for developmental dysplasia of the hip in children. *J Child Orthop* 2012; 6(3): 173–176.
  34. Ashoor M, Abdulla N, Elgabaly EA, et al. Evidence based treatment for developmental dysplasia of the hip in children under 6 months of age. *Surgeon* 2021; 19(2): 77–86.