

Single Case

Netherton's Syndrome: A Case of Two Male Siblings Diagnosed in Adulthood

Akshay Flora^a Annika Smith^b

^aDiscipline of Medicine, The Central Clinical School, The Faculty of Medicine and Health, University of Sydney, Sydney, NSW, Australia; ^bDepartment of Dermatology, Westmead Hospital, Sydney, NSW, Australia

Keywords

Netherton's syndrome · Congenital ichthyosiform erythroderma · Trichorrhexis invaginata · Psoriasis · Ichthyosis linearis circumflexa

Abstract

Netherton's syndrome (NS) is a rare autosomal recessive genetic disease caused by a germline mutation in the SPINK5 gene. It is most commonly diagnosed in neonates due to the presence of congenital ichthyosiform erythroderma. Affected individuals will typically also develop a hair shaft abnormality known as trichorrhexis invaginata, severe atopy, and a migratory rash known as ichthyosis linearis circumflexa. The chronicity and severity of NS adversely affects a patient's quality of life to a large extent. It is therefore important that this condition is identified early, and treatment to reduce cutaneous inflammation is initiated in a timely fashion. However, due to this condition being relatively rare, a lack of awareness may lead clinicians to misdiagnose it as atopic dermatitis or undifferentiated psoriasis. Clinicians should therefore be aware of the peripheral stigmata that this disease may present as in adulthood, so that a correct diagnosis can be made if it was previously missed. Here we present a case of two male siblings from Jordon who were misdiagnosed since childhood as having erythrodermic psoriasis. Clinical examination of one of the siblings, as an adult, revealed multiple peripheral features associated with NS. Genetic analysis through sanger sequencing was also able to identify a mutation in the SPINK5 gene, confirming the diagnosis.

© 2020 The Author(s)
Published by S. Karger AG, Basel

Introduction

Netherton's syndrome (NS) is a rare autosomal recessive genodermatosis caused by a germline mutation in the SPINK5 gene located on chromosome 5q32 [1]. SPINK5 normally plays a critical role in optimising skin barrier function and regulating desquamation of keratinocytes [1]. Clinically, the three main features of this syndrome include congenital ichthyosiform erythroderma, a hair shaft abnormality known as trichorrhexis invaginata (TI), and severe atopy.

The phenotype of NS is variable. The first manifestation of this syndrome is typically in the neonatal period, where erythroderma and sparse hair is present. These neonates are at a serious risk of mortality from dehydration, hypothermia, and sepsis. Individuals that survive the neonatal period often have improvement of their symptoms over time, although some individuals have persisting generalised erythroderma that is present throughout adulthood [2]. NS that is inadequately treated may have a significant impact on an individual's quality of life.

This report describes a case of two male siblings who experienced persisting widespread erythroderma since birth, but only received a formal diagnosis of NS during adulthood.

Case Report

A 39-year-old male of Israeli origin presented to a psoriasis clinic in Sydney with erythroderma. The patient recently migrated from Jordan 3 months prior, where he grew up with an older brother (aged 42) who he noted had similar cutaneous features to him. The parents of both siblings were of a consanguineous relationship.

Our patient reports having had this condition since birth; he and his brother were born with erythroderma and failure to thrive. During childhood, he experienced periodic worsening of his skin condition, which was labelled as "psoriasis," and slow growing hair that was sparse. He also noticed that he would develop significant skin inflammation in response to eating certain foods, although he denied anaphylaxis. Despite the severity of his clinical presentation at the time, he was told by doctors that he had a rare form of psoriasis and was given topical steroid creams that provided minimal relief to his symptoms. The resulting physical appearance and chronicity of the condition has led to significant impacts on the patient's social and psychological functioning.

Examination revealed a gentleman short in stature with widespread erythema and scale involving the trunk, limbs and face. Of note, the quality of the scale was different on the proximal thighs, where it was double edged and circumferential, constituting ichthyosis linearis circumflex (ILC) clinically (Fig. 1). The patient's scalp hair was sparse in the crown region, as well as being dry and stiff. Trichoscopy demonstrated TI with a bamboo-like appearance of the hair shaft which was confirmed with formal hair microscopy (Fig. 2).

Laboratory investigations revealed an elevated IgE level of 775 IU/mL (reference range 0–100 IU/mL), suggesting an atopic predisposition. Serum immunoglobulin levels of IgG, IgA and IgM were within reference range, and radioallergosorbent testing to seafood and staple food mix was negative. A 4-mm punch biopsy of the right thigh demonstrated epidermal acanthosis, patchy parakeratosis, hypergranulosis and agranulosis, and focal occasional intraepidermal lymphocytic infiltrate. The papillary dermis contained dilated vessels, and a mild perivascular lymphocytic infiltrate. Genetic analysis through sanger sequencing identified a mutation in the SPINK5 gene.

Intensification of topical steroid therapy was instituted in the form of betamethasone dipropionate 0.05% ointment, emollient and wet wrap technique. Discussion of systemic therapy took place with the decision to commence low-dose oral acitretin. Soon after review, the patient indicated his intention to return to Jordan unexpectedly where he would pursue ongoing dermatologic care.

Discussion

The clinical appearance and severity of NS often varies with age. During the neonatal period, congenital ichthyosiform erythroderma and atopic manifestations are most prominent. The erythroderma has variations in erythema and scale [3]. After the first year of life, some infants develop TI of the hair shaft, which has a bamboo-like appearance that is best appreciated on trichoscopy [3]. This sign is considered highly specific for NS but is not always present.

Throughout adolescence and adulthood, some individuals have persistence of erythroderma, whilst others develop ILC. ILC has a serpiginous appearance with migratory scaling plaques that have double-edged scale, and typically follows a waxing and waning course. Individuals typically also have recalcitrant atopic dermatitis or localised patches of erythema with scale [4].

Apart from TI, other hair abnormalities include pili torti and trichorrhexis nodosa, which represent twisted or fractured hair shafts, respectively [5]. Sparsity of hairs may be noted on the scalp or on the eyebrows, and the hair is commonly short and lustreless [5]. Patients will often report that their hair is dry, itchy, and difficult to style.

Atopy, elevated IgE levels, and eosinophilia are common features of NS. The atopic dermatitis in NS may respond well to emollients and topical steroids, but will not resolve the erythroderma or ILC, and thus should be a clue for diagnosis. Familial consanguinity, and siblings with similar clinical features may also aid in diagnosis, as NS is autosomal recessive.

Once there is a clinical suspicion of NS, more definitive confirmation may be sought through hair microscopy, skin biopsy or DNA sequencing. DNA sequencing is used to identify germline mutations in the SPINK5 gene, which will support the diagnosis [6]. The SPINK5 gene normally encodes the protein kinase lymphoepithelial Kazal-type inhibitor, known as LEKTI [1]. LEKTI is responsible for inhibiting kallikreins, which are a family of epidermal proteases that cause desquamation. Therefore, mutations in SPINK5 lead to uncontrolled activity of kallikreins, causing inflammation and impaired cornification, leaving patients susceptible to cutaneous infections [1]. Genetic testing will identify germline SPINK5 mutation and confirm diagnosis in close to 64–75% of cases, whilst the rest of the cases rely upon clinical suspicion and findings [7].

NS is a chronic illness with no current cure. Treatment is largely symptomatic, with liberal use of bland emollients along with topical corticosteroids and calcineurin inhibitors for inflammatory skin lesions [8]. Caution with topical corticosteroids is advised, as they carry a risk of increased systemic absorption due to skin barrier defects [5]. Oral acitretin has also been demonstrated to improve cutaneous lesions and foster hair growth in regions of alopecia associated with the disease [9]. Furthermore, psoralen UVA therapy may lead to improvement of cutaneous lesions [10].

More advanced therapy for treatment refractory cases includes intravenous immunoglobulin, which has shown efficacy in severe cases of NS, although this is a costly treatment and requires monthly infusions, potentially making it impractical for this chronic condition [11]. Infliximab (anti-TNF α) infusions have also been reported to cause a significant

improvement in cutaneous inflammation associated with NS [12], although further studies are still required.

Kallikrein inhibitors represent a new potential therapy for NS, with Tan *et al.* demonstrating a reduction in human kallikrein proteolytic activity within transgenic mice [13]. In NS, kallikrein inhibition is typically absent, and thus the inhibitor properties of this treatment may prevent or minimise the inflammatory cutaneous features that are typically present. This study also identified minimal cytotoxic activity of some kallikrein inhibitors against healthy keratinocytes [13], suggesting that it may be safe for human use, pending further studies.

Adults with NS may also develop non-melanoma skin cancers at an early age due to chronic skin inflammation [3]. Routine skin surveillance should therefore be performed, with a low threshold to biopsy suspicious lesion to exclude malignancy [3].

Conclusion

A lack of awareness of NS may often lead to the condition being misdiagnosed as AD or undifferentiated psoriasis during infancy and adult life. Clinicians should be aware of the peripheral stigmata that this syndrome may present with in adults in order to heighten their diagnostic suspicion of this syndrome. Furthermore, the lack of cure for this condition, and extensive cutaneous involvement should trigger clinicians to screen for psychosocial symptoms.

Acknowledgement

We would like to thank Dr. Cathy Zhao for her assistance in producing the photographs and helping organise the relevant information to produce this case report.

We would like to thank Dr. Hashem Shahin for the genetic analysis performed for the two siblings reported in this case.

Statement of Ethics

The research associated with this article was conducted ethically in accordance with the World Medical Association Declaration of Helsinki.

The patient involved in this case report has given written, informed consent for their photos and relevant clinical information to be used in producing this article.

Disclosure Statement

The authors have no conflicts of interest to declare.

Funding Sources

There has been no funding source from any third party for the production of this case.

Author Contributions

Akshay Flora was involved in gathering the relevant clinical information regarding the patient, conducting a literature review, and drafting the article.

Annika Smith was the supervisor involved in identifying the patient's condition as being suitable for a case report, as well as editing the drafted versions of the article for publication.

References

- 1 Chavanas S, Bodemer C, RoCHAT A, Hamel-Teillac D, Ali M, Irvine AD, et al. Mutations in SPINK5, encoding a serine protease inhibitor, cause Netherton syndrome. *Nat Genet*. 2000 Jun;25(2):141–2.
- 2 Judge MR, Morgan G, Harper JL. A clinical and immunological study of Netherton's syndrome. *Br J Dermatol*. 1994 Nov;131(5):615–21.
- 3 Hovnanian A. Netherton syndrome: skin inflammation and allergy by loss of protease inhibition. *Cell Tissue Res*. 2013 Feb;351(2):289–300.
- 4 Sun JD, Linden KG. Netherton syndrome: a case report and review of the literature. *Int J Dermatol*. 2006 Jun;45(6):693–7.
- 5 Smith DL, Smith JG, Wong SW, deShazo RD. Netherton's syndrome: a syndrome of elevated IgE and characteristic skin and hair findings. *J Allergy Clin Immunol*. 1995 Jan;95(1 Pt 1):116–23.
- 6 Saleem HMK, Shahid MF, Shahbaz A, Sohail A, Shahid MA, Sachmechi I. Netherton Syndrome: A Case Report and Review of Literature. *Cureus*. 2018;10(7):e3070.
- 7 Sprecher E, Chavanas S, DiGiovanna JJ, Amin S, Nielsen K, Prendiville JS, et al. The spectrum of pathogenic mutations in SPINK5 in 19 families with Netherton syndrome: implications for mutation detection and first case of prenatal diagnosis. *J Invest Dermatol*. 2001 Aug;117(2):179–87.
- 8 Bin Saif G, Al-Khenaizan S. Netherton syndrome: successful use of topical tacrolimus and pimecrolimus in four siblings. *Int J Dermatol*. 2007 Mar;46(3):290–4.
- 9 Duquia RP, Almeida HL Jr, Souza PR, Vettorato G. Síndrome de Netherton com 20 anos de acompanhamento. *An Bras Dermatol*. 2006;81(6):563–6.
- 10 Nagata T. Netherton's syndrome which responded to photochemotherapy. *Dermatologica*. 1980;161(1):51–6.
- 11 Renner ED, Hartl D, Rylaarsdam S, Young ML, Monaco-Shawver L, Kleiner G, et al. Comèl-Netherton syndrome defined as primary immunodeficiency. *J Allergy Clin Immunol*. 2009 Sep;124(3):536–43.
- 12 Fontao L, Laffitte E, Briot A, Kaya G, Roux-Lombard P, Fraitag S, et al. Infliximab infusions for Netherton syndrome: sustained clinical improvement correlates with a reduction of thymic stromal lymphopoietin levels in the skin. *J Invest Dermatol*. 2011 Sep;131(9):1947–50.
- 13 Tan X, Soualmia F, Furio L, Renard JF, Kempen I, Qin L, et al. Toward the first class of suicide inhibitors of kallikreins involved in skin diseases. *J Med Chem*. 2015 Jan;58(2):598–612.

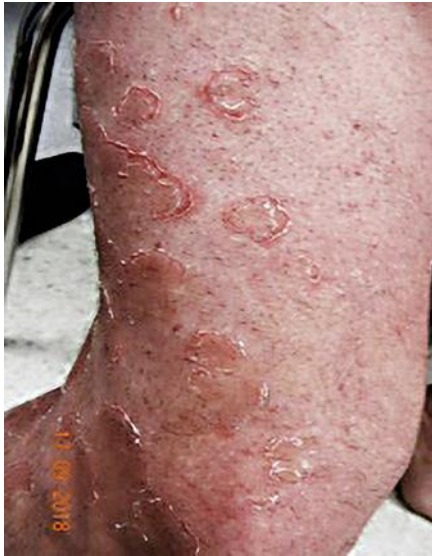

Fig. 1. Ichthyosis linearis circumflexa of the right thigh and lower leg.

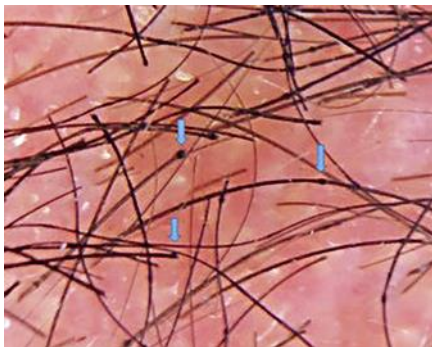


Fig. 2. Trichorrhexis invaginata with “bamboo appearance” seen on trichoscopy.