

Original Article



A Multicenter Pilot Study of Biliary Atresia Screening Using Digital Stool Color Imaging

Kannamon Waitayagitgumjon ,¹ Wannisa Poocharoen ,^{2,3}
Suchin Trirongjitmoah ,⁴ Kriengsak Treeprapin ,⁵ Arada Suttiwongsing ,⁶
Thetiya Wirifai ,⁷ Chira Trirongchitmoah ,⁸ and Pitiporn Tangkabuanbutr

¹Department of Surgery, Bhumibol Adulyadej Hospital, Royal Thai Air Force, Bangkok, Thailand

²Department of Surgery, Queen Sirikit National Institute of Child Health, Ratchathewi, Bangkok, Thailand

³Department of Surgery, College of Medicine, Rangsit University, Bangkok, Thailand

⁴Department of Electrical and Electronics Engineering, Faculty of Engineering, Ubon Ratchathani University, Ubon Ratchathani, Thailand

⁵Department of Mathematics, Statistics and Computer, Faculty of Science, Ubon Ratchathani University, Ubon Ratchathani, Thailand

⁶Department of Surgery, Chiangrai Prachanukroh Hospital, Chiang Rai, Thailand

⁷Department of Surgery, Khon Kaen Hospital, Khon Kaen, Thailand

⁸Department of Surgery, Sunpasitthiprasong Hospital, Ubon Ratchathani, Thailand

⁹Department of Surgery, Ratchaburi Hospital, Ratchaburi, Thailand

OPEN ACCESS

Received: Sep 25, 2023

Revised: Jan 29, 2024

Accepted: Mar 15, 2024

Published online: May 7, 2024

Correspondence to
Wannisa Poocharoen

Department of Surgery, Queen Sirikit National Institute of Child Health, 420/8 Ratchawithi Road, Thung Phayathai Subdistrict, Ratchathewi, Bangkok 10400, Thailand.
Email: surgeryunit@hotmail.com

Copyright © 2024 by The Korean Society of Pediatric Gastroenterology, Hepatology and Nutrition

This is an open-access article distributed under the terms of the Creative Commons Attribution Non-Commercial License (<https://creativecommons.org/licenses/by-nc/4.0/>) which permits unrestricted non-commercial use, distribution, and reproduction in any medium, provided the original work is properly cited.

ORCID iDs

Kannamon Waitayagitgumjon
<https://orcid.org/0000-0003-3491-804X>
Wannisa Poocharoen
<https://orcid.org/0009-0006-7151-190X>
Suchin Trirongjitmoah
<https://orcid.org/0009-0004-2508-1123>

ABSTRACT


Purpose: The presence of acholic stool in biliary atresia (BA) patients is the basis of a stool color card (SCC), a screening tool that has led to more patients receiving Kasai portoenterostomy earlier. This study aimed to evaluate the color image processing of stool images captured using smartphones. We propose that measuring digital color parameters is a more objective method for identifying BA stools and may improve the sensitivity of BA screening.

Methods: A prospective study was conducted in five hospitals in Thailand between October 1, 2020, and December 31, 2021. Stools from infants presenting with jaundice, acholic stool, or dark-colored urine were photographed. Digital image color analysis was performed, and software was developed based on the color on the original SCC. Sensitivity and specificity for predicting BA stools were compared between the SCC and the software.

Results: Of 33 infants eligible for data collection, 19 were diagnosed with BA. Saturation and blue were two potential digital color parameters used to differentiate BA stools. The receiver operating characteristic curve was used to determine the optimum cutoff point of both values, and when saturation ≤ 56 or blue ≥ 61 was set as a threshold for detecting BA stool, high accuracy was achieved at 81.8% and 78.8%, respectively.

Conclusion: Digital image processing is a promising technology. With appropriate cutoff values of saturation in hue, saturation, value and blue in red, green, blue color models, BA stools can be identified, and equivocal-colored stools of non-BA patients can be differentiated with acceptable accuracy in infants presenting with jaundice.

Keywords: Biliary atresia; Image processing; Neonatal jaundice

Kriengsak Treeprapin <https://orcid.org/0009-0006-0646-967X>Arada Suttiwongsing <https://orcid.org/0000-0003-0991-2463>Thetiya Wirifai <https://orcid.org/0009-0009-5327-931X>Chira Trirongchitmoh <https://orcid.org/0000-0001-5275-227X>Pitiporn Tangkabanutr <https://orcid.org/0009-0008-6186-6904>**Funding**

None.

Conflict of Interest

The authors have no financial conflicts of interest.

INTRODUCTION

Biliary atresia (BA) is a rare but serious surgical disease that remains the most frequent hepatic cause of death in childhood and is a major indication for pediatric liver transplantation worldwide [1,2]. Timely diagnosis and surgical intervention are of the utmost importance; otherwise, all patients progress to cirrhosis and die within 2 years [3]. It has been shown that Kasai hepatic portoenterostomy (KPE), a standard surgical treatment for BA, performed before patients reach 60 days of age improves long-term native liver survival compared with KPE performed at an older age [4,5]. This time-critical disease could benefit from a highly sensitive screening program. The stool color card (SCC) is a self-monitoring tool developed in Japan in 1977. It contains a set of stool pictures with varying shades of color, of which three of the seven shades represent pale-pigmented stools. By comparing the infant's stool to the pictures on the card, caregivers can identify acholic stool, one of the hallmark symptoms of BA resulting from impaired bile drainage [6]. Acholic stool can be observed at varying onsets, ranging from within the first month after birth to up to 5 months [7,8]. We proposed that the digital colorimetric detection of stool colors could provide a more objective method for quantifying stool pigmentation and enhance the sensitivity and specificity of SCC screening for BA. This study aimed to evaluate the digital image analysis of stool images taken with smartphones to identify acholic stools in patients with BA and to compare its accuracy with that of conventional SCC.

MATERIALS AND METHODS

Study population

After approval by the Ethics Committee of the Queen Sirikit National Institute of Child Health, a prospective study was conducted in five regional hospitals in Thailand. Eligible participants were infants aged 2 weeks to 6 months who presented to the pediatric surgery unit with jaundice, dark-colored urine, or pale stool between October 1, 2020, and December 31, 2021. Written informed consent to photograph the stool samples was obtained from the parents of each infant. Patients who had undergone previous hepatobiliary surgery were excluded from the study, and those with incomplete information on the final diagnosis were withdrawn from the data analysis. Informative data, including relevant demographics, results of the investigation, age at operation, and treatment outcomes, were collected. The timing and choice of investigations to diagnose BA or exclude other causes of jaundice depended on the protocols of each participating hospital and attending physicians. BA diagnosis was confirmed using intraoperative cholangiography (IOC) or intraoperative findings. The study complied with the Declaration of Helsinki, and the individual data of all patients were kept confidential.

Photo shooting method

A smartphone camera with at least a 10-megapixel resolution was required. The smartphones used in this study included the iPhone® (Apple Inc.) and Samsung® and other Android phones. The photos were taken using the following standardized protocol: a stool sample was placed on 100 g/m² white A4 paper. A validated SCC [6] was also placed next to the sample for comparison with subsequent image analysis. The photos were taken with a flash in a room with standard illumination, and the distance between the sample and device was approximately 30 cm. All photos were captured during the initial evaluation before the patients underwent any procedure. For the subjective assessment of stool color, the SCC

score was graded by the parents of the participant and by the treating physician. The SCC contained seven photographs of normal and abnormal stool colors. Among the seven shades, the 1st to 3rd shades were considered abnormal and warranted further investigation, whereas the 4th to 7th shades were normal pigmented stools.

Software development

Stool image analysis was performed in collaboration with computer engineers at Ubon Ratchathani University. De-identified stool images were preprocessed by background subtraction and removal of the shadow of the stool. Software was developed and installed on a standard computer to generate a color histogram that represented the distribution of colors in the stool image and was analyzed in red, green, blue (RGB) and hue, saturation, value (HSV) color spaces. A color histogram was also obtained of each shade on the SCC placed beside the sample. The values with the highest cumulative frequency for each color parameter were recorded. The stool image and seven pictures on the SCC were matched for similarity based on the least Euclidean distance between the values of the color parameters with the highest cumulative frequency. The HSV and RGB color values of the stool images were obtained by measuring the average values of 10 randomly selected spots on the original image for subsequent analysis (Fig. 1).

Statistical analysis

Statistical analysis was performed using SPSS version 28 for Windows (IBM Co.). The two patient groups, BA and non-BA, were compared in terms of several demographic and clinical variables. The results for continuous nonparametric variables were expressed as medians with interquartile ranges (IQR). Categorical variables were expressed as percentages. Continuous variables were compared using the Mann–Whitney U-test for non-normally distributed data.

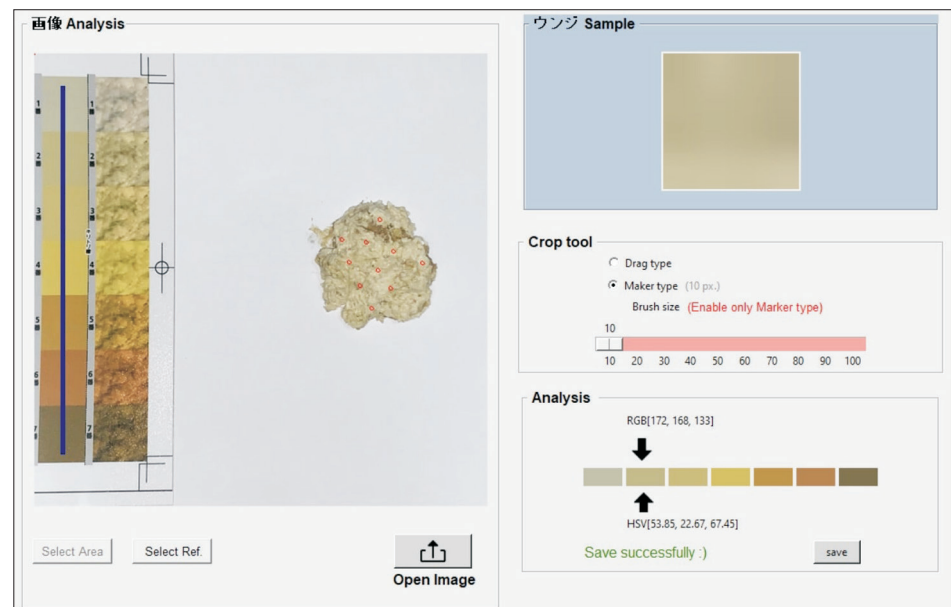


Fig. 1. Stool color analysis software.

RGB: red, green, blue, HSV: hue, saturation, value.

Categorical variables were compared using Fisher's exact test or the chi-squared test. The results were considered statistically significant at $p < 0.05$. The diagnostic performance of the SCC and the application was measured for sensitivity, specificity, positive predictive value (PPV), negative predictive value (NPV), and accuracy. Inter-rater reliability (IRR) of the SCC was tested using the intraclass correlation coefficient (ICC). The discriminative power of the digital color parameters was assessed by calculating the area under the receiver operating characteristic (ROC) curve, setting BA or non-BA stool as the outcome and RGB and HSV values as the predicting variables. An area under the curve (AUC) above 0.7 was considered acceptable for outcome prediction. The cutoff point of the color parameters for optimal clinical performance was determined using the ROC curve.

Ethics statement

This study used de-identified photographs and was approved by the Ethics Committee of the Queen Sirikit National Institute of Child Health (institutional review board number IRB00007346, study approval number: REC.163/2563 (Re. 1)).

RESULTS

A total of 33 infants were prospectively recruited for the study, of which 19 (58%) were diagnosed with BA and 14 (42%) were non-BA, diagnosed with other causes of cholestasis, such as neonatal hepatitis ($n=6$), parenteral nutrition or intestinal failure-associated cholestasis ($n=7$), and choledochal cysts ($n=1$). The overall median age at the first surgical consultation was 64 (IQR, 52–84) days, which was comparable between the two groups ($p=0.799$); however, significant differences were observed in median birth weight ($p=0.007$), gestational age ($p=0.002$), and body weight ($p=0.011$). Patients in the non-BA group had more comorbidities ($p=0.01$) and a history of parenteral nutrition ($p=0.0004$). At the time of presentation, all patients had jaundice. Of the patients with BA, 84% had abnormal pale stools, whereas only 50% of the patients without BA had a history of pale stools. The median age at the onset of pale-colored stool in the BA group was 47 (IQR, 52–84) days.

All patients in the BA group underwent laparotomy, with or without IOC, for a definite diagnosis. Five (36%) non-BA patients were subjected to diagnostic laparotomy and IOC to exclude BA. Among the 19 BA patients, 15 (79%) underwent KPE, while the remaining 4 (21%) had advanced biliary cirrhosis and were transferred for primary liver transplantation. The median age at surgery in the BA group was 65 (IQR, 57.5–83) days. Parents and treating physicians were asked to rate the infants' stool color based on conventional SCC. Only two (6%) parents had previous experience using the SCC, but its accuracy in identifying BA stool in this cohort was 76%, with a sensitivity and specificity of 89.5% and 57.1%, respectively. The SCC results rated by the treating physician were almost identical (**Table 1**), with the ICC analysis demonstrating excellent IRR (0.932; 95% confidence interval [CI], 0.867–0.966).

When using our developed software on the same set of stool pictures, the sensitivity in detecting BA stool using RGB and HSV color spaces was 68.4% and 47.4%, respectively, which was lower than that of SCC. The specificity, PPV, NPV, and accuracy in comparison with those of SCC are shown in **Table 1**. We further analyzed the color parameters of the stool pictures using the RGB and HSV color spaces. Six color parameters were tested for diagnostic performance using the ROC curve. Saturation (S) and blue (B) were identified as relevant color parameters for distinguishing BA stools from non-BA stools, with an AUC of 0.816 (95%

Table 1. Diagnostic performance of stool color card, developed software, and saturation (S) and blue (B) component cutoff values

Diagnostic performance	SCC (rated by parents)	SCC (rated by treating physician)	Application		S _{≤56}	B _{≥61}
			HSV	RGB		
Sensitivity	89.5	94.7	47.4	68.4	84.2	89.5
Specificity	57.1	57.1	64.3	50.0	78.6	64.3
Positive predictive value	73.9	75.0	64.3	65.0	84.2	77.3
Negative predictive value	80.0	88.9	47.4	53.8	78.6	81.8
Accuracy	76.0	78.8	54.6	60.6	81.8	78.8

Values are presented as percentage.

SCC: stool color card, HSV: hue, saturation, value, RGB: red, green, blue.

Table 2. AUC from ROC curves for each color parameter for predicting BA stools

Color parameters		AUC	p-value	95% confidence interval
HSV	H (hue)	0.609	0.291	0.408–0.810
	S (saturation)	0.816	0.002	0.660–0.972
	V (value)	0.609	0.291	0.403–0.815
RGB	R (red)	0.594	0.362	0.386–0.802
	G (green)	0.637	0.184	0.428–0.847
	B (blue)	0.799	0.004	0.640–0.957

AUC: area under the curve, ROC: receiver operating characteristic, BA: biliary atresia.

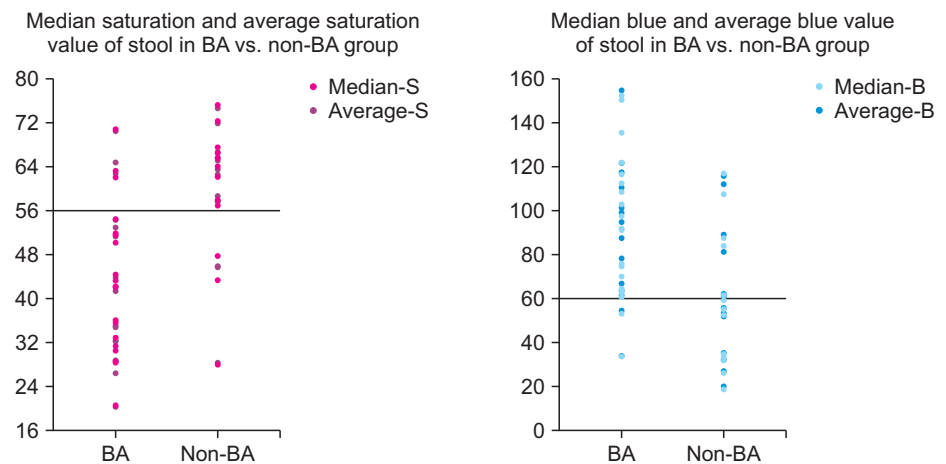


Fig. 2. Saturation (S) and blue (B) values of stools from BA and non-BA patients. BA: biliary atresia.

CI, 0.660–0.972) and 0.799 (95% CI, 0.640–0.957) (**Table 2**). The optimum cut-off points of S and B for predicting BA stool based on the highest Youden index on the ROC curve were lower than 56 and higher than 61, respectively. Using this cutoff point to discriminate BA and non-BA stools, the sensitivities for S and B were found to be 84.2% and 89.5%, respectively, while the specificities were 78.6% and 64.3%, respectively (**Fig. 2**).

DISCUSSION

Currently, the two main potential methods for BA screening are a laboratory-based approach using direct or conjugated serum bilirubin (DB/CB) levels during the neonatal period and home-based screening using a SCC [6]. The measurement of serum DB/CB requires blood samples. Moreover, the test can only be performed in hospital-based laboratories, limiting

its general feasibility. In contrast, the SCC provides caregivers with a point-of-care tool for continuous surveillance of their infant's stool. The introduction of nationwide SCC screening in Taiwan in 2004 was followed by a decrease in the proportion of late referrals (9.5% to 4.9%) and an improvement in the rate of KPE performed within the first 60 days (68.9% to 73.6%) [9]. A 19-year cohort study in Japan has also shown high accuracy of SCC with sensitivity and specificity at 1-month check-up of 76.5% (95% CI, 62.2–90.7) and 99.9% (95% CI, 99.9–100.0), respectively [10]. In this study, the SCC used by parents and physicians appeared to have good sensitivities of 89.5% and 94.7%, respectively; however, the specificity was lower (57.1%) for both raters. However, this could be explained by differences in the control group, as healthy infants were not included in this study, and pale-colored stool can be observed in other causes of cholestasis, such as neonatal hepatitis, if bile excretion is severely impaired [11]. Although the SCC has been shown to be a user-friendly tool with high reliability between different raters, its interpretation is more subjective and may cause difficulties, especially for parents, in judging stools with equivocal colors, as demonstrated in this study. The majority of stool samples in our BA cases were rated as number 2 and number 3, a transitional shade before normally pigmented stool, which could lead to a delayed diagnosis.

Smartphones offer an attractive platform for digital image colorimetry and are increasingly utilized in various fields of medical science. The main function of a smartphone is its camera, which allows quantification of color images. In Japan, Baby Poop is an iPhone application designed to identify BA stools using pattern recognition and machine learning processes. According to one study of this application, a sensitivity and specificity of 100% were reported (95% CI, 0.48–1.00 and 0.90–1.00, respectively) [12]. In the United States, a smartphone application called PoopMD was developed in 2015 for BA screening. It compares the area of concern within the stool photographs selected by users with a gold standard set of stool pictures and interprets the color as normal, pale, or indeterminate using Color-hex. A pilot study using this application yielded 100% sensitivity and 89% specificity [13]. Currently, these applications are limited to smartphone platforms and are available only in their respective countries. The software developed in this study is the first to use digital image colorimetry to classify stool specimens compared with the original SCC captured in the same setting as the gold standard, rather than relying on human visual perception. This method avoids the need to limit its use to a specific smartphone platform or standardize ambient light. However, the accuracy of this software in detecting BA stools was not as high as that of SCC, with a sensitivity of 68.4% and 47.4% and a specificity of 50% and 64.3% when using the RGB and HSV color spaces, respectively. Possible factors that might have compromised accuracy were the inhomogeneous nature of stool images and the method of selecting the representative median color, resulting in inaccurate color measurement.

As demonstrated by Shen et al. [14], the saturation (S) values of the HSV color space are directly proportional to the amount of biliary pigment in the stool. When saturation below 60% was set as the cutoff point, alcoholic stools were identified with a sensitivity of 100% and a specificity of 85%. This study confirmed that the average values of saturation (S) and blue (B) are two potential parameters for quantifying stool color and identifying BA stools. Because most acholic stools presented in BA patients are not completely white in color, distinguishing hypopigmented BA stools by setting an optimum cut-off point for these two parameters could potentially surpass the performance of conventional SCC. In this study, when the cut-off points for BA stool were set at saturation (S) less than 56 and blue (B) greater than 61, the sensitivity was comparable with that of SCC at 84.2% and 89.5%, respectively, while the specificity was higher at 78.6% and 64.3%, respectively.

Late referral and diagnosis of BA are ongoing problems in Thailand. The median age at KPE documented in a study conducted from 2006 to 2015 in a Thai tertiary referral hospital was 101 (IQR, 42–213) days, and 20% (n=24) of these patients already had severe liver fibrosis upon diagnosis [15]. In this study, we showed that stool color can be efficiently evaluated using smartphone digital image colorimetry with a versatile smartphone model and ambient light. A simple self-screening application could be developed to help parents detect abnormally colored stools and seek earlier medical attention. A limitation of this study is the lack of stool specimens from healthy infants as a control group, which would better demonstrate the diagnostic accuracy of our method for BA screening in the general population. In future research, a more accurate method for selecting representative areas for color measurement should be pursued, and the software algorithm should be modified to incorporate the cutoff values of saturation and blue to enhance its accuracy.

ACKNOWLEDGEMENTS

The authors would like to thank Dr. Korakot Niruttiwat for her contribution in data collection and Dr. Jarruphong Noitumyae for his assistance in the statistical processing of data. We would also like to express our gratitude to Dr. Rangsak Niramis for his professional advice and language polishing in the preparation of the manuscript.

REFERENCES

1. Gesprasert G, Chongsrisawat V, Tantemsapya N, Thirapattaraphan C, Nonthasoot B, Tovikkai C, et al. The first report of pediatric liver transplantation in Thailand from the Thai liver transplant registry. *Transplantation* 2020;104 (Suppl 3):S536. [CROSSREF](#)
2. Anderson CD, Turmelle YP, Lowell JA, Nadler M, Millis M, Anand R, et al. The effect of recipient-specific surgical issues on outcome of liver transplantation in biliary atresia. *Am J Transplant* 2008;8:1197-204. [PUBMED](#) | [CROSSREF](#)
3. Howard ER, MacLean G, Nio M, Donaldson N, Singer J, Ohi R. Survival patterns in biliary atresia and comparison of quality of life of long-term survivors in Japan and England. *J Pediatr Surg* 2001;36:892-7. [PUBMED](#) | [CROSSREF](#)
4. Ohi R, Nio M, Chiba T, Endo N, Goto M, Ibrahim M. Long-term follow-up after surgery for patients with biliary atresia. *J Pediatr Surg* 1990;25:442-5. [PUBMED](#) | [CROSSREF](#)
5. Redkar R, Karkera PJ, Raj V, Bangar A, Hathiramani V, Krishnan J. Outcome of biliary atresia after Kasai's portoenterostomy: a 15-year experience. *Indian Pediatr* 2017;54:291-4. [PUBMED](#) | [CROSSREF](#)
6. Matsui A. Screening for biliary atresia. *Pediatr Surg Int* 2017;33:1305-13. [PUBMED](#) | [CROSSREF](#)
7. Matsui A, Sasakia N, Arakawa Y, Ishikawa T, Momoya T, Kasano Y, et al. Neonatal mass screening for biliary atresia: a pilot study in Tochigi Prefecture, Japan. *Screening* 1993;2:201-9. [CROSSREF](#)
8. Yang MC, Chang MH, Chiu SN, Peng SF, Wu JF, Ni YH, et al. Implication of early-onset biliary atresia and extrahepatic congenital anomalies. *Pediatr Int* 2010;52:569-72. [PUBMED](#) | [CROSSREF](#)
9. Tseng JJ, Lai MS, Lin MC, Fu YC. Stool color card screening for biliary atresia. *Pediatrics* 2011;128:e1209-15. [PUBMED](#) | [CROSSREF](#)
10. Gu YH, Yokoyama K, Mizuta K, Tsuchioka T, Kudo T, Sasaki H, et al. Stool color card screening for early detection of biliary atresia and long-term native liver survival: a 19-year cohort study in Japan. *J Pediatr* 2015;166:897-902.e1. [PUBMED](#) | [CROSSREF](#)
11. Watanatittan S, Rattanasuwan T, Niramis R, Buranakitjaroen V, Anuntkosol M. Diagnostic problems in infantile cholestatic jaundice. *Thai J Surg* 1998;19:45-50.
12. Hoshino E, Hayashi K, Suzuki M, Obatake M, Urayama KY, Nakano S, et al. An iPhone application using a novel stool color detection algorithm for biliary atresia screening. *Pediatr Surg Int* 2017;33:1115-21. [PUBMED](#) | [CROSSREF](#)

13. Franciscovich A, Vaidya D, Doyle J, Bolinger J, Capdevila M, Rice M, et al. PoopMD, a mobile health application, accurately identifies infant acholic stools. *PLoS One* 2015;10:e0132270. [PUBMED](#) | [CROSSREF](#)
14. Shen Z, Zheng S, Dong R, Chen G. Saturation of stool color in HSV color model is a promising objective parameter for screening biliary atresia. *J Pediatr Surg* 2016;51:2091-4. [PUBMED](#) | [CROSSREF](#)
15. Noitumyae J, Laorwong S, Anantkosol M, Niramis R. [Biliary atresia in infancy: an analysis of diagnosis, prognostic factors and outcomes of treatment]. *J Dep Med Serv* 2018;43:66-72. Thai.