

Trauma and reconstruction

A report of a retained bullet in the bladder which migrated from an extraperitoneal injury

Chintan Mehta^{*}, Matthew Loecher, Allison Sih, Adam C. Reese

The Lewis Katz School of Medicine at Temple University, 3401 N. Broad Street Philadelphia, PA, 19140, USA



ARTICLE INFO

Keywords:

Bladder injury
Retained foreign body in bladder
Cystostomy
Genitourinary trauma
Extraperitoneal injury

ABSTRACT

Genitourinary trauma secondary to a gunshot wound is uncommon as it only occurs in about 10% of cases. We present a case of a gentleman who suffered a gunshot wound to the pelvis. The bullet was originally extraluminal to the bladder; however, upon repeat CT scan eight days later, the bullet had migrated intra-luminally. We hope to show through this case that uncomplicated extraperitoneal injuries with an adjacent missile might benefit from early surgical exploration.

Introduction

Genitourinary trauma occurs in approximately 6–11% of patients admitted with gunshot wounds.¹ As retained missiles can lead to urethral or ureteral obstruction, calculus formation, and infection, it is recommended to remove the missile if present within the bladder or collecting system. In 90% of cases with penetrating bladder injuries an entry and exit site are noted along the bladder wall.¹ We present a unique case of a penetrating extraperitoneal bladder injury with retained extraluminal missile with migration into the bladder lumen.

Case report: A 27-year-old male presented to the emergency department with multiple gunshot wounds (GSW). There were found to be five wounds of the left upper chest, left posterior upper arm, right foot, and left buttock. Pelvic X-ray in the trauma bay revealed a retained missile within the pelvis. Computed tomography (CT) of the abdomen and pelvis with contrast showed an extraperitoneal bladder injury of the right anterior bladder wall with retained missile adjacent to the bladder with significant metal artifact obscuring the bladder wall (Fig. 1, A). Post imaging, a catheter was placed with return of light pink urine which quickly cleared to yellow. Patient was taken emergently to the OR for axillary artery repair with vascular surgery. With no other intra-abdominal injuries requiring exploration, the patient's extraperitoneal bladder injury was managed conservatively with catheter decompression.

A CT cystogram obtained 8 days later showed an intact bladder

without contrast extravasation and the missile at the posterior midline of the bladder (Fig. 1, B). With the missile now in a new, dependent position, bedside cystoscopy was performed which confirmed the presence of a retained bullet in the bladder.

The patient was taken to the operating room for removal of the retained missile. A repeat cystogram was performed confirming an intact bladder wall (Fig. 2). Cystoscopy showed no urethral injury and confirmed a free-floating, intact bullet. There was a right lateral wall hematoma with no other mucosal wall damage. Due to its large size, the bullet was unable to be removed cystoscopically. A small suprapubic cystostomy was made to extract the foreign body. Under direct inspection, the bladder appeared intact. The cystostomy was closed in 2 layers and catheter was left in place post-operatively. A repeat fluoroscopic cystogram on post-operative day 10 showed no extravasation and his catheter was removed.

Discussion

Genitourinary penetrating trauma often occurs in the setting of multiple organ system injuries with a multidisciplinary team approach. We present the unique case of a GSW to the pelvis with a bullet initially extrinsic to the bladder, but later found to have migrated into the bladder lumen.

Reported management of retained missiles in the pelvis range from observation to endoscopic, laparoscopic, or open surgical extraction.^{2–4}

Abbreviations: AUA, American Urological Association; CT, Computed tomography.

^{*} Corresponding author.

E-mail addresses: csmehta@temple.edu (C. Mehta), matthew.loecher@tuhs.temple.edu (M. Loecher), Allison.sih@tuhs.temple.edu (A. Sih), adam.reese@tuhs.temple.edu (A.C. Reese).

<https://doi.org/10.1016/j.eucr.2020.101463>

Received 28 September 2020; Accepted 21 October 2020

Available online 22 October 2020

2214-4420/© 2020 The Authors.

Published by Elsevier Inc.

This is an open access article under the CC BY-NC-ND license

(<http://creativecommons.org/licenses/by-nc-nd/4.0/>).

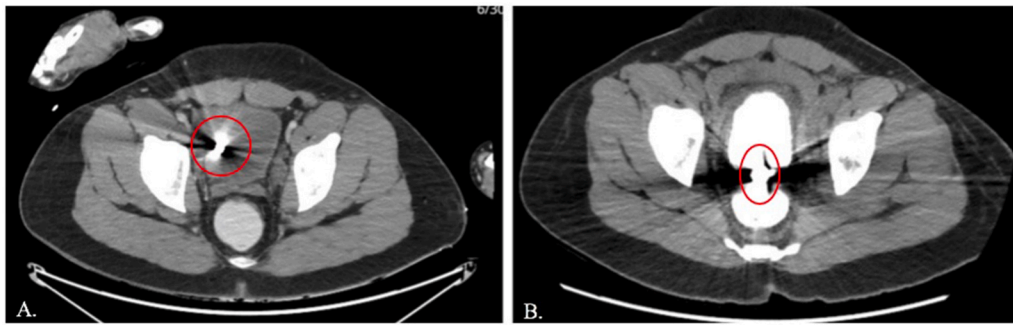


Fig. 1. Computerized tomography abdomen/pelvis (CTAP) during hospital stay.

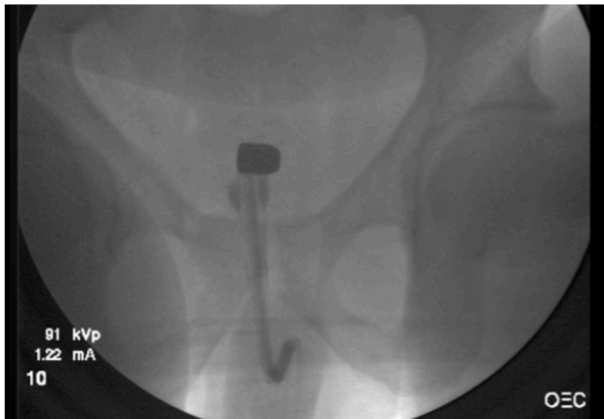


Fig. 2. Fluoroscopy taken in operating room during procedure on hospital day 10. This demonstrates a retained bullet in an intact bladder.

Per the AUA Urotrauma guidelines, extraperitoneal bladder injuries can be further classified into complicated and uncomplicated.⁵ Bladder injuries are considered complicated in the setting of exposed bony spicules in the bladder, concurrent rectal and/or vaginal lacerations and concern for bladder neck injuries. In the setting of a possible intraluminal missile, guidelines also suggest that these patients be managed as complicated patients with immediate surgical evaluation in order to prevent delayed complications.

In this setting, the patient had no other indications for exploratory laparotomy and did not clearly meet the definition of a complicated extraperitoneal bladder injury. With these findings, his emergent vascular injuries were treated and his abdomen and pelvis were not explored. Approximately one week after the initial injury, imaging revealed that the bullet had migrated inside the bladder. Therefore, failure to remove the bullet at the time of initial presentation resulted in the need for a second procedure, thus representing a potential opportunity for improvement in care.

This case highlights the complexities of extraperitoneal bladder injuries caused by penetrating compared to blunt mechanisms. Perhaps penetrating extraperitoneal injuries with an adjacent foreign body should be considered complex and therefore explored at the time of

initial presentation.

Conclusion

This case describes a patient who suffered multiple GSWs, one of which was retained in the pelvis near an extraperitoneal bladder injury. At presentation, according to AUA urotrauma guidelines, his injury was considered uncomplicated and thus, he was treated conservatively with catheter decompression. On follow-up imaging eight days later, the bullet had migrated into the bladder, and the entry site had healed. Therefore, a cystostomy was performed to extract the retained bullet. For similar cases with genitourinary trauma, we recommend considering surgical management for uncomplicated extraperitoneal bladder injuries with an adjacent retained missile.

Funding

This research did not receive any specific grant from funding agencies in the public, commercial, or not-for-profit sectors. Chintan Mehta: Writing of original draft, Matthew Loecher: Writing of review and editing, Allison Sih: Writing of review and editing, Adam Reese: Writing of review and editing, Supervision

Declaration of competing interest

None.

References

1. Cinman NM, McAninch JW, Porten SP, et al. Gunshot wounds to the lower urinary tract: a single-institution experience. *J Trauma Acute Care Surg*. 2013;Mar;74(3):725–730. <https://doi.org/10.1097/TA.0b013e31827e1658>. discussion 730–1.
2. Raz O, Shilo Y, Stav K, Leibovici D. Late migration of a retained bullet into the urinary bladder presenting with acute urinary retention. *Isr Med Assoc J*. 2007;Jun;9(6):484–485. PMID: 17642402.
3. Shekar A, Arojo I, Bukavina L, et al. Acute urinary retention due to late migration of a retained bullet to the urethral meatus. *Urology*. 2019;129:e6. <https://doi.org/10.1016/j.urology.2019.03.021>.
4. Friedman AA, Trinh QD, Kaul S, et al. Complete endoscopic management of a retained bullet in the bladder. *Can Urol Assoc J*. 2013;Jan-Feb;7(1-2):E143–E145. <https://doi.org/10.5489/cuaj.258>. PMID: 23671506; PMCID: PMC3650824.
5. Morey A, Brandes S, Daniel Dugi, et al. Urotrauma guideline 2017. Retrieved September 06, 2020, from <https://www.auanet.org/guidelines/urotrauma-guideline>.