



Contents lists available at ScienceDirect

International Journal of Surgery Case Reports

journal homepage: www.casereports.com

Side-to-side caval anastomosis in a patient receiving a liver graft from a marginal donor with situs inversus totalis



Tommaso Maria Manzia*, Laura Tariciotti, Roberta Angelico, Luca Toti, Alessandro Anselmo, Giuseppe Tisone

Department of Experimental Medicine and Surgery, Tor Vergata University, Rome, Italy

ARTICLE INFO

Article history:

Received 18 September 2014

Received in revised form 5 October 2014

Accepted 10 October 2014

Available online 11 December 2014

Keywords:

Situs inversus totalis

Marginal donor

Liver transplantation

Piggyback technique

ABSTRACT

INTRODUCTION: The donor situs inversus totalis status was considered an absolute contraindication to liver transplantation due to the technical difficulties involved. Only in recent years has a very young deceased donor with situs inversus totalis been considered as a potential donor.

PRESENTATION OF CASE: We herein report a single case of 57-year-old male patient with hepatocellular carcinoma who received a liver transplantation from a 73-year-old woman with situs inversus totalis. Liver was implanted using a 1992-Belghiti piggyback technique positioning the larger hemiliver in the left upper quadrant and the left in the liver fossa. We assisted a good graft reperfusion without surgical or anesthetic problems. His hospital stay was relatively uneventful and he was discharged from hospital on postoperative day 7. At 8 months of follow-up the patient is alive and in good clinical condition.

DISCUSSION: The donor situs inversus totalis does not require any modification of transplant procedure if the donor-recipient size match permits a comfortable placement of the graft in a standard anatomical position. To the best of our knowledge, this is the first case of liver transplantation with a graft from a "marginal" donor with situs inversus totalis using a 1992-Belghiti piggyback technique.

CONCLUSION: The donor situs inversus totalis status should not be considered a contraindication for LT and the piggyback technique should be considered the surgery of choice.

© 2014 The Authors. Published by Elsevier Ltd. on behalf of Surgical Associates Ltd. This is an open access article under the CC BY-NC-ND license (<http://creativecommons.org/licenses/by-nc-nd/3.0/>).

1. Introduction

"Situs inversus" is a congenital condition characterized by a symmetric "mirror-image" orientation of all organs with respect to the midline. This malformation is defined "totalis" when the anomaly includes both the thoracic (dextrocardia) and abdominal viscera. Situs inversus totalis (SIT) occurs with an incidence of 0.1% in the general population and often coexists with cardiac and visceral malformations, including pre-duodenal position of the portal vein, underdevelopment of the vena porta and vena cava, polysplenia, congenital biliary atresia, or midgut volvulus.

In the past, situs inversus malformation was considered an absolute contraindication to LT for the technical complexity, due to the vascular anomalies and the difficulties in achieving an adequate graft position in the recipient's abdomen. However, during the last years, there have been several cases of successful transplants in recipients with situs inversus totalis,¹ but until now only

seven cases of deceased donors with situs inversus totalis have been reported in literature.

Herein we present a case of LT with a graft from a deceased SIT donor, using a large side-to-side vena cava anastomosis for graft implantation.

The study was approved by the Local Ethical Committee and the patient's signed consent form was obtained.

2. Case report

A 73-year-old woman was referred to our institution as a potential deceased liver donor. Routine chest X-ray and ultrasound examination demonstrated dextrocardia and "mirror image liver". A status of SIT was confirmed after donor laparotomy. Liver and kidney were recovered using standard techniques and preservation solution. No technical difficulties were encountered during organ procurement. A 57-year-old male with Hepatitis C-related end stage liver disease and 5 cm max. diameter hepatocellular carcinoma lesion was selected as recipient. His tumor had previously been treated by trans-arterial chemoembolization. The adjusted and unadjusted Mayo End-Stage Liver Disease scores were 18 and 10, respectively. The waiting list time was 6 months. During backbench procedure, the hepatic artery was located on the right side and the common bile duct on the left, the portal vein

Abbreviations: SIT, situs inversus totalis; LT, liver transplantation.

* Corresponding author at: Department of Experimental Medicine and Surgery, Tor Vergata University, Viale Oxford n.81, 00133 Rome, Italy. Tel.: +39 06 20908294. E-mail address: tomanzia@libero.it (T.M. Manzia).

<http://dx.doi.org/10.1016/j.ijscr.2014.10.037>

2210-2612/© 2014 The Authors. Published by Elsevier Ltd. on behalf of Surgical Associates Ltd. This is an open access article under the CC BY-NC-ND license (<http://creativecommons.org/licenses/by-nc-nd/3.0/>).

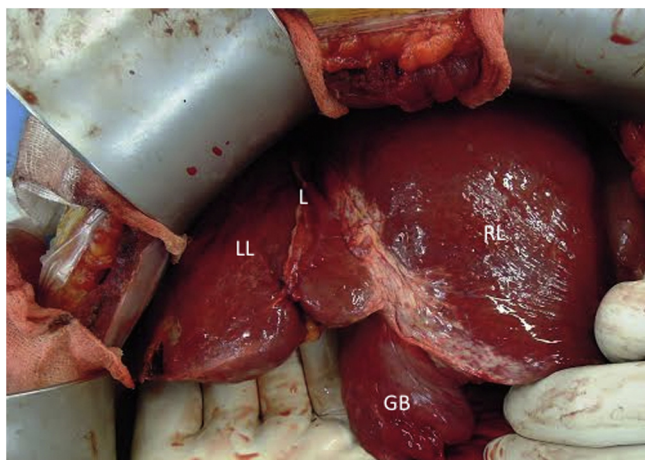


Fig. 1. The graft status after the artery reconstruction. The left hemiliver was placed in the liver fossa and the right over the stomach. The donor venous system was anastomosed with the recipient venous system using a large side-to-side 3–0 prolene running suture. RL: right hemiliver; LL: left hemiliver; GB: gallbladder; L: falciform ligament.

being behind the common bile duct. The liver weight was 1300 g. In order to perform a 1992–Belghiti piggyback technique the supra and infra hepatic vena cava were sutured. On the recipient, a right subcostal incision was made with preservation of the left rectus muscle. Hepatectomy was performed with the preservation of the vena cava and the suture ligation of right, middle and left hepatic veins. A large Satinsky clamp was placed on the recipient vena cava with about 2 cm open for the venous flow. The donor liver was placed with the larger hemiliver in the left upper quadrant and the left in the liver fossa (Fig. 1). The liver implantation was made by a large side-to-side cavo-cava anastomosis using a running 3/0 prolene suture. Once portal vein anastomosis was performed, the preservation solution was flushed away by 1000cc glucoasate 5% from a cannula inserted into the donor vena cava. For artery reconstruction, the cut-off of the coeliac axis of the donor was anastomosed with the cut-off right–left hepatic junction of the recipient. Biliary reconstruction was performed by duct-to-duct anastomosis without placement of a “T” type drainage tube (Fig. 2).

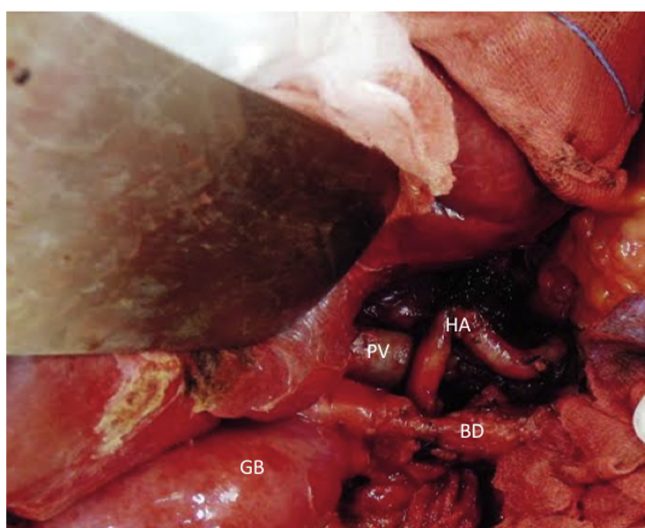


Fig. 2. The hepatic pedicle after transplantation. The portal vein was reconstructed using a 5–0 prolene running suture and the recipient hepatic with a 6–0 prolene suture on the cut-off of the donor coeliac axis. The donor bile duct was precisely on the same axis as the recipient duct. PV: portal vein; HA: hepatic artery; BD: bile duct; GB: gallbladder.

Table 1
Liver transplantations from donors with situs inversus.

Authors (year)	Donor age (years)	Recipient age (years)	Primary disease	Technique	Vascular reconstruction	Biliary reconstruction	Outcome
Asfar (1995)	23	63	Post-alcoholic cirrhosis	Counterclockwise 90° rotation	Vena cava end-to-side anastomosis	Roux en-Y choledochojejunostomy	Died on postoperative day 20 for ARDS, bile leak, sepsis
Herrera (1996)	43	40	Cirrhosis non-defined	Orthotopic, piggyback	Vena cava end-to-side anastomosis	End-to-end choledochocholecholeostomy with T-tube stent	Alive, 30 months
Braun [6]	19	56	Post-alcoholic cirrhosis	Orthotopic, piggyback	Vena cava end-to-side anastomosis	End-to-end choledochocholecholeostomy with T-tube stent	Alive, 17 months
Sugawara (2001)	34	2	Biliary atresia	Living related donor graft	Vena cava end-to-end anastomosis	Roux en-Y choledochojejunostomy with stent	Alive, 17 months
Pomposelli (2007)	41	49	HCV-end stage liver disease	Retroversus implant (180° rotation), piggyback	Vena cava end-to-end anastomosis	Roux en-Y choledochojejunostomy	Non-occlusive clot in vena cava on 9 postoperative day, no follow-up reported
Dou (2010)	NA	50	End-stage Budd–Chiari syndrome	Clockwise 15° rotation, temporary water balloons	Vena cava end-to-end anastomosis	End-to-end choledochocholecholeostomy	Alive, 10 months
Sun [7]	23	58	HBV-end stage liver disease	Orthotopic, piggyback	Vena cava end-to-end anastomosis	End-to-end choledochocholecholeostomy	Alive, 36 months
Manzia (2014) [present case]	73	57	Hepatocellular carcinoma	Orthotopic, piggyback	Vena cava side-to-side anastomosis	End-to-end choledochocholecholeostomy	Alive, 6 months

NA: not available.

We assisted a good graft reperfusion without surgical or medical problems. The cold and warm ischemia times were 7.45 h and 40 min, respectively. The total operative time was 6.40 h and the patient was extubated in the intensive care unit 3 h after surgery. His hospital stay was relatively uneventful with excellent graft function and he was discharged from hospital on postoperative day 7. Surveillance computed tomography scan performed at postoperative day 15 showed no surgery complications. At 8 months of follow-up the patient is alive and in good clinical condition.

3. Discussion

Over the last few years, in order to contrast organ shortage, the transplant community has expanded the criteria for organ donation and marginal donors have been increasingly used worldwide. In this context, the SIT donor, who was previously considered an absolute contraindication for LT due to the technical difficulties involved, is currently being taken into account, even if only in cases of young donors. The main issue is a liver rotation on the vascular axis and the blockage of venous outflow. To avoid this anatomical concern various authors have described different operations but a standard technique has not yet been defined.

To the best of our knowledge, this is the eighth case reported worldwide on the use of donor with situs inversus (Table 1). The very first case was reported in 1995 by Asfar et al.²; they rotated the liver 90° counter clockwise, placing the left side in the upright space and the right in the paracolic sulci. After ligation of the inferior vena cava, an end-to-side anastomosis between the intrahepatic vena cava and recipient's inferior cava was performed. Herrera et al.³ and Pomposelli et al.⁴ described a further two cases of orthotopic LT using piggyback techniques with and without rotation of the liver, respectively. In Pomposelli's case, the liver was implanted and rotated 180° along the axis of the vena cava, positioning the larger anatomic hemiliver in the right upper quadrant. This position permitted a direct anastomosis of the suprahepatic vena cava of the graft to the confluence of the middle and left hepatic veins, however, a Roux en-Y choledochojejunostomy was necessary to complete the bile duct reconstruction, since the native biliary duct was situated too posteriorly to reach the graft common bile duct. Other authors have suggested the end-to-end cava anastomosis performing a standard LT with the removal of vena cava and the positioning of a water balloon in the right-upper quadrant in order to avoid unwanted movement of the liver graft.⁵

The present case is the first using a donor over 65 years old; in fact all the previously described cases used a young donor in conditions in which it would be difficult to refuse an organ with suboptimal anatomical conditions. Also our case is the first using a Belghiti (Belghiti-1992) piggyback technique with the smaller hemiliver in the right upper abdominal quadrant. The small size of the graft, in this case, resulted in a great technical advantage because, at the implant stage, the right hemiliver was easily rotated in the right liver fossa, enabling the surgeon to safely perform the side-to-side vena cava anastomosis. In order to avoid cava anastomosis kinking, we decided to perform this vena cava anastomosis only after seeing *the liver comfortably placed* in the recipient abdomen. In this way, the donor bile duct was located on the same axis as the recipient duct and an end-to-end bile duct anastomosis was easily performed, thus avoiding the Roux en-Y choledochojejunostomy.

We believe that the SIT status should not be considered a contraindication for LT and should be ranked in the marginal donors category. If the donor–recipient size match permits a comfortable placement of the graft in a standard anatomical position, the situs inversus of the donor does not require any modification of surgery, and the piggyback technique with a large side-to-side cava anastomosis should be the preferred technique. This permits the placement of the graft in its natural position and avoids the Roux en-Y choledochojejunostomy.

Conflict of interest

The authors have no conflict of interest to disclose.

Funding

No funding sources were received to support the study.

Ethical approval

Written informed consent was obtained from the patient for publication of this case report and accompanying images. A copy of the written consent is available for review by the Editor-in-Chief of this journal on request.

Author contributions

Tommaso Maria Manzia and Roberta Angelico wrote the paper; Luca Toti, Alessandro Anselmo collected the data. Giuseppe Tisone and Laura Tarcioni designed the study.

Key learning point

- Liver transplantation using a marginal donor with situs inversus totalis is feasible and safe and should not be considered as a relative contraindication to liver transplantation.

Acknowledgments

Mrs. Serena Rotunno and Dr. Anna De Francesco provided invaluable assistance in English revision of the manuscript. We thank Dr. Piero Rossi for the photos.

References

1. Sugawara Y, Makuuchi M, Takayama T, Yoshino H, Mizuta K, Kawarasaki H. Liver transplantation from situs inversus to situs inversus. *Liver Transpl* 2001;**7**(9):829–30.
2. Asfar S, Ozcay N, Grant D, Wall W. Transplantation of the liver from a donor with complete situs inversus and dextrocardia. *Transplantation* 1995;**59**(3):442–4.
3. Herrera LA, Castillo J, Martino E, Rabanal JM, Fleitas MG. Orthotopic liver transplantation from a donor with abdominal situs inversus. *Transplantation* 1996;**62**(1):133–5.
4. Pomposelli JJ, DaCosta MA, McPartland K, Jenkins RL. Retroversus implantation of a liver graft: a novel approach to the deceased donor with situs inversus totalis. *Am J Transplant* 2007;**7**(7):1869–71.
5. Dou J, Yang T, Cao JL, Gao QJ, Su YL, Zhu ZJ. Classical orthotopic liver transplantation from a donor with situs inversus totalis using slight rotation of the liver graft. *Chin Med J (Engl)* 2010;**123**(10):1353–5.
6. Braun F, Rodeck B, Lorf T, Canelo R, Wietzke P, Hartmann H, Ramadori G, Ringe B. Situs inversus of donor or recipient in liver transplantation. *Transpl Int* 1998;**11**(3):212–5.
7. Sun XY, Qin K, Dong JH, Li HB, Lan LG, Huang Y, Cao S, Li ZJ. Liver transplantation using a graft from a donor with situs inversus totalis: a case report and review of the literature. *Case Rep Transplant* 2013;(sep 10). Epub 2013.

Open Access

This article is published Open Access at scimedirect.com. It is distributed under the [IJSCR Supplemental terms and conditions](#), which permits unrestricted non commercial use, distribution, and reproduction in any medium, provided the original authors and source are credited.