

Symptomatic Elongated Styloid Process or Eagle's Syndrome: A Case Report

Hossein Shahoon ^{1*} • Camellia Kianbakht ²

¹Assistant Professor, Department of Oral and Maxillofacial Surgery, Faculty of Dentistry, Shahed University of Medical Sciences, Tehran, Iran

²Dentist, Private Practice, Tehran, Iran

*Corresponding author; E-mail: shahoon11@yahoo.com

Abstract

Elongation of the styloid process or stylohyoid ligament calcification is a well recognized finding of dental practice, and an incidence of 4 to 30 percent has been reported on radiographs. Rarely, complete mineralization of the stylohyoid ligament or elongation of styloid process has been associated with difficulties in intubation and significant clinical symptoms, which is termed Eagle's syndrome, and it exhibits dull or sharp intermittent pain felt along the glossopharyngeal nerve that is located in the hypopharynx and at the base of the tongue and recurrent throat pain or foreign body sensation, dysphagia, or facial pain. Additional symptoms may include neck or throat pain with radiation to the ipsilateral ear. In the case presented, the elongated process caused a broad tenderness in left lateral and posterior cervical as well as temporal regions.

Key words: Eagle's syndrome, stylocarotid syndrome, elongated styloid process.

Introduction

In 1652, Pietro Marchetti, a surgeon from Padua, observed an elongation of the styloid process related to an ossifying process of the stylohyoid ligament. Weinlecher described symptoms related to an elongated styloid process in 1872. It was Eagle (1937 and 1949) who first defined stylalgia as an autonomous entity related to abnormal length of the styloid process or to mineralization of the stylohyoid ligament complex.^{1,2} Eagle's syndrome was described by Eagle as styloid Process of more than 25 mm long, or when there is calcification of the stylomandibular ligament.³ It can cause pharyngeal and cervical pain on swallowing, speaking, opening of the mouth, or during movement of the cervical region, sensation of a foreign body in the oropharynx, or pain radiating to the ear.^{4,5}

The etiology and pathogenesis of this syndrome are controversial. According to Eagle, a previous surgical trauma such as tonsillectomy, or a chronic irritation of the stylomandibular ligament, could cause osteitis, tendonitis, or periostitis, which could lead to reactive ossifying hyperplasia

of the styloid process. Other authors have suggested hypotheses such as osseous metaplasia of the Reichert cartilage residues, persistence of mesenchymal elements capable of producing bone tissue in adults, and ossification of the stylohyoid ligament related to endocrine disorders.³

The frequency of ossification of the styloid chain—styloid process, stylohyoid ligament and greater horn of the hyoid bone—has been found to vary from 4% to 30% and to be mostly asymptomatic. Eagle estimated the frequency of 3–4% for symptoms in patients presenting an elongated styloid process.⁶ The incidence of elongated styloid process is reported to be 4 to 7%. Only 4 to 10.3% of patients with an elongated styloid process are reported to experience pain.⁷

Eagle postulated that there are two types of the syndrome that came to bear his name: the classic type and the carotid artery type.¹ The average length of the styloid process has been shown to be less than 3 cm with the normal length ranging from 1.52 cm to 4.77 cm; only 11 of 2,000 cranial dissections have detected a styloid process longer

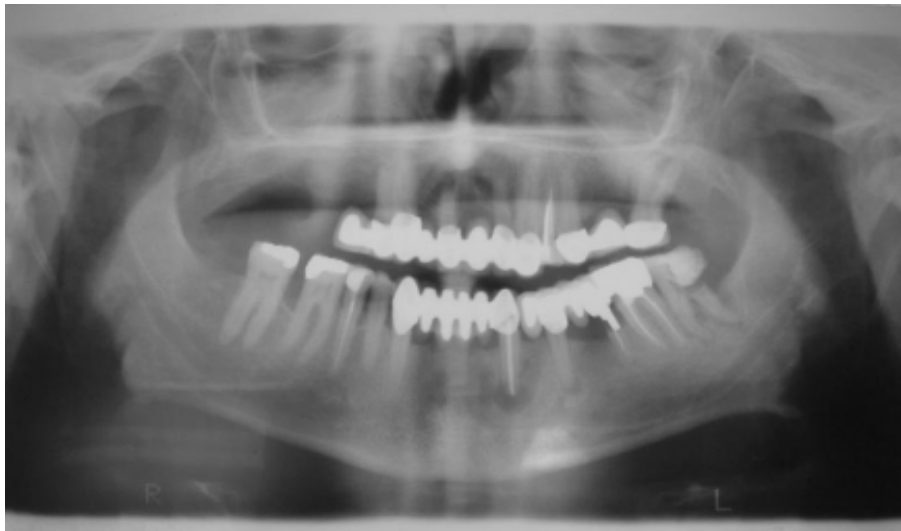

Figure 1. Panoramic radiograph of patient showing the elongated styloid process.

than 4 cm. However, the length of the styloid process has not been found to be correlated to the severity of pain.⁸ In this report, we describe a case of Eagle's syndrome that was characterized by a broad tenderness in left lateral and posterior cervical as well as temporal regions.

Case report

A 50-year-old female presented to Shahed University Dental School with a 3-year history of a small swelling on her left lateral pharyngeal region. She also had a sharp pain for one year on the left side of her neck radiating to temporal and posterior cervical regions. The pain had led to a disability in raising the left arm even for daily activities. However, there was no facial pain. Patient had sought medical care for the pain several times without a definitive diagnosis or treatment.

In the extra-oral examination, patient's frontal view was symmetric. During the examination, temporomandibular joint was found to be normal,

and maximum mouth opening was in the normal range. Examination of the pharynx also revealed no significant findings.

In the intra-oral examination, the patient exhibited a mild xerostomia. The mineralized process was palpable in the left lateral pharyngeal region, and was associated with tenderness.

A panoramic radiograph was taken (Figure 1), and a diagnosis of Eagle's syndrome was made based on clinical and radiographic findings.

Under local anesthesia and intravenous sedation, resection of approximately two-thirds of elongated styloid process was performed (Figure 2). In three day follow-up, patient was completely symptom-free.

Discussion

The styloid process is a slender bony projection arising from the lower surface of the petrous portion of the temporal bone. This process originates from Reichert's cartilage of the second brachial arch and persists as a structure running from the base of the skull to the lesser horn of the hyoid, passing between the internal and external carotid arteries. It is also adjacent to the glossopharyngeal and vague nerves.⁴

Elongation of the styloid process or stylohyoid ligament calcification is a well recognized finding of dental practice. Most cases are asymptomatic; however, a small number of such patients experience symptoms of Eagle's syndrome, related to the compression of adjacent nerves and blood vessels.

The length of the styloid process is individually variable and according to Lindeman,⁹ it is 2-3 cm long. A 'long' styloid process has been defined as more than 4 cm, since in this situation, the highest incidence of Eagle's syndrome occurs.¹⁰ But according to recent studies, the normal range of its

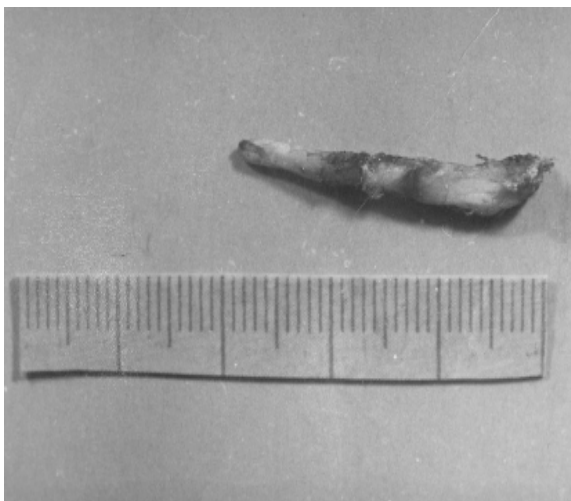


Figure 2. Resected portion of styloid process is approximately 3 cm.

size varies from 1.52 to 4.77 cm.⁸ The elongation length styloid process in the present case was comparable to the above-mentioned findings, as the surgically removed portion was 3 cm and at least 1 cm was left intact. This syndrome is found more often in females and affects subjects more than 50 years old most often, as did in our case.¹¹

The pathogenesis of elongated styloid process is still a matter of debate. Eagle proposed surgical trauma or local chronic irritation could cause consequent reactions like ossifying hyperplasia. Later, different hypotheses formulated such as osseous metaplasia of the Reichert cartilage residues, persistence of mesenchymal elements capable of producing bone tissue in adults, and ossification of the stylohyoid ligament related to endocrine disorders in women at menopause.³ In this case, since the patient did not have a history of trauma to the region, the pathogenesis is likely to be related to endocrine disorders of the patient who was at menopause.

In cases reported by Eagle,¹ pharyngeal discomfort associated with elongated styloid process including vague facial pain, especially while swallowing, turning the head, or opening the mouth was present. However, the present case exhibited a broad tenderness in the neck and left arm, without any facial pain. Other symptoms may include dysphagia, dysphasia, otalgia, dizziness, and transient syncope.

Eagle originally described two distinct syndromes: the classic Eagle's syndrome (classical stylohyoid syndrome) and carotid artery syndromes (stylocarotid syndrome). The classic Eagle's syndrome develops by fibrous tissue formation in the area of a mineralized stylohyoid complex, distorting the cranial nerve endings in the tonsillar fossa following tonsillectomy. It is characterized by dull and persistent pharyngeal pain especially in the tonsillar area, accompanied occasionally by dysphagia and painful swallowing, foreign body sensation, as much as facial and/or cervical pain. A second form of this condition which is not dependent upon tonsillectomy is known as carotid artery syndrome or stylocarotid syndrome. The elongated, mineralized complex is thought to impinge on the internal or external carotid arteries and associated sympathetic nerve fibers. The patient's complaint is cervical pain while turning the head, i.e. when the carotid artery is compressed, which may be radiated to the other sites the artery supplies. In order to diagnose Eagle's syndrome, it is necessary to obtain an accurate case history to define the type of the syndrome.^{12,13} In our case, an intense pain in the left lateral region of the neck radiating to the tem-

poral and posterior cervical regions was present. Since the elongated apparatus compresses the adjacent nerves, palpation of the neck near the trapezius muscle elicited tenderness and the pain radiated to her ipsilateral arm. These findings directed us to diagnose the second type of Eagle's syndrome (stylocarotid syndrome).

The treatment for Eagle's syndrome may be medical or surgical. Medical treatment consists of infiltration of steroids or local anesthetics, or oral administration of carbamazepine. However, the long-term results of medical treatment are not satisfactory.¹⁴ The styloid process may be partially removed by intra- or extra-oral approaches. The extra-oral approach has the advantage of providing better visualization of the operative field, and it is possible to resolve any vascular injury without major complications. However, there are some disadvantages, such as the complexity of the technique that demands longer operating time, and an external scar that is not cosmetically pleasing. The intra-oral approach has advantages over the extra-oral technique in that it is quicker and easier to perform, eliminates the need for extensive dissection considering the risks in the cervical region, and does not leave an external scar.¹⁵

Other factors other than only a long styloid process may give rise to Eagle's syndrome. An accurate case history and the specialist's intuition are fundamental to the differential diagnosis regarding several other pharyngo-cranio-facial pain disorders. Eagle's syndrome should be considered in the evaluation of patients with recurrent throat and neck pain. In the opinion of the authors, surgical treatment should be the first choice with the trans-oral approach being the preferable technique. This approach avoids potential injury to important structures of the maxillo-vertebro-pharyngeal space and is characterized by a short operation as well as an absence of visible scars and reduced hospitalization period.

References

1. Eagle W. Elongated styloid process: Report of two cases. *Arch Otolaryngol* 1937;25:584-7.
2. Eagle W. Symptomatic elongated styloid process: Report of two cases of styloid process carotid artery syndrome with operation. *Arch Otolaryngol* 1949;49:490-3.
3. de Souza Carvalho AC, Magro Filho O, Garcia IR Jr, de Holanda ME, de Menezes JM Jr. Intraoral approach for surgical treatment of Eagle syndrome. *Br J Oral Maxillofac Surg* 2009;47:153-4.
4. Rechtweg JS, Wax MK. Eagle's Syndrome: A Review. *Am J Otolaryngol* 1998;19:316-21.
5. Prasad KC, Kamath MP, Reddy KJ, Raju K, Agarwal S. Elongated styloid process (Eagle's Syn-

- drome): A clinical study. *J Oral Maxillofac Surg* 2002;60:171–5.
6. Klécha A, Hafian H, Devauchelle B, Lefèvre B. A report of post-traumatic Eagle's syndrome. *Int J Oral Maxillofac Surg* 2008;37:970–2.
 7. Murtagh RD, Caracciolo T, Fernandez G. CT findings associated with Eagle syndrome. *AJNR Am J Neuroradiol* 2001;22: 1401–2.
 8. Kim E, Hansen K, Frizzi J. Eagle syndrome: Case report and review of the literature. *Ear Nose Throat J* 2008;87:631–3.
 9. Lindeman P. The elongated styloid process as a cause of throat discomfort. *J Laryngol Otol* 1985;99: 500–8.
 10. Mansour P, Young WJ. Variability of the styloid process and stylohyoid ligament in panoramic radiographs. *Oral Surg Oral Med Oral Pathol* 1986;61:522–6.
 11. Fini G, Gasparini G, Filippini F, Becelli R, Marcotullio D. The long styloid process syndrome or Eagle's syndrome. *J Craniomaxillofac Surg* 2000;28:123–7.
 12. Bafaqeeh SA. Eagle syndrome: Classic and carotid artery types. *J Otolaryngol* 2000;29:88–94.
 13. Vaidhyanath R, Kenningham R. Elongated styloid process or Eagle's syndrome. *Br J Hosp Med (Lond)* 2008;69:354.
 14. Ceylan A, Koybasioglu A, Celenk F, Yilmaz O, Uslu S. Surgical treatment of elongated styloid process: Experience of 61 cases. *Skull Base* 2008;18:289–95.
 15. Blythe JN, Matthews NS, Connor S. Eagle's syndrome after fracture of the elongated styloid process. *Br J Oral Maxillofac Surg* 2009;47:233–5.